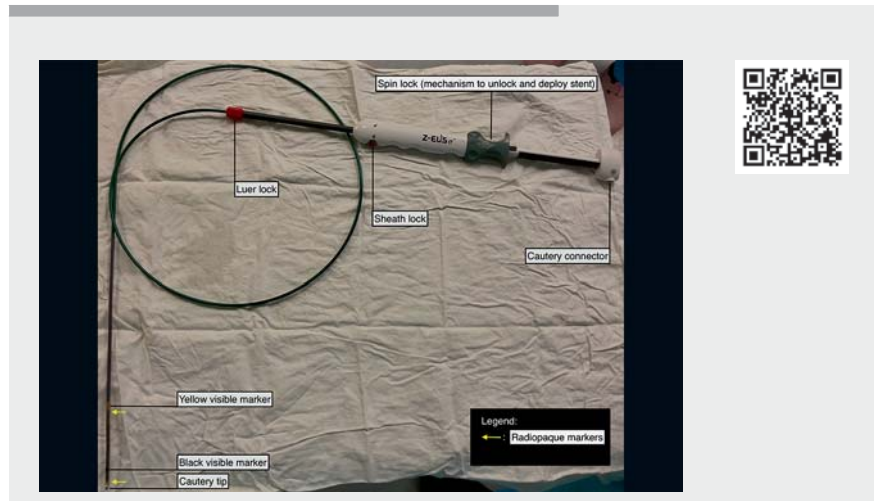


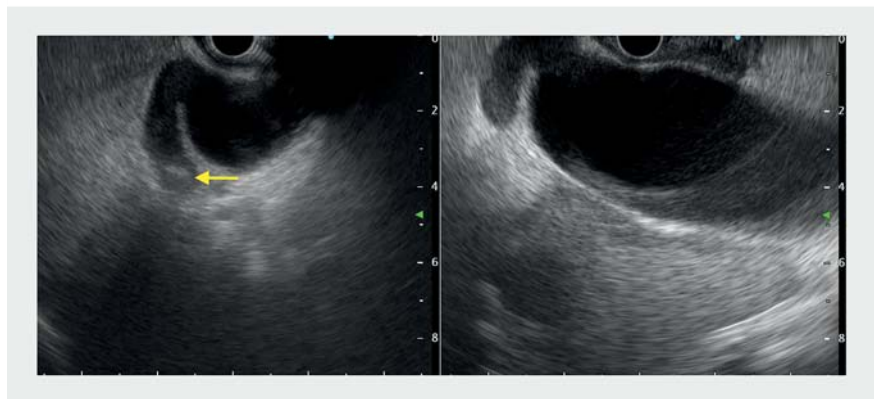Endoscopic ultrasound-guided gallbladder drainage using a novel cautery-enhanced, endoscopist-deployed lumen-apposing metal stent

OPEN
ACCESS

An 85-year-old woman presented with right upper abdominal pain and fever. Examination revealed tenderness in the right hypochondrium with a positive Murphy's sign. White cell count was $16.3 \times 10^9/L$, but liver function was normal. Transabdominal ultrasound confirmed acute cholecystitis with a 6-mm cystic duct stone. Owing to the patient's pre-existing Alzheimer's disease and frail pre-morbid condition, we decided for endoscopic ultrasound-guided gallbladder drainage (EUS-GBD) after discussion with the patient's main caregiver [1–3]. The procedure was performed in an endoscopy suite with fluoroscopy capabilities and the patient was placed in the prone position under conscious sedation (► **Video 1**). A linear echoendoscope (GF-UCT260; Olympus, Tokyo, Japan) was advanced to the first part of the duodenum and a distended gallbladder up to 10 cm and a 6-mm cystic duct stone were identified (► **Fig. 1**). There were no stones in the common bile duct. EUS-GBD was performed via direct puncture with a novel cautery-enhanced, lumen-apposing metal stent (LAMS) (Hanarostent Z-EUS IT; M.I. Tech, Gyeonggi-do, South Korea) (► **Fig. 2**). This is a 12 mm (diameter) × 30 mm (length) fully-covered, lumen-apposing stent with an inter-flange distance of 22 mm. The opening and deployment of the proximal and distal flanges of the stent were fully controlled by the endoscopist. The opening of the distal flange was confirmed on endoscopic ultrasound (EUS) (► **Fig. 3**), while the proximal flange was visualized endoluminally (► **Fig. 4**). The procedure took 20 minutes and there was good drainage of purulent bile at the end. Abdominal X-ray confirmed a good stent opening and the presence of the air cholecystogram (► **Fig. 5**). The patient's fever subsided and her white cell count normalized by day two after the procedure and she was discharged with a one-week course of oral antibiotics.



► **Video 1** Use of a novel cautery-enhanced, endoscopist-deployed lumen-apposing metal stent to perform endoscopic ultrasound-guided gallbladder drainage.




► **Fig. 1** Endoscopic ultrasound images of a distended gallbladder and cystic duct stone. Arrow (←) shows the cystic duct stone.

The availability of a cautery-enhanced, endoscopist-deployed LAMS allows precise stent placement under EUS guidance to drain the gallbladder into the duodenum. It makes for safer stent deployment in tight spaces and reduces the need for an experienced assistant.

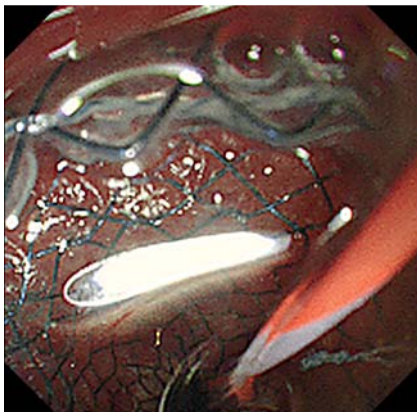
Endoscopy_UCTN_Code_TTT_1AS_2AD

Competing interests

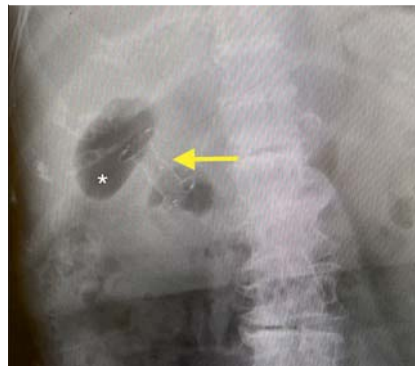AYB Teoh is a consultant for Boston Scientific, Cook Medical, Taewoong Medical, Microtech Medical, and M.I. Tech Medical Corporations. LWL Ong, SM Chan, and HC Yip declare no conflicts of interest.



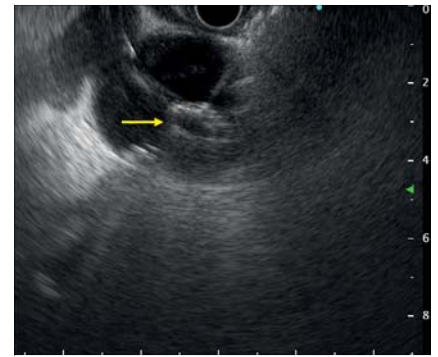
► Fig. 2 The cautery-enhanced, lumen-apposing metal stent.



► Fig. 4 Endoluminal image of the proximal flange of the fully deployed stent.



► Fig. 5 Abdominal X-ray of the stent and air cholecystogram. Arrow (←) shows the lumen-apposing metal stent; * shows the air cholecystogram.



► Fig. 3 Endoscopic ultrasound image of the distal flange of stent fully deployed. Arrow (→) shows the distal flange of the stent.

References

- [1] James TW, Baron TH. EUS-guided gallbladder drainage: a review of current practices and procedures. *Endosc Ultrasound* 2019; 8: S28–S34
- [2] Teoh AYB, Kitano M, Itoi T et al. Endosonography-guided gallbladder drainage versus percutaneous cholecystostomy in very high-risk surgical patients with acute cholecystitis: an international randomised multicentre controlled superiority trial (DRAC 1). *Gut* 2020; 69: 1085–1091
- [3] Cho SH, Oh D, Song TJ et al. Comparison of the effectiveness and safety of lumen-apposing metal stents and anti-migrating tubular self-expandable metal stents for EUS-guided gallbladder drainage in high risk surgical patients with acute cholecystitis. *Gastrointest Endosc* 2020; 91: 543–550

Bibliography

Endoscopy 2022; 54: E800–E801

DOI 10.1055/a-1806-1646

ISSN 0013-726X

published online 6.5.2022

© 2022. The Author(s).

This is an open access article published by Thieme under the terms of the Creative Commons Attribution-NonDerivative-NonCommercial License, permitting copying and reproduction so long as the original work is given appropriate credit. Contents may not be used for commercial purposes, or adapted, remixed, transformed or built upon. (<https://creativecommons.org/licenses/by-nc-nd/4.0/>)
Georg Thieme Verlag KG, Rüdigerstraße 14, 70469 Stuttgart, Germany



The authors

Lester Wei Lin Ong^{1,2}, Shannon Melissa Chan¹, Hon Chi Yip¹, Anthony Yuen Bun Teoh¹

1 Department of Surgery, Prince of Wales Hospital, The Chinese University of Hong Kong, Hong Kong

2 Department of General Surgery, Sengkang General Hospital, Singapore

Corresponding author

Anthony Yuen Bun Teoh, MD

Department of Surgery, Prince of Wales Hospital, The Chinese University of Hong Kong, Central Avenue, 999077 Hong Kong, China

Fax: +852-3505-7974

anthonyteoh@surgery.cuhk.edu.hk