

## EDUCATIONAL FORUM

# Real-Time Fusion Imaging of Liver Ultrasound



Shen-Yung Wang<sup>1\*</sup>

<sup>1</sup> Division of Gastroenterology, Department of Medicine, MacKay Memorial Hospital Tamsui Branch, Taiwan

Received 13 February 2017; accepted 28 February 2017  
Available online 27 March 2017

## Background and principles of ultrasound fusion imaging

Ultrasound plays an extremely important role in the clinical diagnosis and treatment of liver diseases. Because ultrasound can conveniently provide different types of liver images, liver ultrasound is widely used in the clinical diagnosis and treatment of liver diseases. Although this imaging technique is mature and stable, some issues affecting the clinical application of liver ultrasound remain. Inconsistencies between computed tomography (CT) scan, magnetic resonance imaging (MRI), and liver ultrasound images for focal liver lesions are not uncommon in clinical practice. Because CT or MRI images consist of cross-sectional and coronal and sagittal plane images, how to accurately identify the foci of interest in these images using real-time B-mode ultrasound images conventionally requires the ultrasound operator to mentally rearrange CT or MRI images into the planes corresponding to the real-time B-mode ultrasound locations. However, this process requires considerable training and experience. Although liver ultrasound does not require the use of additional instruments, operator mistakes do occur. When performing liver ultrasound scans, air in the lungs and intestinal gas frequently interfere with the acoustic window, and small or inconspicuous foci may be concealed in locations not easily observed on ultrasound

images. Finally, operators sometimes mistake false foci in the liver ultrasound images as the target foci, which may be erroneously subjected to treatment.

Real-time fusion imaging can simultaneously fuse two different images, which may be images acquired earlier (such as CT, MRI, or even ultrasound contrast agent images) or real-time liver ultrasound images. The main principles involved in this method are the use of an electromagnetic field generator and receiver to determine the spatial location and direction of the ultrasound probe, and the use of a computer to aid in spatial target matching involving different images. Because of advances in computational power and software technology, this method can now analyze and reconstruct images acquired earlier in real time, and allows images acquired earlier to be synchronously fused in real time with the ultrasound images currently being acquired as the ultrasound probe moves over the patient's body.

## How is real-time ultrasound fusion imaging of the liver performed?

Preliminary tasks for real-time ultrasound fusion imaging of the liver include set up and positioning of the patient, electromagnetic field apparatus, and ultrasound machine. First, the patient is asked to assume a relaxed posture,

Conflicts of interest: The author has no conflicts of interest to declare.

\* Correspondence to: Shen-Yung Wang, Division of Gastroenterology, Department of Medicine, MacKay Memorial Hospital Tamsui Branch, 47, Minquan Road, Tamsui District, New Taipei City 25173, Taiwan.

E-mail address: [sywang@mmh.org.tw](mailto:sywang@mmh.org.tw).

<http://dx.doi.org/10.1016/j.jmu.2017.03.003>

0929-6441/© 2017, Elsevier Taiwan LLC and the Chinese Taipei Society of Ultrasound in Medicine. This is an open access article under the CC BY-NC-ND license (<http://creativecommons.org/licenses/by-nc-nd/4.0/>).

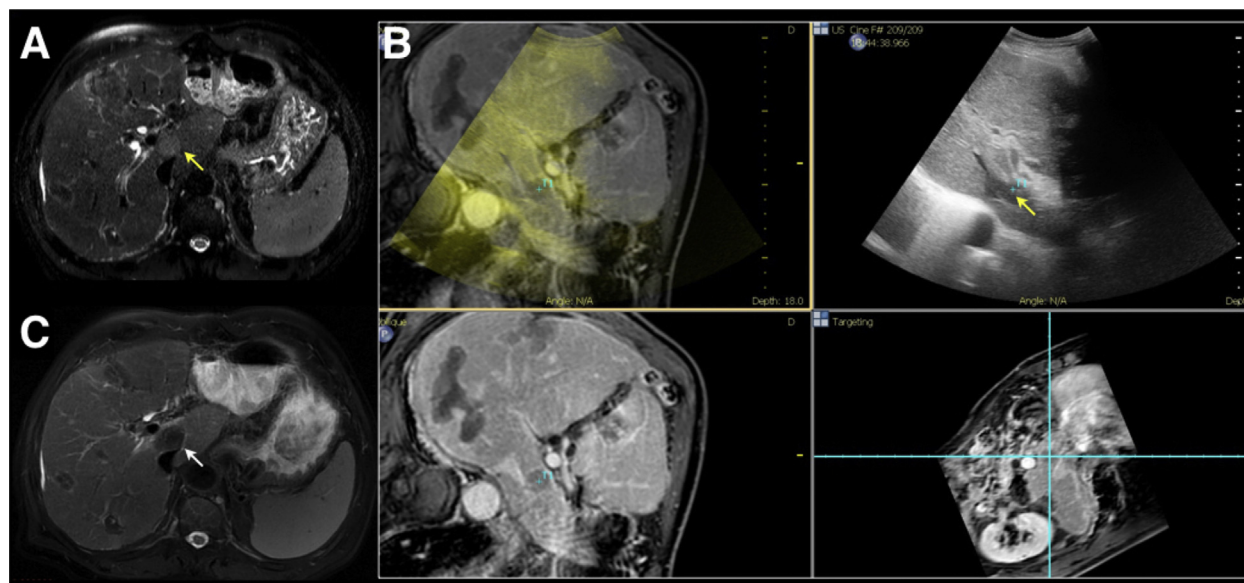
which he or she can maintain for a certain period, as patient movements will influence the accuracy of comparison when performing real-time ultrasound fusion imaging. Second, the probe sensors are connected; if there is a mobile electromagnetic field generator, it must be moved to an appropriate location. Because ultrasound systems from different vendors may use different electromagnetic tracking technologies, there are also differences in optimal electromagnetic field generator location, but the ultimate solution is to ensure that the displayed probe-sensing strength is at an acceptable level across the field of liver examination. Third, CT or MRI images stored on a server or storage medium are retrieved. Finally, image fusion begins after these preliminary tasks have been completed. The electromagnetic field generator will be initiated, and the ultrasound machine will then acquire dynamic ultrasound images. In accordance with the positioning point, plane, and three-dimensional (3D) data, the spatial information contained in the CT or MRI and ultrasound images will be corrected so that the two sets of images can be fused and displayed in real time.

In general, any of the following methods can be used to generate corresponding fusion coordinates. First, an external device is put on the patient's body while receiving a CT scan. The fusion ultrasound is then performed, and the external tracking device is operated either manually or automatically as a match coordinate. Second, the match can be performed on a point-to-point basis. The operator can assign the corresponding points within the liver on different images as internal positioning coordinates. Usually, more than three coordinates are required for a successful fusion registration. Third, the match can be

performed on the two-dimensional basis. The operator moves the ultrasound probe to a plane of acquiring images corresponding to one of the previous CT or MRI images, which are normally in a cross-sectional plane as positioning planes, and assign the corresponding plane as the matching coordinates. Fourth, the match is performed based on 3D information. This is a relatively new method that involves using an ultrasound probe to acquire 3D ultrasound images, after which a computer compares and matches them with the 3D-reconstructed spatial coordinates from CT or MRI images.

### Application of real-time ultrasound fusion imaging for liver tumor ablation

Percutaneous minimal invasive therapies, especially radiofrequency ablation, have been confirmed to be a very effective means of treating early small hepatocellular carcinoma. Indeed, radiofrequency ablation is currently an important therapeutic option for the treatment of liver cancer and is widely accepted in Taiwan and worldwide. Precise placement of ablation probes is directly related to the therapeutic efficacy of radiofrequency ablation. Compared with CT guidance, placement of ablation probes on ultrasound guidance saves money and time, is more efficient, and exposes the patient to less radiation. Thus, real-time ultrasound fusion imaging offers many benefits (Figure 1) during interventional therapy of liver cancer [1]. Previous studies have shown that when assisted by real-time ultrasound fusion imaging, the detection of inconspicuous hepatocellular carcinoma that is not apparent in



**Figure 1** Use of ultrasound fusion imaging of the liver in radiofrequency ablation of hepatocellular carcinoma (HCC). (A) A 2-cm HCC can be seen at S1 (arrow) in a T2 magnetic resonance imaging (MRI) image. (B) Ultrasound fusion imaging is used to confirm that the hypoechoic focus at S1 seen under ultrasound is the focus displaying early wash-out characteristics under the portovenous phase of MRI. (C) The HCC has been completely ablated (arrow) after the patient received ultrasound-guided percutaneous radiofrequency ablation.

B-mode ultrasound images is significantly improved [2], and the possibility of successful percutaneous radiofrequency ablation is increased [3,4]. Furthermore, other studies have pointed out that real-time ultrasound fusion imaging has a higher detection rate than conventional B-mode ultrasound in the case of small hepatocellular carcinomas less than 2 cm in size [5].

During the radiofrequency ablation treatment for liver cancer, the generation of gas bubbles can make it difficult to perform real-time assessment of the ablation probe location and to determine whether or not the ablation is appropriate using conventional B-mode ultrasound. By contrast, real-time fusion imaging can provide an understanding of whether or not the probe location and ablation zone are appropriate based on comparison with images acquired earlier [6]. Although it is sometimes difficult to assess recurrence or the presence of residual liver cancer foci after locoregional treatment using ultrasound, fusion imaging can match the cancer foci discovered in CT or MRI examinations with dynamic ultrasound images in real time, enhancing the possibility and accuracy of interventional ablation therapy, and reducing treatment errors and possible related complications.

### Use of an automatic registration system in real-time ultrasound fusion imaging of the liver

Compared with previous generation of fusion imaging ultrasound systems, which are usually impacted by slow and discontinuous operation due to insufficient computer processing power, most real-time fusion ultrasound systems currently available on the market strive to improve and simplify fusion operating processes; however, the assignment of matching points or planes still requires considerable training and experience to achieve acceptable accuracy of fusion ultrasound imaging of the liver, and achieving satisfactory fusion results may be impossible in some difficult cases, even after expending much time.

Automatic registration systems constitute a novel means of performing registration automatically in real-time ultrasound fusion imaging [7]. This method primarily involves the use of a 3D ultrasound probe or hand-moved two-dimensional ultrasound probe to acquire 3D ultrasound images, after which a computer automatically calculates the geometry of intrahepatic blood vessels (requires contrast-enhanced scan images) or the contour of the liver surface shown in 3D ultrasound and CT images. After processing, the computer will automatically match the 3D spatial coordinates in the two sets of images. Under ideal circumstances, this approach can automatically complete image fusion within 1 minute. This new advancement not only greatly reduces barriers for operators to perform such imaging technique and eases the operator learning curve,

but also reduces possible human influence, simplifies procedures, and shortens the working time [8].

### Conclusion

While liver ultrasound is an indispensable tool in clinical medicine, it still has certain limitations for the diagnosis or for performing interventional procedures of focal liver lesions. Real-time ultrasound fusion imaging of the liver is a novel advanced technology in ultrasound imaging and is gaining more acceptance. After ultrasound images and other images acquired previously are synchronized, it is possible to perform further diagnosis and interventional therapy of focal liver lesions that are difficult to discover using conventional B-mode ultrasound. The development of this technique in recent years has greatly simplified the operating process and shortened the time required. Real-time ultrasound fusion imaging of the liver can facilitate ablation therapy of liver cancer in cases where treatment using conventional ultrasound is difficult or impossible, while boosting the possibility and accuracy of interventional ablation therapy and enhancing therapeutic effectiveness.

### References

- [1] Makino Y, Imai Y, Igura T, et al. Usefulness of the multimodality fusion imaging for the diagnosis and treatment of hepatocellular carcinoma. *Dig Dis* 2012;30:580–7.
- [2] Min J, Lim H, Lim S, et al. Radiofrequency ablation of very-early-stage hepatocellular carcinoma inconspicuous on fusion imaging with B-mode US: value of fusion imaging with contrast-enhanced US. *Clin Mol Hepatol* 2014;20:61–70.
- [3] Makino Y, Imai Y, Ohama H, et al. Ultrasonography fusion imaging system increases the chance of radiofrequency ablation for hepatocellular carcinoma with poor conspicuity on conventional ultrasonography. *Oncology* 2013;84:44–50.
- [4] Song K, Lee M, Rhim H, et al. Fusion imaging-guided radiofrequency ablation for hepatocellular carcinomas not visible on conventional ultrasound. *AJR Am J Roentgenol* 2013;201:1141–7.
- [5] Lee M, Rhim H, Cha D, et al. Planning US for percutaneous radiofrequency ablation of small hepatocellular carcinomas (1–3 cm): value of fusion imaging with conventional US and CT/MR images. *J Vasc Interv Radiol* 2013;24:958–65.
- [6] Sakakibara M, Ohkawa K, Katayama K, et al. Three-dimensional registration of images obtained before and after radiofrequency ablation of hepatocellular carcinoma to assess treatment adequacy. *AJR Am J Roentgenol* 2014;202:W487–95.
- [7] Wein W, Brunke S, Khamene A, et al. Automatic CT-ultrasound registration for diagnostic imaging and image-guided intervention. *Med Image Anal* 2008;12:577–85.
- [8] Kim AY, Lee MW, Cha DI, et al. Automatic registration between real-time ultrasonography and pre-procedural magnetic resonance images: a prospective comparison between two registration methods by liver surface and vessel and by liver surface only. *Ultrasound Med Biol* 2016;42:1627–36.