

Delayed retropharyngeal hematoma following a minor facial blunt trauma

Yuya Kitai^{a,*}, Ryota Sato^b

^a Department of Emergency Medicine, Nerima Hikarigaoka Hospital, Tokyo, Japan

^b Department of Critical Care Medicine, Respiratory Institute, Cleveland Clinic, Cleveland, OH, United States of America

ARTICLE INFO

Keywords:

Delayed retropharyngeal hematoma
Airway obstruction
Minor blunt trauma

ABSTRACT

We described the case of 75 years old male patient with an airway obstruction due to retropharyngeal hematoma that developed after a minor blunt trauma to the face. The patient was not taking any anticoagulants or antiplatelet agents and did not have any coagulopathy. This case report indicates that emergency physicians must be aware of the risk of delayed airway obstruction in elderly patients regardless of whether the patient is using anticoagulants or antiplatelet agents.

Introduction

Airway obstruction caused by retropharyngeal hematoma after a head and neck blunt trauma is a rare but can be a life-threatening complication. Delayed retropharyngeal hematoma can occur even in the absence of any symptoms or irregular imaging findings at the initial assessment.

We describe the case of 75 years old male patient with an airway obstruction due to retropharyngeal hematoma that developed after a minor blunt trauma to the face.

Case report

A 75-year-old man who fell from a ladder while cutting down a tree at a height of 2.5 m was brought to the emergency department. The patient hit his face on the tree, then on the roof, and fell with his knees on the ground. Upon presentation, he denied loss of consciousness and was not taking any antiplatelet agent and anticoagulant.

Results of a physical examination showed that he was not in acute distress, with the following vital signs: blood pressure, 146/70 mmHg; heart rate, 56 beats/min; respiratory rate, 24/min; oxygen saturation, 98% in room air; and body temperature, 36.2 °C. He had minor abrasions on the face that did not require a suture, and tenderness on his left chest wall and scapula was present. Neither stridor nor wheeze was detected. There were no negative neurological findings.

Laboratory tests revealed a hemoglobin level of 11.2 g/dL and platelet count of 194,000/ μ L. His activated partial thromboplastin time was 31.7 s, and international normalized ratio of prothrombin time was 1.08.

Cervical computed tomography (CT) scan revealed no evidence of spinal fracture or abnormality of the retropharyngeal space (Fig. 1), but fractures on the left scapula and left fifth metacarpal were found. The emergency physician initially planned to discharge

* Corresponding author at: 2-11-1, Hikarigaoka, Nerima city, Tokyo 179-0072, Japan.
E-mail address: ykitai2019@gmail.com (Y. Kitai).

the patient, with recommendation for outpatient follow-up. However, the patient ended up being hospitalized because he had two brief syncopal episodes with transient bradycardia in the emergency department and thus, underwent observation.

Six hours after the injury, he reported difficulty in swallowing and his neck started to swell. An acute decline in oxygen saturation led to the detection of stridor. An upper airway obstruction was suspected based on this rapid progression. With the finding of tissue swelling around the vocal cords, an emergent tracheal intubation was performed. Immediately after the intubation, a contrast-enhanced cervical CT scan was performed, which showed a retropharyngeal hematoma with extravasation in front of C6 (Fig. 1). The cervical and thyroid arteries were intact, but a minor artery in front of the vertebral body was injured. Conducting angiography-guided embolization was technically difficult, and owing to the risk of further bleeding, surgical decompression was also considered risky. Therefore, his hematoma was conservatively managed.

The circumference of the patient's neck reached a maximum of 45.5 cm on the day after his admission (Fig. 2). On day 6 after admission, he was finally extubated.

The patient was discharged on day 10 after admission without any other significant complication. Follow-up was conducted in the outpatient department 20 days after his injury, which revealed no evidence of dysphagia or airway obstruction.

Discussion

Retropharyngeal hematoma is a rare incident caused by blood accumulation in the retropharyngeal space between the vertebral body and pharyngeal muscles. The causes of retropharyngeal hematoma include anticoagulation, cervical spine trauma, great vessel trauma, iatrogenic injury, foreign bodies, and spontaneous bleeding [1–4]. In most cases, this entity occurs in the setting of coagulopathy. However, in the present case, the patient did not have any coagulopathy.

Most previously reported cases involved patients aged >70 years [5–8]. Elderly patients have multiple risk factors for the formation of hematoma, including laxity of connective tissue. Reports have indicated that in general, retropharyngeal hematomas develop immediately or within hours after the head and neck trauma [9]. However, retropharyngeal hematoma can occur even several days after the minor trauma [10,11]. In the patient in this case report, the bleeding site was at the level of C6 and carotid bifurcation was located at C5. Carotid sinus reflex due to external compression may be suggested on the basis of the presence of vasovagal syncope.

Therefore, emergency physicians need to be aware of the risk of delayed retropharyngeal hematoma and airway obstruction in the first several hours even if initial assessment is unremarkable, particularly in the elderly population. As the present case showed, tissue edema possibly due to venous congestion secondary to the hematoma can make endotracheal intubation difficult. Therefore, staff needs to be aware that difficult airway is possible in these cases.

Conclusion

In this case report, we described a patient with delayed retropharyngeal hematoma after a minor blunt trauma. This case suggests

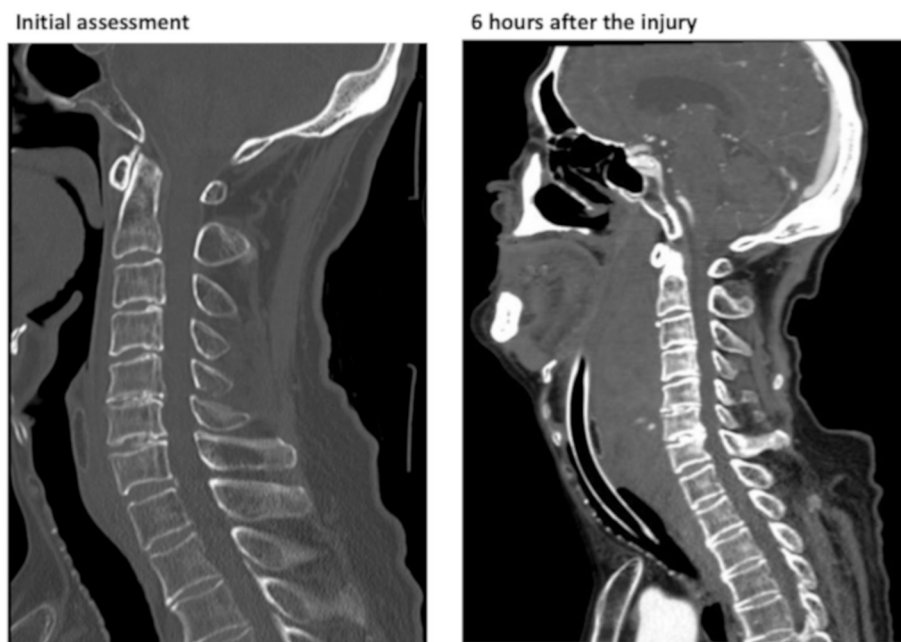


Fig. 1. Cervical CT scan revealed no evidence of spinal fracture or abnormality of the retropharyngeal space at initial assessment. CT at 6 h after injury showed a retropharyngeal hematoma with extravasation in front of C6.

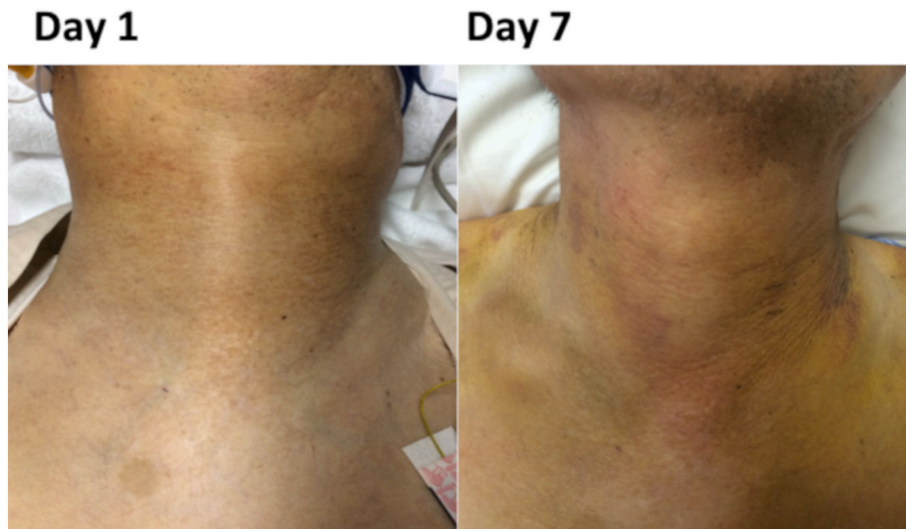


Fig. 2. The circumference of the patient's neck reached a maximum of 45.5 cm on the day after his admission and returned to be a usual state on day 7.

that emergency physicians must be alert to the risk of delayed retropharyngeal hematoma after minor trauma to the face and neck, particularly in the elderly population, irrespective of whether the patient is using anticoagulants or antiplatelet agents.

Funding source

None.

Declaration of competing interest

None.

References

- [1] D.E. Gurr, R.M. Walls, Anti-coagulation and spontaneous retropharyngeal hematoma, *J Emerg Med* 24 (4) (2003) 469–470.
- [2] S. Chiti-Batelli, F. Vaz, S. Coman, Traumatic retropharyngeal haematoma in an anticoagulated patient: case report and proposal for a clinical protocol, *Acta Otolaryngol.* 125 (4) (2005) 443–445.
- [3] C. Duvillard, M. Ballester, P. Romanet, Traumatic retropharyngeal hematoma: a rare and critical pathology needed for early diagnosis, *Eur. Arch. Otorhinolaryngol.* 262 (9) (2005) 713–715.
- [4] R.W. Stewart, M. Hardjasudarma, L. Nall, G. Mathews, R. Davis 2nd, Fatal outcome of jugular vein cannulation, *South. Med. J.* 88 (11) (1995) 1159–1160.
- [5] D. Myssiorek, C. Shalmi, Traumatic retropharyngeal hematoma, *Arch Otolaryngol Head Neck Surg* 115 (9) (1989) 1130–1132.
- [6] J.V. O'Neill, J.M. Toomey, G.G. Snyder 3rd, Retropharyngeal hematoma secondary to minor blunt trauma in the elderly patient, *J. Otolaryngol.* 6 (1) (1977) 43–46.
- [7] C.A. McLauchlan, R. Pidsley, P.J. Vandenberg, Minor trauma—major problem. Neck injuries, retropharyngeal haematoma and emergency airway management, *Arch Emerg Med* 8 (2) (1991) 135–139.
- [8] J.P. Smith, P. Morrissey, R.S. Hemmick, A.F. Haas, B.I. Bodai, Retropharyngeal hematomas, *J Trauma* 28 (4) (1988) 553–554.
- [9] C. El Kettani, R. Badaoui, F.X. Lesoin, D. Le Gars, M. Ossart, Traumatic retropharyngeal hematoma necessitating emergency intubation, *Anesthesiology* 97 (6) (2002) 1645–1646.
- [10] P. Gooder, R. Henry, Impending asphyxia induced by anticoagulant therapy, *J. Laryngol. Otol.* 94 (3) (1980) 347–352.
- [11] R.A. Pollock, J.M. Purvis, D.F. Apple Jr., H.H. Murray, Esophageal and hypopharyngeal injuries in patients with cervical spine trauma, *Ann Otol Rhinol Laryngol* 90 (4 Pt 1) (1981) 323–327.