



Contents lists available at ScienceDirect

# Indian Pacing and Electrophysiology Journal

journal homepage: [www.elsevier.com/locate/IPEJ](http://www.elsevier.com/locate/IPEJ)

## Retrieval of a Micra transcatheter pacing system in a heart with a preexisting lead

Junji Morita<sup>\*</sup>, Masato Fukunaga, Kenichi Hiroshima, Michio Nagashima, Mizuki Miura, Kenji Ando

Department of Cardiology, Kokura Memorial Hospital, Japan

### ARTICLE INFO

#### Article history:

Received 7 March 2018

Received in revised form

19 April 2018

Accepted 24 May 2018

Available online 25 May 2018

#### Keywords:

Dislodgement

Transcatheter pacing system

TPS retrieval

### ABSTRACT

We report the case of a 74-year-old man with a previously implanted pacemaker lead. He had undergone Medtronic™ Micra Transcatheter Pacing System (TPS, Medtronic plc, MN, USA) implantation because of lead fracture. We implanted a new TPS and retrieved the dislodged one. We used a multiple-loop snare (EN snare<sup>®</sup>) and an 8.5F steerable sheath (Agilis NXT; St. Jude Medical, St Paul, MN, USA). The TPS was obstructed by the chordae tendineae of the tricuspid valve and the pacemaker lead. We pushed the TPS to the apex site; this enabled us to move the TPS away from the chordae tendineae and pacemaker lead. The TPS body was caught in the inferior vena cava and was successfully retrieved. To our knowledge, this is the first case reporting TPS retrieval in a heart with preexisting lead.

Copyright © 2018, Indian Heart Rhythm Society. Production and hosting by Elsevier B.V. This is an open access article under the CC BY-NC-ND license (<http://creativecommons.org/licenses/by-nc-nd/4.0/>).

### 1. Introduction

The clinical efficacy of pacemaker therapy is well established. Early and late pacemaker adverse events are mostly associated with the implanted lead. Transcatheter pacing systems (TPS) recently represent an exciting development compared with conventional pacemakers [1].

Few reports on TPS retrieval are present in the literature, but apparent cases of dislodgement are rare [2–4]. We report a case of a TPS with visible dislodgement and its retrieval in a heart with preexisting lead.

### 2. Case report

We report the case of a 74-year-old man with a previously implanted pacemaker lead. In 1999, he had undergone left pectoral single-chamber pacemaker implantation for bradycardia with atrial fibrillation. In 2008, he underwent lead extraction for pocket infection and right pectoral single-chamber pacemaker implantation. In October 2017, the pacemaker pacing capture threshold showed increasing voltage because of the lead fracture, and he

underwent Medtronic™ Micra Transcatheter Pacing System (TPS, Medtronic plc, MN, USA) implantation (Fig. 1A). During this procedure, the pacing threshold fluctuated, particularly during the pull test.

Immediately after the procedure, the TPS exhibited pacing failure and radiographically visible dislodgement.

We opted to implant a new TPS and retrieve the dislodged TPS. Fluoroscopy findings revealed that the dislodged TPS was located near the tricuspid valve. Subsequently, a new TPS was successfully implanted to prevent the bradycardia during the procedure. We utilized a multiple-loop snare (EN snare<sup>®</sup>) and an 8.5F steerable sheath (Agilis NXT; St. Jude Medical, St Paul, MN, USA) after retrieval of the old TPS was unsuccessful using a single-loop snare (Goose Neck Snare). We caught the tines but were unable to pull the device out since the movement of the TPS was obstructed by the chordae tendineae of the tricuspid valve and the pacemaker lead (Fig. 1B; Movie 1).

Supplementary video related to this article can be found at <https://doi.org/10.1016/j.ipej.2018.05.001>.

We pushed the TPS to the apex site; this enabled us to move the TPS away from the chordae tendineae and pacemaker lead (Fig. 1C). We pulled it out from the right ventricle and were able to freely move it in the inferior vena cava.

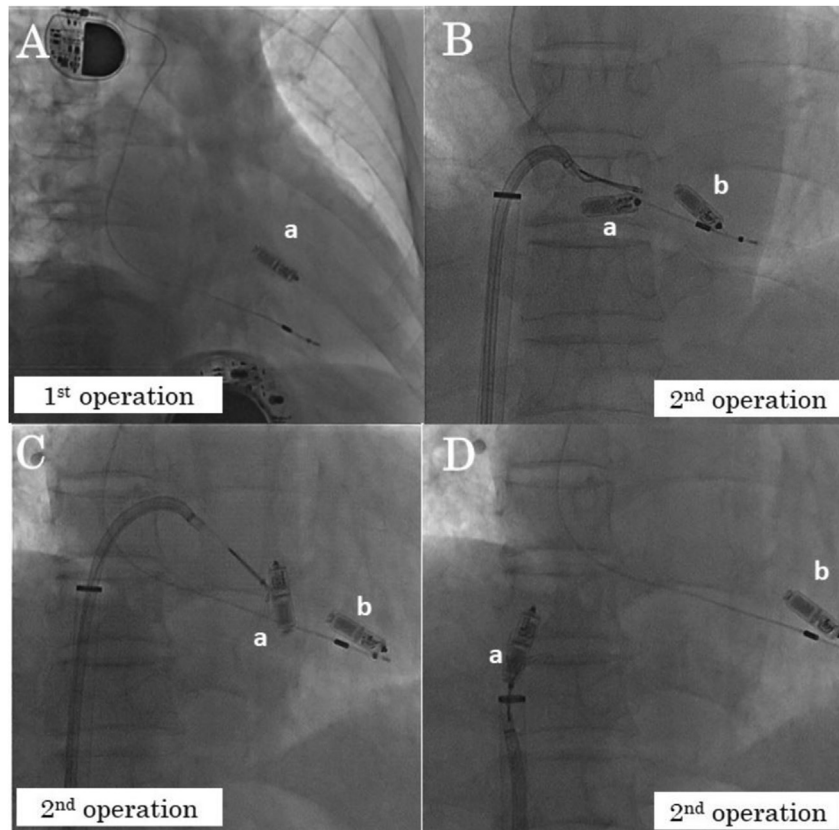
The TPS body was caught in the inferior vena cava and was successfully retrieved (Fig. 1D; Movie 2).

Supplementary video related to this article can be found at

<sup>\*</sup> Corresponding author. Department of Cardiology, Kokura Memorial Hospital, 3-2-1 Asano, Kokurakita-ku, Kitakyushu 802-8555 Japan.

E-mail address: [mjunji1982@yahoo.co.jp](mailto:mjunji1982@yahoo.co.jp) (J. Morita).

Peer review under responsibility of Indian Heart Rhythm Society.



**Fig. 1.** TPS fluoroscopyDirection of the fluoroscopy in the figure is RAO view.

(A) First operation, (B–D) second operation. (a) old TPS, (b) new TPS.  
 (A) Postoperative fluoroscopy of the first operation showing the old TPS in the septa of the right ventricle.  
 (B) Retrieval of the old TPS obstructed by the chordae tendineae of the tricuspid valve and the pacemaker lead.  
 (C) Pushing the old TPS to the apex site.  
 (D) Catching the body of the old TPS.

<https://doi.org/10.1016/j.ipej.2018.05.001>.

### 3. Discussion

The visible dislodgement of a TPS is a rare complication [2]. In this case, the pacing threshold fluctuated during the pull test. It may mean that the fixation tines were nearly dislodged from myocardium. The TPS design incorporates a proximal retrieval feature to enable acute retrieval. But, the technique has not been established. Some studies have demonstrated the possibility of early retrieval by catching the proximal head [3,4]. We were unable to move the TPS after catching the TPS using a snare. We caught and pulled back the TPS but it didn't move. While the lead curve was changing little. Therefore, we thought the TPS was obstructed by the chordae tendineae of the tricuspid valve or the pacemaker lead, and we required the technique of pushing the TPS to the apex. In this case, we caught the proximal head, the tines and the body. The number of TPS dislodgement cases will increase as TPS implantation becomes widespread; hence, further experience is required in TPS retrieval.

### 4. Conclusion

This is the first case reporting TPS retrieval in a heart with a preexisting lead.

### Conflicts of interest

None.

### Acknowledgements

None.

### References

- [1] Reynolds D, Duray GZ, Omar R, Soejima K, Neuzil P, Zhang S, Narasimhan C, Steinwender C, Brugada J, Lloyd M, Roberts PR, Sagi V, Hummel J, Bongiorno MG, Knops RE, Ellis CR, Gornick CC, Bernabei MA, Laager V, Stromberg K, Williams ER, Hudnall JH, Ritter P. Micra transcatheter pacing study group. A leadless intracardiac transcatheter pacing system. *N. Engl. J Med* 2016;374: 533–41.
- [2] Roberts P, Clementy N, Al Samadi F, Garweg C, Martinez-Sande J, Iacopino S, Johansen JB, Vinolas Prat X, Kowal RC, Klug D, Mont L, Steffel J, Li S, Van Osch D, El-Chami MF. A leadless pacemaker in the real-world setting: the micra transcatheter pacing system post-approval registry. *Heart Rhythm* 2017;14: 1375–9.
- [3] Grubman E, Ritter P, Ellis CR, Giocondo M, Augostini R, Neuzil P, Ravindran B, Patel AM, Omdahl P, Pieper K, Stromberg K, Hudnall JH, Reynolds D. Micra transcatheter pacing study group. To retrieve, or not to retrieve: system revisions with the Micra transcatheter pacemaker. *Heart Rhythm* 2017;14: 1801–6.
- [4] Afzal M, Daoud E, Cunnane R, Mulpuru S, Koay A, Hussain A, Omar R, Wei KK, Amin A, Kidwell G, Patel N, Love C, Lloyd M, Sterliński M, Goldbarb S, Leal MA, Gabriels J, Patel A, Jadonath R, Grubman E, Crossley G, Pepper C, Lakkireddy D, Okabe T, Hummel JD, Augostini RS. Techniques for successful early retrieval of the micra transcatheter pacing system: a worldwide experience. *Heart Rhythm* 2018;30103–6. S1547-5271(18).