

Methylprednisolone and plasmapheresis are effective for life-threatening diffuse alveolar hemorrhage and gastrointestinal hemorrhage in granulomatosis with polyangiitis

A case report and literature review

Shen Ning, MD, Xinhua Zhang, MD, Cheng Xu, MD, Xin Dang, MD, Hao Cheng, PhD, Kejian Zhu, PhD, Yongmei Han, MD*

Abstract

Rationale: The treatment of granulomatosis with polyangiitis (GPA) with life-threatening complications, such as diffuse alveolar hemorrhage (DAH) and gastrointestinal hemorrhage (GIH), remains challenging.

Patient concerns: A 70-year-old female presented with a 6-month history of a productive cough and a 10-day history of arthralgia that progressed to respiratory failure and massive hematochezia.

Diagnoses: Chest high-resolution computed tomography (HRCT) revealed multiple nodules, masses, and cavities. Urinalysis indicated microscopic hematuria. Test of proteinase3-anti-neutrophil cytoplasmic autoantibody (PR3-ANCA) was positive.

Interventions: The patient was transferred to the intensive care unit (ICU) and successfully treated with glucocorticoid pulse therapy and plasmapheresis. We combined mycophenolate mofetil (MMF) with glucocorticoid for maintenance treatment.

Outcomes: The patient survived and is in a stable condition. We report this case that presented with a productive cough, followed by arthralgia, DAH, and GIH.

Lessons: Effective remission-induction therapy is a key to survival, while maintaining a balance between immunosuppression and avoiding infection is another challenge.

Abbreviations: ANCA = anti-neutrophil cytoplasmic autoantibody, DAH = diffuse alveolar hemorrhage, EGPA = eosinophilic granulomatosis with polyangiitis, GIH = gastrointestinal hemorrhage, GPA = granulomatosis with polyangiitis, HRCT = high-resolution computed tomography, ICU = intensive care unit, MMF = mycophenolate mofetil, MPA = microscopic polyangiitis, PR3 = proteinase3.

Keywords: diffuse alveolar hemorrhage, gastrointestinal hemorrhage, granulomatosis with polyangiitis, methylprednisolone, plasmapheresis therapy

Editor: N/A.

Funding/support: This work was supported by grants from the Educational Commission of Zhejiang Province (No. Y201534754).

Ethical approval is not necessary because this is a case report based on the clinical data during the patient's hospitalization other than a research or an experiment.

The patient has given her consent and authorized her clinical data in our report to be published in *Medicine*. She has signed the Patient Consent Form.

The authors declare no competing financial interests.

Sir Run Run Shaw Hospital, School of Medicine, Zhejiang University, Hangzhou, China.

* Correspondence: Yongmei Han, Sir Run Run Shaw Hospital, School of Medicine, Zhejiang University, 3 Qingchun East Road, Hangzhou 310020, China. (e-mail: 3408235@zju.edu.cn).

Copyright © 2018 the Author(s). Published by Wolters Kluwer Health, Inc. This is an open access article distributed under the terms of the Creative Commons Attribution-Non Commercial-No Derivatives License 4.0 (CCBY-NC-ND), where it is permissible to download and share the work provided it is properly cited. The work cannot be changed in any way or used commercially without permission from the journal.

Medicine (2018) 97:17(e0592)

Received: 23 March 2018 / Accepted: 6 April 2018

<http://dx.doi.org/10.1097/MD.00000000000010592>

1. Introduction

Anti-neutrophil cytoplasmic autoantibody (ANCA)-associated vasculitis (AAV) includes granulomatosis with polyangiitis (GPA), microscopic polyangiitis (MPA), and eosinophilic granulomatosis with polyangiitis (EGPA). Watts et al^[1] reported that the incidence of GPA was 10.6 per million in Norwich and 4.9 per million in Spain. GPA is a systemic necrotizing vasculitis involving small- and medium-sized blood vessels. It affects multiple systems, including the upper and/or lower respiratory tract, kidneys, skin, joints, gastrointestinal tract, and nervous system. As the respiratory system and kidneys are most commonly involved, patients often first present to respiratory or nephrology departments. We report a patient who presented with a productive cough as initial symptom, and subsequently developed arthralgia, diffuse alveolar hemorrhage (DAH), and gastrointestinal hemorrhage (GIH).

2. Case presentation

2.1. Case description

A 70-year-old female was initially admitted to the Department of Respiration with a 6-month history of a productive cough and

Table 1**Laboratory results at admission.**

Laboratory data	Results	Normal reference ranges
White blood cell count, 10 ⁹ /L	7.7	3.5–9.5
Neutrophils %	86.3	40.0–75.0
Hemoglobin, g/dl	10.9	11.5–15.0
Platelet count, 10 ⁹ /L	438	125–350
Urine erythrocyte, /HPF	100–200	0–3
Proteinuria, mg/24h	1052.7	0–150
Stool occult blood	Positive	Negative
Creatinine, μmol/L	80	41–81
Alanine transaminase, U/L	32	7–40
Aspartate transaminase, U/L	44	13–35
Prothrombin time, s	13.8	11.5–14.5
Partial thromboplastin time, s	39.2	29.2–41.2
Erythrocyte sedimentation rate, mm/h	91	0–20
High sensitivity C reactive protein, mg/dl	168.9	0.0–5.0
Creatine kinase, IU/L	933	40–200
Rheumatoid factor, IU/mL	254.8	0.0–40.0
Antinuclear antibodies	Negative	Negative
Cytoplasmic ANCA	Positive	Negative
Proteinase3 ANCA	Positive	Negative
Sputum culture	Negative	Negative

10⁹/L = billion per liter, g/dL = gram per deciliter, /HPF = per high power field, mg/24h = milligram per 24 hours, μmol/L = micromoles per liter, U/L = units per liter, mm/h = millimeter per hour, mg/dL = milligram per deciliter, IU/L = international units per liter, ANCA = anti-neutrophil cytoplasmic autoantibody.

fever, and a 10-day history of arthralgia and lower limbs edema with purpura. She denied hemoptysis or chest distress. Antibiotic therapy prescribed after the onset of her symptoms was ineffective. Her appetite and body weight were unchanged.

She had no comorbidities other than hypertension and her family history was unremarkable. She was a nondrinker and nonsmoker and worked as a homemaker.

2.2. Clinical findings and diagnosis

The thoracic physical examination was negative. The Numeric Rating Scale score was 2 for tenderness of her wrists, knees, and ankles bilaterally. There were no other positive findings on physical examination. The initial laboratory findings are summarized in Table 1. Multiple nodules, masses, and cavities were found on her chest high-resolution computed tomography (HRCT) (Fig. 1). Pathology of percutaneous lung puncture biopsy suggested chronic inflammation, fibroblast proliferation, and a histiocytic reaction. Doppler ultrasonography indicated deep vein thrombosis of the left leg. Consequently, she was clinically diagnosed with GPA. Paranasal sinus HRCT was negative. Electromyogram and nerve conduction velocity indicated multiple peripheral neuropathy of the limbs. A skin biopsy showed leukocytoclastic vasculitis.

2.3. Initial therapeutic intervention

Due to her positive stool occult blood, we recommended a gastroscopy and a colonoscopy, which were refused. She was started on methylprednisolone (80mg/day). The day after starting the methylprednisolone, the patient produced about 500 mL of bloody stool and developed dizziness and a cold sweat. Her blood pressure was 103/55 mm Hg and heart rate was 100 bpm. Abdominal examination and digital rectal examination were negative. A complete blood count showed a hemoglobin

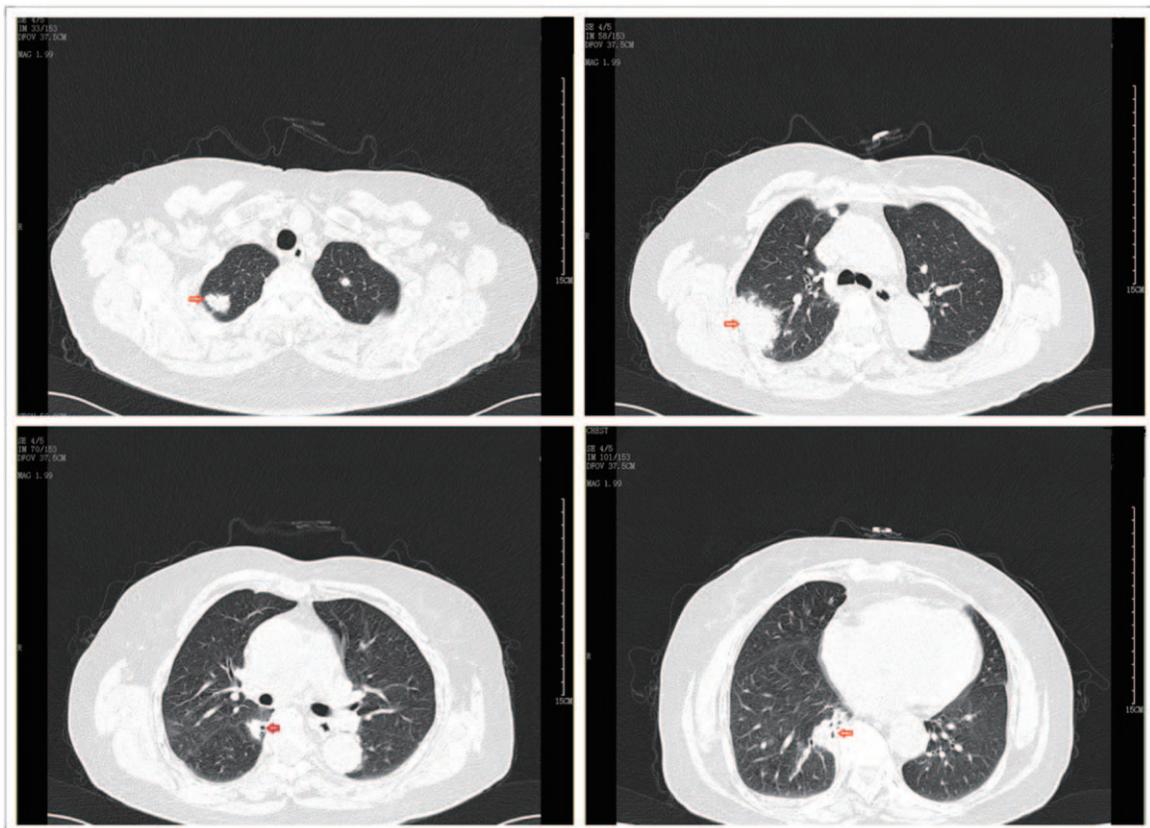


Figure 1. Multiple nodules, masses, and cavities (arrows) were found in chest HRCT scan at admission.

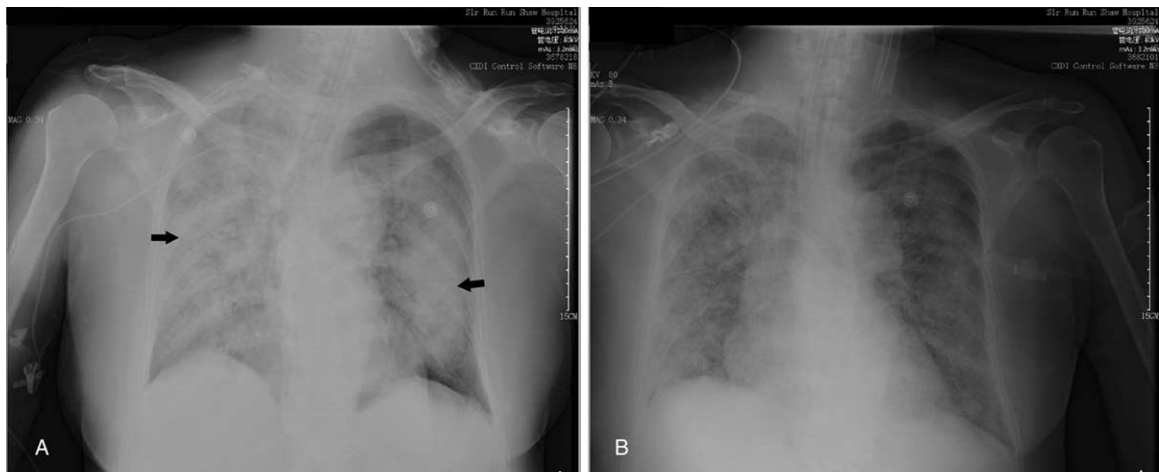


Figure 2. (A) The chest X-ray film showed multiple sheet cloudy, irregular, and massive occupation in both lung field (arrows). (B) The second chest radiography indicated significant improvement of previous cloudy and massive occupation 2 days after the first film.

level of 5.0g/dL. The methylprednisolone was stopped and she was treated with somatostatin, a stronger proton-pump inhibitor; oral intake was halted and a fluid infusion started. However, no active bleeding was seen on gastroscopy or colonoscopy. Gastroscopy showed chronic erosive gastritis and colonoscopy found a polyp of colon, which was thought too small to cause such massive GIH. We postulated that the GIH was related to GPA, rather than being an adverse effect of methylprednisolone.

2.4. Clinical events and progression

The night following the colonoscopy, before we restarted the methylprednisolone, the patient developed a severe nonproductive cough and distress, with no hemoptysis. Her respiratory rate was 30 breaths/min, the body temperature elevated to 38.6°C, and oxygen saturation was 90% on 5L/min oxygen. She was intubated and sent to the intensive care unit (ICU) due to her worsening respiratory failure. Her hemoglobin fell to 5.0g/dL and a transfusion was administered. A chest radiography revealed multiple patchy areas and massive consolidation in both lungs (Fig. 2A). The aspirated sputum was bloody. On bronchoscopy, there were bloody tracheal secretions bilaterally, severe congestion, and edema of the bronchial mucosa in both lower lobes and the

right middle lobe. Bronchoalveolar lavage indicated DAH. We started with methylprednisolone pulse therapy (500 mg daily for 5 days), combined with intravenous immunoglobulin (25 g daily for 5 days), and daily plasmapheresis. The high-sensitivity C-reactive protein (hs-CRP, 179.5 mg/L) and procalcitonin (PCT, 1.2 ng/mL) levels were elevated. Sputum cultures grew *Pseudomonas aeruginosa* and she was treated with antibiotics. Considering the positive sputum culture for *P. aeruginosa* and the increased risk of opportunistic infection after immunosuppression, we did not add cyclophosphamide or rituximab immediately.

Two days later, the patient’s general condition improved, her vital signs were stable, and her hemoglobin stabilized at above 9.0g/dL. A second chest radiography indicated an improvement of the previous cloudy and massive occupation (Fig. 2B). The methylprednisolone pulse therapy was conducted for 5 days, followed by intravenous methylprednisolone (160 mg daily). The daily plasmapheresis was continued. The next day, she again had bloody stools (about 700 mL) and her hemoglobin had dropped to 5.1g/dL. We continued the methylprednisolone therapy and plasmapheresis, and administered a transfusion and other supportive treatment. The hematochezia stopped 2 days later.

Repeat chest HRCT showed diffuse bilateral interstitial infiltration with moderate pleural effusions (Fig. 3). Two weeks

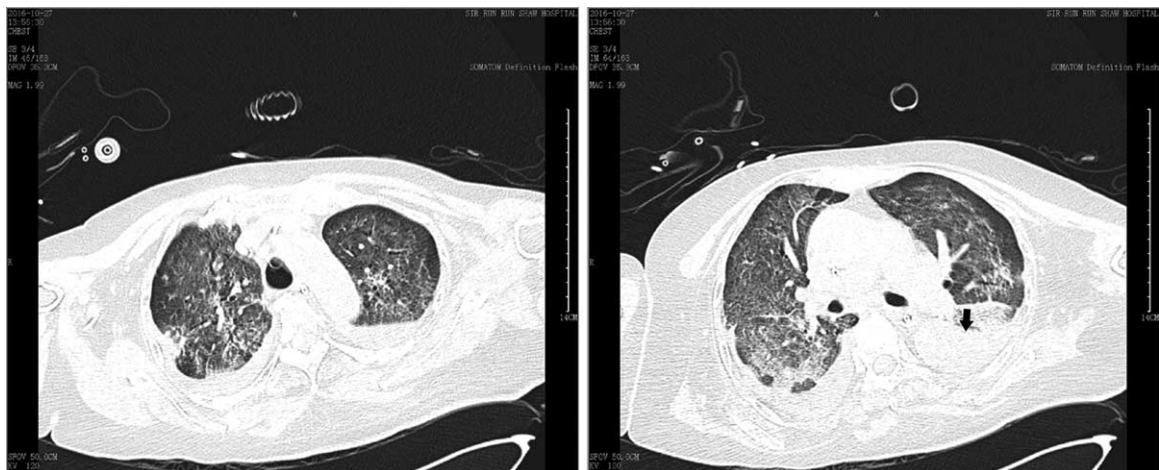


Figure 3. The reexamined chest HRCT revealed diffuse bilateral interstitial infiltration with moderate pleural effusion (arrow).

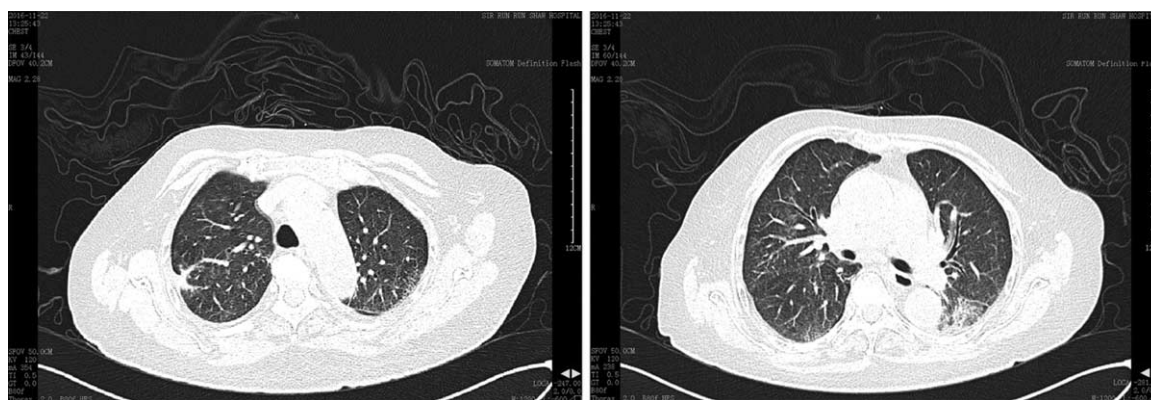


Figure 4. The chest HRCT after treatment showed that the previous diffuse bilateral interstitial infiltration recovered and the pleural effusion disappeared.

after starting of methylprednisolone pulse therapy, she had undergone plasmapheresis 10 times (daily for the initial 7 bouts and every other day for the remaining 3). The methylprednisolone dose was decreased to 80 mg daily. The patient's condition improved, although extubation remained difficult due to her respiratory failure. We performed a tracheotomy to help wean her from the respirator.

2.5. Outcome and follow-up

Two days after the tracheotomy, she was discharged from the ICU and admitted to the Rheumatology Department. We tapered and then withdrew the antibiotics. Mycophenolate mofetil (MMF; 750 mg twice a day) was added as the immunosuppressive therapy. We also added compound sulfamethoxazole to prevent pneumocystosis. A repeated chest HRCT revealed improvement in the diffuse bilateral interstitial infiltration and the pleural effusion had disappeared (Fig. 4). The hs-CRP decreased to 0.7 mg/L, the erythrocyte sedimentation rate was 19 mm/h, the hemoglobin recovered to 10 g/dL, the PCT was normal, the stool occult blood turned negative, and a sputum culture was negative. The patient was discharged and followed as an outpatient. At the 17-month follow-up, she was stable on low-dose oral methylprednisolone combined with MMF.

3. Literature review and discussions

GPA is a systemic disease characterized by necrotizing vasculitis that most commonly affects the upper and lower respiratory tract, kidneys, skins, and joints. Gastrointestinal involvement is much less frequent in patients with GPA. Our patient presented with a productive cough as the initial symptom, followed by polyarthralgia, myalgia, and purpura. Chest HRCT revealed nodules and cavitation. She was positive for PR3-ANCA and urinalysis showed hematuria. A skin biopsy revealed leukocytoclastic vasculitis. Although a biopsy of lung found nothing specific and the CT of the sinuses was negative, she was diagnosed with GPA on the basis of her clinical manifestations, radiographic and laboratory findings, and skin histology. She had deep vein thrombosis, which has been reported at a high incidence in GPA patients.^[2] While hospitalization, she developed life-threatening complications, including DAH and GIH.

DAH is a life-threatening syndrome that mainly manifests as dyspnea and hemoptysis. The incidence of DAH in AAV patients is 5% to 45% in GPA, 29% in MPA, and 3% in EGPA.^[3,4] In a

retrospective study of 131 patients with AAV in China, Lin et al^[5] found that 12 patients developed DAH; the incidence of DAH was 2.47%, 40.9%, and 3.59% in GPA, MPA, and EGPA, respectively. DAH may be the initial finding in GPA patients, or it may occur during the glucocorticoid and immunosuppressive therapy. As in our patient, about one-third of DAH patients do not develop hemoptysis, as the alveolar volume is sufficiently large to hold the blood and prevent it from diffusing into the bronchi.^[6] We considered that the drop of hemoglobin seen in our patient resulted from gastrointestinal bleeding, based on the persistent positive test of stool occult blood. The initial minimal respiratory symptoms and previous massive GIH in our patient confused us and made the diagnosis of DAH difficult. When she developed dyspnea and her oxygen saturation dropped, we were alert to the alveolar hemorrhage, which was confirmed by the following chest radiography and bronchoscopy. Clinicians should always be wary when a patient has no hemoptysis, but the hemoglobin gradually declines and the oxygen saturation get progressively worse for unknown reasons. Chest radiography and bronchoscopy are of great value in the early diagnosis of DAH.

One limitation in the management of our case was that we did not obtain specimens of gastrointestinal mucosa at endoscopy; furthermore, capsule endoscopy was not performed because of the patient's reluctance. There are few reports on AAV complicated by GIH. It may occur at the same time as upper and lower respiratory symptoms or renal insufficiency. In rare cases, GIH is the only manifestation. GIH can occur either before or after the start of glucocorticoid therapy and there are usually no specific findings at endoscopy.^[7] The presence of GIH may limit the use of pulse methylprednisolone therapy and requires more intensive monitoring. Our patient developed massive GIH twice, both times after starting of methylprednisolone, while there was no evidence of bleeding at gastroscopy or colonoscopy. It was not clear whether her GIH was due to her primary disease or the high-dose methylprednisolone therapy. We believe that her GIH was a complication of GPA based on the following evidence. First, she had persistent positive stool occult blood test before the methylprednisolone therapy. Second, her GIH recovered gradually and the stool occult blood test turned negative after the treatment with high-dose methylprednisolone.

In 1996, Kishimoto and Nieuwoya^[8] reported a patient with both alveolar hemorrhage and GIH with positive cytoplasmic ANCA. We present our case to share our experience of choosing effective therapeutic intervention according to the patient's condition. Glucocorticoids combined with either cyclophosphamide or

rituximab are highly recommended for remission-induction in life-threatening AAV.^[9] We searched PubMed and found 13 cases in 11 case reports of adult GPA with DAH.^[10–20] Of the 13 cases, 11 received glucocorticoids and cyclophosphamide, and 1 used the combination of glucocorticoids, cyclophosphamide, and rituximab, the remaining patient died before any treatment. Only 2 of the 12 treated patients died because of the rapidly aggressive disease. However, the infection risk is much higher in patients treated with immunosuppressive therapy. The reported first-year incidence of infection is about 51%.^[21] It is challenging to maintain a balanced between immunosuppression and infection prevention. Plasmapheresis is also recommended for organ-threatening and life-threatening AAV.^[9] A retrospective review of 20 patients with DAH and AAV confirmed the benefits of plasmapheresis.^[22] In our case, we immediately started with intravenous pulse methylprednisolone and daily plasmapheresis after she was intubated and admitted to the ICU. Because she already had a *P. aeruginosa* infection based on positive sputum cultures and her infection risk was much higher, we delayed the immunosuppressive therapy. We also used intravenous immune globulin to replenish her antibody levels. After DAH entered remission and we controlled the infection, she was treated with oral glucocorticoids and MMF as remission-maintenance therapy. At the 17-month follow-up, our patient has not relapsed.

4. Conclusion

Both DAH and GIH are life-threatening complications of GPA. Although methylprednisolone therapy combined with either cyclophosphamide or rituximab is recommended for remission-induction, individualized treatment according to each patient's clinical condition is more effective. We present this case to provide our experience of methylprednisolone and plasmapheresis therapy for DAH and GIH in GPA.

Author contributions

Data curation: Cheng Xu.

Funding acquisition: Yongmei Han.

Investigation: Ning Shen, Xin Dang.

Software: Xinhua Zhang.

Supervision: Kejian Zhu.

Validation: Kejian Zhu, Hao Cheng.

Writing – original draft: Ning Shen.

Writing – review & editing: Yongmei Han.

References

- [1] Watts RA, Gonzalez-Gay MA, Lane SE, et al. Geoepidemiology of systemic vasculitis: comparison of the incidence in two regions of Europe. *Ann Rheum Dis* 2001;60:170–2.
- [2] Merkel PA, Lo GH, Holbrook JT, et al. Brief communication: high incidence of venous thrombotic events among patients with Wegener granulomatosis: the Wegener's Clinical Occurrence of Thrombosis (WeCLOT) Study. *Ann Intern Med* 2005;142:620–6.
- [3] Manganelli P, Fietta P, Carotti M, et al. Respiratory system involvement in systemic vasculitides. *Clin Exp Rheumatol* 2006;24(2 Suppl 41): S48–59.
- [4] Guillevin L, Cohen P, Gayraud M, et al. Churg-Strauss syndrome. Clinical study and long-term follow-up of 96 patients. *Medicine (Baltimore)* 1999;78:26–37.
- [5] Lin Y, Zheng W, Tian X, et al. Antineutrophil cytoplasmic antibody-associated vasculitis complicated with diffuse alveolar hemorrhage: a study of 12 cases. *J Clin Rheumatol* 2009;15:341–4.
- [6] Ioachimescu OC, Stoller JK. Diffuse alveolar hemorrhage: diagnosing it and finding the cause. *Cleve Clin J Med* 2008;75: 258, 260, 264–265 passim.
- [7] Harper L, Morgan MD, Walsh M, et al. Pulse versus daily oral cyclophosphamide for induction of remission in ANCA-associated vasculitis: long-term follow-up. *Ann Rheum Dis* 2012;71:955–60.
- [8] Kishimoto N, Nieuvoysa T. Alveolar hemorrhage, skin eruption, and gastrointestinal bleeding accompanied by crescentic glomerulonephritis in a patient with cytoplasmic anti-neutrophil cytoplasmic antibody. *Nihon Kyobu Shikkan Gakkai Zasshi* 1996;34:790–5.
- [9] Yates M, Watts RA, Bajema IM, et al. EULAR/ERA-EDTA recommendations for the management of ANCA-associated vasculitis. *Ann Rheum Dis* 2016;75:1583–94.
- [10] Vanoli J, Riva M, Vergnano B, et al. Granulomatosis with polyangiitis presenting with diffuse alveolar hemorrhage requiring extracorporeal membrane oxygenation with rapid multiorgan relapse: a case report. *Medicine (Baltimore)* 2017;96:e6024.
- [11] Kaya H, Yilmaz S, Sezgi C, et al. Two cases of extrapulmonary onset granulomatosis with polyangiitis which caused diffuse alveolar haemorrhage. *Respir Med Case Rep* 2014;13:32–6.
- [12] Moreno-Gonzalez G, Corral-Ansa L, Sabater-Riera J, et al. Pulmonary thromboembolism and diffuse alveolar hemorrhage in granulomatosis with polyangiitis vasculitis. *Respir Care* 2014;59:e206–9.
- [13] Vaishnav KU, Bhatt C, Desai A. Diffuse alveolar haemorrhage in granulomatosis with polyangiitis (Wegener's) with coexistent rheumatoid arthritis. *BMJ Case Rep* 2012;2012: pii: bcr2012006184.
- [14] Nguyen T, Martin MK, Indrikovs AJ. Plasmapheresis for diffuse alveolar hemorrhage in a patient with Wegener's granulomatosis: case report and review of the literature. *J Clin Apher* 2005;20:230–4.
- [15] Travis WD, Carpenter HA, Lie JT. Diffuse pulmonary hemorrhage. An uncommon manifestation of Wegener's granulomatosis. *Am J Surg Pathol* 1987;11:702–8.
- [16] Arulkumaran N, Suleman R, Cecconi M, et al. Rituximab associated pneumonitis in antineutrophil cytoplasmic antibody-associated vasculitis. *J Clin Rheumatol* 2012;18:39–41.
- [17] Lau RA, Bains R, Suraweera D, et al. A rare case of digital ischemia and gangrene in ANCA-associated vasculitis with review of the literature. *Case Rep Rheumatol* 2017;2017:2421760.
- [18] Mahajan V, Whig J, Kashyap A, et al. Diffuse alveolar hemorrhage in Wegener's granulomatosis. *Lung India* 2011;28:52–5.
- [19] Cardenas-Garcia J, Farmakiotis D, Baldovino BP, et al. Wegener's granulomatosis in a middle-aged woman presenting with dyspnea, rash, hemoptysis and recurrent eye complaints: a case report. *J Med Case Rep* 2012;6:335.
- [20] Arora R. Massive alveolar haemorrhage: a rare life threatening complication of Wegener's granulomatosis-report of a rare case. *Quant Imaging Med Surg* 2014;4:509–11.
- [21] McGregor JG, Negrete-Lopez R, Poulton CJ, et al. Adverse events and infectious burden, microbes and temporal outline from immunosuppressive therapy in antineutrophil cytoplasmic antibody-associated vasculitis with native renal function. *Nephrol Dial Transplant* 2015;30(Suppl 1): i171–81.
- [22] Klemmer PJ, Chalermkulrat W, Reif MS, et al. Plasmapheresis therapy for diffuse alveolar hemorrhage in patients with small-vessel vasculitis. *Am J Kidney Dis* 2003;42:1149–53.