

Bilateral superiorly based malar transposition flaps for nasal tip reconstruction: A case report

SAGE Open Medical Case Reports
JCMS Case Reports
Volume 9: 1–3
© The Author(s) 2021
Article reuse guidelines:
sagepub.com/journals-permissions
DOI: 10.1177/2050313X21993280
journals.sagepub.com/home/sco



David B Roy¹, Paarth Dodia² and Michael Roberts³

Abstract

The Peng flap was originally described in 1987 as a viable option for re-creation of the convexity of the dorsum and nasal tip in a one step. Defects extending into the sidewall can result in multi-stage procedures. Beustes-Stefanelli in 2015 published a midline-based nasolabial transposition flap utilizing a single-stage repair for large defects of the nasal tip. There is minimal literature on large nasal tip defects repaired in a single stage and few modifications to the Peng flap. In this case, the sidewall involvement on top of the extent of nasal tissue removed limits the various different methods.

Keywords

Surgery, wound, dermatology, cancer

Introduction

Burget and Menick's 1985 nasal subunit principle provides a framework from which to design a flap that respects the three-dimensional contours of the surface anatomy for post-surgical nasal reconstruction.¹ The Peng flap was originally described in 1987 as a viable option for re-creation of the convexity of the dorsum and nasal tip in a one-step fashion using the excellent tissue match of the nasal sidewall.² Defects extending into the sidewall, however, often involve multi-stage morbid procedures.

The flap of Beustes-Stefanelli et al. utilizes a midline-based nasolabial transposition (MNT) flap in a single-stage repair for large defects of the nasal tip, and potentially those extending into the lower dorsum and the columella.³ This flap has the advantage of avoiding the two stages usually required in forehead and nasolabial flaps. Avoidance of the forehead option spares forehead tissue and subsequent scarring. Avoidance of nasolabial flaps allows for a single-stage procedure for large defects and the subsequent lack of a pedicle, which some patients may not tolerate.

We present a single-stage repair of a nasal defect extending from the nasal tip, dorsum, and portions of the bilateral nasal sidewalls, based on the principle of the flaps described by Peng and Beustes-Stefanelli. However, due to the nasal sidewall involvement, malar tissue was instead harvested and designed appropriately. The resultant flaps were advanced across the lateral malar tissue and into the lateral sidewall, re-creating the convexity along the midline at the nasal tip and avoiding any distortion of the medial canthi. Ultimately,

the malar tissue provides an excellent match for the lateral nasal sidewalls, dorsum, and nasal tip (Figures 1–4).

Discussion

Local cutaneous flaps are chosen based upon location along the nasal curvature, as well as the color and texture of the adjacent tissue, to produce a healthy flap with minimal tension and scarring, along with minimization of tension to discourage secondary distortion. Given the lack of freely mobile peripheral tissue and the tri-dimensional shape, reconstruction of large defects involving the nasal tip can be a challenging task. There are a number of different methods from which to choose from, depending upon the size and anatomical location of the surgical defect.^{4–6}

In this case, the sidewall involvement on top of the extent of nasal tissue removed limits the various different methods. The choice for this patient was a novel approach, a bilateral superiorly based malar transposition (BSMT) flap. This flap is an expansion of the MNT flap described by Beustes-Stefanelli et al combined with aspects of the aforementioned Peng flap.³

¹Pine Belt Dermatology and Skin Cancer Center, Petal, MS, USA

²School of Medicine, William Carey University, Biloxi, MS, USA

³Goodman Dermatology P.C., Roswell, GA, USA

Corresponding Author:

Michael Roberts, Goodman Dermatology P.C., 2500 Hospital Blvd #280, Roswell, GA 30076, USA.

Email: Medroberts.823@gmail.com



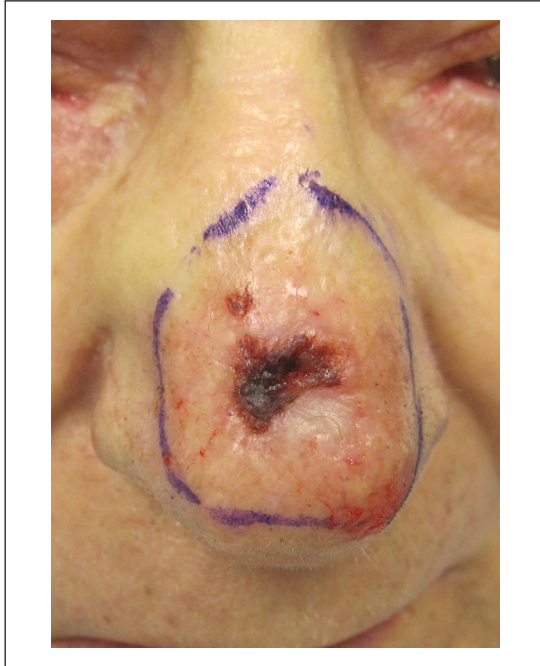

Figure 1. Pre-operative view of the patient's nose, displaying the biopsy-confirmed basal cell carcinoma (BCC) with pink, distorted skin adjacent to the lesional area.

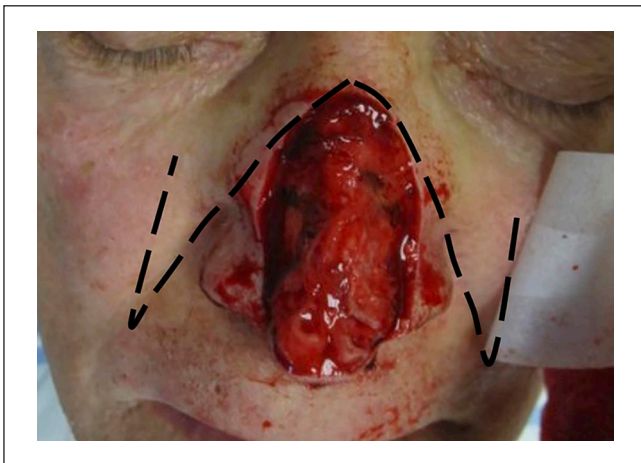


Figure 2. Post-surgical defect following Mohs surgery, illustrating the extent of the tumor and vast majority of nasal structures involved prior to histological clearance.

The Peng flap was reported as a “pinch” modification of Rintala’s glabellar linear advancement flap for repair of large defects extending into the dorsum and nasal tip.⁷ It is an advancement rotation flap that recruits skin from the bilateral nasal sidewalls to re-create the convexity of the nasal tip in a single step. Due to the origin of the skin involved and the course of flap advancement, skin color and texture are preserved alongside nasal architecture. This repair could not be executed for the patient as the defect was too large and involved too much of the upper dorsum. Furthermore, it

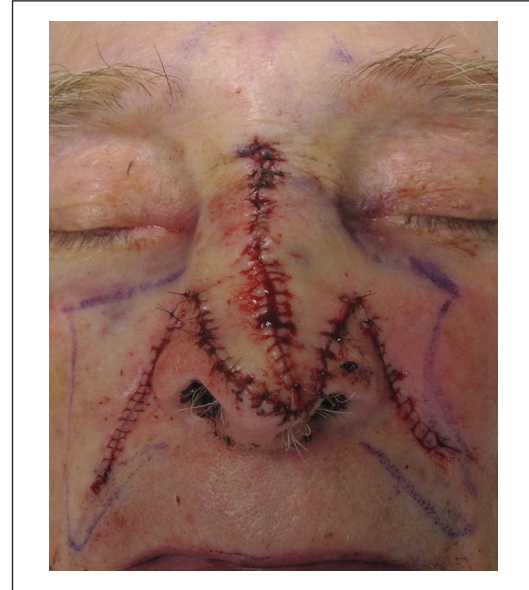

Figure 3. Post-nasal reconstruction, displaying the bilateral malar transposition flaps adjoining along the midline of the nose, extending from the bridge to the tip, with minimal tension on the surrounding critical structures.

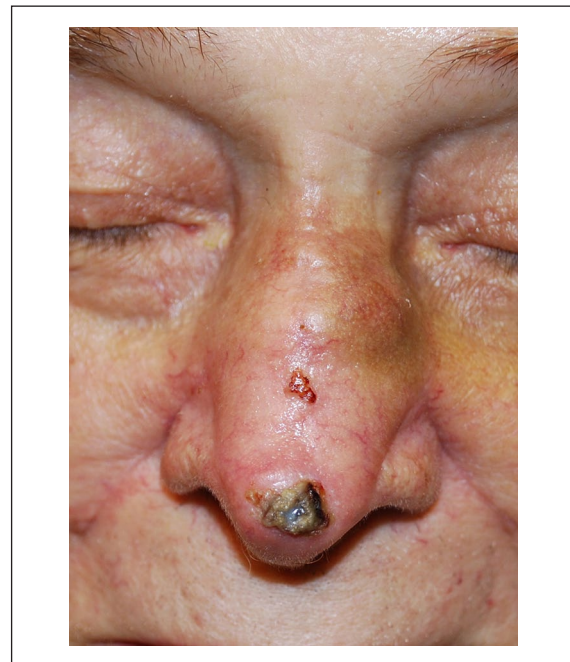


Figure 4. Two weeks following Mohs surgery, whereby minimal scarring and an excellent color match can be appreciated. Of note, at the tip, a small site of resolving tissue necrosis secondary to expulsion of an absorbable suture can be seen. Resolving bruising is also appreciated.

avoids the need for a skin graft or two-step interpolation flap while providing an excellent tissue match.¹ Despite the apparent underutilization of the flap, there have been few reports of modifications to the original Peng flap.^{4,8,9}

In the MNT flap, skin is recruited from the nasolabial groove and transposed to the midline to execute a single-step repair of large defects greater than 3 cm involving the nasal tip. One of the benefits of this technique is that any potential scarring can be hidden in the nasolabial groove and between the dorsum and ipsilateral sidewall. In addition, with this technique, the extent of dorsal involvement from the primary defect becomes a non-issue. However, by design, the MNT flap cannot be utilized in situations where a defect extends into the upper part of the ipsilateral sidewall.⁷

To decrease the movement of the advancement flap, Rowe et al. suggested creating incisions at the most distal portion of the defect for the two rotating arms.⁸ On the other hand, Rowe et al. proposed incisions more laterally along the alar grooves to create a larger pedicle base that results in greater flap survival.⁹ Cesar et al. reported their success with Rowe's modification, attributing the functional outcomes to the symmetry of the flap design. In addition, they suggested that the excellent cosmetic results are achieved by placing the incisions at the junction of aesthetic subunits, thus preventing distortion of the ala.⁴

Declaration of conflicting interests

The author(s) declared no potential conflicts of interest with respect to the research, authorship, and/or publication of this article.

Funding

The author(s) received no financial support for the research, authorship, and/or publication of this article.

Informed consent

Informed consent was received by the patient involved and is on file with the principal author.

References

1. Burget GC and Menick FJ. The subunit principle in nasal reconstruction. *Plast Reconstr Surg* 1985; 76(2): 239–247.
2. Peng VT, Sturm RL and Marsh TW. Pinch modification of the linear advancement flap. *J Dermatol Surg Oncol* 1987; 13(3): 251–253.
3. Beustes-Stefanelli M, O'Toole G and Schertenleib P. The midline-based nasolabial transposition (MNT) flap. *Ann Plast Surg* 2015; 74(4): 426–431.
4. Cesar A, Barros A, Santos P, et al. Surgical pearl on reconstructing surgical defects of the nasal tip. *Dermatol Report* 2016; 8(1): 6828.
5. Frodel J and Haugen T. Reconstruction of complex nasal dorsal and sidewall defects. *Arch Facial Plast Surg* 2011; 13(5): 343–346.
6. Austin G and Shockley W. Reconstruction of nasal defects: contemporary approaches. *Curr Opin Otolaryngol Head Neck Surg* 2016; 24(5): 453–460.
7. Rintala AE and Asko-Seljavaara S. Reconstruction of midline skin defects of the nose. *Scand J Plast Reconstr Surg* 1969; 3(2): 105–108.
8. Rowe D, Warshawski L and Carruthers A. The Peng flap: the flap of choice for the complex curve of the central nasal tip. *Dermatol Surg* 1995; 21: 149–152.
9. Ahern RW and Lawrence N. The Peng flap: reviewed and refined. *Dermatol Surg* 2008; 34(2): 232–237.