

Received: 2021.07.27

Accepted: 2021.10.04

Available online: 2021.10.25

Published: 2021.11.29

# A Reason to Rethink Fasting Guidelines? Marijuana-Induced Gastroparesis and the Implications for Aspiration Risk in the Nil Per Os (NPO) Patient: A Case Report

## Authors' Contribution:

Study Design A  
Data Collection B  
Statistical Analysis C  
Data Interpretation D  
Manuscript Preparation E  
Literature Search F  
Funds Collection G

E **Caitlin A. Cammarano**  
E **Joseph Evan Villaluz**

Department of Anesthesia, Kaweah Health Medical Center, Visalia, CA, USA

**Corresponding Author:** Caitlin Cammarano, e-mail: [caitcam26@gmail.com](mailto:caitcam26@gmail.com)  
**Financial support:** None declared  
**Conflict of interest:** None declared

**Patient:** **Male, 24-year-old**  
**Final Diagnosis:** **Gastroparesis • tetrahydrocannabinol**  
**Symptoms:** **Vomiting**  
**Medication:** —  
**Clinical Procedure:** —  
**Specialty:** **Anesthesiology**

**Objective:** **Unusual clinical course**

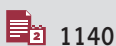
**Background:** Tetrahydrocannabinol has been implicated in gastroparesis development, a disorder characterized by delayed gastric emptying in the absence of mechanical obstruction. While most patients with gastroparesis present with upper gastrointestinal symptoms, patients with significantly delayed emptying can be asymptomatic, creating a dangerous aspiration risk.

**Case Report:** A 24-year-old man with a body mass index of 22 presented for right lower extremity open reduction and internal fixation. He endorsed daily marijuana use. His last meal was at 10 PM the prior night. After induction of general anesthesia and laryngeal mask airway (LMA) placement, 150 cc of gastric contents filled the LMA. The LMA was immediately removed and 25 to 50 cc of gastric contents was suctioned from the oropharynx. The airway was immediately secured with an endotracheal tube, after which 500 cc of clear gastric contents was suctioned from the stomach. Bronchoscopy revealed no obvious gastric contents in the tracheobronchial tree. The patient maintained adequate ventilation and oxygenation. He was safely extubated and brought to the post-anesthesia care unit, where recovery was uneventful.

**Conclusions:** Our case raises important questions and considerations for management of THC- dependent patients with potential for impacting NPO guidelines. It is unclear whether the quantity and chronicity of THC use effects gastroparesis development. The patient endorsed no signs of hyperemesis syndrome or gastric fullness; therefore, we cannot reliably deem patients risk-free based on their lack of symptomology alone. Until the true incidence of THC-induced gastroparesis is elicited in further studies, it is prudent to take aspiration precautions in all patients who endorse THC use.

**Keywords:** **Anesthesia, General • Cannabis • Gastroparesis**

Full-text PDF: <https://www.amjcaserep.com/abstract/index/idArt/934187>




1140



—



—



12



## Background

Gastroparesis is a disorder characterized by the delayed gastric emptying of food in the absence of mechanical obstruction. It generally manifests as symptoms of early satiety, postprandial fullness, or nausea and vomiting. Gastric emptying scintigraphy is considered the criterion standard test for diagnosing gastroparesis. Most frequently, it is associated with diabetes mellitus or is secondary to viral or idiopathic etiology [1]. A lesser known cause of gastroparesis is delta-9-tetrahydrocannabinol (THC) use, an association that has been identified but rarely reported [2,3]. With a paucity of THC-associated gastroparesis cases in the literature, we cannot conclude if patients endorsing THC use will present with the symptoms described above or if the anti-emetic and analgesic effects of THC could blunt the abdominal pain associated with delayed gastric emptying. The incidence of aspiration for general anesthesia in adults ranges between 1 and 5 per 10 000 patients, depending on risk factors [4]. Although cannabinoids decrease gastric motility and colonic propulsion, how much this impacts aspiration risk in the perioperative period and the incidence of aspiration among marijuana users have yet to be studied [5].

While most patients with gastroparesis present with upper gastrointestinal symptoms, the relationship between symptoms and the rate of gastric emptying is limited, and up to 40% of patients with gastroparesis can be asymptomatic [6]. This creates a dangerous aspiration risk for the unsuspecting anesthesiologist, particularly in patients who endorse no other risk factors for aspiration. This risk cannot be underestimated with the ever-increasing prevalence of THC use.

## Case Report

We present the case of a 24-year-old man scheduled for an elective open reduction and internal fixation of a right fibula fracture. The patient endorsed daily marijuana use of 2 g/day for 6 years. He denied use of opioids or other medications that affect gastric emptying. His body mass index was 22 and he denied any history that would present an aspiration risk. His last full meal was reported to be at 10 PM the prior night, which met standard nil per os (NPO) guidelines. Use of a laryngeal mask airway (LMA) therefore seemed appropriate. The patient was then brought to the operating room; all standard American Society of Anesthesiologists-recommended monitors were used, and general anesthesia was induced with standard induction medications with the patient in the supine position. An LMA was placed, and the patient was kept spontaneously breathing. Shortly after placement, 150 cc of gastric contents was noticed to be filling the LMA. The LMA was immediately removed and 25 to 50 cc of gastric contents was suctioned from the oropharynx. Rapid sequence induction was

then performed and the airway was secured with an endotracheal tube, followed by placement of an orogastric tube, with 500 cc of clear gastric contents suctioned from the stomach. Bronchoscopy revealed no obvious gastric contents in the tracheobronchial tree. The patient maintained adequate oxygen saturation and ventilation throughout the procedure. At the conclusion of the procedure, the patient was safely extubated and was brought to the post-anesthesia care unit, where his recovery was uneventful.

## Discussion

The legalization of marijuana and subsequent normalization of its everyday use has brought about unique considerations for the anesthesia provider. In a 2018 survey of 9000 adults in a nationally representative sample, 14% of respondents endorsed marijuana use [7]. The financial motivators are even more robust; by 2025, legal cannabis sales are projected to generate \$23 billion in the United States [8]. Several systemic effects of THC, the active ingredient in marijuana, have been described, including that of its ability to greatly slow gastric emptying from an average of 30 min to 120 min [9]. The mechanism behind this has been attributed to THC's inhibition of gastrointestinal smooth muscle and anticholinergic effects [10]. Hyperemesis has also been reported in chronic cannabis smokers [11], an association that is paradoxical considering its anti-emetic qualities. While the anesthetic implications of THC use have been identified in regards to the respiratory and cardiac systems, there are no case reports of THC-induced gastroparesis as a cause of near-aspiration and the implications for anesthetic management. There is 1 case report describing cannabinoid-induced gastroparesis confirmed by a gastric emptying study in a patient presenting to the Emergency Department with severe nausea and vomiting. This patient was otherwise healthy and had no other risk factors for gastroparesis, like our patient. Recognizing this risk has important value in aspiration prevention in the chronic THC user presenting for elective surgery.

Our case raises important considerations for management of THC-dependent patients. There are a few limitations associated with our case report, which represent opportunities for further discussion and research. The first question is whether cannabidiol (CBD)-containing products, devoid of THC, also confer gastroparesis risk. One study found that implementing dronabinol (synthetic marijuana) and marijuana in patients with preexisting gastroparesis decreased abdominal pain [12]. However, the study did not investigate marijuana's impact on reduction of the gastroparesis, but rather its effect on a correlated symptom; therefore, the role of CBD on aspiration risk is unclear. Further studies comparing THC vs CBD alone can help determine whether a difference exists and if

similar precautions should be taken in those patients using CBD-containing products.

Another question is whether quantity and chronicity of THC use impacts the development of gastroparesis. A dose of 10 mg/m<sup>2</sup> per body surface area has been found to significantly inhibit gastric emptying, but plasma THC levels did not correlate with the degree of gastric emptying inhibition [9], suggesting difficulty in predicting how long the effects on gastric emptying last. Our patient endorsed 2 g/day for 6 years, but, since he denied ever having associated symptoms, we cannot conclude when delayed gastric emptying began to determine if the gastroparesis was dose- or time-dependent of THC use.

## Conclusions

While the connection between THC use and delayed gastric emptying is clear, the impact of THC on aspiration risk has yet to be defined and leaves unanswered questions for the

anesthesiologist. Should the American Society of Anesthesia Fasting Guidelines be modified with respect to the THC user? Would it be reasonable to cancel a case if the anesthesiologist believes the risk of aspiration in a patient who endorses THC use is too great to proceed and therefore requires further preoperative workup? Our case report puts forth the idea that cannabinoid use should be deemed an important risk factor for pulmonary aspiration until further studies can define its impact and incidence on aspiration in patients undergoing general anesthesia.

Another pertinent takeaway from the perspective of patient safety is that the patient endorsed no signs of hyperemesis syndrome or gastric fullness. We therefore cannot reliably risk-stratify based on the patient's lack of symptomology alone, much like how we assess aspiration risk in patients with gastroesophageal reflux disease. Until the true incidence of THC-induced gastroparesis can be elicited in further studies, it is prudent to take aspiration precautions in all patients who endorse THC use.

## References:

1. Camilleri M, Chedid V, Ford A, et al. Gastroparesis. *Nat Rev Dis Primers*. 2018;4(1):41
2. Shinha T, Agarwal R, Lazarides A, Levey R. Cannabinoid-induced gastroparesis. *Am J Gastroenterol*. 2011;106(S1):189-90
3. Aviello G, Romano B, Izzo A. Cannabinoids and gastrointestinal motility: Animal and human studies. *Eur Rev Med Pharmacol Sci*. 2008;12(5):81-93
4. Benington S, Severn A. Preventing aspiration and regurgitation. *Anaesth Intensive Care Med*. 2007;8(9):368-72
5. Ladha K, Manoo V, Virji A. The impact of perioperative cannabis use: A narrative scoping review. *Cannabis Cannabinoid Res*. 2019;4(4):219-30
6. Bharucha A. Epidemiology and natural history of gastroparesis. *Gastroenterol Clin North Am*. 2015;44(1):9-19
7. Steigerwald S, Wong P, Cohen B, et al. Smoking, vaping, and use of edibles and other forms of marijuana among U.S. adults. *Ann Intern Med*. 2018;169(12):890-92
8. Page, R Allen L Kloner R, et al. Medical marijuana, recreational cannabis, and cardiovascular health: A scientific statement from the American Heart Association. *Circulation*. 2020;142(10):131-52
9. McCallum R, Soykan K, Sridhar R, et al. Delta-9-tetrahydrocannabinol delays the gastric emptying of solid food in humans: A double-blind, randomized study. *Aliment Pharmacol Ther*. 1999;13(1):77-80
10. Camilleri, M. Cannabinoids and gastrointestinal motility: Pharmacology, clinical effects, and potential therapeutics in humans. *Neurogastroenterol Motil*. 2018;30(9):13370
11. Allen, J, de Moore G, Heddle R, Twartz J. Cannabinoid hyperemesis: Cyclical hyperemesis in association with chronic cannabis abuse. *Gut*. 2004;53(11):1566-70
12. Barbash B, Mehta D, Siddiqui MT, et al. Impact of cannabinoids on symptoms of refractory gastroparesis: A single-center experience. *Cureus*. 2019;11(12):6430