

# Endoscopically Assisted Reconstruction of Posterior Tibial Tendon for Stage 2 Posterior Tibial Tendon Dysfunction



Zhuohao Chow Liang, B.B.C., and  
Tun Hing Lui, M.B.B.S. (H.K.), F.R.C.S. (Edin.), F.H.K.A.M., F.H.K.C.O.S.

**Abstract:** The posterior tibial tendon functions as a primary stabilizer of the medial longitudinal arch of the foot. Posterior tibial tendon dysfunction accounts for 80% of cases of adult-acquired flatfoot deformity. It is classified into 4 stages based on the function of the tibialis posterior tendon, the reducibility of the deformity, and the condition of the ankle joint. The purpose of this Technical Note is to describe the technical details of endoscopically assisted reconstruction of the posterior tibial tendon for stage 2 posterior tibial tendon dysfunction. It consists of using the medial half of the anterior tibialis tendon as a primary transfer and augmentation by the flexor digitorum longus. This construct is then protected with a subtalar arthroereisis.

The posterior tibial tendon (PTT) functions as a primary stabilizer of the medial longitudinal arch of the foot. It inverts the subtalar joint and locks the transverse tarsal joints, preventing collapse of the medial arch. PTT dysfunction (PTTD) accounts for 80% of cases of adult-acquired flatfoot deformity.<sup>1,2</sup> It is classified into 4 stages based on the function of the tibialis posterior tendon, the reducibility of the deformity, and the condition of the ankle joint.<sup>3-5</sup> Stage 1 PTTD consists of PTT tenosynovitis without evidence of arch collapse. The PTT has failed in stage 2 PTTD; a flexible flatfoot deformity develops, and the patient is unable to accomplish a single leg heel rise. This stage has been subdivided into 3 types. The stage

is IIA1 if valgus heel predominates with flexible forefoot; IIA2 if valgus heel predominates with fixed forefoot supination; IIB if abduction of the foot predominates; and IIC if there is a valgus hindfoot associated with medial column instability.<sup>5</sup> In stage III, the patient has a fixed deformity with uncorrectable hindfoot valgus and forefoot abduction. In stage IV, the patient has ankle deformity with evidence of lateral talar tilt caused by attenuation of the deltoid ligament. Conservative treatment includes orthotics and eccentric muscle training.<sup>1,6</sup> If the patient is well compensated, the pain goes away with the use of orthotics alone, and the deformity does not worsen, there is no need for any surgical procedure. Only in those cases in which conservative treatment fails is surgery indicated at least 6 months after initiation of treatment.<sup>6</sup> Functional surgery is indicated for treatment in the early stages. If patient has a fixed deformity, corrective and stabilizing surgery is performed.<sup>2</sup> Stage 2 disease, by definition, should not have any associated arthropathy; soft tissue reconstructive procedures are preferred over bone and joint reconstruction techniques.<sup>1,7</sup> A tendon transfer with flexor hallucis longus or flexor digitorum longus (FDL) is often the procedure of choice.<sup>2,7,8</sup> Regardless of the method of reconstruction, a protective mechanism is required to prevent premature re-elongation or rerupture of the reconstructed PTT. The most commonly used protection is some form of calcaneal osteotomy; this corrects calcaneal valgus and shifts the line of pull of the

From the Department of Orthopaedics and Traumatology (Z.C.L.), Tuen Mun Hospital; and Department of Orthopaedics and Traumatology (T.H.L.), North District Hospital, Hong Kong, China.

The authors report no conflicts of interest in the authorship and publication of this article. Full ICMJE author disclosure forms are available for this article online, as [supplementary material](#).

Received October 5, 2018; accepted October 25, 2018.

Address correspondence to Tun Hing Lui, M.B.B.S. (H.K.), F.R.C.S. (Edin.), F.H.K.A.M., F.H.K.C.O.S., Department of Orthopaedics and Traumatology, North District Hospital, 9 Po Kin Rd, Sheung Shui, NT, Hong Kong, SAR, China. E-mail: [luith@ha.org.hk](mailto:luith@ha.org.hk) or [luithdeerek@gmail.com](mailto:luithdeerek@gmail.com)

© 2018 by the Arthroscopy Association of North America. Published by Elsevier. This is an open access article under the CC BY-NC-ND license (<http://creativecommons.org/licenses/by-nc-nd/4.0/>).

2212-6287/181207

<https://doi.org/10.1016/j.eats.2018.10.019>

**Table 1.** Indications and Contraindications of Endoscopically Assisted Reconstruction of the Posterior Tibial Tendon for Stage 2 Posterior Tibial Tendon Dysfunction

Indications	Contraindications
1. Symptomatic stage 2 posterior tibial tendon dysfunction recalcitrant to conservative treatment	1. More advanced stages of posterior tibial tendon dysfunction 2. Active infection at the operative site 3. Absence of functional tibialis posterior muscle 4. Pain and tenderness at the navicular insertion of the posterior tibial tendon 5. Presence of huge accessory navicular bone or complete rupture of the posterior tibial tendon (relative contraindications)

Achilles tendon away from being a deforming force.<sup>7</sup> In addition to calcaneal osteotomy, the option of subtalar arthroereisis is gaining in popularity to protect the reconstruction.<sup>7</sup> An arthroereisis implant stabilizes the subtalar joint and prevents excessive hindfoot valgus by supporting the talus and preventing plantar-medial displacement.<sup>7</sup> Endoscopic synovectomy by means of posterior tibial tendoscopy has been demonstrated as a valid therapeutic tool in the treatment of stage 1 PTTD resistant to conservative treatment.<sup>9-11</sup> This approach avoids the need for a long incision, extensive soft tissue dissection, and postoperative immobilization. Endoscopic synovectomy has also been used in management of stage 2 PTTD and can allow for continued conservative therapy while avoiding more invasive surgery in most cases.<sup>10,12</sup> In contrast to stage 1 disease, calcaneal and medial column osteotomies may be needed in addition to the endoscopy with synovectomy.<sup>10</sup> Recently, a technique of endoscopically assisted PTT reconstruction has been reported. The purpose of this Technical Note is to describe the technical details of this endoscopic reconstruction technique, which consists of using the medial half of the anterior tibialis tendon (ATT) as a primary transfer and augmentation by the FDL. This construct is then protected with a subtalar arthroereisis.<sup>13</sup> It is indicated for symptomatic stage 2 PTTD recalcitrant to conservative treatment. It is contraindicated in more advanced

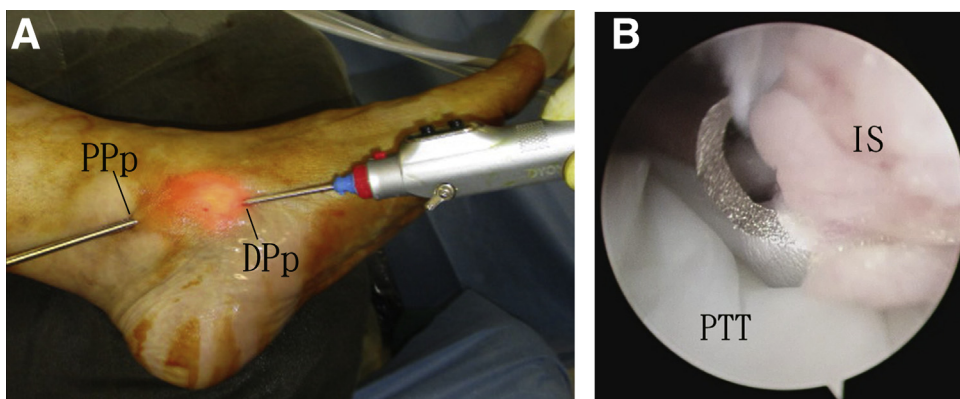
stages of PTTD or if there is active infection at the operative site. It is also contraindicated if there is no functional tibialis posterior muscle or if pain and tenderness are present at the navicular insertion of the PTT. It is relatively contraindicated in the presence of huge accessory navicular bone or complete rupture of the PTT (Table 1). In a case of complete rupture of the PTT, the tendon rupture ends may adhere to the tendon sheath, and it may be difficult to identify them endoscopically. Open reconstruction may be needed.

## Technique

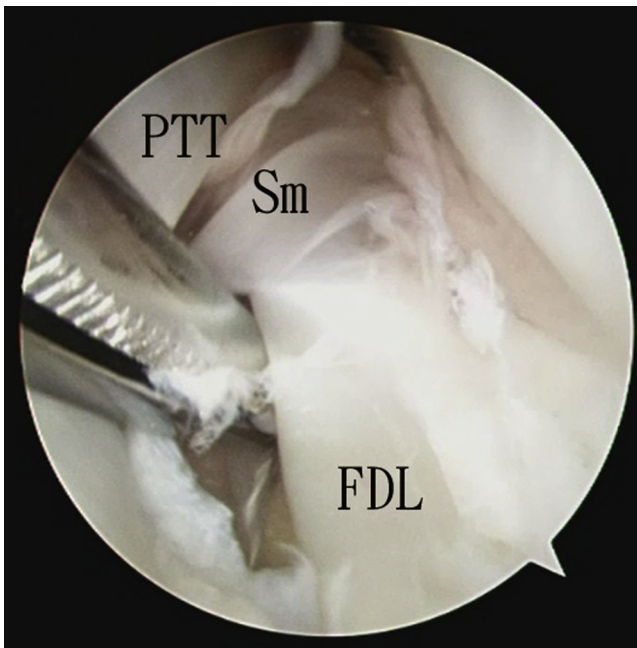
### Preoperative Planning and Patient Positioning

The diagnosis of stage 2 PTTD is confirmed clinically and radiologically. Magnetic resonance imaging and ultrasonography are useful in detecting PTT lesions.<sup>12</sup> However, tendoscopy is more effective than magnetic resonance imaging for detection of a spring ligament tear.<sup>12,14</sup>

The patient is placed in the supine position with the legs spread. A thigh tourniquet is applied to provide a bloodless surgical field. Fluid inflow is by gravity, and no arthropump is used. A 2.7-mm 30° arthroscope (Henke Sass Wolf GmbH, Tuttlingen, Germany) is used for this procedure.



**Fig 1.** Endoscopically assisted reconstruction of posterior tibial tendon for stage 2 posterior tibial tendon dysfunction of left foot. The patient is in the supine position with the legs spread. (A) Posterior tibial tendoscopy is performed with the proximal portal as the viewing portal and the distal portal as the working portal. (B) Endoscopic synovectomy is performed. (DPp, distal portal for posterior tibial tendoscopy; IS, inflamed synovium; PPp, proximal portal for posterior tibial tendoscopy; PTT, posterior tibial tendon.)



**Fig 2.** Endoscopically assisted reconstruction of PTT for stage 2 PTT dysfunction of left foot. The patient is in the supine position with the legs spread. Posterior tibial tendoscopy is performed with an arthroscope: the distal portal is the viewing portal, and the proximal portal is the working portal. The Sm between the PTT and FDL tendon is released by an arthroscopic shaver. (FDL, flexor digitorum longus; PTT, posterior tibial tendon; Sm, septum.)

### Portal Placement

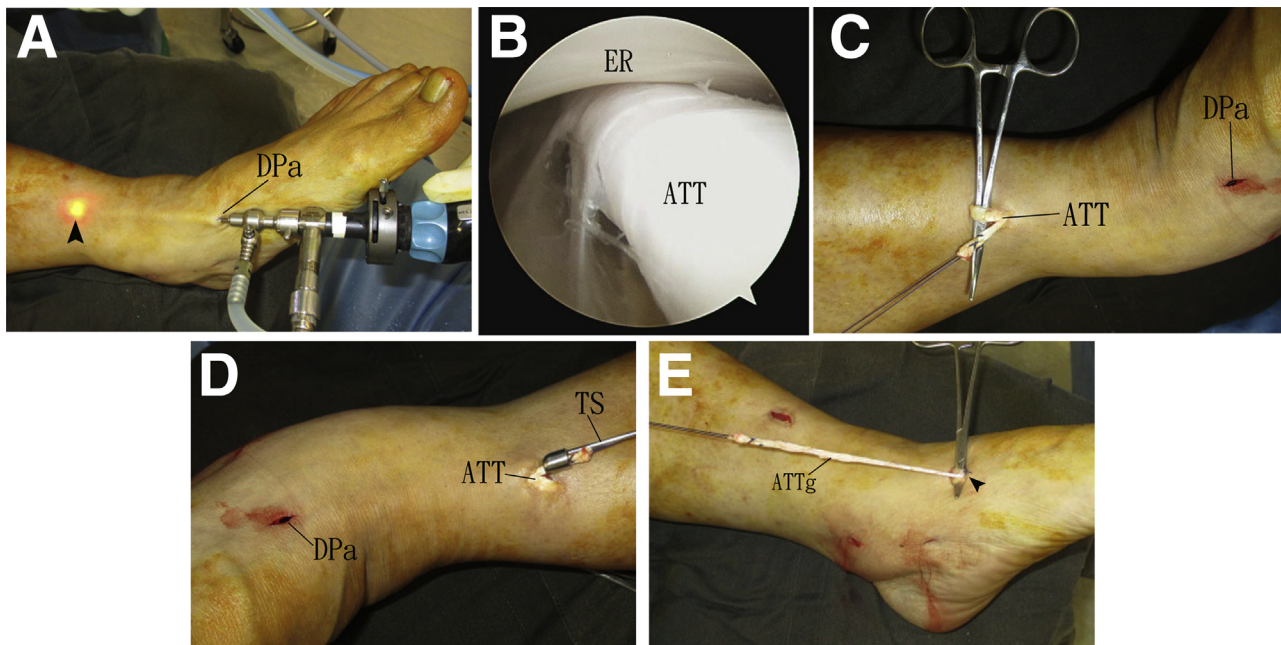
This procedure has 2 parts: posterior tibial tendoscopy and anterior tibial tendoscopy. The distal portal used for posterior tibial tendoscopy (DPp) is located just proximal to the navicular insertion of the PTT. The proximal portal used for posterior tibial tendoscopy (PPp) is located 1 cm proximal to the medial malleolar tip. The distal used for anterior tibial tendoscopy (DPa) is located at the level of the talonavicular joint.

### Endoscopic Synovectomy of PTT Sheath

One-centimeter skin incisions are made at the portal sites of posterior tibial tendoscopy. The subcutaneous tissue is bluntly dissected down to the tendon sheath with a hemostat. The tendon sheath is incised open. Posterior tibial tendoscopy is performed, and endoscopic synovectomy is completed with an arthroscopic shaver (Dyonics; Smith & Nephew, Andover, MA) (Fig 1). The portals are interchangeable as viewing and working portals.

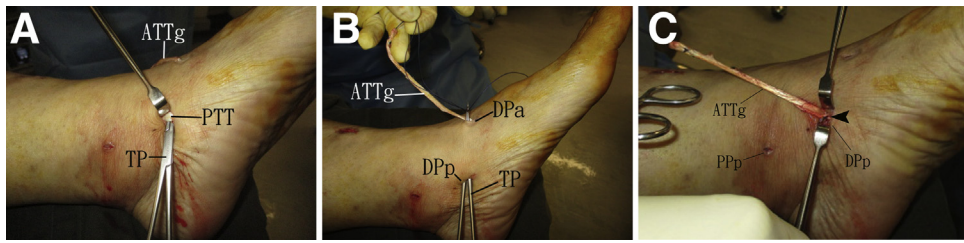
### Release of Septum Between the PTT and FDL Tendon

Posterior tibial tendoscopy is performed with the DPp as the viewing portal. The septum between the PTT and the FDL is identified at the plantar-lateral side of the PTT. The span of the septum between the



**Fig 3.** Endoscopically assisted reconstruction of posterior tibial tendon for stage 2 posterior tibial tendon dysfunction of left foot. The patient is in the supine position with the legs spread. (A) Anterior tibial tendoscopy is performed via the distal portal. The ATT is traced proximally to its musculotendinous junction, marked by the arthroscopic light spot (arrowhead). (B) Endoscopic view shows the ATT under the ER. (C) A 1-cm incision is made at this point. The ATT is split, the medial half is cut, and a stay suture is applied with a No. 1 Vicryl suture. (D) The ATTg is stripped distally to the DPa with a TS. (E) The ATT is sutured with a No. 2 Ultrabraid suture (arrowhead) at the DPa to prevent further splitting of the tendon. The ATTg is retrieved to the DPa. (ATT, anterior tibial tendon; ATTg, split ATT graft; DPa, distal portal for anterior tibial tendoscopy; ER, extensor retinaculum; TS, tendon stripper.)





**Fig 4.** Endoscopically assisted reconstruction of posterior tibial tendon for stage 2 posterior tibial tendon dysfunction of left foot. The patient is in the supine position with the legs spread. (A) The PTT is pierced by a pointed TP at the DPp. (B) The TP is advanced to the DPa, and the stay stitch of the ATTg is grasped. (C) The graft is then transferred to the DPp and passed through the PTT. The ATTg is tensioned, and the intersection between the PTT and the graft is sutured with a No. 2 Ultrabraid suture (arrowhead). (ATTg, split anterior tibial tendon graft; DPp, distal portal for posterior tibial tendoscopy; PPp, proximal portal for posterior tibial tendoscopy; PTT, posterior tibial tendon; TP, tendon passer.)

portals is incised open with an arthroscopic shaver and a pair of Supercut scissors (Stille, Lombard, IL) (Fig 2). The release should be extended a few centimeters proximal to the PPp. This can prevent blockage of the gliding motion of the FDL tendon after reconstruction.

#### Harvest of Split ATT Graft

A 5-mm incision is made at the DPa. The subcutaneous tissue is bluntly dissected to the ATT. Anterior tibial tendoscopy is performed via this portal. The ATT is traced proximally to its musculotendinous junction. A 1-cm incision is made at this point. The ATT is split, the medial half is cut, and a stay stitch is applied with a No. 1 Vicryl suture (Ethicon, Johnson & Johnson, Cincinnati, OH). The split ATT graft is stripped distally to the DPa with a tendon stripper (Aesculap, Hazelwood, MO). The ATT is sutured with an eyed needle (FavorMed, Ningbo, China) loaded with a No. 2 Ultrabraid suture (Smith & Nephew) at the DPa to prevent

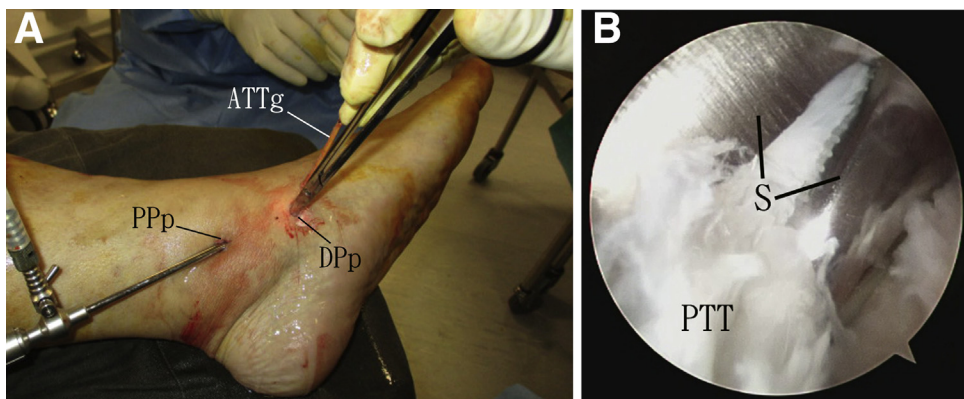
further splitting of the tendon. The split ATT graft is retrieved to the DPa (Fig 3).

#### Transfer of Split ATT to DPp

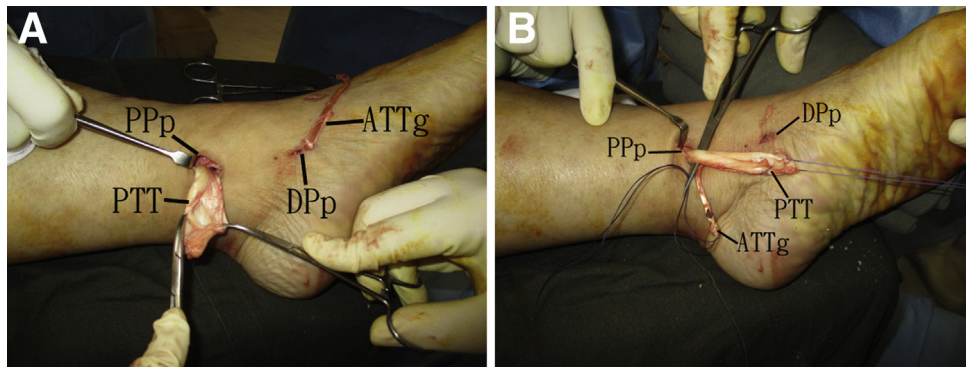
The PTT is pierced by a pointed tendon passer (Aesculap) at the DPp. The passer is advanced to the DPa, and the stay stitch of the split ATT graft is grasped. The graft is then transferred to the DPp and passed through the PTT. The split ATT graft is tensioned, and the intersection between the PTT and the graft is sutured with a No. 2 Ultrabraid suture (Fig 4).

#### Endoscopically Assisted Tenotomy of the PTT

Posterior tibial tendoscopy is performed with the PPp as the viewing portal. The PTT is cut proximal to the sutured site of the split ATT graft to the PTT with the Supercut scissors (Fig 5). The proximal PTT stump is retrieved to the PPp. After this step, the PTT sheath is emptied, and the deltoid ligament and spring ligament can be examined endoscopically for any tear. If there is



**Fig 5.** Endoscopically assisted reconstruction of posterior tibial tendon for stage 2 posterior tibial tendon dysfunction of left foot. The patient is in the supine position with the legs spread. (A) Posterior tibial tendoscopy is performed with the proximal portal as the viewing portal and the distal portal as the working portal. (B) The PTT is cut proximal to the sutured site of ATTg to the PTT with Supercut scissors. (ATTg, split anterior tibial tendon graft; DPp, distal portal for posterior tibial tendoscopy; PPp, proximal portal for posterior tibial tendoscopy; PTT, posterior tibial tendon; S, Supercut scissors.)



**Fig 6.** Endoscopically assisted reconstruction of posterior tibial tendon for stage 2 posterior tibial tendon dysfunction of left foot. The patient is in the supine position with the legs spread. (A) The PTT stump is retrieved to the Pp. (B) The ATTg is transferred to the Pp and weaved to the PTT proximal to the diseased tendon segment in the Pulvertaft manner with a No. 2 Ultrabraid suture. The tendons are tensioned, and the foot is plantarflexed and inverted during the repair. (ATTg, split anterior tibial tendon graft; DPp, distal portal for posterior tibial tendoscopy; Pp, proximal portal for posterior tibial tendoscopy; PTT, proximal posterior tibial tendon.)

a tear in the spring ligament, it can be repaired endoscopically via the DPp.<sup>15</sup>

### Suturing the Split ATT to the Proximal Stump of the PTT

The split ATT graft is transferred to the Pp and weaved to the PTT proximal to the diseased tendon segment in the Pulvertaft manner with a No. 2 Ultrabraid suture (Fig 6). The tendons are tensioned, and the foot is plantarflexed and inverted during the repair.

### FDL Augmentation

The FDL tendon is retrieved to the Pp with a hemostat. The tendon is side-by-side sutured to the split ATT graft–PTT construct with a No. 2 Ultrabraid suture. The foot is plantarflexed and inverted, and the lesser toes are dorsiflexed during the repair (Fig 7). This can prevent postoperative lesser toe deformity.

### Subtalar Arthroereisis

A 2-cm incision is made at the sinus tarsi. The extensor digitorum brevis muscle is reflected dorsally. A guidewire (Arthrex, Naples, FL) is inserted into the sinus tarsi and tarsal canal. The sinus tarsi is dilated with cannulated dilators (Arthrex). A Prostop arthroereisis implant (Arthrex) of appropriate size is inserted into the sinus tarsi with the foot kept in inversion (Figs 8 and 9, Video 1, Table 2).

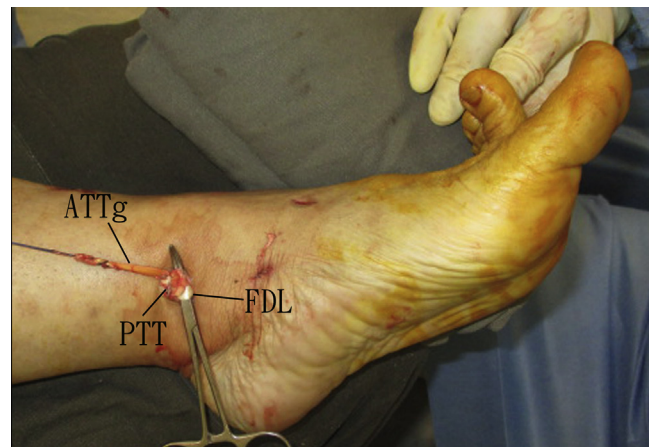
After the operation, an inversion cast is applied for 3 weeks and followed by application of a neutral cast for another 3 weeks. The patient is advised to practice non-weight-bearing walking for 6 weeks and then to resume weight-bearing walking with an arch support.

## Discussion

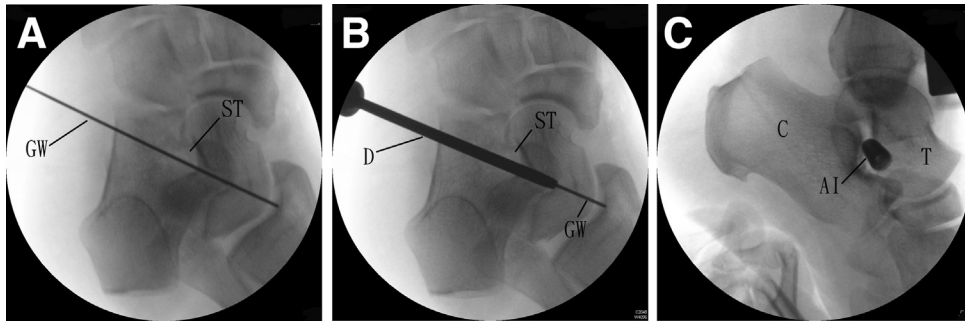
Reconstruction of the PTT by split ATT graft can preserve the flexor hallucis longus and FDL without

sacrificing the action of the tibialis anterior. However, the tendon graft is thin compared with the normal thickness of the PTT. Side-by-side augmentation with the FDL tendon can increase the thickness of the reconstructed tendon. Moreover, the FDL provides an additional motion unit to the tendon construct.

The PTT is not the only soft tissue structure that is diseased in adult-acquired flatfoot deformity. The spring ligament is the principle static medial stabilizer and may also be involved.<sup>9</sup> In addition to the tendon transfer, spring ligament repair may be needed.<sup>2</sup>

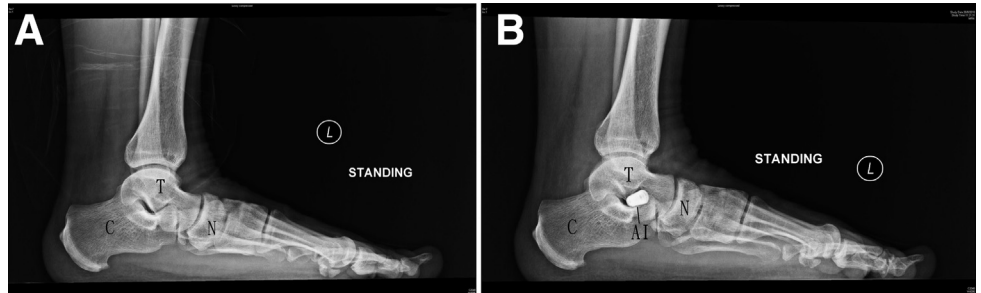


**Fig 7.** Endoscopically assisted reconstruction of posterior tibial tendon for stage 2 PTT dysfunction of left foot. The patient is in the supine position with the legs spread. The FDL tendon is retrieved to the proximal portal for posterior tibial tendoscopy by using a hemostat. The tendon is side-by-side sutured to the ATTg-PTT construct with a No. 2 Ultrabraid suture. The foot is plantarflexed and inverted, and the lesser toes are dorsiflexed during the repair. (ATTg, split anterior tibial tendon graft; FDL, flexor digitorum longus; PTT, posterior tibial tendon.)



**Fig 8.** Endoscopically assisted reconstruction of posterior tibial tendon for stage 2 posterior tibial tendon dysfunction of left foot. The patient is in the supine position with the legs spread. (A) A GW is inserted into the ST and tarsal canal. (B) The ST is dilated with a cannulated D. (C) A Prostop AI is inserted into the sinus tarsi. (AI, arthroereisis implant; C, calcaneus; D, dilator; GW, guidewire; ST, sinus tarsi; T, talus.)

**Fig 9.** Endoscopically assisted reconstruction of posterior tibial tendon for stage 2 posterior tibial tendon dysfunction of left foot. (A) Preoperative standing lateral radiograph of the illustrated case shows flatfoot deformity with talonavicular sag. (B) Postoperative standing lateral radiograph shows correction of the deformity. (AI, Prostop arthroereisis implant; C, calcaneus; N, navicular bone; T, talus.)



**Table 2.** Pearls and Pitfalls of Endoscopically Assisted Reconstruction of the Posterior Tibial Tendon for Stage 2 Posterior Tibial Tendon Dysfunction

Pearls	Pitfalls
<ol style="list-style-type: none"> <li>1. Release of the septum between the posterior tibial and flexor digitorum longus tendons should be extended a few centimeters proximal to the proximal portal for posterior tibial tendoscopy.</li> <li>2. During stripping of the tendon graft, the distal advancement of the stripper may be blocked by the proximal edge of the extensor retinaculum. The stripper can be turned until the stem is facing anteriorly and is pushed posteriorly to overcome the blockage.</li> <li>3. The diseased posterior tibial tendon is grossly thickened, requiring several cuts by the scissors to complete the tenotomy.</li> <li>4. The lesser toes should be dorsiflexed during side-by-side augmentation with the flexor digitorum longus tendon.</li> </ol>	<ol style="list-style-type: none"> <li>1. Overlooking the disrupted accessory navicular synchondrosis as a source of medial foot pain may lead to persistent pain after posterior tibial tendon reconstruction.</li> <li>2. Oversized arthroereisis can lead to sinus tarsi pain or early dislodgement of the implant and wound dehiscence.</li> </ol>

**Table 3.** Advantages and Risks of Endoscopically Assisted Reconstruction of the Posterior Tibial Tendon for Stage 2 Posterior Tibial Tendon Dysfunction

Advantages	Risks
<ol style="list-style-type: none"> <li>1. Better cosmesis</li> <li>2. Less soft tissue dissection</li> <li>3. Less postoperative pain</li> <li>4. Preservation of flexor hallucis longus and flexor digitorum longus actions</li> </ol>	<ol style="list-style-type: none"> <li>1. Injury to the medial plantar nerve</li> <li>2. Rupture of the anterior tibial tendon</li> <li>3. Dislodgement of the arthroereisis implant</li> </ol>

Endoscopic assessment of spring ligament and repair are possible with the same reported endoscopic approach.<sup>14-17</sup>

Calcaneal medializing osteotomy has been the most popular procedure for correction of adult-acquired flatfoot deformity; it has produced the best results according to the published literature and can be performed in a minimally invasive manner.<sup>6,18</sup> However, in adult flatfoot caused by PTT dysfunction, the talus is shifted plantar, medial, and forward, which is a triplane deformity. The correction of the deformity by means of a medializing calcaneal osteotomy acts only in 1 plane, not in all 3 planes, and the osteotomy usually achieves a displacement of between 6 and 10 mm, which is not sufficient to correct the heel valgus in some cases.<sup>12</sup> This does not happen with arthroereisis, in which the whole deformity is corrected before the implant is placed.<sup>6</sup>

The advantages of this endoscopic technique include better cosmesis, less soft tissue dissection, and less postoperative pain. The flexor hallucis longus and FDL actions are preserved. The major risk with the endoscopic approach to the PTT is injury to the medial plantar nerve. Although this approach avoids the medial plantar nerve, damage is still possible and may be greater in patients with severe flatfoot deformities.<sup>10</sup> Other potential risks include rupture of the ATT and dislodgement of the arthroereisis implant (Table 3). This is not a technically demanding procedure and can be attempted by average foot-and-ankle arthroscopists.

## References

1. Smyth NA, Aiyer AA, Kaplan JR, Carmody CA, Kadakia AR. Adult-acquired flatfoot deformity. *Eur J Orthop Surg Traumatol* 2017;27:433-439.
2. Crevoisier X, Assal M, Stanekova K. Hallux valgus, ankle osteoarthritis and adult acquired flatfoot deformity: A review of three common foot and ankle pathologies and their treatments. *EFORT Open Rev* 2016;1:58-64.
3. Johnson KA, Strom DE. Tibialis posterior tendon dysfunction. *Clin Orthop Relat Res* 1989;239:196-206.
4. Myerson MS, Corrigan J. Treatment of posterior tibial tendon dysfunction with flexor digitorum longus tendon transfer and calcaneal osteotomy. *Orthopedics* 1996;19:383-388.
5. Bluman EM, Title CI, Myerson MS. Posterior tibial tendon rupture: A refined classification system. *Foot Ankle Clin* 2007;12:233-249, v.
6. Viladot Voegeli A, Fontecilla Cornejo N, Serrá Sandoval JA, Alvarez Goenaga F, Viladot Pericé R. Results of subtalar arthroereisis for posterior tibial tendon dysfunction stage IIA1. Based on 35 patients. *Foot Ankle Surg* 2018;24:28-33.
7. Ling SK, Lui TH. Posterior tibial tendon dysfunction: An overview. *Open Orthop J* 2017;11:714-723.
8. Ruffilli A, Traina F, Giannini S, Buda R, Perna F, Faldini C. Surgical treatment of stage II posterior tibialis tendon dysfunction: Ten-year clinical and radiographic results. *Eur J Orthop Surg Traumatol* 2018;28:139-145.
9. Bojanic I, Dimnjakovic D, Mahnik A, Smoljanovic T. Is there any room for tendoscopy in the surgical treatment of posterior tibial tendon insufficiency? *Lijec Vjesn* 2016;138:144-151.
10. Wake J, Martin K. Posterior tibial tendon endoscopic debridement for stage I and II posterior tibial tendon dysfunction. *Arthrosc Tech* 2017;6:e2019-e2022.
11. Chow HT, Chan KB, Lui TH. Tendoscopic debridement for stage I posterior tibial tendon dysfunction. *Knee Surg Sports Traumatol Arthrosc* 2005;13:695-698.
12. Bernasconi A, Sadile F, Welck M, Mehdi N, Laborde J, Lintz F. Role of tendoscopy in treating stage II posterior tibial tendon dysfunction. *Foot Ankle Int* 2018;39:433-442.
13. Lui TH. Endoscopic assisted posterior tibial tendon reconstruction for stage 2 posterior tibial tendon insufficiency. *Knee Surg Sports Traumatol Arthrosc* 2007;15:1228-1234.
14. Lui TH. Posterior tibial tendoscopy: Endoscopic synovectomy and assessment of the spring (calcaneonavicular) ligament. *Arthrosc Tech* 2015;4:e819-e823.
15. Lui TH. Endoscopic repair of the superficial deltoid ligament and spring ligament. *Arthrosc Tech* 2016;5:e621-e625.
16. Lui TH, Mak CYD. Arthroscopic approach to the spring (calcaneonavicular) ligament. *Foot Ankle Surg* 2018;24:242-245.
17. Lui TH. Arthroscopic repair of superomedial spring ligament via talonavicular arthroscopy. *Arthrosc Tech* 2017;6:e31-e35.
18. Lui TH. Percutaneous posterior calcaneal osteotomy. *J Foot Ankle Surg* 2015;54:1188-1192.