

isolate of serotype O123:H– is recorded in the database of the World Health Organization Collaborating Centre for Reference and Research on *Escherichia* and *Klebsiella* (F. Scheutz, pers. comm.).

Two strains of STEC O123:H–*stx2d* were isolated from asymptomatic persons in Germany during 1996–2000 (8). A study in Australia in 2003 reported using a strain of O123:H–*stx1 stx2 ehxA* from Switzerland that had been isolated from a person with diarrhea (9).

We report foodborne transmission of STEC O123:H– that resulted in a cluster of clinical cases of infection. Eating ground beef is a well-established mode of STEC transmission, particularly for serotype O157:H7. STEC serotype O123:H– has been isolated from feces of healthy lambs and sheep in Spain (10) and in southwestern Australia (9) and is considered to be among the predominant ovine STEC serotypes in these countries.

This family outbreak shows that STEC serotype O123:H–, albeit rarely described as causing human illness, can cause severe human infection. This serotype can also cause clusters of STEC infections and be transmitted by ingestion of undercooked ground beef.

Acknowledgments

We thank Sylvie Peters, Hélène Perin, Lydie Pachtchenko-Claudet, Marie-Odile Klippenspies, Julie Hanot, Laurent Claudet, Philippe Couratier, and Valerie le Bourg for assistance with investigating this outbreak; and Flemming Scheutz for verifying serotypes and virulence genes.

**Lisa A. King,
Ingrid Filliol-Toutain,
Patricia Mariani-Kurkidjian,
Véronique Vaillant,
Christine Vernozy-Rozand,
Sarah Ganet, Nathalie Pihier,
Patrick Niaudet,
and Henriette de Valk**

Author affiliations: Institut de Veille Sanitaire, Saint Maurice, France (L.A. King, V. Vaillant, H. de Valk); Institut Pasteur, Paris, France (I. Filliol-Toutain); Hôpital Robert Debré, Paris (P. Mariani-Kurhidjian); VetAgro Sup Campus Vétérinaire de Lyon, Marcy l'Etoile, France (C. Vernozy-Roxand, S. Gantet); Direction Générale de l'Alimentation, Paris (N. Pihier); and Hôpital Necker Enfants Malades, Paris (P. Niaudet)

DOI: 10.3201/eid1609.100472

References

- Espié E, Grimont F, Mariani-Kurkdjian P, Bouvet P, Haeghebaert S, Filliol I, et al. Surveillance of hemolytic uremic syndrome in children less than 15 years of age, a system to monitor O157 and non-O157 Shiga toxin-producing *Escherichia coli* infections in France, 1996–2006. *Pediatr Infect Dis J*. 2008;27:595–601. DOI: 10.1097/INF.0b013e31816a062f
- Paton AW, Paton JC. Detection and characterization of Shiga toxin-producing *Escherichia coli* by using multiplex PCR assays for *stx1*, *stx2*, *eaeA*, enterohemorrhagic *E. coli hlyA*, *rfbO111*, and *rfbO157*. *J Clin Microbiol*. 1998;36:598–602.
- Coimbra RS, Grimont F, Lenormand P, Burguière P, Beutin L, Grimont PAD. Identification of *Escherichia coli* O-serogroups by restriction of the amplified O-antigen gene cluster (*rfb*-RFLP). *Res Microbiol*. 2000;151:639–54. DOI: 10.1016/S0923-2508(00)00134-0
- Coimbra RS, Lefevre M, Grimont F, Grimont PA. Clonal relationships among *Shigella* serotypes suggested by cryptic flagellin gene polymorphism. *J Clin Microbiol*. 2001;39:670–4. DOI: 10.1128/JCM.39.2.670-674.2001
- Read SC, Clarke RC, Martin A, De Grandis SA, Hii J, McEwen S, et al. Polymerase chain reaction for detection of verocytotoxin-producing *Escherichia coli* isolated from animals and food sources. *Mol Cell Probes*. 1992;6:153–61. DOI: 10.1016/0890-8508(92)90060-B
- Perelle S, Dilasser F, Grout J, Fach P. Detection by 5'-nuclease PCR of Shiga toxin producing *Escherichia coli* O26, O55, O91, O103, O111, O113, O145 and O157:H7, associated with the world's most frequent clinical cases. *Mol Cell Probes*. 2004;18:185–92. DOI: 10.1016/j.mcp.2003.12.004
- Ribot EM, Fair MA, Gautom R, Cameron DN, Hunter SB, Swaminathan B, et al. Standardization of pulsed-field gel electrophoresis protocols for the subtyping of *Escherichia coli* O157:H7, *Salmonella*, and *Shigella* for PulseNet. *Foodborne Pathog Dis*. 2006;3:59–67. DOI: 10.1089/fpd.2006.3.59
- Friedrich AW, Bielaszewska M, Zhang WL, Pulz M, Kuczius T, Ammon A, et al. *Escherichia coli* harboring Shiga toxin 2 gene variants: frequency and association with clinical symptoms. *J Infect Dis*. 2002;185:74–84. DOI: 10.1086/338115
- Brett KN, Ramachandran V, Hornitzky MA, Bettelheim KA, Walker MJ, Djordjevic SP. *stx1c* is the most common Shiga toxin 1 subtype among Shiga toxin-producing *Escherichia coli* isolates from sheep but not among isolates from cattle. *J Clin Microbiol*. 2003;41:926–36. DOI: 10.1128/JCM.41.3.926-936.2003
- Blanco M, Blanco JE, Mora A, Rey J, Alonso JM, Hermoso M, et al. Serotypes, virulence genes, and intimin types of Shiga toxin (verotoxin)-producing *Escherichia coli* isolates from healthy sheep in Spain. *J Clin Microbiol*. 2003;41:1351–6. DOI: 10.1128/JCM.41.4.1351-1356.2003

Address for correspondence: Lisa A. King, Département de Maladies Infectieuses, Institut de Veille Sanitaire, 12 rue du Val d'Osne, 94415 Saint-Maurice CEDEX, France; email: l.king@invs.sante.fr

Austrian Syndrome Associated with Pandemic (H1N1) 2009 in Child

To the Editor: In 1957, an American internist reported the preference of *Streptococcus pneumoniae* for the aortic valve and its frequent association with meningitis and pneumonia (1), an association now known as Austrian syndrome. This syndrome mainly occurs in middle-age men who have predisposing factors, such as chronic alcoholism, altered immune state, duodenal fistula, and ear or sinus infections.

One case of Austrian syndrome has been reported in the pediatric age group, in a 7-year-old girl in whom aortic valve endocarditis developed

after pneumococcal meningitis infection (2). In pneumococcal endocarditis, the native aortic valve is the most frequent location of vegetation. Valve replacement must be considered to avoid development of cardiogenic shock, whereas medical treatment alone may be adequate in some cases of mitral endocarditis (3,4).

We report a previously healthy adolescent with Austrian syndrome associated with pandemic (H1N1) 2009 infection. Cardiac involvement resulted in extensive mitral valve destruction requiring surgical valve replacement.

A 13-year-old boy had cough, nasal congestion, and a fever $\geq 103^{\circ}\text{F}$ for 2 weeks before being seen at a hospital. On the day he was admitted to hospital, he became unarousable, and weakness was noted on his left side. His medical history included mild asthma requiring no therapy over the past 3 years. His immunizations were up to date except for seasonal influenza and pandemic (H1N1) 2009 vaccination.

When admitted to hospital, his temperature was 38.7°C , blood pressure 97/47 mm Hg, respiratory rate 77 breaths/min, and heart rate 150 beats/min. Pupils were 3 mm in diameter and reactive to light and accommodation. Weakness and hypertonia of the left upper and lower extremities were noted. He had neck stiffness without Kernig sign or Brudzinski sign. Complete blood count showed a leukocyte count of 26,400 cells/mm³ and differential of 92.1% neutrophils, 5.3% lymphocytes, 2.6% monocytes, and 0.1% eosinophils; hemoglobin level of 12.9 g/dL; hematocrit 38.6%; and a thrombocyte count of 102,000 cells/mm³. A plain chest radiograph showed a left lower lobe infiltrate. Computed tomography of the head showed a large infarction involving the right frontal lobe at the distribution of the right middle cerebral artery; small infarcts involved the left frontal lobe and the right parietal lobe.

Lumbar puncture showed a leukocyte count of 100 cells/mm³, 71% neutrophils, 8% bands, 15% lymphocytes, 5% monocytes, and 1% eosinophils; protein 195 mg/dL, and glucose 6 mg/dL, with a blood glucose level of 140 mg/dL. Gram stain of the cerebrospinal fluid showed gram-positive cocci in pairs. The patient was treated with intravenous ceftriaxone, vancomycin, and dexamethasone. He subsequently became unconscious and hypotensive and required intubation with mechanical ventilation and intravenous dopamine. His nasal wash sample was positive for pandemic (H1N1) 2009 RNA by real-time reverse transcription-PCR; oseltamivir (75 mg) through a nasogastric tube every 12 h for 5 days was administered. Because of heart murmur, a 2-dimensional echocardiography was conducted; it showed a large mitral valve vegetation 1.6 cm \times 2.1 cm attached to the posterior mitral leaflet and mild to moderate mitral insufficiency. Because of this finding, he was transferred to Children's

Hospital of Michigan for surgical intervention.

Physical examination at Children's Hospital showed a well-nourished adolescent who was intubated and sedated. A grade 3 systolic ejection murmur at the left lower sternal border was noted. Neurologic examination showed sluggish pupils, decreased tone of the left extremities, and bilateral Babinski sign. No meningeal signs were observed. Magnetic resonance imaging of the head showed multiple areas of infarction, with the largest being in the right middle cerebral artery distribution and a smaller one in the left frontal region (Figure). A few small scattered areas of infarction bilaterally were suggestive of cerebral embolism.

Two days after transfer, the patient underwent mitral valve replacement with a St. Jude prosthetic valve (St. Jude Medical, St. Paul, MN, USA). A 2.5-cm vegetation was found on the atrial surface of the inferior aspect of the posterior mitral leaflet involving the inferior commissure. The posterior

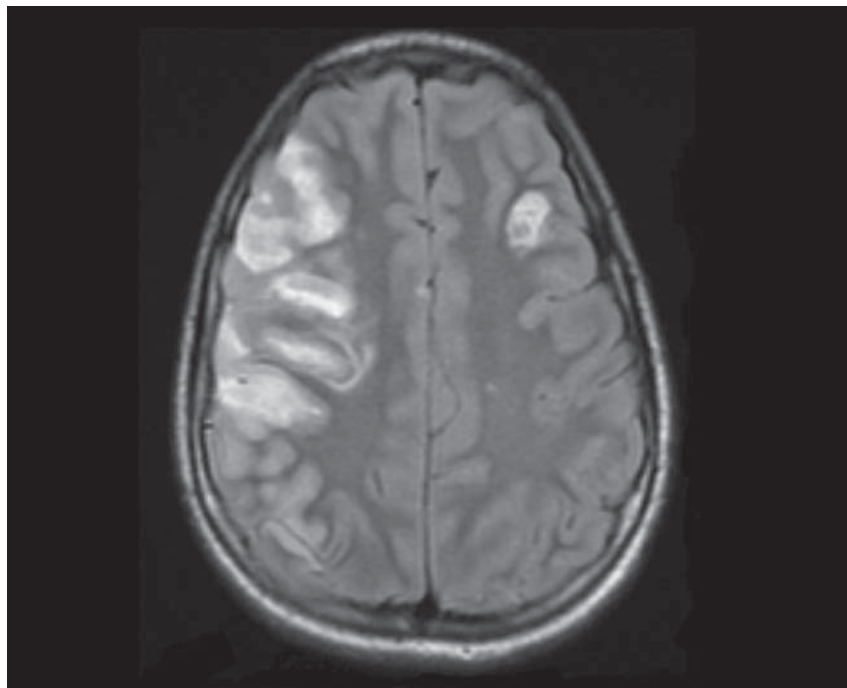


Figure. Magnetic resonance image of the head of the patient, a 13-year-old boy, showing multiple areas of infarction bilaterally with the largest in the right middle cerebral artery distribution and a smaller one in the left frontal region consistent with embolic infarcts.

leaflet associated with the vegetation was destroyed. The vegetation culture, pericardial fluid culture, tissue culture from the resected mitral valve, and 3 blood cultures yielded no bacterial growth.

The patient required ventilator support for 7 days. Follow-up computed tomography on day 8 showed a stable appearance of cerebral infarcts. Coumadin was started to prevent thrombus development at the prosthetic valve. He went home after completing a 4-week treatment course of ceftriaxone. At that time, there was still noticeable left-sided weakness of the extremities. He could only communicate by using eye movements with no verbal response.

During the 20th century influenza pandemics, secondary bacterial pneumonia was a notable cause of death. The current pandemic (H1N1) 2009 outbreak is evolving rapidly, and it is unknown if pandemic (H1N1) 2009 may lead to an increase in rare complications of pneumococcal infection, such as endocarditis. Thus, Austrian syndrome should be considered in any patient with pandemic (H1N1) 2009 complicated by pneumococcal infection and a new heart murmur.

Waseem Alhushki and Chokechai Rongkavilit

Author affiliation: Wayne State University, Detroit, Michigan, USA

DOI: 10.3201/eid1609.091779

References

1. Austrian R. Pneumococcal endocarditis, meningitis, and rupture of the aortic valve. *AMA Arch Intern Med.* 1957;99:539–44.
2. Rammeloo L, Hruda J, Sobotka-Plojhar M, Avis W, Schoof P. Austrian syndrome in a child—aortic valve endocarditis following pneumococcal meningitis. *Int J Cardiol.* 2004;94:321–2. DOI: 10.1016/j.ijcard.2003.03.025
3. Aronin SI, Mukherjee SK, West JC, Cooney EL. Review of pneumococcal endocarditis in adults in the penicillin era. *Clin Infect Dis.* 1998;26:165–71. DOI: 10.1086/516279
4. Lefort A, Mainardi JL, Selton-Suty C, Casassus P, Guillemin L, Lortholary O. *Streptococcus pneumoniae* endocarditis in adults. A multicenter study in France in the era of penicillin resistance (1991–1998). The Pneumococcal Endocarditis Study Group. *Medicine (Baltimore).* 2000;79:327–37. DOI: 10.1097/00005792-200009000-00006

Address for correspondence: Waseem Alhushki, Children's Hospital of Michigan, 3901 Beaubien Blvd, Detroit, MI 48201 USA; email: walhushk@dmc.org

Rickettsia sibirica mongolitimonae in Traveler from Egypt

To the Editor: Tick-borne rickettsioses are zoonoses caused by spotted fever group (SFG) *Rickettsia* spp. (*I*), which have been reported as a frequent cause of fever in international travelers (2). In Egypt, Mediterranean spotted fever caused by *Rickettsia conorii* transmitted by the brown dog tick, *Rhipicephalus sanguineus*, is known to be present, although cases are rarely documented. Moreover, an emerging pathogen, *R. aeschlimannii*, has been detected in *Hyalomma dromedarii* ticks, collected from camels, and in *H. impeltatum* and *H. marginatum rufipes*, collected from cows (3). We report a case of *Rickettsia sibirica mongolitimonae* infection in a French traveler who returned from Egypt

In September 2009, a previously healthy 52-year-old man living in France was admitted to the infectious diseases unit of a hospital in Nantes, France, with a 10-day history of fever, asthenia, headache, and arthromyalgia. Three days earlier, he had returned from a 2-week trip to Egypt. He had fever (38°C), painful axillary lymph-

adenopathies, and an inoculation eschar surrounded by an inflammatory halo on the left scapular area (online Appendix Figure, www.cdc.gov/EID/content/16/9/1495-appF.htm), but he did not have a rash. During his travel, he had been unsuccessfully treated for headache, arthromyalgia, and diarrhea by amoxicillin-clavulanate (3 g/d), nonsteroidal antiinflammatory drugs, and gentamicin cream on the eschar for 3 d. No tick bite was reported by the patient. We suspected an SFG rickettsiosis. The patient received 200 mg doxycycline in a single dose and rapidly improved.

The immunofluorescence assay for antibodies reactive against SFG antigens showed increased levels of immunoglobulin M (titer 16) and G (titer 128). Results of Western blot with cross-adsorption assays supported the hypothesis that the infection was caused by *R. sibirica mongolitimonae* (*I*). To identify the involved rickettsiae, PCR amplifications and sequencing *gltA*, *ompA*, and *ompB* fragment genes of *Rickettsia* spp. and multispacer typing (MST), based on the sequence of variable intergenic spacers, were performed by using DNA samples obtained from an eschar biopsy and a lesion swab (4,5). A negative control (sterile water and DNA from a sterile biopsy specimen) and a positive control (DNA from *R. montanensis*) were included in each test. Amplicon sequencing confirmed the presence of *R. sibirica mongolitimonae* DNA in patient samples. The sequence homology to *R. sibirica mongolitimonae* DNA was *ompA*, 99.4%; *gltA*, 99.7%; and *ompB*, 100% (GenBank accession nos. DQ097082, DQ097081, and AF123715, respectively). The MST sequences were 100% homologous to the genotype of *R. sibirica mongolitimonae* MST type U (idem HA-91). We injected shell vial cultures with eschar biopsy specimens (4). Fifteen days later, positive Gimenez staining and immunofluorescence confirmed