



Contents lists available at ScienceDirect

International Journal of Surgery Case Reports

journal homepage: www.casereports.com

Xantogranulomatous pyelonephritis: The missed diagnosis



Yassine EL Abiad*, Youness Dehayni, Abdelmounaim Qarro, Bouzid Balla, Abdelghani Ammani, Mohammed Alami

Department of Urology, Military Hospital Moulay Ismail, Meknès, Morocco

ARTICLE INFO

Article history:

Received 4 October 2015
 Received in revised form
 10 November 2015
 Accepted 24 November 2015
 Available online 30 November 2015

Keywords:

Diagnostic imaging
 Infection
 Renal cell carcinoma
 Tumor
 Xantogranulomatous pyelonephritis

ABSTRACT

INTRODUCTION: Xantogranulomatous pyelonephritis (XGPN) is a rare chronic inflammatory disease of the kidney that can be focal or diffuse with the focal form imitating greatly renal cell carcinoma (RCC).
PRESENTATION OF CASE: We report a challenging clinical case of a 38-year old male with right flank pain persisting for 3-months, imaging showed an 8 cm heterogenous mass of the upper pole of the right kidney and invading the liver. A right radical nephrectomy including the adrenal in the resection was performed under the tentative diagnosis of renal cell carcinoma (RCC) whereas histology revealed focal XGPN.
DISCUSSION: Preoperative diagnosis of focal XGPN was difficult because of radiological similarities to RCC and lack of history of stone disease or urinary tract infection.
CONCLUSION: This case highlights the need to include XGPN in the differential diagnosis of RCC even in the era of modern imaging.

© 2015 The Authors. Published by Elsevier Ltd. on behalf of IJS Publishing Group Ltd. This is an open access article under the CC BY-NC-ND license (<http://creativecommons.org/licenses/by-nc-nd/4.0/>).

1. Introduction

Xantogranulomatous pyelonephritis (XGPN) is an uncommon chronic inflammatory process characterized by destruction and replacement of renal and/or perirenal tissue with a diffuse infiltration of granulomatous tissue containing lipid-filled macrophages (xantoma cells).

It mainly affects middle-aged females especially in the presence of chronic obstruction and suppuration. It is classified as diffuse or focal type which is a great imitator of renal cell carcinoma (RCC) because of radiological similarities.

We report a more diagnostic-challenging case that lack even the usual clinical presentation and risk factors.

2. Presentation of case

A 38-year-old man with a 3-months history of right flank pain associated with a 6 kg unintentional weight loss over this period. The patient reported no history of fever, stones disease or urinary tract infections. Physical examination showed no remarkable findings but right flank sensitivity at palpation.

First, an ultrasonography (US) was performed and revealed an 8 cm-hyperechogene heterogene mass of the upper right-kidney pole with close contact with the liver. An abdominal computed tomography (CT) confirmed the presence of an 8 cm/7.5 cm well-circumscribed and heterogenous right upper-pole renal mass which is extending to the right adrenal gland and the inferior face of the liver. No lymphadenopathy was seen. Also there was no evidence of hydronephrosis, renal or ureteral calculi (Figs. 1 and 2).

Laboratory findings showed an elevated neutrophils count (17,000/ml), elevated sedimentation speed (130 mm/first hour) and elevated liver enzymes but a sterile urine culture.

Based on these results, an open right radical nephrectomy including the adrenal in the resection was performed. The mass was adherent to the inferior face of the liver but resection of all suspected tissue was possible and hemostasis established using Surgicel meshes.

The patient tolerated the procedure well and was discharged 3 days later after an uneventful recovery, well ahead of expectations given the extent of his surgery.

Final histology revealed a focal 5 cm × 4 cm × 3 cm renal mass which consist with a xantogranulomatous pyelonephritis (Fig. 3).

At 2-months follow-up there was no evidence of recurrence or complication and the patient was not subject to adjuvant therapy.

3. Discussion

Xantogranulomatous pyelonephritis is a rare form of chronic, usually unilateral, renal infection. Since 1916, when Schlagenhaupt described the first case [1], 300 cases have been reported [2]. The etiology of the disease remains unknown. It typically

* Corresponding author at: N°895, Soraya II, Route Haj Kaddour, Meknès, Morocco. Fax: +212 535510941.

E-mail addresses: yassineelbiad@gmail.com (Y. EL Abiad), dr.y.dehayni@gmail.com (Y. Dehayni), abdelmounaimqarro@yahoo.fr (A. Qarro), bbouziduro@hotmail.com (B. Balla), ammani-1@hotmail.com (A. Ammani), alami.mohammed1@yahoo.fr (M. Alami).

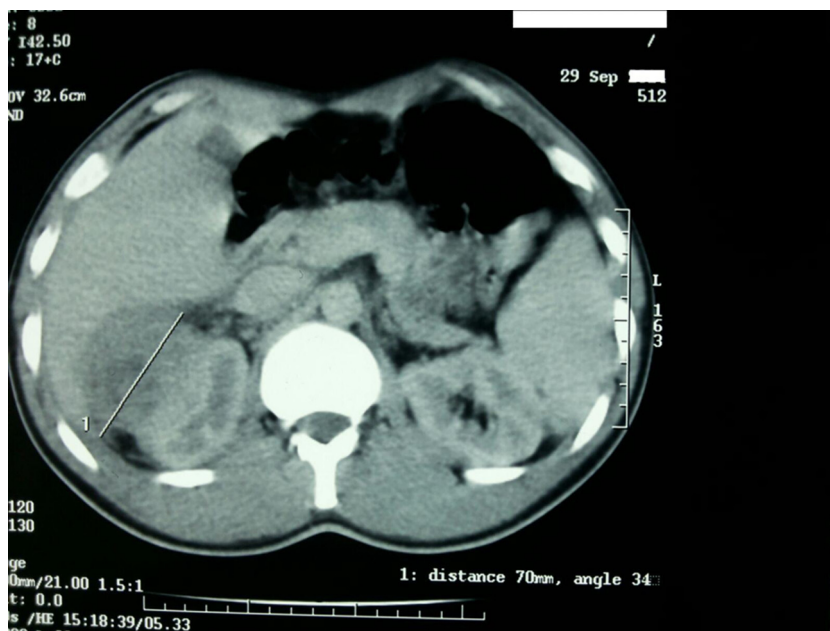


Fig. 1. A non-contrast CT axial view of the abdomen showing an upper pole mass of the right kidney with close contact with liver.

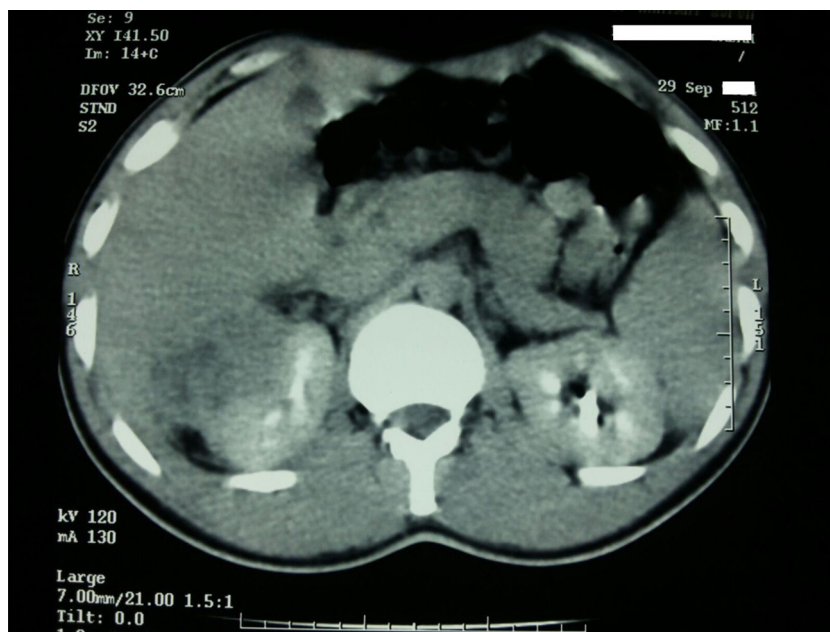


Fig. 2. A contrast-enhanced CT axial view of the abdomen showing the extent of the upper pole tumor of the right kidney to the calyceal tract.

affects middle-aged women in the presence of chronic obstruction and suppuration particularly if induced by *Proteus* sp. and *Escherichia coli* [3].

Histologically, XGPN is characterized by destruction and replacement of the renal parenchyma and even adjacent tissues with granulomatous tissue containing lipid-filled macrophages (xantoma cells). The diffuse form is more common (85%) than the focal one which poses a real challenging diagnosis [4].

The CT is considered the best imaging study to diagnose XGPN and some authors cited hydronephrosis, stone presence or a history thereof and parenchymal thickening as possible hints to diagnose it [1,4]. However radiological similarities to RCC especially when invading peri-renal organs and tissues, liver and adrenal gland in

our case, justify its name as 'great imitator' [1]. Also 7 cases of inferior vena cava (IVC) thrombus due to XGPN have been described [5].

In this case, the absence of CT hints like hydronephrosis and stones and the presence of the liver invasion made the diagnosis more challenging, therefore ruling out renal cancer would not have been possible preoperatively.

Conservative management of XGPN with antibiotics has been used in some cases and the use of preoperative biopsy is still limited by the risk of seeding and the high false-negative results [6].

Subsequently, treatment is often given by large open surgery and in the few cases managed by laparoscopy, high conversion rates were observed [7].

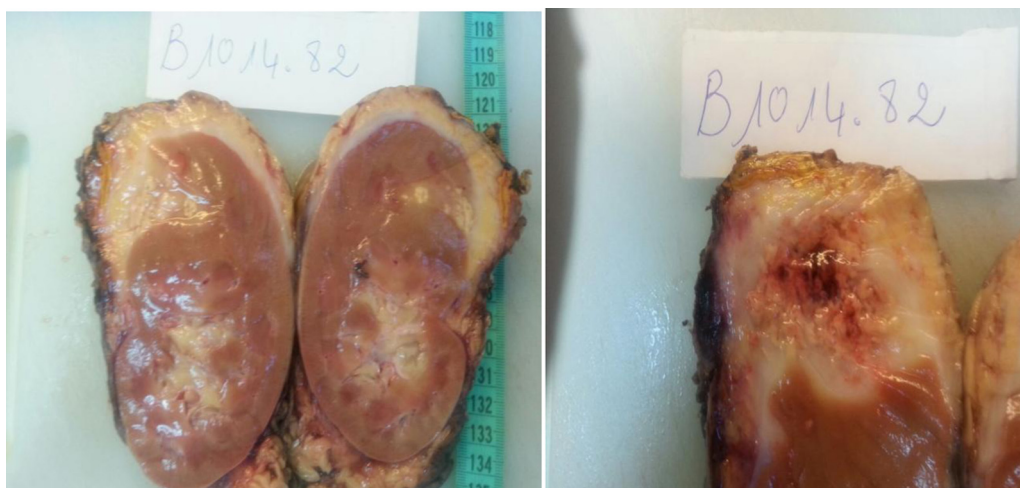


Fig. 3. Macroscopic view of a longitudinal section of the right kidney showing a 5 cm × 4 cm × 3 cm upper pole and anterior focal mass invading adrenal gland and the perirenal fat but distant from the hilum.

4. Conclusion

This rare case of focal XGPN in a male without history of urological disease highlights the need for careful intraoperative evaluation of unexpected findings, as well as serving as a reminder of the need to include XGPN in the differential diagnosis of RCC even in the era of modern imaging and particularly in patients with a single kidney or an impaired renal function.

Funding

None reported.

Conflicts of interest

None of the contributing authors have any conflict of interest, including specific financial interests or relationships and affiliations relevant to the subject matter or materials discussed in the manuscript.

Ethical approval

We do not have an ethics committee.

Authors contribution

Study concept : EL ABIAD Yassine; QARRO Abdelmounaim.

Data collection, data analysis or interpretation: EL ABIAD Yassine; DEHAYNI Youness; BALLA Bouzid; AMMANI Abdelghani; ALAMI Mohammed.

Writing the paper: EL ABIAD Yassine; QARRO Abdelmounaim.

Consent

Written informed consent was obtained from the patient for publication of this case report and accompanying images. A copy of the written consent is available for review by the Editor-in-Chief of this journal on request.

Guarantor

Yassine EL ABIAD.

Acknowledgments

We thank all members of staff of Urology department.

References

- [1] I. Zorzos, V. Moutzouris, C. Petraki, G. Katsou, Xanthogranulomatous pyelonephritis: the great imitator justifies its name, *Scand. J. Urol. Nephrol.* 36 (February (1)) (2002) 74–76.
- [2] S. Gerus, W. Apoznański, T. Szydełko, D. Patkowski, Pyelonephritis xanthogranulomatosa in a 7-year-old girl, *Cent. Eur. J. Urol.* 65 (3) (2012) 162–163.
- [3] M.A. Anhalt, C.D. Cawood, R. Scott Jr., Xanthogranulomatous pyelonephritis: a comprehensive review with report of 4 additional cases, *J. Urol.* 105 (January (1)) (1971) 10–17.
- [4] J.C. Kim, US and CT findings of xanthogranulomatous pyelonephritis, *Clin. Imaging* 25 (March–April (2)) (2001) 118–121.
- [5] H.M. Rosevear, M.M. Meier, B.L. Gallagher, F.N. Joudi, Surgically discovered xanthogranulomatous pyelonephritis invading inferior vena cava with coexisting renal cell carcinoma, *Sci. World J.* 18 (January (9)) (2009) 5–9.
- [6] A. Garberini, M. Caricato, S. Valeri, et al., Xanthogranulomatous pyelonephritis and renal carcinoma: report of a clinical case and review of the literature, *Suppl. Tumori* 4 (May–June (3)) (2005) S210.
- [7] F. Korkes, R.L. Favoretto, M. Bróglío, C.A. Silva, M.G. Castro, M.D. Perez, Xanthogranulomatous pyelonephritis: clinical experience with 41 cases, *Urology* 71 (February (2)) (2008) 178–180.

Open Access

This article is published Open Access at sciedirect.com. It is distributed under the [IJSCR Supplemental terms and conditions](#), which permits unrestricted non commercial use, distribution, and reproduction in any medium, provided the original authors and source are credited.