

BRIEF COMMUNICATION

Missing correlation of retinal vessel diameter with high-altitude headache

Gabriel Willmann¹, M. Dominik Fischer^{1,2}, Kai Schommer³, Peter Bärtsch³, Florian Gekeler^{1,4} & Andreas Schatz¹

¹Centre for Ophthalmology, University of Tübingen, Tübingen, Germany

²Nuffield Laboratory of Ophthalmology, University of Oxford, United Kingdom

³Department of Sports Medicine, Medical Clinic, University Hospital Heidelberg, Heidelberg, Germany

⁴Department of Ophthalmology, Katharinenhospital, Stuttgart, Germany

Correspondence

Florian Gekeler, Department of Ophthalmology, Katharinenhospital, Kriegsbergstraße 60, 70174 Stuttgart, Germany. Tel: +49 711 27833101; Fax: +49 711 27833109; E-mail: f.gekeler@klinikum-stuttgart.de

Funding Information

This study was supported by the Wilderness Medical Society (WMS) with the Charles S. Houston Research Award; Imedos, Jena, Germany and Heidelberg Engineering, Heidelberg, Germany. The supporting sources had no role in study design; collection, analysis, and interpretation of data; writing the report; and the decision to submit the report for publication.

Received: 3 September 2013; Revised: 12 October 2013; Accepted: 14 October 2013

Annals of Clinical and Translational Neurology 2014; 1(1): 59–63

doi: 10.1002/acn3.18

Abstract

The most common altitude-related symptom, high-altitude headache (HAH), has recently been suggested to originate from restricted cerebral venous drainage in the presence of increased inflow caused by hypoxia. In support of this novel hypothesis, retinal venous distension was shown to correlate with the degree of HAH. We quantified for the first time retinal vessel diameter changes at 4559 m using infrared fundus images obtained from a state of the art Spectralis™ HRA+OCT with a semiautomatic VesselMap 1® software. High-altitude exposure resulted in altered arterial and venous diameter changes at high altitude, however, independent of headache burden.

Introduction

The cause of high-altitude headache (HAH) is unknown. The idiosyncratic nature of HAH during high-altitude exposure and consequently in acute mountain sickness (AMS) was first hypothesized to result from an increase in intracranial pressure (ICP) in the form of cerebral edema secondary to high-altitude hypoxemia.¹ However, subsequent studies investigating HAH in AMS and the presence of increased ICP have found little evidence to support this hypothesis.^{2–4} Furthermore, recent studies suggest that the degree of hypoxia in AMS is not able to

cause sufficient cerebral edema resulting in respective symptoms typical of AMS including headache.^{2,5}

Although it is well known that high-altitude exposure leads to a marked increase in cerebral blood flow,⁶ cerebral –and subsequently retinal – venous physiology has until recently been thought to be of little consequence with regard to disease pathophysiology of HAH. However, as various similarities between clinical syndromes resulting from restricted cerebral venous outflow and HAH may exist,^{7,8} recent studies have started to focus on gaining a better understanding of the cerebral inflow/outflow mismatch at high altitude with regard to HAH.

Wilson et al.^{9,10} have postulated and first shown that distension of large cerebral veins due to restricted cerebral venous outflow in the presence of increased inflow may account for HAH. This finding was supported by a positive correlation between retinal venous distension and the severity of HAH on preceding days during trekking to an altitude of 5300 m.

Our study investigated retinal vessel diameter in correlation with HAH burden and AMS in order to investigate the proposed pathophysiological mechanisms of HAH using – for the first time – infrared fundus imaging and semiautomatic assessment of vascular diameters in a well-established setting for studying AMS.¹¹

Methods

Study design and clinical assessment of high-altitude exposure

Eighteen healthy subjects (14 volunteers and four investigators; seven females, 11 males; age 25–54 years) were exposed to the research facility of the Capanna Margherita at 4559 m (CM; Valais Alps, Italy) to assess retinal vessel changes with regard to AMS/HAH as described previously.^{12,13} Ascent to CM was completed within 24 h with one overnight stay at the Capanna Gnifetti 3647 m. All subjects spent three nights at the research facility at high altitude before descending back to low altitudes (341 m) on day 4. Before and after high-altitude exposure, subjects were asked to spend at least 2 weeks below 2000 m to exclude confounding effects due to previous altitude exposure (baseline = before and baseline 2 = after descent from high altitude). Ophthalmological exclusion criteria included current or positive history of conditions affecting the posterior chamber (e.g., diabetic retinopathy, retinal artery or vein occlusion, age-related macular degeneration, history of retinal surgery or glaucoma) on either eye and/or optical opacities limiting imaging quality.

Assessment of AMS, HAH, and clinical parameters

For assessment of AMS and intensity of HAH, the Lake-Louise (LL) and the AMS-cerebral scores (AMS-C) of the Environmental Symptom Questionnaire (ESQ III) were used once at each baseline examination and twice daily at high altitude. For both scores, subjects answered questions about the severity of symptoms of AMS including HAH; for LL symptoms are graded 0 = no, 1 = mild, 2 = moderate, and 3 = severe symptoms, and for the AMS-C Score symptoms are graded from 0 = no to 5 = extremely severe symptoms, respectively. Consistent with previous literature, AMS was assumed when both

scores met the cut-off criteria set for $LL \geq 5$ and $AMS-C \geq 0.70$ in the presence of headache.^{2,12,14} Measurements of oxygen saturation (SpO_2) and heart rate (HR) were performed once at each baseline and at high altitude in the morning before getting up and after >5 min at rest in the evening with a finger pulse oxymeter (oxy control 4c®; Geratherm Medical AG, Geschwenda, Germany). Values were recorded after 1 min of steady measurement.

Retinal vessel analysis

Infrared fundus images were obtained using two identical Spectralis™ HRA+OCT (Heidelberg Engineering, Heidelberg, Germany) devices at baseline and high altitude in the morning after arrival as described previously.^{12,15} Careful calibration of the laser light source of the Spectralis™ HRA+OCT device at high altitude was performed after helicopter transport (Air Zermatt AG Heliport, Zermatt, Switzerland). Assessment of retinal artery and vein diameters was performed using the semiautomatic VesselMap 1® software (Imedos Systems, Jena, Germany) to quantify vascular changes in one disk diameter peripheral of the optic disk margin between baseline and high altitude (Fig. 1A).

Statistical analysis

A longitudinal analysis between altitude and baseline measurements was performed by multivariate analysis of variance (MANOVA) for repeated measures (significance level of $P < 0.05$). Pearson's correlation coefficient assessed a possible correlation between retinal vessel diameter changes and scores of HAH and AMS as assessed by LL and AMS-C as well as clinical parameters of SpO_2 and HR the morning after arrival at high altitude.¹⁶ Data are shown in terms of intraindividual differences (value during altitude exposure – value at baseline) with 95% confidence limits at each time point.

The study was performed after volunteers were informed about the nature of the study protocol and after written informed consent in accordance with the tenets of the Declaration of Helsinki 1975 (1983 revision). It was approved by the local IRB (Ethik-Kommission der Medizinischen Fakultät/Universitätsklinikum Tübingen, IEC project number: 258/2010B01).

Results

Clinical parameters, AMS, and HAH

Incidence of AMS ($LL \geq 5$ and $AMS-C \geq 0.7$) was 56% ($n = 10/8$) in the morning after arrival at high altitude. The overall scores for AMS were $LL = 5.2 \pm 2.6$ (mean \pm SD) and $AMS-C = 1.1 \pm 0.8$; mean LL for subjects with AMS

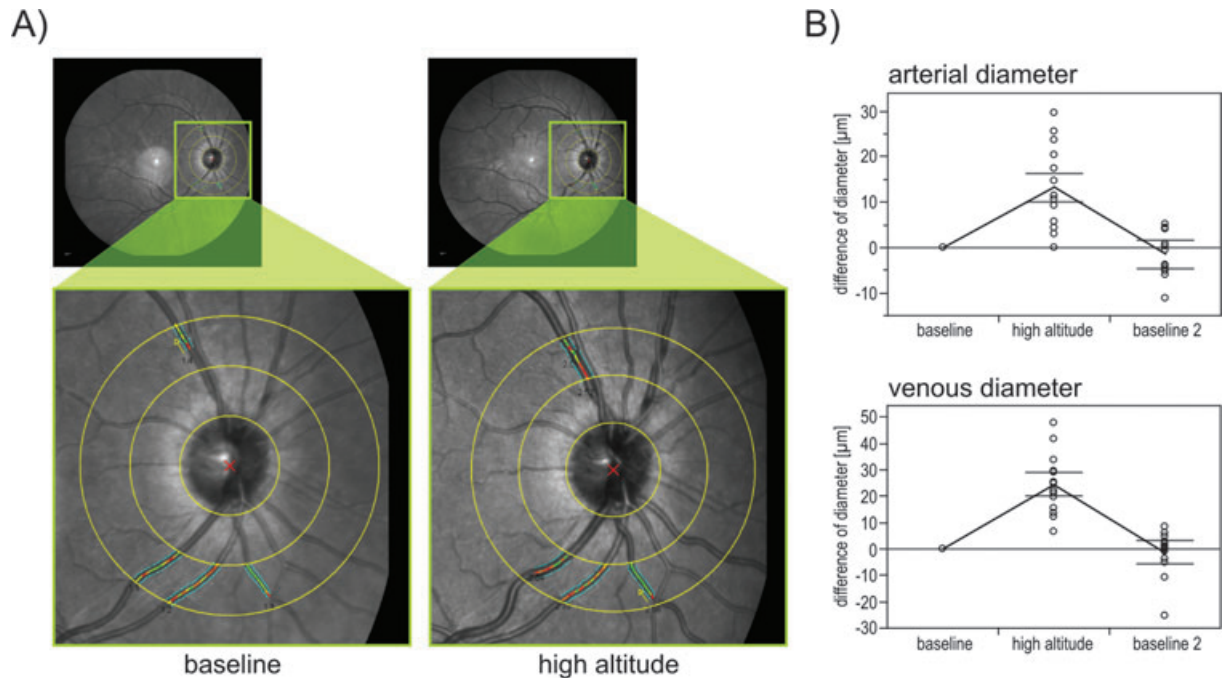


Figure 1. Vessels diameter increase at high altitude. (A) Infrared fundus images obtained from a Spectralis® (Heidelberg Engineering, Germany) at baseline (left) and at high altitude (right). VesselMap 1 analyzer (Imedos Systems, Germany) was used to quantify the change in retinal vessel diameter one disk diameter from the optic disk margin in 18 healthy subjects for arteries and veins. (B) Intraindividual differences in vessel diameter for arteries (top) and veins (bottom) in the morning after arrival at high altitude compared to baseline recordings before exposure revealed a significant increase in vessel diameter. Recordings after high-altitude exposure revealed no significant differences in vessel diameter compared to preexposure values.

(AMS+) = 6.9 ± 1.5 and without (AMS-) = 3.1 ± 1.7 and the average AMS-C for AMS+ = 1.7 ± 0.5 and AMS- = 0.4 ± 0.3 , respectively. Average headache scores in the morning after arrival at high altitude were $LL_{\text{headache}} = 1.3 \pm 0.6$ and $AMS-C_{\text{headache}} = 2.6 \pm 1.2$; mean LL_{headache} for AMS+ = 1.7 ± 0.5 and AMS- = 0.9 ± 0.4 ; and $AMS-C_{\text{headache}}$ for AMS+ = 3.3 ± 0.8 and AMS- = 1.6 ± 0.9 , respectively. Clinical parameters for peripheral oxygen saturation decreased to $SpO_2 = 73 \pm 6\%$ in all subjects in the morning after arrival at high altitude compared to baseline = $98 \pm 1\%$; mean SpO_2 for AMS+ = $72 \pm 6\%$ and AMS- = $75 \pm 6\%$ at high altitude ($P > 0.05$); HR increased to $83 \pm 10/\text{min}$ compared to baseline = $60 \pm 7/\text{min}$; mean HR for AMS+ = $85 \pm 9/\text{min}$ and AMS- = $80 \pm 10/\text{min}$ in the morning after arrival at high altitude ($P > 0.05$). All changes in clinical parameters were completely reversible after descent to low altitudes.

Retinal vessel analysis and correlation with AMS and HAH

Mean arterial (AD) and venous diameters (VD) at baseline before exposure were $AD_{\text{baseline}} = 122.7 \pm 14.8 \mu\text{m}$

and $VD_{\text{baseline}} = 148.0 \pm 15.3 \mu\text{m}$. The mean of AD_{altitude} significantly increased by 13.6 ± 19.8 to $136.4 \mu\text{m}$ and VD_{altitude} by 26.7 ± 22.1 to $171.7 \mu\text{m}$ in the morning after arrival at high altitude ($P < 0.05$; Fig. 1B). Average AD_{altitude} in AMS+ = $133.4 \pm 18.9 \mu\text{m}$ and in AMS- = $140.0 \pm 21.7 \mu\text{m}$; average VD_{altitude} in AMS+ = $168.2 \pm 17.3 \mu\text{m}$ and in AMS- = $176.2 \pm 27.6 \mu\text{m}$. All changes were completely reversible upon descent as shown at baseline 2 ($P > 0.05$; Fig. 1B). As anticipated by the values listed above, Pearson's coefficient showed no correlation between increased mean AD or VD for both LL and AMS-C scores of AMS (Fig. 2A and B) or HAH (Fig. 2C and D). In addition, changes in mean AD and VD between baseline and high altitude did not correlate with clinical parameters of SpO_2 and HR (only a nonsignificant trend between vessel diameter and SpO_2 was seen in the form of a negative correlation (AD vs. SpO_2 : $r = -0.39$, $P = 0.11$; VD vs. SpO_2 : $r = -0.26$, $P = 0.29$).

Interpretation

A significant increase in central retinal vessel diameter for both arteries and veins occurred in response to high-altitude exposure in healthy subjects. Consistent

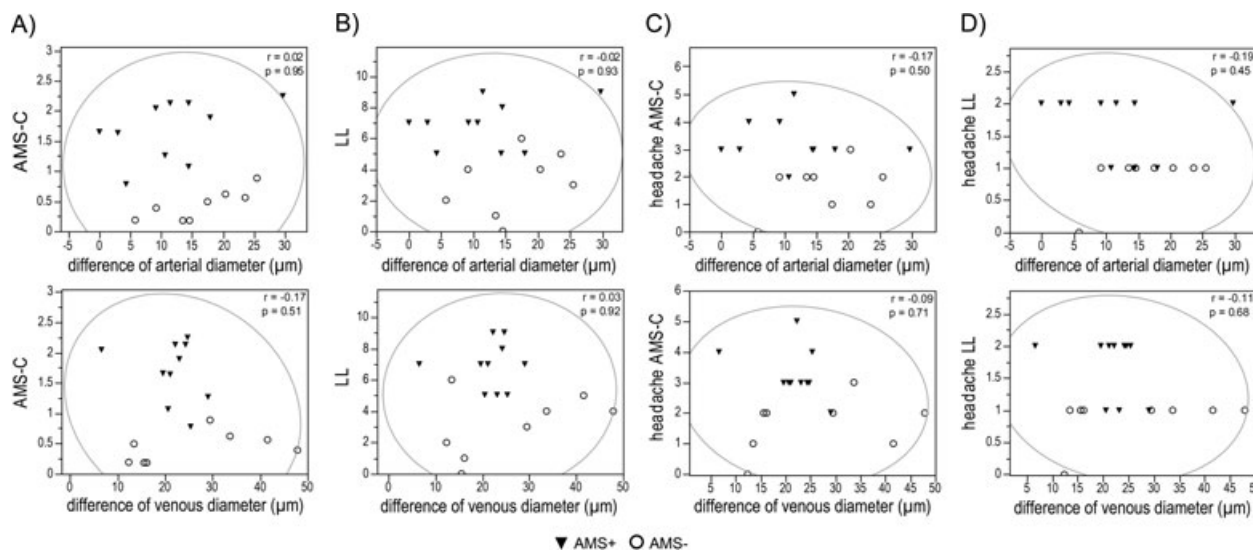


Figure 2. Missing correlation of vessel diameter changes to high-altitude headache and acute mountain sickness. Pearson's correlations between arterial (top panel) and venous (bottom panel) vessel diameters during high-altitude exposure and scores for acute mountain sickness (A and B) and its respective headache scores (C and D). None of the correlation reached statistical significance. AMS-C, acute mountain sickness cerebral score; LL, Lake Louise score; AMS+, acute mountain sick; AMS-, healthy subjects.

with previous literature this increase was greater in veins compared to arteries.¹⁷ Our findings demonstrate the increase in cerebral blood flow due to hypoxia as a physiological response to high-altitude exposure in non-acclimatized humans. However, in contrast to the recently published data by Wilson et al.,^{9,10} who reported a correlation between HAH or AMS scores during ascent and retinal vessel diameters measured 2–3 days after arrival at 5300 m, we found no such correlation when assessing retinal vessel diameters and HAH or AMS scores simultaneously at 4559 m. In our opinion, the type of exposure protocol with immediate assessment of HAH/AMS scores and respective vessel analysis is of great importance with regard to a valid outcome. In addition, the assessment of AMS and HAH remains highly subjective presenting a potential limitation of the study. Nevertheless, our findings do not support the concept of restricted cerebral venous outflow in the presence of increased inflow accounting for HAH or AMS when assuming that central retinal veins may reflect gross intracerebral venous changes because of draining into the sinus cavernosus.

Acknowledgments

This study was supported by the Wilderness Medical Society (WMS) with the Charles S. Houston Research Award; Immedos, Jena, Germany and Heidelberg Engineering, Heidelberg, Germany. The supporting sources had no role in study design; collection, analysis, and interpre-

tation of data; writing the report; and the decision to submit the report for publication.

Conflict of Interest

The Wilderness Medical Society (WMS) supported this study with the Charles S. Houston Research award to Gabriel Willmann.

References

- Roach RC, Hackett PH. Frontiers of hypoxia research: acute mountain sickness. *J Exp Biol* 2001;204:3161–3170.
- Bailey DM, Roukens R, Knauth M, et al. Free radical-mediated damage to barrier function is not associated with altered brain morphology in high-altitude headache. *J Cereb Blood Flow Metab* 2006;26:99–111.
- Bailey DM, Bartsch P, Knauth M, Baumgartner RW. Emerging concepts in acute mountain sickness and high-altitude cerebral edema: from the molecular to the morphological. *Cell Mol Life Sci* 2009;66:3583–3594.
- Wilson MH, Newman S, Imray CH. The cerebral effects of ascent to high altitudes. *Lancet Neurol* 2009;8:175–191.
- Kallenberg K, Bailey DM, Christ S, et al. Magnetic resonance imaging evidence of cytotoxic cerebral edema in acute mountain sickness. *J Cereb Blood Flow Metab* 2007;27:1064–1071.
- Brugniaux JV, Hodges AN, Hanly PJ, Poulin MJ. Cerebrovascular responses to altitude. *Respir Physiol Neurobiol* 2007;158:212–223.

7. Binder DK, Horton JC, Lawton MT, McDermott MW. Idiopathic intracranial hypertension. *Neurosurgery* 2004;54:538–551; discussion 51–2.
8. Burgess KR, Cooper J, Rice A, et al. Effect of simulated altitude during sleep on moderate-severity OSA. *Respirology (Carlton, Vic)* 2006;11:62–69.
9. Wilson MH, Imray CH, Hargens AR. The headache of high altitude and microgravity – similarities with clinical syndromes of cerebral venous hypertension. *High Alt Med Biol* 2011;12:379–386.
10. Wilson, MH, Davagnanam, I, Holland G, et al. Cerebral venous system and anatomical predisposition to high-altitude headache. *Ann Neurol* 2013;73:381–389.
11. Bartsch P, Shaw S, Franciolli M, et al. Atrial natriuretic peptide in acute mountain sickness. *J Appl Physiol* 1988;65:1929–1937.
12. Willmann G, Fischer MD, Schatz A, et al. Quantification of optic disc edema during exposure to high altitude shows no correlation to acute mountain sickness. *PLoS One* 2011;6:e27022.
13. Schneider M, Bernasch D, Weymann J, et al. Acute mountain sickness: influence of susceptibility, preexposure, and ascent rate. *Med Sci Sports Exerc* 2002; 34:1886–1891.
14. Willmann G, Fischer MD, Schatz A, et al. Retinal vessel leakage at high altitude. *JAMA* 2013;309:2210–2212.
15. Fischer MD, Willmann G, Schatz A, et al. Structural and functional changes of the human macula during acute exposure to high altitude. *PLoS One* 2012;7:e36155.
16. Roach, R, Bartsch, P, Hackett P, and Oelz O. The Lake Louise AMS scoring consensus committee. The Lake Louise acute mountain sickness scoring system. In: Sutton JR, Coates G, Huston CS, eds. *Hypoxia and Molecular Medicine*. Burlington, VT: Queen City Printers, 1993; pp. 272–274.
17. Bosch MM, Merz TM, Barthelmes D, et al. New insights into ocular blood flow at very high altitudes. *J Appl Physiol* 2009;106:454–460.