

Case report

Congenital Chagas' disease transmission in the United States: Diagnosis in adulthood



Jorge Murillo, MD FACP^{a,b}, Lina M. Bofill, MD MPH FACP, Assistant Director^{c,d,*},
Hector Bolivar, MD^e, Carlos Torres-Viera, MD MPH^{a,b}, Julio A. Urbina, PhD^f,
Daniel Benhayon, MD^g, Jaime R. Torres, MD MPHTM^{c,h}

^a Herbert Wertheim College of Medicine, Florida International University, United States

^b South Florida Infectious Disease and Tropical Medicine Center, Miami, FL, United States

^c Global Health Consortium, Florida International University, United States

^d Miller School of Medicine, University of Miami, Miami, FL, United States

^e Division of Infectious Disease, University of Miami-ACRU, Miami, FL, United States

^f Venezuelan Institute for Scientific Research, Caracas, Venezuela

^g Cardiac and Vascular Institute, Memorial Healthcare System, Hollywood, FL, United States

^h Tropical Medicine Institute, Central University of Venezuela, Caracas, Venezuela

ARTICLE INFO

Article history:

Received 23 June 2016

Received in revised form 21 July 2016

Accepted 21 July 2016

Keywords:

Chagas disease

Pregnancy

Transmission

Congenital

ABSTRACT

Two brothers with congenitally-acquired Chagas' disease (CD) diagnosed during adulthood are reported. The patients were born in the USA to a mother from Bolivia who on subsequent assessment was found to be serologically positive for *Trypanosoma cruzi*. Serologic screening of all pregnant women who migrated from countries with endemic CD is strongly recommended.

© 2016 The Authors. Published by Elsevier Ltd. This is an open access article under the CC BY-NC-ND license (<http://creativecommons.org/licenses/by-nc-nd/4.0/>).

Introduction

American trypanosomiasis, a chronic systemic parasitosis also known as Chagas' disease (CD), is caused by the protozoan kinetoplastid parasite *Trypanosoma cruzi*. CD has afflicted humanity since its earliest presence in the New World and is still the largest parasitic disease burden of the American continent. The disease is technically a zoonosis, as the natural reservoirs of the *T. cruzi* are a large variety of marsupial and placental mammals autochthonous to the American continent, the parasite being naturally transmitted among them by Reduviid (Triatominae) hematophagous insects. Human disease results from the invasion of natural ecotopes, as well as from the establishment of the vectors in human dwellings, due to the poor socioeconomic conditions of most rural human populations from Mexico to

Argentina, where the disease is endemic. Vector-borne transmission to humans initiates when the infected Triatomine bug defecates after a blood meal. The metacyclic trypomastigotes present in fecal droplets enter through the bite wound or by direct contact with mucosal membranes causing infection. The parasite can also be transmitted congenitally from infected mothers to newborns, by transfusion of contaminated blood, organ transplants and orally by ingestion of contaminated foods and drinks. These routes of transmission, together with intense international migrations in recent decades, have led to the spread of the disease to non-endemic areas, such as the U.S., Western Europe, Australia and Japan [1].

According to World Health Organization, in 2015, about 6–7 million people are estimated to be infected with *T. cruzi* worldwide and responsible for 12,000 deaths annually, mostly in 21 endemic Latin American countries [2]. Three countries, Argentina, Brazil and Mexico, concentrate more than 60% of cases, followed by Bolivia and Colombia [2]. In the US it has been estimated that 2% of approximately 17 million Latin American immigrants in 2007, were potentially infected with *T. cruzi*; of these, approximately 65,000 might have or may develop signs and symptoms of chronic CD [3]. It is estimated that between 63 and

* Corresponding author at: Global Health Consortium, 11200 SW 8th St., AHC4-224, Miami, FL 33199, United States.

E-mail addresses: linabofill@gmail.com, GHC@fiu.edu (L.M. Bofill), libofill@fiu.edu (J.R. Torres).

¹ www.GHC.fiu.edu.

315 acquire *T. cruzi* infection in the U.S every year. Based on these estimates, Chagas cardiomyopathy may affect approximately 30,000–45,000 persons in the United States [4,5]. According to the Pan American Health Organization (PAHO), congenital transmission appears to account for more than 25% of the world new cases of CD [6]. In the United States there is great concern for potential congenital transmission of *T. cruzi* from infected mothers to infants [7]. The first documented case of congenital transmission in the United States was recorded in 2012 [8]. The patient was born by cesarean section at 29 weeks of gestational age due to fetal hydrops from an asymptomatic mother with history of Chagas disease diagnosed in Bolivia (country of origin), but never treated for the infection [8].

We report two adult male siblings with presumptive congenital transmission of *T. cruzi*, born in the United States to a Bolivian seropositive mother, who had a strong epidemiological exposure to triatomine insects 28 years prior to her migration to the United States.

Case reports

Case 1: A 24-year-old Hispanic male was referred by the Florida Health Department for evaluation after a voluntary blood donation serology for CD tested positive in September 2014. The patient was born and raised in the state of Maryland (Silver Spring) and at the age of 5 moved to Miami, Florida. The patient had no exposure to potential sources of infected vectors, such as sub-standard housing (i.e. cracks on the walls and foundations of homes made of adobe/mud, thatched roofs) and/or potential animal reservoirs and infected vectors, either in the United States or during his four visits, for less than two weeks each, to La Paz city in Bolivia. An interview with the patient's mother revealed that during his childhood, the patient never visited or stayed in high endemic rural areas for CD in Bolivia. Past medical history: In May 2013, the patient was evaluated for left sided chest pain in the emergency department of one of the local hospitals. His physical examination and laboratory results were normal, including cardiac enzymes. An electrocardiogram (EKG) was obtained and reported as normal. Seven months later, an outpatient follow up evaluation showed no symptoms and his general physical examination was normal. Laboratory work showed a normal blood cell count, chemistry (BUN, creatinine, electrolytes), and liver function tests (ALT, AST). A repeated serology for *T. cruzi* antibodies was reactive. The patient never received a blood transfusion and reported a non-complicated dental surgery. In February 2015, a new EKG revealed an incomplete right bundle branch block (RBBB) and first-degree atrioventricular (AV) block (Fig. 1). A transthoracic echocardiogram was normal. *T. cruzi* serology was confirmed by two different serology tests. A *T. cruzi* enzyme immunoassay (AB EIA), was reactive: OD 2.747 (reactivity: OD > 0.330; Sens. 100%, Spec. 98.7%). An immunoblot assay AB IB (TESA), was reported positive (Sens. 97.6%, Spec. 96.6%). Both tests were performed at the Center for Disease Control and Prevention (CDC). The patient was treated orally with Nifurtimox at 10 mg/kg, daily, divided in three doses, for 90 days. The patient completed the treatment and only reported loss of appetite and weight during drug administration. Follow up laboratory work (complete blood count, basic chemistry analysis and liver function tests) was normal.

Case 2: As a result of an extended epidemiological family questioning analysis, the patient's only sibling was contacted for evaluation. The patient is a 26 year-old male, who was diagnosed to have a positive serology for *T. cruzi* in 2008 post a voluntary blood donation, and confirmed by the CDC. The patient denied previous blood transfusions and never traveled to Bolivia or any other endemic destinations in the Americas. In 2012, a new evaluation

and EKG were normal. Treatment with Nifurtimox, 10 mg/kg orally daily, divided in three doses for 90 days as per CDC protocol, was provided. The patient tolerated and completed treatment. His primary care physician has followed him on a regular basis, and to date the patient has remained without evidence of active clinical disease.

The patients' mother was born and resided in the city of Concepción, Bolivia, until she was 18 years of age. She lived in a house described with mud walls and thatch. She had knowledge of the existence of the triatomine insects locally called "vinchuca". She moved to Silver Spring, Maryland in 1982 where she had two uneventful pregnancies and deliveries in 1988 and 1990, moving to Miami five years later. While in the United States, the mother never lived in sub-standard housing, rural or sub-urban areas, had contact with potential animal reservoirs, or received blood transfusions. She had been a blood donor prior to the Red-Cross protocol including Chagas' disease screening since 2007 [5]. Considering that the two sons were diagnosed with CD without a clear known source of infection, she was tested at the blood bank as per her sons' request. The initial blood bank serology was positive (March 2011) and most recently confirmed by the CDC in April 2015. Treatment was offered to the patient, but she never returned for follow up.

Discussion

The present report represents the second instance of congenital transmission in the United States. Congenital transmission varies among study population and parasite load [9]. The capacity of parasites to invade placental cells, as well as its virulence and level of parasitemia in pregnant women, is critical in the maternal-fetal transmission. Parasitemia increases during the 2nd and 3rd trimesters of pregnancy and high maternal parasitemia are associated with congenital transmission. Indeed, transmission occurs in nearly 100% of pregnant women with reactivated infections, in about 50% of acute infection during pregnancy, and in roughly 5% of chronic infection in endemic countries [14,15]. Autochthonous infections have been reported in the United States. The CDC has confirmed twenty-eight cases have been locally transmitted from 1955 to 2015 [10]. Vector human transmission in the United States is rare and is likely related to a lower vector transmission efficacy due to the delayed defecation of the triatomine insects and better housing conditions [11,12]. Although possible, vectorial transmission in our cases is extremely unlikely in view to the fact that the patients never lived in sub-standard conditions in the United States or were exposed to vectors and small animal reservoirs while traveling (La Paz city, Bolivia, case 1). Patients were born to an infected mother who was never screened for CD during her two pregnancies, despite a strong epidemiological history of exposure to *T. cruzi* in Bolivia. The epidemiology of CD is changing due to immigration from endemic areas of Latin America. Around 300,000 persons infected with *T. cruzi* are estimated to live in the United States [6]. The National Notifiable Disease Surveillance System (NNDSS) of the United States does not require the mandatory notification of CD to public health authorities, making it difficult to accurately evaluate local transmission. Few states (Massachusetts, Arizona, Texas and Tennessee) consider CD a notifiable disease. Public entities at the Federal and State level need to support the expansion of the surveillance programs nationwide. Awareness of CD among physicians in the United States – in particular primary care physicians, pediatricians, obstetricians and cardiologists – is fairly low [6]. The limited knowledge of congenital *T. cruzi* transmission is reflected by the lack of screening of pregnant women at risk, as evidenced in the current report.

The identification of *T. cruzi* by xenodiagnosis CD and can be routinely used to accurately diagnose the disease in the acute phase. However, during the indeterminate or chronic phase, diagnosis is made by serological methods.

Once a positive diagnosis has been confirmed, there are only two drugs available for treatment (nifurtimox and benznidazole).

Nifurtimox (Lampit[®], Bayer; a 2-nitrofurane) is the only anti-*T. cruzi* agent available in the US, through CDC. The drug, as well as benznidazole (LAFEPE; a 5-nitroimidazole available in Latin America), is active in acute infections (80–95%), and efficacy varies among the endemic areas probably due to differences in the in vivo susceptibility of the circulating parasite populations.

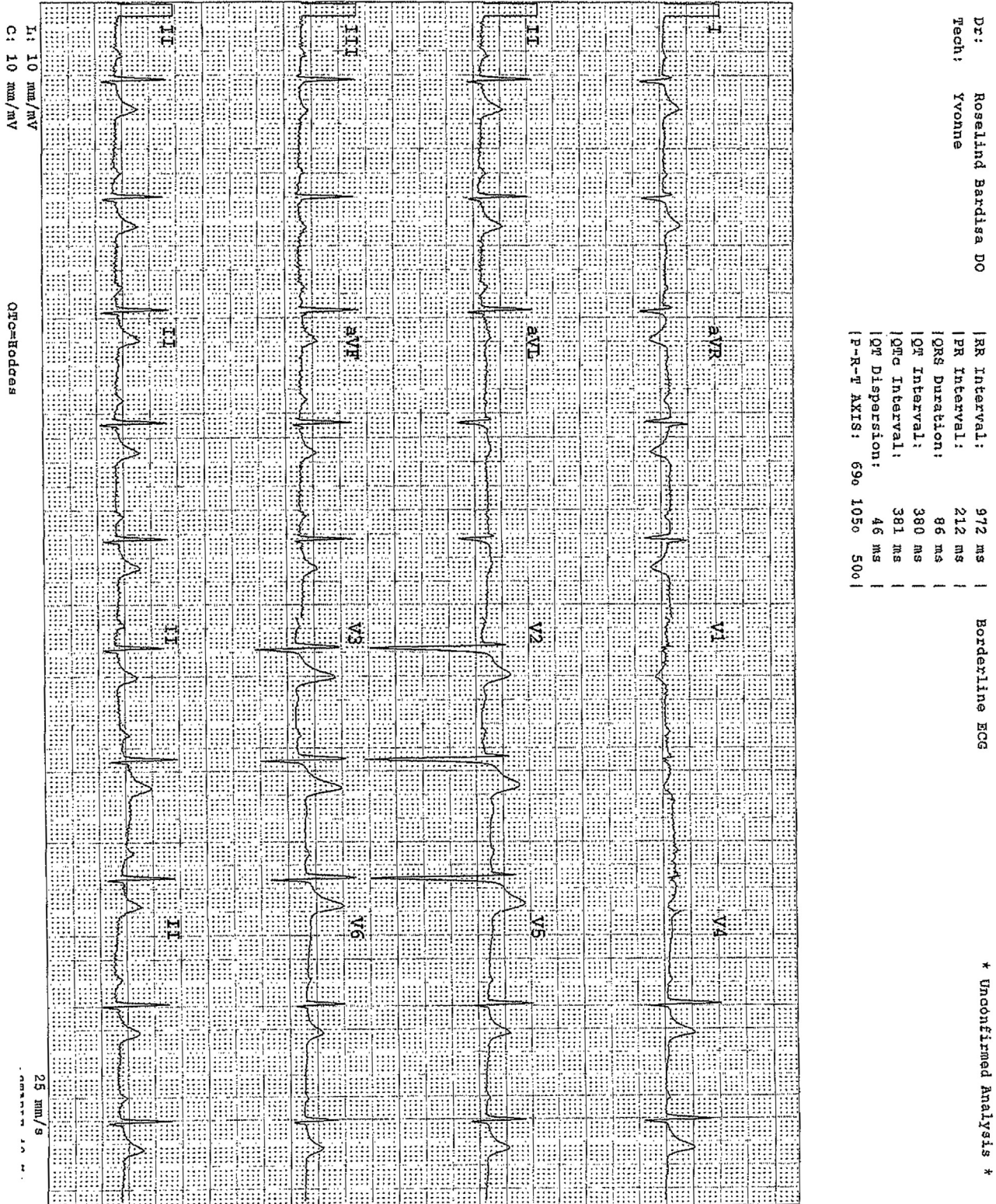


Fig. 1. Incomplete right bundle branch block (RBBB) and first-degree atrioventricular (AV) block.

Congenital CD response to treatment is close to a 100% cure and generally well tolerated when treatment is administered within the first year of life [13–15]. The efficacy of both drugs in the prevalent chronic phase of the disease is significantly lower and more variable, depending on the duration of the infection [16]. Two recent studies that evaluated the efficacy of nifurtimox in chronic patients using quantitative *T. cruzi* PCR and a novel proteomic biomarker found that in 77.8% and 43.3% of treated patients the circulating parasite burden dropped below the limit of detection of the methods after 13 and 36 months, respectively [17,18]. Adverse effects are frequent, dose-related and reversible: they include anorexia, nausea, vomiting, gastric pain, insomnia, headache, vertigo, excitability, myalgia, arthralgia and convulsions; peripheral polyneuritis can occur which may necessitate discontinuation of treatment [19].

The diagnosis and treatment of CD needs to be emphasized and should be included in routine laboratory tests of pregnancy among immigrant women from endemic countries. All infants with congenital disease should be treated during the first twelve months due to the high cure rates and treatment tolerance.

References

- [1] Montgomery SP, Starr MC, Cantey PT, Edwards MS, Meymandi SK. Neglected parasitic infections in the United States. *Am J Trop Med Hyg* 2014;90:814–8.
- [2] Chagas Disease in Latin America: an epidemiological update based on 2010 estimates. *Wkly Epidemiol Rec* 2015;90(6):33–43.
- [3] Schmunis GA, Yadon ZE. Chagas Disease: a Latin American health problem becoming a world health problem. *Acta Trop* 2010;115:14–21.
- [4] Bern CM, Montgomery SP. An estimate of the burden of Chagas disease in the United States. *Clin Infect Dis* 2009;49:e52–54.
- [5] Center for Disease Control and Prevention. Congenital transmission of chagas disease-Virginia. *MMWR Morb Mortal Wkly Rep* 2010;61:477–9.
- [6] Hotez PJ, Dumonteil E, Betancourt Cravioto M, Borrazzi ME, Rapia-Conyer R, Meymandi S, Karunakara U, Ribeiro I, Cohen RM, et al. An unfolding tragedy of Chagas Disease in North America. *PLoS Negl Trop Dis* 2013;7:e2300.
- [7] Buekens P, Almendares O, Carlier Y, Dumonteil E, Eerhard M, Gamboa-Leon R, James M, Padilla N, Wesson D, Xiong X, et al. Mother-to-child-transmission of Chagas' disease in North America: why don't we do more? *Matern Child Health J* 2008;12:283–6.
- [8] Center for disease control and prevention congenital transmission of chagas disease – Virginia. *MMWR* 2012;61:477–9.
- [9] Rendell VR, Gilman RH, Valencia E, Galdos-Cardenas G, Verastegui M, Sanchez L, et al. Trypanosoma cruzi-infected pregnant women without vector exposure have higher parasitemia levels: implications for congenital transmission risk. *PLoS One* 2015;10(3):e0119527. doi:<http://dx.doi.org/10.1371/journal.pone.0119527> (accessed 28.05.15).
- [10] Kuehn B. Putting chagas disease under US radar screen. *JAMA* 2015;313:1195–7.
- [11] Dorn PL, Perniciaro L, Yabsley MJ, Roelli DM, Balsamo G, Diaz J, Wesson D, et al. Autochthonous transmission of Trypanosoma cruzi, Louisiana. *Emerg Inf Dis* 2007;13:605–7.
- [12] Bern C, Kjos S, Yabsley M, Montgomery S. Trypanosoma cruzi and Chagas' disease in the United States. *Clin Microbiol Rev* 2011;24:655–81.
- [13] Bern C, Montgomery MD, Herwaldt P, Rassi BL, Jr A, Marin-Neto JA, Dantas RO, Maquire JH, Acquatella H, Morillo C, Kirchoff LV, Gilman RH, Reyes PA, Salvatella R, Moore AC, et al. Evaluation and treatment of Chagas Disease in the United States. A systematic review. *JAMA* 2007;298(18):2171–81.
- [14] Cevallos AM, Hernández R. Chagas Disease: pregnancy and congenital transmission. *BioMed Res Int* 2014. doi:<http://dx.doi.org/10.1155/14/401864> article ID 401864.
- [15] Torrico F, Alonso-Vega C, Suarez E, Rodriguez P, Torrico MC, Dramaix M, Truyens C, Carlier Y, et al. Maternal trypanosoma cruzi infection, pregnancy outcome, morbidity, and mortality of congenitally infected and non- infected newborns in Bolivia. *Am J Trop Med Hyg* 2004;70(2):201–2.
- [16] Urbina JA. Recent clinical trials for the etiological treatment of chronic chagas disease: advances, challenges and perspectives. *J Eukaryot Microbiol* 2015;62(1):149–56.
- [17] Muñoz C, Zulantay I, Apt W, Ortiz S, Schijman AG, Bisio M, Ferrada V, Herrera C, Martínez G, Muñoz AS, et al. Evaluation of nifurtimox treatment of chronic Chagas disease by means of several parasitological methods. *Antimicrob Agents Chemother* 2013;57(9):4518–23.
- [18] Santamaria C, Chatelain E, Jackson Y, Ward BJ, Chappuis F, Ndao M. Serum biomarkers predictive of cure in Chagas disease patients after nifurtimox treatment. *BMC Infect Dis* 2014;14(1):302.
- [19] <http://apps.who.int/medicinedocs/en/d/Jh2922e/2.11.2.html>.