

Case report: Transcatheter valve repair with Cardioband: a new treatment option for secondary tricuspid regurgitation in cardiac transplant patients

Monique Wösten *, Stephan Baldus, and Roman Pfister 

Department of Cardiology, Heart Center, University of Cologne, Kerpener Str. 62, 50937, Cologne, Germany

Received 6 April 2020; first decision 30 April 2020; accepted 5 November 2020; online publish-ahead-of-print 13 December 2020

Background

Tricuspid regurgitation (TR) is the most frequent valvular complication after cardiac transplantation. As in native hearts, the role of surgical therapy particularly in secondary TR is unclear due to high procedural risk and unsatisfying results. Currently, percutaneous techniques are under development for TR repair with less procedural risk and promising preliminary results.

Case summary

We present a 67-year-old man who underwent heart transplantation (biatrial anastomosis) because of ischaemic heart disease 15 years ago and aortic valve replacement in 2010. Because of progressive severe dyspnoea (New York Heart Association Class III) in 2018 and signs of right heart failure with ascites he underwent transthoracic echocardiography which showed normal graft function, but massive TR of functional aetiology. The heart team decision was an interventional approach using the Cardioband System (Edwards Lifesciences) to treat TR based on the high risk associated with a third cardiac surgery and impaired right ventricular function. The procedure was performed in general anaesthesia with transoesophageal echocardiography and fluoroscopic guidance. Tricuspid regurgitation improved from massive to mild with a mean pressure gradient of 2.9 mmHg.

Discussion

This is the first case report of Cardioband implantation in tricuspid position in a heart transplant patient with the good technical and clinical result, suggesting that this technique might offer a treatment option to highly selected post-transplant patients with secondary severe TR and high surgical risk.

Keywords

Transcatheter valve repair • Cardioband • Secondary tricuspid regurgitation • Valvular heart disease • Heart failure • Case report

Learning points

- Tricuspid regurgitation is a frequent problem in transplant hearts with an unmet need for treatment given the high surgical risk of these patients.
- Percutaneous annuloplasty with Cardioband implantation in tricuspid position is feasible in post-transplant patients with secondary tricuspid regurgitation despite abnormal anatomy resulting from atrial anastomosis.
- The Cardioband system might offer a treatment option for tricuspid regurgitation to highly selected post-transplant patients given the low risk of the procedure.

* Corresponding author. Tel: (+49) 22147832401, Email: monique.woesten@uk-koeln.de

Handling Editor: Brown Richard Alexander

Peer-reviewers: Rudzinski Piotr, Nikodem and Sinning Christoph

Compliance Editor: Cassar Mark Philip

Supplementary Material Editor: Patel Peysh A

© The Author(s) 2020. Published by Oxford University Press on behalf of the European Society of Cardiology.

This is an Open Access article distributed under the terms of the Creative Commons Attribution Non-Commercial License (<http://creativecommons.org/licenses/by-nc/4.0/>), which permits non-commercial re-use, distribution, and reproduction in any medium, provided the original work is properly cited. For commercial re-use, please contact journals.permissions@oup.com

Introduction

Tricuspid regurgitation (TR) is the most frequent valvular complication in the donor allograft after cardiac transplantation with reported incidences of up to 84%.¹ Approximately 34% of TR in post-transplant patients is moderate to severe and is associated with symptoms of right heart failure, impaired quality of life, and increased mortality.² This is of increasing relevance in the context of excellent long-term survival in contemporary heart transplant patients. As in native hearts, the role of surgical therapy particularly in secondary TR is unclear due to high procedural risk, and results of surgical tricuspid valve repair are frequently unsatisfying.³

Timeline

Heart transplantation in 2003
 Aortic valve replacement in 2010
 Progressive dyspnoea New York Heart Association III with diagnosis of severe tricuspid regurgitation in 2018
 Cardioband implantation in tricuspid position in 2018
 Clinical follow-up after 3 and 6 months

Case presentation

Here, we present a 67-year-old man who underwent heart transplantation (biatrial anastomosis) because of ischaemic heart disease in 2003. He underwent aortic valve replacement because of severe aortic stenosis in 2010. The patient presented with progressive severe dyspnoea [New York Heart Association (NYHA) Class III] in 2018 and signs of right heart failure with ascites. Transthoracic echocardiography showed normal graft and aortic prosthesis function,⁴ but massive tricuspid regurgitation of functional aetiology with dilated right ventricle (56 mm basal), right atrium (53.5 cm²), and impaired right ventricular function (tricuspid annular plane systolic excursion 14 mm) (Supplementary material online, Videos S1 and S2, Figure 1 A and B). Additional medical history comprised chronic kidney disease (stage G3b) and persistent atrial fibrillation. Liver function was slightly impaired with decreased albumin (34 g/L) and cholinesterase (4.3 kU/L), mild increase in bilirubin (2 mg/dL), and normal alanine aminotransferase and aspartate aminotransferase.

The heart team decision was an interventional approach using the Cardioband System (Cardioband, Edwards Lifesciences) to treat TR based on the high risk associated with a third cardiac surgery and impaired right ventricular function. Coronary angiography excluded relevant allograft vasculopathy. Cardiac computed tomography was performed for the planning of the procedure which estimated a 112.8 mm device length according to annulus circumference and showed acceptable proximity of the right coronary artery (Figure 1C and D). The procedure was performed in general anaesthesia with

transoesophageal echocardiography (TOE) guidance. Starting anterior close to the aorta the Cardioband was implanted clockwise along the tricuspid annulus using 16 anchors (device size E) (Figure 1E). The aortic valve prosthesis moderately impaired echocardiographic visualization particularly around the inferior segments in this case. Finally, the Cardioband was successively cinched under TOE control to the maximum stage 5.0 (Figure 1F and G). Tricuspid regurgitation improved from massive [vena contracta (VC) 16 mm, effective regurgitation orifice area 0.79 cm², mean pressure gradient 1.6 mmHg, coaptation gap 7 mm] to mild (VC 3 mm, no coaptation gap) with a mean pressure gradient of 2.9 mmHg and a reduction in annular diameter from 41 mm to 36 mm in the four-chamber view (Supplementary material online, Videos S3 and S4, Figure 1H and I). The patient improved to NYHA Class II at 3 months follow-up visit with a decrease of NTproBNP levels from 6361 ng/L to 3291 ng/L after 6 months.

Discussion

Several devices are currently evaluated for percutaneous tricuspid valve repair, with the most common technique being the edge-to-edge repair using the MitraClip (in tricuspid position) or the recently CE approved TriClip (both Abbott Vascular). Given the advanced right ventricular dilatation with a coaptation gap of 7 mm, we decided for an annuloplasty based technique in this patient. The Cardioband system is a catheter-delivered annular reduction system that mimics the surgical annuloplasty approach. So far, it is the only CE-approved annuloplasty device for the tricuspid valve based on results of the TRI-REPAIR-trial on 30 patients with functional TR.⁵ A major advantage in comparison to surgical therapy is the low procedural risk. The most common procedure associated with adverse events observed in about 10% of patients of the TRI-REPAIR trial were bleedings and coronary complications due to proximity to the right coronary artery. A further advantage is the reversible and successive annular reduction process, which allows adaptation to optimize results of TR under beating heart conditions. The latter might be of particular interest in transplant hearts where distorted anatomy due to the anastomosis is assumed to contribute to TR pathology. Pre-procedural assessment of right atrial dimension and tricuspid valve morphology is crucial in the context of a transplant heart and can be derived from routinely performed pre-procedural transthoracic and transoesophageal echocardiography and cardiac computer tomography. Extremely large atria in patients with biatrial anastomosis might preclude adequate manoeuvring of the device but was no problem in this case. Organic damage of the tricuspid valve resulting from for instance prior biopsies must be excluded.

This is the first report of Cardioband implantation in tricuspid position in a heart transplant patient with the good technical and clinical result, suggesting that this technique might offer a treatment option to highly selected post-transplant patients with secondary TR and high surgical risk. Other reasons for heart failure, particularly cardiac allograft vasculopathy and rejection must be considered during the evaluation process.

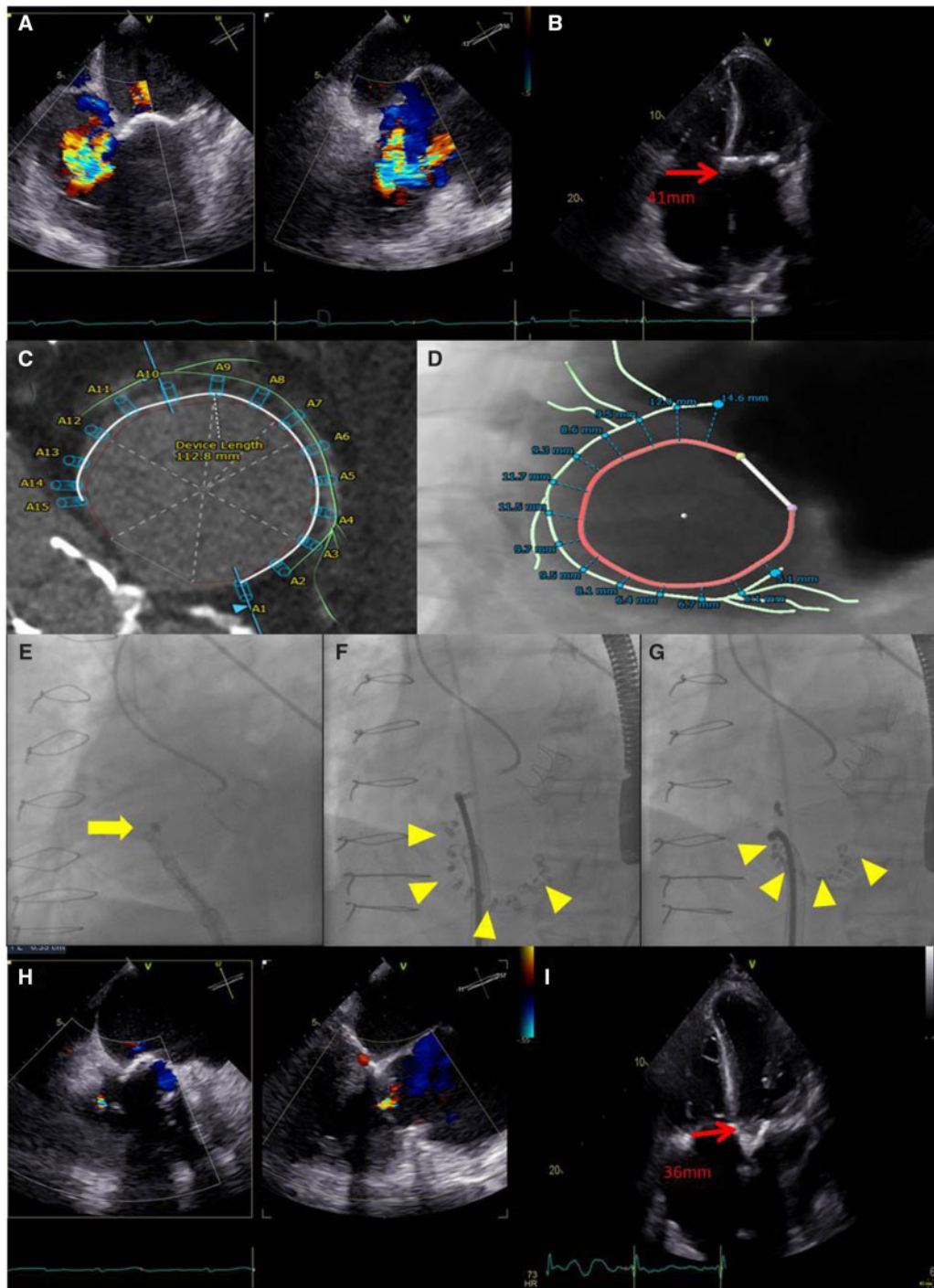


Figure 1 (A) Colour Doppler of transoesophageal echocardiography X-plane view shows severe tricuspid regurgitation before Cardioband implantation. (B) Transthoracic echocardiography four-chamber view shows tricuspid annular dilatation (41 mm) before Cardioband implantation. (C) Computed tomography shows the tricuspid annulus circumference with the device length (112.8 mm) and schematic anchors. (D) Computed tomography shows the tricuspid annulus circumference (red line) and the right coronary artery (yellow line) with the measured distance in between (blue measurements). (E) Fluoroscopic image, yellow arrowhead indicates the first implanted screw anchor next to the aortic valve prosthesis. A right coronary guide catheter and guidewire in the right coronary artery are in position for orientation during the procedure. (F) Fluoroscopic image, yellow arrowheads indicate the implanted screw anchors of Cardioband system before cinching. (G) Fluoroscopic image, yellow arrowheads indicate the implanted screw anchors of Cardioband system after cinching. (H) Colour Doppler of transoesophageal echocardiography X-plane view shows mild tricuspid regurgitation after Cardioband implantation. (I) Transthoracic echocardiography four-chamber view shows shortening of the tricuspid annulus (36 mm) after Cardioband implantation.

Lead author biography



Dr. Monique Wösten, MD, Second State Examination in Medicine, University of Hamburg at December 2013. Intern Cardiology at Heart Center, University of Cologne from February 2014 to March 2020. Specialist of Internal Medicine and Cardiology at Heart Center, University of Cologne since April 2020.

Supplementary material

[Supplementary material](#) is available at *European Heart Journal - Case Reports* online.

Slide sets: A fully edited slide set detailing this case and suitable for local presentation is available online as [Supplementary data](#).

Consent: Informed consent has not been obtained for publication of this case report. The authors have followed procedures as per their local ethics committee. Every effort has been made to anonymise the case. This situation has been discussed with the editors.

Conflict of interest: S.B.: Lecture fees, travel grants, and research support from Edwards Lifesciences. R.P.: Fees for presentation and consultancy from Edwards Lifesciences. M.W. declares no conflict of interest.

Funding: None declared.

References

1. Wong RC, Abrahams Z, Hanna M, Pangrace J, Gonzalez-Stawinski G, Starling R et al. Tricuspid regurgitation after cardiac transplantation: an old problem revisited. *J Heart Lung Transplant* 2008;**27**:247–252.
2. Chan MC, Giannetti N, Kato T, Kornbluth M, Oyer P, Valentine HA et al. Severe tricuspid regurgitation after heart transplantation. *J Heart Lung Transplant* 2001;**20**:709–717.
3. Kwon MH, Shemin RJ. Tricuspid valve regurgitation after heart transplantation. *Ann Cardiothorac Surg* 2017;**6**:270–274.
4. Badano LP, Miglioranza MH, Edvardsen T, Colafranceschi AS, Muraru D, Bacal F, et al.; Document reviewers. European Association of Cardiovascular Imaging/ Cardiovascular Imaging Department of the Brazilian Society of Cardiology recommendations for the use of cardiac imaging to assess and follow patients after heart transplantation. *Eur Heart J Cardiovasc Imaging* 2015;**16**:919–948.
5. Nickenig G, Weber M, Schueler R, Hausleiter J, Nábauer M, von Bardeleben RS et al. 6-Month outcomes of tricuspid valve reconstruction for patients with severe tricuspid regurgitation. *J Am Coll Cardiol* 2019;**73**:1905–1915.