

# Case planning and execution of inframalleolar bypass for chronic limb-threatening ischemia

Clara M. Gomez-Sanchez, MD, and Michael S. Conte, MD, *San Francisco, CA*

## ABSTRACT

Chronic limb-threatening ischemia is challenging to treat because of the complex patient population, heterogeneity of limb presentations, and complicated arterial pathology. To meet this challenge, vascular surgeons need a broad range of skills to appropriately tailor interventions to each patient's specific needs. One tool in the armamentarium for patients with extensive arterial occlusive disease below the knee is an inframalleolar bypass. However, these procedures require a systematic approach to surgical planning and a high degree of technical competence. We describe our approach to inframalleolar bypass for limb preservation in suitable patients with advanced tibial artery disease. (*J Vasc Surg Cases Innov Tech* 2023;9:1-7.)

**Keywords:** Peripheral arterial occlusive disease; Chronic limb-threatening ischemia; Amputation; Surgical

The incidence of peripheral arterial disease continues to increase around the world, and its end-stage disease, chronic-limb threatening ischemia (CLTI), affects an estimated 2 million people per year in the United States.<sup>1</sup> The patient population tends to be complex, with high rates of diabetes and kidney disease and a considerable burden of cardiovascular disease<sup>2</sup>; successful limb salvage requires a comprehensive approach to diagnosis, medical management, surgical intervention, and long-term surveillance. Occlusive disease affecting below-knee arteries is common in CLTI, particularly in those with diabetes. Endovascular surgery techniques have rapidly advanced the field of vascular surgery and expanded treatment options in patients with peripheral arterial disease. However, outcomes for percutaneous angioplasty and atherectomy in infrapopliteal vessels have been overall disappointing in terms of durability and clinical outcomes,<sup>3,4</sup> and no drug-eluting devices have been approved for infrapopliteal use by the US Food and Drug Administration to date. In contrast, several large series have demonstrated excellent rates of limb salvage in CLTI patients with extensive tibial disease who underwent bypass to inframalleolar targets.<sup>5-7</sup> Given the increasing global prevalence of diabetes and renal

disease, distal bypass to inframalleolar targets remains an essential skill set for vascular surgeons today.

## HOW I DO IT

**Preoperative assessment and decision-making.** The decision to proceed with a specific operation begins with an assessment of three factors: patient, problem, and anatomy. A comprehensive understanding of the patient's comorbidities and functional status is essential to determine the likelihood of success and the risks and potential benefits of intervention. This evaluation should provide a full understanding of the cardiovascular and pulmonary risk factors, with particular attention to ambulatory and functional status. Estimation of operative risk and long-term survival are central to informed decision making, and predictive tools such as the Vascular Quality Initiative CLTI risk calculator are valuable.<sup>8</sup>

The indications for intervention for severe infrapopliteal arterial disease should be limited to rest pain or tissue loss. In this context, the limb status should be formally described using the SVS Threatened Limb Classification system (wound, ischemia, and foot infection),<sup>9</sup> which integrates wound, ischemia, and infection severity into score to stratify the risk of limb loss and assess the proposed benefit of revascularization. A patient with a low wound, ischemia, and foot infection stage may be one in whom wound care should be pursued first or endovascular treatment favored if anatomically appropriate; however, those with extensive ischemic tissue loss and anatomically complex disease often warrant an open approach to revascularization. The distribution of tissue loss is also important; a heel wound, for example, is a high-risk problem because there are few functional limb salvage options if surgical resection is required.

High-fidelity imaging of the arterial anatomy is fundamentally important to operative planning. Cross-sectional imaging generally provides inadequate evaluation of the small vessels below the knee and especially below the

---

From the Division of Vascular and Endovascular Surgery, Department of Surgery, University of California San Francisco.

Author conflict of interest: M.C. is an Abbott advisory board member. No other potential conflicts of interest are reported.

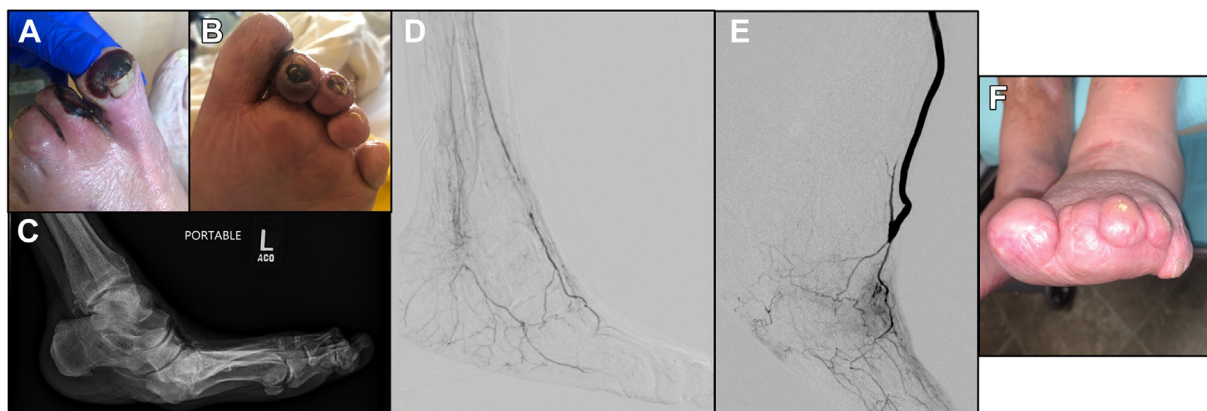
Correspondence: Clara M. Gomez-Sanchez, MD, Division of Vascular and Endovascular Surgery, University of California San Francisco, 400 Parnassus Ave, A-581, San Francisco, CA 94143 (e-mail: [clara.gomez-sanchez@ucsf.edu](mailto:clara.gomez-sanchez@ucsf.edu)).

The editors and reviewers of this article have no relevant financial relationships to disclose per the Journal policy that requires reviewers to decline review of any manuscript for which they may have a conflict of interest.

2468-4287

© 2023 The Author(s). Published by Elsevier Inc. on behalf of Society for Vascular Surgery. This is an open access article under the CC BY-NC-ND license (<http://creativecommons.org/licenses/by-nc-nd/4.0/>).

<https://doi.org/10.1016/j.jvscit.2023.101116>



**Fig 1.** (A, B) Preoperative photos demonstrating rapidly progressive digit gangrene on the hallux and second digit with an ulcer at the tip of the second digit. (C) Lateral radiograph of the foot demonstrating a severe deformity as well as severely calcified dorsal and plantar vessels. (D) Planning angiogram demonstrated diffuse disease in the tibial vessels with abrupt occlusion of the anterior tibial at the ankle. The posterior tibial is not visualized, but there is a posterior branch from the peroneal extending to the ankle. The common plantar is occluded and only one plantar branch is visible. (E) Completion angiogram after popliteal to dorsalis pedis bypass. The outflow target overlies the branch point of the lateral tarsal branch. There is a gentle curve proximally as the bypass crosses the tibia. (F) One year after bypass finds complete healing of the partial hallux and second through fourth toe amputations. Case included with permission from patient.

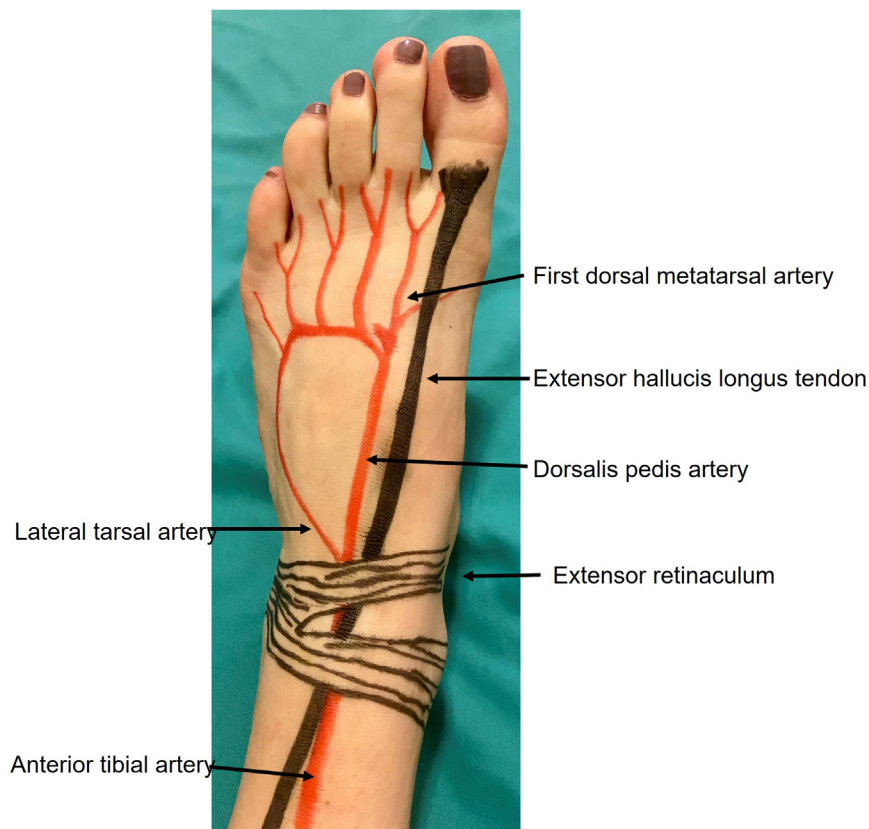
ankle, but is useful in evaluating for proximal disease. Duplex ultrasound examination is a critical tool for initial evaluation and surveillance, but has technical limitations in tibial and pedal vessels and may be inadequate to determine the ideal position for a bypass target confidently. Our practice is to perform digital subtraction angiography on all patients considered for bypass to below-knee vessels to adequately assess inflow and outflow targets. Inflow should come from a healthy segment of artery as close to the distal target as possible without any untreated or high-risk disease proximal to it. It is reasonable to use an inflow target that is distal to a patent iliac stent, femoral endarterectomy, or a short segment of a successfully treated superficial femoral artery (SFA). However, positioning a bypass distal to an untreated hemodynamically significant lesion or a treated long-segment chronic total occlusion of the SFA or popliteal portends an unacceptably high risk of downstream failure. The distal target should be examined carefully using both anteroposterior and lateral projections on an angiographic study that captures runoff to the toes. If a patient has multiple pedal targets available, the healthiest vessel with the best collateralization should be selected. The extent of calcification on angiography or even plain film radiography can also help to predict how pliable a segment of artery will be to suturing. Fig 1, A-C, demonstrates a case of a patient with rapidly progressing gangrene with severe arterial calcification in the foot on radiograph. Permission for publication was obtained from all patients whose cases are shown in this article.

The success of any bypass is predicated on having appropriate inflow and outflow, but adequate autologous conduit is an especially critical factor in bypasses

to tibial and inframalleolar targets. We prefer greater saphenous vein of  $\geq 3$  mm, but find that many marginal veins dilate under anesthesia, so we often attempt to use a vein  $>2.5$  mm on preoperative vein mapping. Many studies have identified a single-segment greater saphenous vein as the ideal lower extremity bypass conduit,<sup>5,10,11</sup> but alternative options with acceptable outcomes include spliced leg vein, small saphenous, and arm vein.<sup>12-14</sup> The stiffness and large caliber of a prosthetic graft is poorly suited to the small size of inframalleolar vessels,<sup>11</sup> and cryopreserved cadaveric vein should be used only with the understanding that the mid-term durability is expected to be poor.<sup>15</sup> A patient with severe rest pain and no adequate autologous conduit is unlikely to receive a lasting benefit from an inframalleolar bypass with a nonautogenous conduit and may be better suited to a primary amputation if the pain is intolerable and no endovascular option is available.

**Conduct of operation.** We find it useful to repeat an intraoperative duplex ultrasound examination of the conduit to confirm the quality of the selected vein and mark the skin for incisional planning. The patient should have the entire affected lower extremity prepped circumferentially into the field, as well as any additional limbs if a conduit is needed from another site. We prefer to have a sterile tourniquet on the field for use during the distal anastomosis, and, if the inflow is below the knee, it can be useful for the proximal as well. A padded bump is used to support the leg in external rotation during dissections.

The greatest unknowns in distal bypass surgery are conduit and target artery quality; thus, we begin the



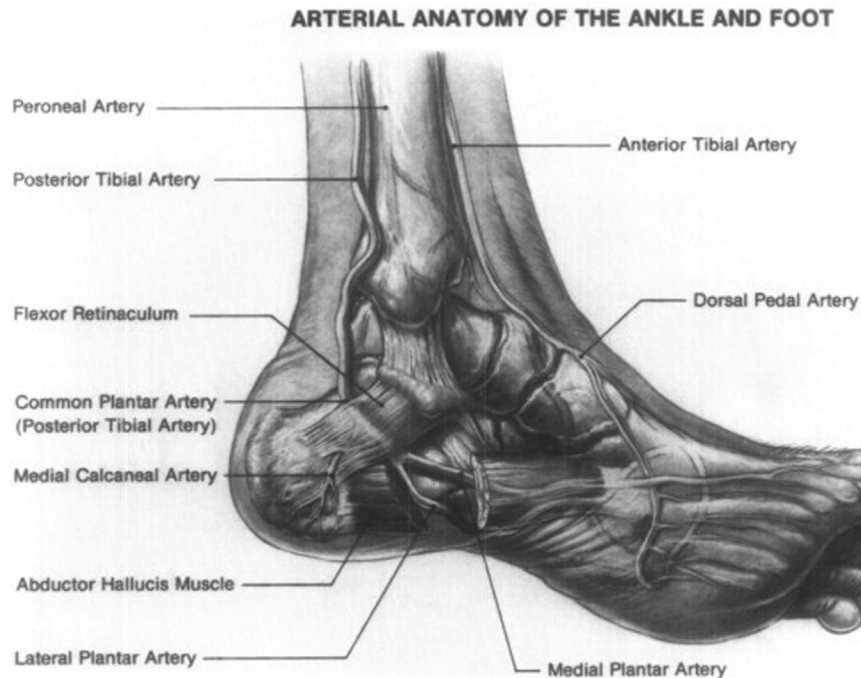
**Fig 2.** Anatomical rendering of the dorsum of the foot with the course of the dorsalis pedis artery and its terminal branches.

operation by exposing the vein and outflow targets to confirm the preoperative plan. If there is unexpected conduit pathology or inadequate diameter, alternate sources of autogenous vein (eg, contralateral leg or arm) are considered. We use intraoperative ultrasound examination to identify and evaluate the planned pedal target. Color Doppler or spectral waveform imaging may be used to confirm that the identified segment of artery is patent consistent with the prior angiography. Determining the adequate target artery for inframalleolar bypass requires experienced judgment and ideally is a vessel with  $>2$  mm in luminal diameter with minimal calcifications. Diffuse, thick circumferential calcifications without gaps may be inoperable, but milder calcification is common and not prohibitive. Fig 1, D, E, demonstrates successful popliteal to dorsalis pedis bypass despite diffuse calcification, with the healed foot seen at 1 year in Fig 1, F. The inflow artery is then exposed and the length of vein necessary for bypass is determined. Inflow from the common femoral artery, SFA, or popliteal artery is isolated in standard fashion, with care during the initial incision to avoid inadvertent injury to the saphenous vein.

The terminus of the anterior tibial artery is the dorsalis pedis, which lies just lateral to the extensor hallucis

longus tendon in the proximal foot and can be identified entering the foot just deep to the edge of the extensor retinaculum (Fig 2). We make a 3-cm longitudinal incision overlying the dorsalis pedis and perform a relatively limited dissection of the vessel if a sterile tourniquet can be used for vascular control on the calf. More distally, the lateral tarsal artery branches from the dorsalis pedis laterally toward the fifth metatarsal head and can be an adequate target if the dorsalis pedis is unacceptable. Lateral retraction or even division of the first and second tendons of the extensor digitorum longus and extensor hallucis brevis muscles may be necessary to achieve distal exposure of the lateral tarsal artery.

The terminus of the posterior tibial artery is the common plantar artery that bifurcates into the lateral and medial plantar arteries as it passes deep to the flexor retinaculum (Fig 3). With the leg in an externally rotated position, an incision is made in the medial foot just inferior to the medial malleolus and the flexor retinaculum is identified and partially transected to expose the common plantar artery. This incision can be followed deeper into the foot under thick plantar fascial tissue and through the abductor hallucis muscle to access the medial or lateral plantar arteries. Of the two, the lateral is typically the more inferior and often the larger. The



**Fig 3.** Anatomical rendering of the medial foot demonstrating the course of the common plantar artery and its terminal branches. (Reprinted with permission by Elsevier from Andros G, Harris RW, Salles-Cunha SX, et al. "Lateral plantar artery bypass grafting: defining the limits of foot revascularization" *J Vasc Surg* 1989; 10:511-21.)

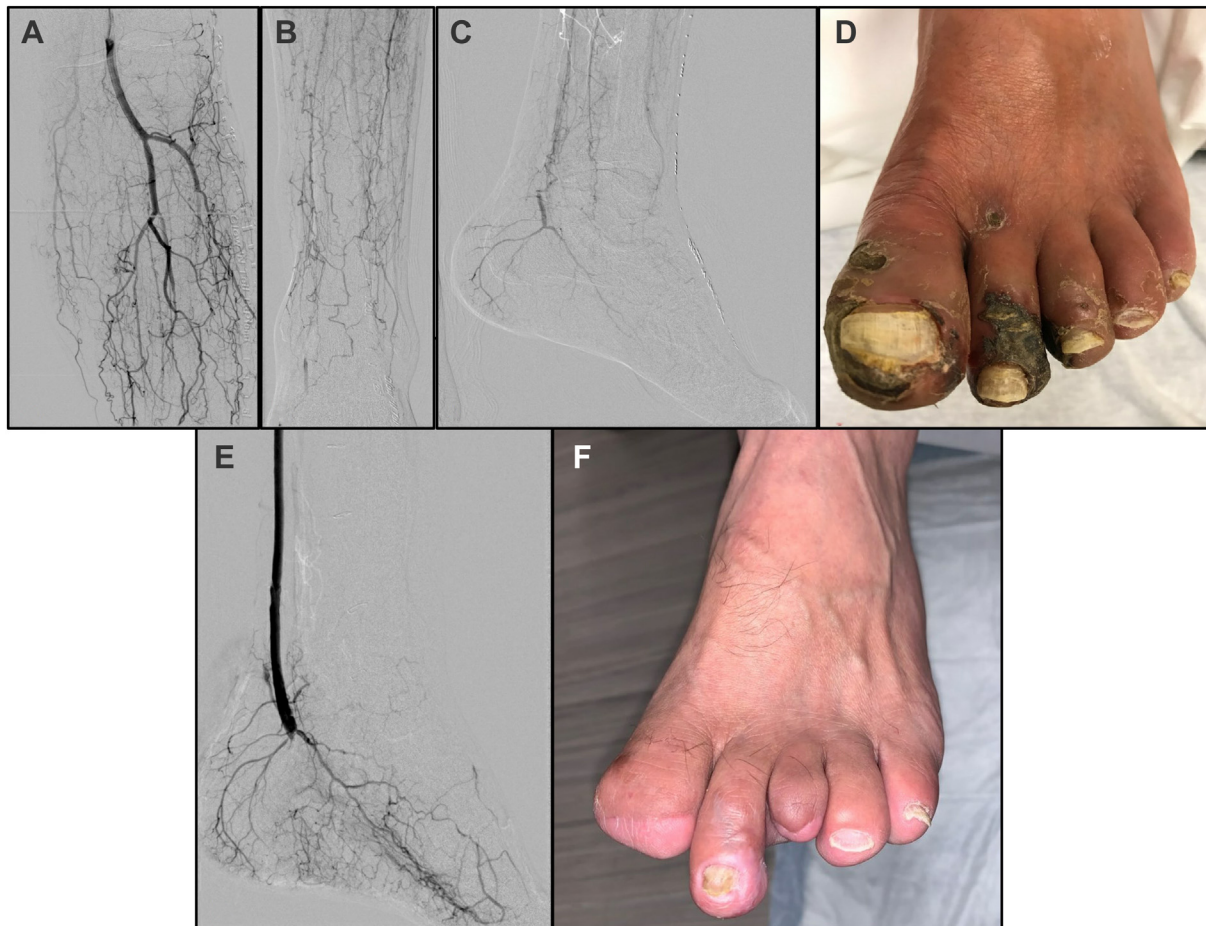
planning angiogram and photos for a patient with patent common plantar and lateral plantar arteries are demonstrated in Fig 4, A-D, with the completion angiogram and a 1-year follow up image in Fig 4, E, F.

Once the intended targets for inflow and outflow have been exposed, we use an umbilical tape to measure the length of conduit needed to achieve a tension-free bypass. The ankle joint is expected to have  $\geq 90^\circ$  of flexion and extension, and the conduit length must accommodate the ability to move with a full range of motion without endangering the graft. We perform open harvest of the vein conduit with as little direct grasping of the vein as possible to avoid inadvertent injury during dissection, and we always harvest several centimeters more than is needed. Longitudinal incisions with skin bridges are used. All side branches are ligated once the necessary length of vein is exposed, with a few larger side branches left with longer stumps for convenient use as entry points for retrograde valvulotomy. We use a buffered crystalloid vein harvest solution (Plasmalyte) containing heparin (4 U/mL) and papaverine (0.12 mg/mL) to flush the graft and keep it hydrated while preparing for implantation.

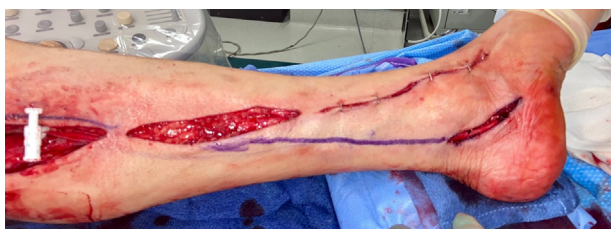The tunneling is performed before heparinization to decrease bleeding complications. Tunneling to the dorsalis pedis or its branches is performed subcutaneously from the medial leg in the proximal one-half of the calf before crossing over the tibia in the distal one-third of the leg in a gentle S shape and approaching the target in a straight line parallel to the tibia. This procedure

typically requires two counterincisions to cross over the tibia. If there is a limited length of saphenous vein available or nearby wounds are prohibitive to a subcutaneous graft position, the tunnel can be made anatomically through the interosseous membrane within the anterior compartment. Tunneling to the plantar vessels is typically performed in the subcutaneous space, passing behind the medial malleolus to enter the medial foot. In both cases, the tunnel may be close to the harvest site of the saphenous vein, but all efforts should be taken to position the bypass in intact tissue beside the harvest site rather than within it in case of wound breakdown (Fig 5). If there is significant edema in the leg, a relaxing incision farther from the graft may be helpful to relieve tension on incisions nearest to the bypass.

Because of the small size of the outflow vessels, we typically perform the bypass in a nonreversed fashion for better size matching. However, a reversed orientation is acceptable if the size match is appropriate. After weight-based heparin is administered, the proximal anastomosis is performed first. After an arteriotomy of 1.0 to 1.5 cm in length is created on the vessel, the vein graft is spatulated and the anastomosis performed with running 5-0 or 6-0 polypropylene sutures. In a deep cavity such as the below-knee popliteal space, a parachute technique may be valuable to best visualize suture placement at the heel of the anastomosis, which is at the greatest risk for narrowing. After completion of the anastomosis, the clamps or tourniquet are released to allow dilation of the graft. In a nonreversed vein, we prefer to



**Fig 4.** (A-C) Planning angiogram demonstrating a patent distal popliteal artery, anterior tibial origin, and tibioperoneal trunk with occlusion of all three tibial vessels and numerous collaterals. (D) Preoperative photo demonstrating progressive dry gangrene affecting the hallux and toes 2 and 3. There was mild drainage from the hallux ulcer but no significant cellulitis on the foot. (E) Completion angiogram demonstrating the distal anastomosis of the bypass at the common plantar artery. Only one of the branches, the lateral plantar, was patent. The pedal arch is heavily diseased as well. (F) Photo at 1 year after bypass demonstrating complete healing of digit 2 as well as the amputation sites of digits 1 and 3. Case included with permission from patient.



**Fig 5.** Popliteal to common plantar bypass demonstrating proximity of the harvest site to the bypass. The proximal bypass is seen in the proximal incision (occluded by a white bulldog clamp), but is positioned deep to the subcutaneous tissues in the mid leg and is not exposed in the harvest site. Distally the vein graft is seen overlying the distal target. Case included with permission from patient.

use a Mills valvulotome to rupture the valves. We prefer not to telescope the entire length of vein onto the valvulotome, and instead access the vein in segments via two

or three larger side branches that have been left long enough to religate without narrowing the graft. The valves are only disrupted with the vein fully distended to avoid accidental laceration. Once completed, there should be robust pulsatile flow from the vein. The distal end of graft is clipped, and the anterior surface marked to help avoid inadvertent twisting of the graft.

Once the graft has been passed through the tunnels and is overlying the distal target, the leg is elevated and an Esmarch bandage is used to exsanguinate the leg before inflation of the tourniquet. A small intraluminal balloon may be needed for inflow control with very severe proximal calcifications. Choosing the best site for the arteriotomy is an important point. It is best to avoid areas of severe calcification; occasionally, an artery with diffuse medial calcification will have a focal gap between plaques that can be advantaged. When the calcification is purely medial, it may be possible to gently crack the

ring with forceps to facilitate suturing. An arteriotomy is made longitudinally for a length of approximately 6 to 12 mm in the inframalleolar vessel with a microscalpel and fine Potts scissors. We confirm that the outflow tract is patent by gently probing with a 1- or 2-mm lacrimal probe and then the graft is trimmed to length. After spatulating the end, we usually use a parachuting technique with 6-0 or 7-0 polypropylene sutures for the anastomosis in a running fashion. In the case of a significantly calcified pedal artery, we tend to use slim tapered-point needles such as the Ethicon Visi-black needle. Thorough flushing is critical before completion of the anastomosis.

We evaluate both anastomoses routinely with intraoperative duplex ultrasound examination to look for any evidence of a technical defect causing hemodynamically significant stenosis. Additionally, we perform a completion angiogram in all patients to confirm there is no compromise in either anastomosis, lie of the graft, or the outflow (Figs 1, E, and 2, E). Papaverine hydrochloride (30-60 mg) is injected into the graft and foot to relieve any spasm. Once satisfied with the technical result, the heparinization is reversed with protamine and meticulous hemostasis achieved.

Multilayered closure with gentle soft tissue handling is essential to prevent wound healing complications over the superficially located graft. Our preference is to use nylon vertical mattress sutures in all incisions below the knee, which remain in place for  $\geq 3$  weeks, but often longer if there is any concern for incomplete healing. Dressings should be placed painstakingly to avoid focal pressure on the bypass graft and windows provided to allow for regular pulse examinations. A gentle ACE wrap may be helpful to decrease postoperative edema, and a posterior splint or boot should be made for patients with bypass to the plantar foot to maintain a neutral position.

**Postoperative management.** Control of edema is paramount for avoiding wound breakdown after pedal bypass. The leg is strictly elevated above the level of the heart at all times during the first 24 hours and any time the patient is not actively ambulating once they have been cleared to get out of bed. We minimize intravenous fluids postoperatively with goal-based resuscitation rather than automatic order sets, and diuresis is commonly used on postoperative day 2 onward to help maintain euvolemia in patients with any renal disease or reduced ejection fraction. We maintain all patients on antiplatelet and statin therapy before and after bypass and initiate rivaroxaban 2.5 mg twice daily on postoperative day 3 unless they have indications for other antithrombotic regimens.<sup>16</sup>

If the patient needs a podiatric procedure after their revascularization, we recommend waiting a minimum of 3 to 5 days for reperfusion and resolution of acute

edema. A transition from dry to wet gangrene may prompt an urgent procedure, but in that situation, it may be prudent to leave the wound open with a plan for delayed primary closure.

Our preference is to repeat noninvasive evaluation with toe pressures before discharge to establish a new baseline. After discharge, we follow patients with an incision check 2 weeks after discharge, then a repeat duplex ultrasound examination and clinical evaluation at 1 month. If no issues are identified, we typically schedule surveillance ultrasound examinations at 3 months and every 6 months thereafter. We are fortunate to have a multidisciplinary limb preservation team, so wounds in our patients are closely followed by podiatric colleagues; it is critical that any worsening of foot wounds are communicated immediately between the podiatrist and the vascular surgeon, such that re-evaluation of the perfusion status and aggressive reintervention can be performed if necessary.

## DISCUSSION

Even in patients with severe distal disease, pedal bypass may offer excellent rates of limb salvage. In a retrospective analysis of 865 patients treated at a single center, one group found a 5-year limb salvage rate for dorsalis pedis bypass of 78.2% with superior performance in patients with saphenous veins over other conduits.<sup>7</sup> Similarly, a series of 98 bypasses performed to plantar or tarsal branches reported a 69% limb salvage rate at 5 years, despite the very distal targets used.<sup>5</sup> Direct comparisons of pedal bypass and infrapopliteal endovascular interventions are limited, but in a review of short-term outcomes of bypass-first vs endovascular-first revascularizations for infrageniculate disease, there were significantly higher rates of major amputation in the endovascular-first cohort with 7.4% vs 4.3% at 30 days.<sup>17</sup> Compelling longer term data from the BEST-CLI trial also supports the use of saphenous vein infrainguinal bypass as first line for CLTI management in patients with adequate vein, although subgroup data on distal tibial or pedal targets are not available yet.<sup>18</sup> Individualized treatment plans that factor in the patient, problem, and anatomy are critical to optimizing outcomes of CLTI treatment, and handling small, diseased vessels in distal bypasses requires a high level of technical finesse. It is critical that a vascular surgeon continues to practice and refine these techniques throughout their career.

## CONCLUSIONS

Inframalleolar bypass is a valuable revascularization option for patients with severe disease below the knee, but requires a high degree of technical skill. Outcomes in patients with adequate autologous conduit are encouraging.

## REFERENCES

1. Duff S, Mafilios MS, Bhounsule P, Hasegawa JT. The burden of critical limb ischemia: a review of recent literature. *Vasc Health Risk Manag* 2019;15:187-208.
2. Aday AW, Matsushita K. Epidemiology of peripheral artery disease and polyvascular disease. *Circ Res* 2021;128:1818-32.
3. Mustapha JA, Finton SM, Diaz-Sandoval LJ, Saab FA, Miller LE. Percutaneous transluminal angioplasty in patients with infrapopliteal arterial disease: systematic review and meta-analysis. *Circ Cardiovasc Interv* 2016;9:e003468.
4. Zia S, Juneja A, Shams S, Faheem B, Shariff MA, Singh K, et al. Contemporary outcomes of infrapopliteal atherectomy with angioplasty versus balloon angioplasty alone for critical limb ischemia. *J Vasc Surg* 2020;71:2056-64.
5. Hughes K, Domenig CM, Hamdan AD, Schermerhorn M, Aulivola B, Blattman S, et al. Bypass to plantar and tarsal arteries: an acceptable approach to limb salvage. *J Vasc Surg* 2004;40:1149-57.
6. Ascer E, Veith FJ, Gupta SK. Bypasses to plantar arteries and other tibial branches: an extended approach to limb salvage. *J Vasc Surg* 1988;8:434-41.
7. Pomposelli FB, Kansal N, Hamdan AD, Belfield A, Sheahan M, Campbell DR, et al. A decade of experience with dorsalis pedis artery bypass: analysis of outcome in more than 1000 cases. *J Vasc Surg* 2003;37:307-15.
8. Simons JP, Schanzer A, Flahive JM, Osborne NH, Mills JL Sr, et al. Survival prediction in patients with chronic limb-threatening ischemia who undergo infrainguinal revascularization. *J Vasc Surg* 2019;69:1375-51S.e3.
9. Mills JL Sr, Conte MS, Armstrong DG, Pomposelli FB, Schanzer A, Sidawy AN, et al. The Society for vascular surgery lower extremity threatened limb classification system: risk stratification based on wound, ischemia, and foot infection (WIFI). *J Vasc Surg* 2014;59:220-34.e1-2.
10. Schanzer A, Hevelone N, Owens CD, Belkin M, Bandyk DF, Clowes AW, et al. Technical factors affecting autogenous vein graft failure: observations from a large multicenter trial. *J Vasc Surg* 2007;46:1180-90; discussion: 90.
11. Almasri J, Adusumalli J, Asi N, Lakis S, Alsawas M, Prokop LJ, et al. A systematic review and meta-analysis of revascularization outcomes of infrainguinal chronic limb-threatening ischemia. *J Vasc Surg* 2018;68:624-33.
12. Nierlich P, Enzmann FK, Metzger P, Dabernig W, Akhavan F, San Martin JE, et al. Arm vein versus small saphenous vein for lower extremity bypass in the absence of both great saphenous veins. *Ann Vasc Surg* 2021;70:341-8.
13. Nierlich P, Enzmann FK, Metzger P, Dabernig W, Aspalter M, Akhavan F, et al. Alternative Venous conduits for below knee bypass in the absence of Ipsilateral great saphenous vein. *Eur J Vasc Endovasc Surg* 2020;60:403-9.
14. McGinagle KL, Pascarella L, Shortell CK, Cox MW, McCann RL, Mureebe L. Spliced arm vein grafts are a durable conduit for lower extremity bypass. *Ann Vasc Surg* 2015;29:716-21.
15. O'Banion LA, Wu B, Eichler CM, Reilly LM, Conte MS, Hiramoto JS. Cryopreserved saphenous vein as a last-ditch conduit for limb salvage. *J Vasc Surg* 2017;66:844-9.
16. Bonaca MP, Bauersachs RM, Anand SS, Debus ES, Nehler MR, Patel MR, et al. Rivaroxaban in peripheral artery disease after revascularization. *N Engl J Med* 2020;382:1994-2004.
17. Dayama A, Tsilimparis N, Kolakowski S, Matolo NM, Humphries MD. Clinical outcomes of bypass-first versus endovascular-first strategy in patients with chronic limb-threatening ischemia due to infrageniculate arterial disease. *J Vasc Surg* 2019;69:156-63.e1.
18. Farber A, Menard MT, Conte MS, Kaufman JA, Powell RJ, Choudhry NK, et al. Surgery or endovascular therapy for chronic limb-threatening ischemia. *N Engl J Med* 2022;387:2305-16.

Submitted Dec 23, 2022; accepted Jan 18, 2023.