



Spontaneous Pneumomediastinum in a Patient with Coronavirus Disease 2019 Pneumonia and the Possible Underlying Mechanism

Pinggui Lei, MD, PhD¹, Jujiang Mao, MD¹,
Pingxian Wang, MD²

Departments of ¹Radiology and ²Medical Insurance, The Affiliated Hospital of Guizhou Medical University, Guiyang, China

Dear Editor,

We read the article by Sun et al. (1) in the *Korean Journal of Radiology* with great interest concerning the computed tomography (CT) findings of coronavirus disease 2019 (COVID-19). The report demonstrated that mediastinal emphysema, giant bulla, and pneumothorax developed as complications of COVID-19 pneumonia during the course of the disease.

Spontaneous pneumomediastinum seems to be rare in COVID-19. Here, we share our opinions on the possible mechanism underlying pneumomediastinum in COVID-19 pneumonia. Further, we report a case of spontaneous pneumomediastinum in a COVID-19 patient (Fig. 1) that was found to resolve on follow-up CT images at our hospital. Severe acute respiratory syndrome coronavirus 2 (SARS-CoV-2), which causes COVID-19, and other coronaviruses

that cause SARS and Middle East respiratory syndrome might have similar characteristics as they belong to the same family *Coronaviridae*. Spontaneous pneumomediastinum was reported in patients with SARS in 2003 (2). A study showed that a substantial proportion (12%) of patients with SARS could develop spontaneous pneumomediastinum unrelated to the use of positive end-expiratory pressure ventilation (2). In SARS, spontaneous pneumomediastinum occurs most frequently when the ground-glass opacities (GGOs) and consolidations in the lungs begin to resolve (3). In this situation, peribronchiolar abscess formation probably leads to interstitial pulmonary emphysema, which tracks back along the bronchovascular sheath and reaches the mediastinum (3). Subsequently, chest CT shows spontaneous pneumomediastinum (3). We believe that the mechanism underlying pneumomediastinum in patients with COVID-19 pneumonia is similar to that in patients with SARS because the viruses in the same *Coronaviridae* family may have similar pathogeneses and imaging features. At our hospital, one (7.14%) out of 14 patients with COVID-19 pneumonia developed spontaneous pneumomediastinum. The patient was a 64-year-old man complaining of fever and fatigue for 7 days. He had a history of recent travel to an area with the COVID-19 epidemic. Chest CT performed 17 days after the onset of symptoms showed progressive resolution of the patient's pneumonic lesions and the presence of spontaneous pneumomediastinum in the anterior mediastinum (Fig. 1A), which had been absent on CT performed at the time of the initial diagnosis (not presented). Follow-up CT performed 24 days after the onset of symptoms revealed resolution of the previously seen anterior pneumomediastinum (Fig. 1B).

Some typical CT features are observed in the patients with COVID-19 pneumonia. GGOs and consolidation are distributed in the peripheral bronchovascular or subpleural areas in the lower lobes, particularly in the right lower lobe, in the early stage. In the advanced or severe stages, GGOs decrease, and GGOs mixed with consolidation or consolidation increase. Fibrosis can be detected as lung lesions dissipate. This case as well as the previously reported cases might indicate that spontaneous pneumomediastinum on CT may be discovered in the late stages when GGOs and GGOs mixed with consolidations begin to resolve.

Received April 7, 2020 Revised April 11, 2020
Accepted April 12, 2020

Corresponding author: Pinggui Lei, MD, PhD, Department of Radiology, The Affiliated Hospital of Guizhou Medical University, No.28, Guiyi Street, Yunyan District, Guiyang 550004, China.

• Tel: (86) 187 8611 8165 • Fax: (86) 851 8677 2193
• E-mail: pingguilei@foxmail.com

This is an Open Access article distributed under the terms of the Creative Commons Attribution Non-Commercial License (<https://creativecommons.org/licenses/by-nc/4.0>) which permits unrestricted non-commercial use, distribution, and reproduction in any medium, provided the original work is properly cited.

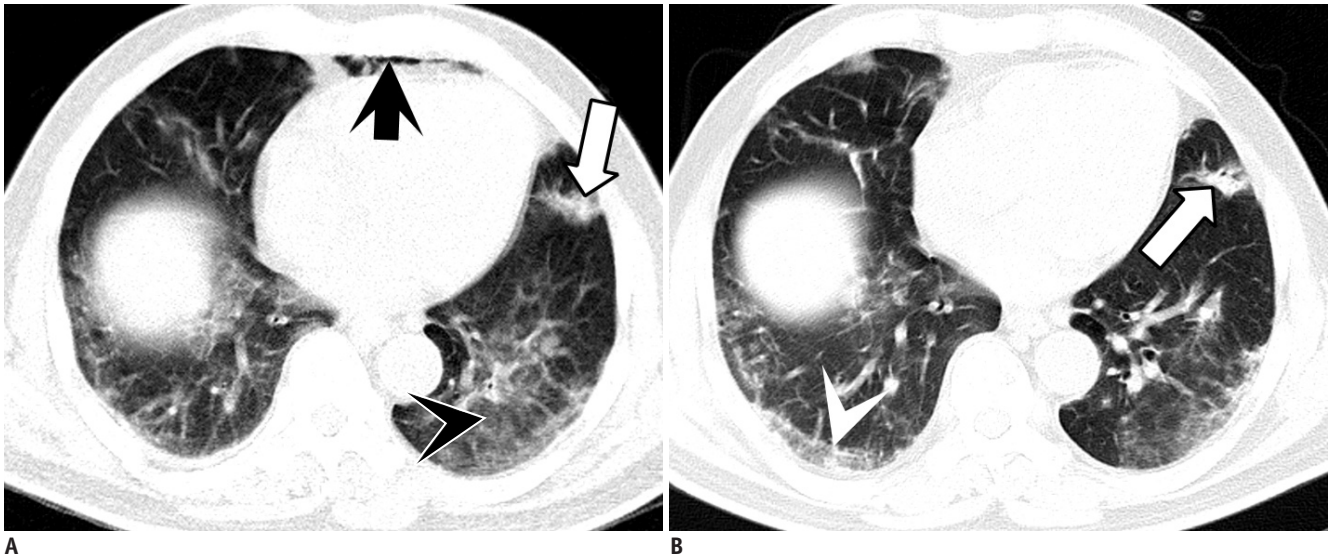


Fig. 1. 64-year-old man with coronavirus disease 2019.

A. Chest CT scan obtained 17 days after onset of symptoms shows GGOs (black arrowhead) and consolidations (white arrow) with spontaneous pneumomediastinum (black arrow) in anterior mediastinum. **B.** Follow-up CT scan obtained 24 days after onset of symptoms shows resolution of anterior pneumomediastinum (not shown), reduced GGOs, increased consolidations or GGOs mixed with consolidations (white arrow), and reticular opacities (white arrowhead) in lung parenchyma. CT = computed tomography, GGOs = ground-glass opacities

ORCID iDs

Pinggui Lei

<https://orcid.org/0000-0001-7610-0292>

Jujiang Mao

<https://orcid.org/0000-0002-7206-7963>

Pingxian Wang

<https://orcid.org/0000-0001-7373-7212>

REFERENCES

1. Sun R, Liu H, Wang X. Mediastinal emphysema, giant bulla,

and pneumothorax developed during the course of COVID-19 pneumonia. *Korean J Radiol* 2020 Mar 20 [Epub]. <https://doi.org/10.3348/kjr.2020.0180>

2. Peiris JS, Chu CM, Cheng VC, Chan KS, Hung IF, Poon LL, et al.; HKU/UCH SARS Study Group. Clinical progression and viral load in a community outbreak of coronavirus-associated SARS pneumonia: a prospective study. *Lancet* 2003;361:1767-1772

3. Hui JY, Cho DH, Yang MK, Wang K, Lo KK, Fan WC, et al. Severe acute respiratory syndrome: spectrum of high-resolution CT findings and temporal progression of the disease. *AJR Am J Roentgenol* 2003;181:1525-1538