

Received: 2012.07.30
Accepted: 2012.08.09

Usefulness of the computed tomography and magnetic resonance in evaluation of progress of treatment of the neoplastic diseases in children

Jolanta Myga-Porosi^o, Hanna Borowiak, Wojciech Sraga, Zuzanna Jackowska, Magdalena Serafin, Ewa Kluczewska

Department and Institute of Medical Radiology and Radiodiagnosis in Zabrze, Medical University of Silesia in Katowice, Zabrze, Poland

Author's address: Jolanta Myga Porosi^o, Department and Institute of Medical Radiology and Radiodiagnosis in Zabrze, Medical University of Silesia in Katowice, 3 Maja 13-15 St., 41-800 Zabrze, Poland, e-mail: jmyga@interia.pl

Summary

Background:

Neoplastic diseases constitute about 1% diseases in children in Poland, what makes about 1200 new incidents during one year. Fast diagnosis in those illnesses is crucial in treatment results. The point of this work was to value usefulness of CT and MRI in diagnostics of neoplastic diseases in children.

Material/Methods:

The retrospective study involved 121 children examined in CT and MRI because of suspicion or during treatment of neoplastic disease. Together 184 CT and 119 MRI examination were performed. Eventually in 106 children neoplastic disease was diagnosed. In 16 cases neoplasm was excluded.

Results:

In the analyzed group of patients acute lymphoblastic and non lymphoblastic leukemia was diagnosed in 68 children (55.7%); among them mycosis was identified after radiological examinations in 7 cases (10.3%). 8 children (6.6%) with non Hodgkin lymphoma and 11 (9%) with Hodgkin lymphoma were examined. Nephroblastoma was found after MRI and CT in 6 cases (4.9%). Presence of tumors, that were classified histopathologically as PNET, was confirmed in 4 children. In 15 cases after MRI and CT neoplastic disease was excluded.

Conclusions:

Depending on the kind of sickness MRI and CT may fulfill basic or subsidiary role in diagnostic and estimating the progress of treatment in neoplastic diseases among children.

Key words:

hematology • pediatric oncology • children • computed tomography • magnetic resonance imaging

PDF file:

<http://www.polradiol.com/fulltxt.php?ICID=883374>

Background

Neoplastic diseases constitute about 1% of the causes of disease among children in Poland. Leukemia is the most common cancer occurring in this age group, the next one is the central nervous system tumor, lymphomas, sarcomas of soft tissues, the sympathetic nervous system tumors, kidney tumors. The incidence of children in Poland is around 130 new cases per 1 million children per year, which represents about 1,200 newly diagnosed cases of cancer per year in children in our country [1].

There is a much closer correlation between patients' age and the peak incidence of various cancers in the case of

cancer in childhood than in adults. Peak incidence of germ cell tumors (neuroblastoma, retinoblastoma, hepatoblastoma) accounts for up to 2 years of age with acute lymphoblastic leukemia between 2 and 4 year of age. Hodgkin's disease is usually diagnosed in child over 4 years of age, while non-Hodgkin lymphoma (NHL) between 7 and 10 years of age, and sarcomas in children between 2 and 6 years of age and over 12 years of age. Although the incidence of cancer in children is much lower than in non-neoplastic diseases, but these very rapid recognition of disease entities is essential to the implementation of the treatment, which increases the chances of recovery.

Table 1. Number of CT and MRI examinations of the individual body regions.

Examination kind	Anatomical area							
	Head	Sinuses	Neck	Chest	Abdomen and pelvis	Spine	Joints	Vascular examination
CT	29	4	10	80	59	0	0	2
MRI	77	0	6	11	10	12	3	0

Table 2. Numer of patients with diagnosis of individual diseases.

	Diagnosis						
	Leukemia	Non-Hodgkin lymphoma	Hodgkin's disease	Neuroblastoma	Wilms' tumor	PNET	Exclusion of cancer
Case number N=121	68 (55.7%)	8 (6.6%)	11 (9.1%)	6 (4.9%)	5 (4.1%)	5 (4.1%)	18 (4.9%)

Radiology in the diagnosis of cancer processes in children is used for different purposes, depending on the conditions faced by a young patient. The aim of this study was to determine the usefulness of computed tomography and magnetic resonance imaging in the diagnosis of different types of tumors in children.

Material and Methods

The clinical material includes 121 children examined with computed tomography and magnetic resonance imaging due to suspected or during treatment of the neoplastic disease.

The study was performed in the Department and Institute of Medical Radiology and Radiodiagnosis of Clinical Hospital No. 1 and in Voxel Magnetic Resonance Laboratory in Zabrze in the years 2008–2011.

49 boys aged 1–17 years (median 7 years) and 30 girls aged 2–17 years (median 7 years) were among children examined with CT. 39 boys aged 1–17 years (median 6 years) and 22 girls aged 1–17 years (median 4.5 years) were among children examined with MRI. In 20 children (10 boys and 10 girls) of the above groups both computed tomography and magnetic resonance imaging were performed. Ultimately, cancer was diagnosed in 106 children. Malignancy was excluded in 16 children during hospitalization.

184 computed tomography examinations and 119 magnetic resonance imaging examinations were performed in total (the number of examinations showing the specific anatomical area is shown in Table 1).

16-row LightSpeed appliance made by GE was used to perform computed tomography. MRI was performed using the HDxT 1.5 T Signa appliance made by GE. The study was conducted using standard protocols using the principles of radiation protection adopted in the Department. In appropriate cases intravenous contrast agents were administered and patient sedation was used. Studies were evaluated on a workstation Advanced Workstation 4.0 HP.

Results

Due to the transparency the patients were grouped with reference to the diagnosis made during hospitalization. The following groups of patients were distinguished: a group of leukemia, non Hodgkin lymphoma, Hodgkin's disease, Wilms' tumor, neuroblastoma, PNET. The number of patients belonging to different groups is shown in Table 2.

Leukemia

In the diagnostic process in the analyzed group of patients acute lymphoblastic or non-lymphoblastic leukemia was diagnosed in 68 children (55.7%).

In these patients the main indication for magnetic resonance imaging and computed tomography was the exclusion of involvement of central nervous system in the underlying disease. CNS involvement was excluded on the basis of head CT examination performed in 20 children (13 boys and 7 girls), based on head MRI examination in 36 children (12 girls and 24 boys). In 5 children head CT examination was performed because of suspected bleeding into CNS. This examination excluded bleeding in 4 cases, but in 1 case it confirmed bleeding to CNS in the form of intracerebral hematoma and subdural hematoma. In 3 cases computed tomography image did not allow a clear diagnosis. In these examinations in the brain symptoms of edema and hypodense lesion were diagnosed and leukemic infiltration of CNS was suspected. The subsequently performed MRI examination in these children, in two cases leukemic infiltration of CNS was confirmed, and in one laboratory-confirmed CNS mycosis.

In 12 children computed tomography was performed in the course of chemotherapy with suspected systemic mycosis. The diagnosis of fungal infection on the basis of computed tomography was confirmed in 7 patients (10.3%). In four cases pulmonary mycosis was confirmed in the form of diffuse pulmonary nodules (in one child), infiltration of lung tissue (in 2 children) and cavities (in one child). Two children were found abscesses in liver and spleen, and

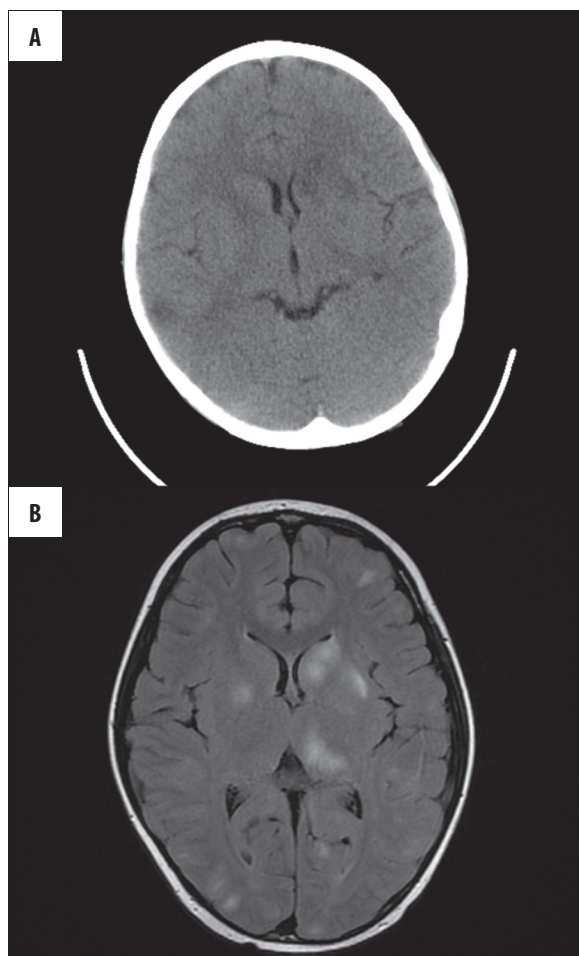


Figure 1. Boy BM, age 8 with diagnosis of acute lymphoblastic leukemia. CT brain examination shows ambiguous hypodense focal lesions in both hemispheres. In MRI examination these were identified as leucemic infiltration.

disseminated nodules in the lung parenchyma. In one child in addition to involvement the liver, spleen, and nodular changes in the lungs parenchyma the renal abscesses and interloop abscess were revealed. Controlled CT performed in these children during treatment with antifungal revealed gradual regression of the described changes.

CT excluded mycosis changes in thoracic cage and abdominal cavity in the remaining 5 children. In 2 cases the reason for referral to the abdominal CT scan was clinical suspicion of intestinal obstruction. In both cases, CT scan confirmed the clinical diagnosis of the features of necrotizing enterocolitis with diffuse swelling of the intestinal wall and intramural pneumatosis. In 1 of these children one also observed features of gastrointestinal bleeding with extravasation of contrast given intravenously into the jejunal lumen.

3 patients (4.4%) were performed MRI examinations during the clinically found relapse of acute lymphoblastic leukemia in order to determine the stage of the process. In 2 boys the meningeal relapse was revealed, which was visible as a thickening and strong contrast enhance of cerebral leptomeningeal. In 1 child meningo – brain relapse

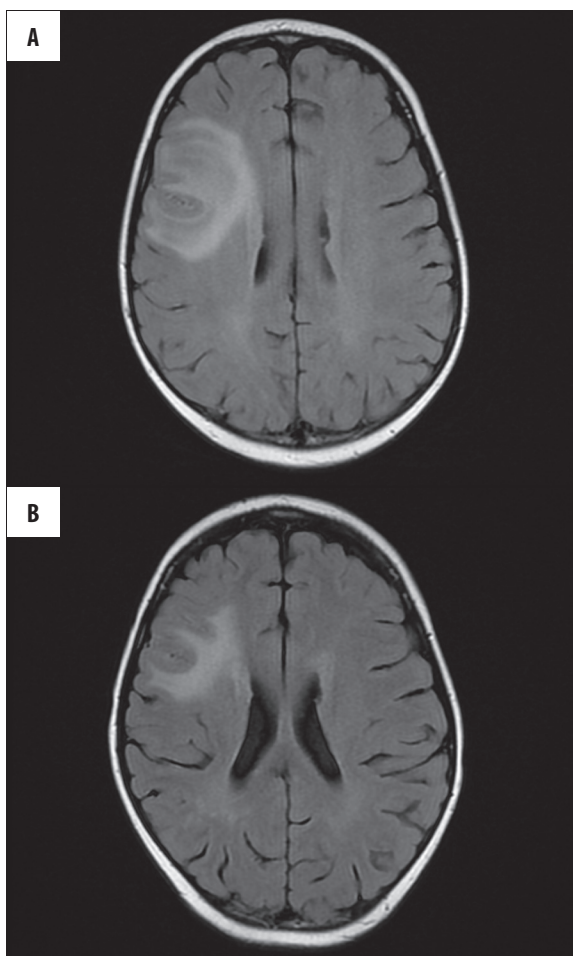


Figure 2. Boy BM, age 8. MRI examination during chemotherapy shows focal mycosis in right brain hemisphere. In check MRI partial remission.

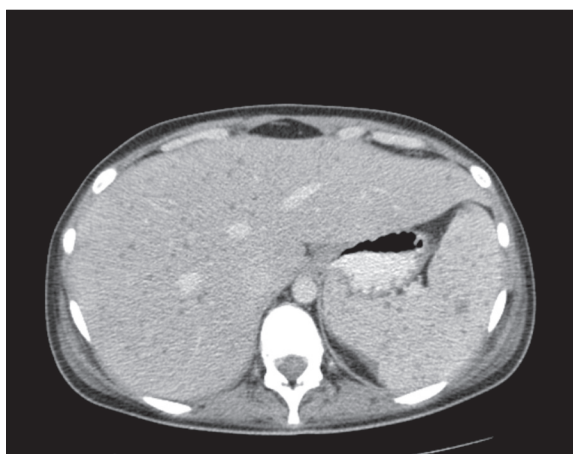


Figure 3. Patient JM age 17 with diagnosis of acute lymphoblastic leukemia during chemotherapy. CT examination with i.v. application of contrast shows multiple, small mycosal abscesses of liver and spleen.

was diagnosed, where next to cerebral leptomeningeal thickening focal infiltration of the occipital lobe with vasogenic edema features and contrast enhance were observed. All these patients were subsequently subjected repeated

control examinations that confirmed the regression of CNS during relapse treatment. In 1 of the boys at a later time there was a second recurrence of meningo – cerebral confirmed radiologically.

MRI of the spine in children with leukemia was performed in 4 patients. In 2 cases correct picture of the spine was seen, in 1 case involvement of cerebral leptomeningeal with their thickening and contrast enhancement, in 1 case involvement of bone marrow with lesion of stronger contrast.

Abdominal MRI was performed in 1 girl as a check on the treatment of systemic mycosis. In this study described in CT lesions in the spleen were not found; however, abscesses in the liver were confirmed (Figures 1–3)

Non-Hodgkin's lymphoma

During the period under review the imaging studies were performed in 8 children (6.6%) with diagnosed non-Hodgkin's lymphoma, including 2 girls and 6 boys. All patients were performed CT of the chest, abdomen and pelvis. The examination revealed pathological nodal masses in the chest in 6 patients, in the abdomen and pelvis in 4 children. In 2 cases, kidneys involvement in lymphoma progress was revealed, which took the form of enlarged kidneys with poorly delineated hypodense lesions. Magnetic resonance imaging examination was performed in 2 patients in order to exclude involvement CNS obtaining the correct picture of the brain. In one boy's spine MR examination was performed because of pain with suspected tumor infiltration, which was not confirmed on CT imaging and MRI of the abdominal cavity as a control to assess the effects of treatment, in which gradual reduction of the dimensions of some aortic lymph nodes was observed.

Hodgkin's disease

11 children (9%), including 8 boys and 3 girls with a diagnosis of Hodgkin's disease were examined with CT and MR. In 7 children CT of the chest and abdomen was performed, 3 of them were also performed CT of the neck. Further examination revealed the numerous packages of enlarged lymph nodes in the neck in 2 children, within the mediastinum in 5 children and within the abdominal cavity in three children. 1 patient had splenic involvement by the disease process in the form of scattered small hypodense lesions. One study of chest CT was performed because of ambiguous PET-CT, which revealed the lesions of enlarged radiotracer uptake in 6th segment of right lung with non-characteristic image. The control CT scan of the chest performed in our laboratory within the right lung did not reveal pathological concentration except for small fibrous changes, which was for the inflammatory nature of the lesion well visible in PET-CT.

MR examinations were performed in 4 children. These examinations included the neck and abdomen in 3 children, and the neck and chest in 1 boy. Packets of enlarged lymph nodes in the neck were revealed in all of these children. In 2 children enlarged lymph nodes in the abdomen, and in 1 patient enlarged mediastinal lymph nodes. In control

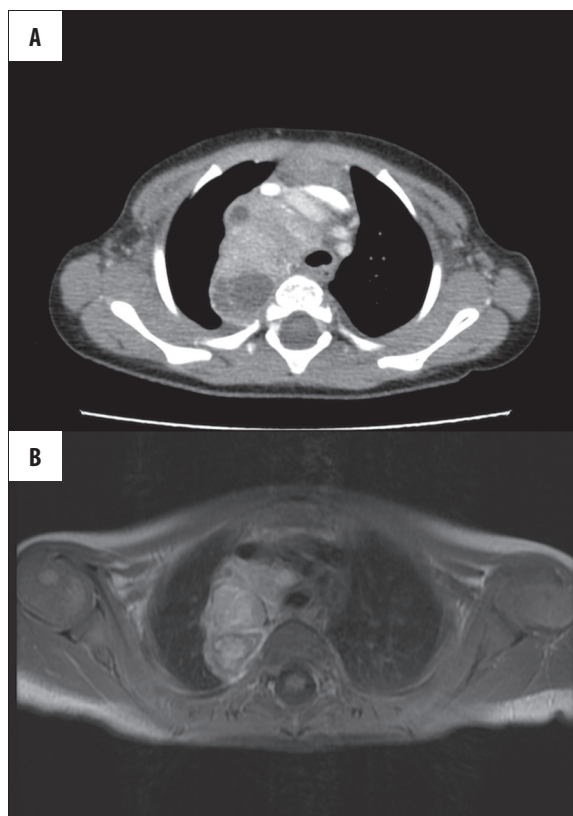


Figure 4. Patient JM age 2. CT examination performed because of dyspnoea. Both CT and MRI examination shows tumor in posterior mediastinum that shapes trachea, histopathological neuroblastoma.

examinations, in the course of both CT and MR treatment reduction of lymph nodes was observed.

Neuroblastoma

6 boys (4.9%) were performed radiological examination that revealed neuroblastoma. Among patients with a diagnosis of this disease in our material there was not a female person. In 3 cases the tumor was located within the posterior mediastinum. In 3 cases within the retroperitoneal space, with 1 in the adrenal location, and 2 localized outside of the adrenal glands. In single CT and MR examinations tumor penetration into the spinal canal with widening of the intervertebral opening was found.

Both CT and MR showed precise data on the location, shape and size of tumors. The MRI revealed the tumor structure more accurately confirming the methaemoglobin signals, providing proof of bleeding (Figure 4)

Wilms' tumor

Among the analyzed group of children Wilms' tumor was found in 5 patients (4.1%), including 3 boys and 2 girls. Further examination of abdominal CT in 4 cases tumor of one kidney was revealed. In 1 of the girls bilateral renal tumors were observed. In 1 of the children thoracic cage examination was performed showing the correct picture of the chest.

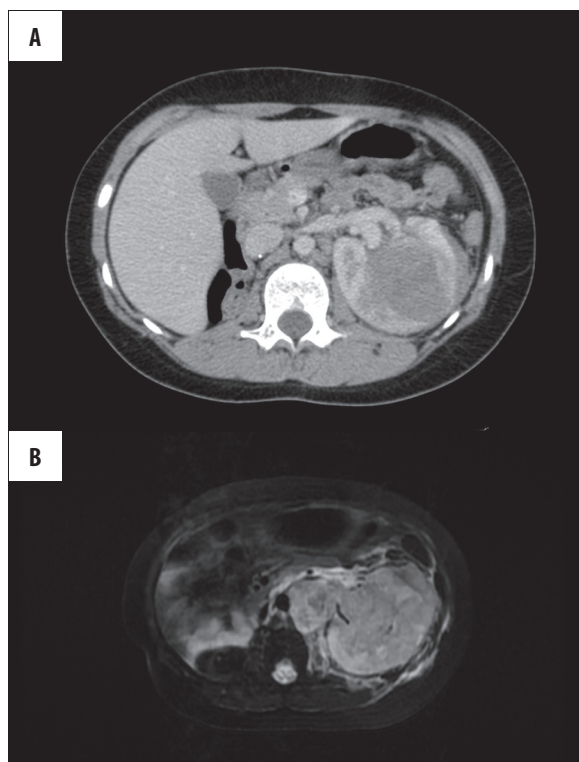


Figure 5. Patient MM age 8 with diagnosis of nephroblastoma post nephrectomy at the right side. MRI examination in T2 FatSat sequence shows another focus of the tumor in left kidney. Controlling CT shows acceleration of tumor size.

In 1 of the children CNS imaging was performed (CT and MRI) because of clinical symptoms of encephalopathy, which occurred during chemotherapy. These examinations excluded the pathological changes within the brain structures (Figure 5).

PNET – primitive neuroendocrine tumors

The presence of tumors which, after histopathological examination, were classified as PNET were diagnosed in 4 children (3.1%), including 3 girls and 1 boy. All tumors were located within the chest wall. Both CT and MRI of the chest revealed the location, shape and size of tumors and the degree of infiltration of the surrounding anatomic structures. CT scan showed significantly better pathological periosteal reactions within the bone infiltration structures. In 2 girls recurrence of the disease was found. In the case of thoracic MRI diagnostic value of these examinations was reduced in 2 cases due to numerous motion artifacts (Figure 6).

Exclusion of cancer

15 children were referred for computed tomography with suspected cancer due to clinical examination or X-rays or ultrasound previously performed. Among these children in 8 patients based on chest X-ray images mediastinal tumor or lymphadenopathy of pulmonary cavities were suspected. Chest computed tomography performed in 6 children revealed the correct picture of the thymus and excluded enlarged lymph nodes. In 2 cases there were atypical

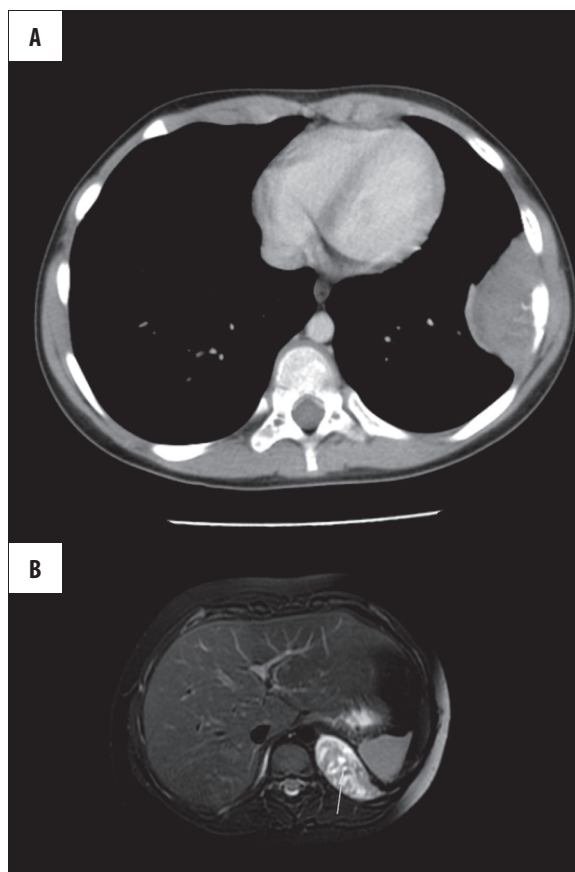


Figure 6. Patient FJ age 4 with suspicion of pleural empyema on the left side. In CT examination malignant thoracic wall tumor – histopathological PNET. In controlling MRI after surgical treatment recurrence of the tumor on the left side.

inflammatory changes in pulmonary parenchyma from a reactive lymph node enlargement within the mediastinum.

3 children were performed abdominal CT examinations of the suspected tumor. In 2 children tomography examination revealed a correct picture of the abdominal organs, and in 1 revealed the presence of retroperitoneal enlarged lymph nodes within the mesentery showing no obvious proliferative features of the process and a small amount of fluid in the peritoneal cavity. During the hospitalization on the basis of additional performed tests lymphadenopathy with *Yersinia enterocolitica* infection was diagnosed.

2 children were referred for computed tomography of the abdomen on the basis of ultrasound suspicion of renal tumor. In both of these children renal cysts were revealed.

1 of the children was subjected to computed tomography because of facial pain and exophthalmos within the right eye socket. CT scan revealed inflammatory changes in ethmoid penetrating to right eye socket.

1 of performed chest computed tomography gave false-positive result. The examination involved a boy aged 16 due to a considerable amount of bloody fluid in the left pleural cavity and inefficient drainage.

Computed tomography of the chest revealed pathological nodal masses within the mediastinum, subpleural nodules, infiltrative lesions in the pulmonary parenchyma, fluid in left pulmonary cavity and pericardial sac. According to the radiological examination metastatic tumor was suspected. However, on the basis of histopathological examination of lymph nodes taken at mediastinoscopy, tuberculosis was diagnosed.

Discussion

Diagnostic imaging in children with suspected proliferative disease requires selection of diagnostic methods, which allow diagnosis and implementation of appropriate treatment in the quickest and least burdensome way for children. Imaging studies in recent years have been rapidly improved as one of the most important elements of the diagnostic – therapeutic process, but the meaning of each imaging studies in various disease entities is different.

In the case of acute leukemia diagnosis is established on the basis of bone marrow smear. Cytochemical studies allow for the differentiation of acute lymphoblastic leukemia from non-lymphoblastic leukemia. Cytogenetic studies, the determination of chromosomal aberrations allow for more accurate determination of the prognosis. Radiology in the diagnosis of these conditions is used to evaluate the involvement of individual organs prior to treatment, especially the central nervous system that affects about 5% of the children. Leukemic infiltration of parenchymal organs occur with less frequency. Radiological examination may be helpful in the case of diagnostic doubts related to the necessity of differentiation of disseminated form of neuroblastoma and ALL, due to the fact that the image of the bone in both of these units may be similar. Radiological examination is helpful in determining the severity of the disease, especially involvement of the central nervous system and bone marrow.

The material analyzed by the authors of the evaluation of brain activities was made on the basis of both CT and MR, but it was MRI study that turned out to be characterized by greater sensitivity and allowed the settlement of diagnostic doubt they have raised in the case of some CT scans [2,3]. Similarly, a higher sensitivity is characterized by magnetic resonance imaging in the evaluation of bone marrow. According to this fact in our analysis of material, there was not even one tomography of the spine.

Another important use for diagnostic imaging of patients with leukemia, is to monitor the treatment to evaluate the occurrence of complications. In the cases studied by the authors imaging examinations usefulness in the diagnosis of mycosis in patients undergoing chemotherapy is taken into consideration.

In the case of mycosis of CNS and evaluation of meningeal and brain – meningeal relapse MRI was found as the study characterized by high efficiency. These findings are consistent with the information contained in the available literature [4-6].

This is not the case in the diagnosis of pulmonary fungal infection or abdominal parenchymal organs [7-9]. In the

case of these disease entities in the opinion of the authors of more useful test is computed tomography, which admittedly exposures children to ionizing radiation, however, it is not as susceptible to artifacts such as MRI, and it is not so heavily dependent on the cooperation of the patient. Note also the much shorter duration of sedation, which is required to perform CT test in comparison with MRI, which is not an inert factor for a young patient. In order to reduce the radiation exposure of patients, the authors call for the development of standard radiological procedures allowing to minimize radiation dose to which patients are exposed.

The studies analyzed by the authors attention was drawn to the fact that MRI has a lower sensitivity in making visible of small lesions characterized with fungal abscess in the spleen when compared with CT. This observation is consistent with the conclusions of Rabushka et al. presented in their work [9].

In view of the radiological diagnosis of abscesses spread to the liver during the treatment of leukemia in the analyzed literature the difficulty in differentiating of these changes from inflammatory pseudo-nodules liver were stressed. These are quite rare lesions of unknown etiology, which do not exhibit features of mycosis in histopathological examination, only the features of necrosis and fibrosis [10].

Imaging diagnostic for sufferers form both Hodgkin's and non-Hodgkin's lymphoma is crucial, as it allows to determine the severity of the disease process, which relies on the therapeutic management [11]. Imaging studies are used to determine the number, size and location of the pathologically changed lymph nodes, with a high degree of probability they allow to distinguish inflammatory from malignant nodes [11-13]. In case of doubt, diagnostic imaging studies allow to schedule a biopsy. The study of choice for evaluation of lymph nodes is considered computed tomography [11,14]. It also allows to evaluate the degree of parenchymal organ involvement, and monitoring the effectiveness of treatment. MRI has shown to have comparable efficacy in these areas; however, it is less effective in the diagnosis of infiltrative lesions of pulmonary parenchyma. In the case of suspected pulmonary parenchymal changes in the chosen examination should be CT scan [11,15]. While evaluating pathological nodal mass in the differential diagnosis other etiological factors should also be taken into account. One of the disease entities, which may cause diagnostic problems is tuberculosis, and it has been proven in clinical material gathered by the authors as well as the available literature [12,16,17].

Embryonal solid tumors in children, among which the most common are neuroblastoma and Wilms' tumor, clinically characterize with often quite long scantily symptomatic or asymptomatic course. In many cases, the only significantly expanding abdominal girth and shortness of breath associated with compression of the bronchial tree in children force parents to report to the doctor. Imaging examinations in case of diagnosis of neuroblastoma are particularly useful to identify the location of the primary tumor, its size, and penetration into the spinal canal.

Computed tomography has been proved to be useful in the evaluation of not only the location of tumors in the chest or

abdomen, but also of bone structures. MRI has an advantage over CT in the evaluation of penetration of the tumor within the spinal canal, whether the degree of involvement of bone marrow is less sensitive in the evaluation of small sized lymph nodes [18–21].

With reference to Wilms' tumors imaging examination allows for identification of the location, the size of the tumor and allows to plan the treatment. The exact determination of the severity of disease is essential for choosing the appropriate treatment [15,22]. For the assessment of primary kidney tumor both CT and MR are characterized by comparable efficacy, but in the case of suspected lung metastases in the available literature it is recommended to perform CT scans [21].

Soft tissue sarcomas in children are heterogeneous group of neoplasms; however, because of similar clinical features and treatment strategies are considered as 1 group. The authors analyzed material included 4 cases of primitive neuroectodermal tumor (PNET). These tumors can occur in places

where there is mesenchymal and neuroectodermal tissue. Because of the variety of locations and forms of these tumors, they require the use of different imaging methods. Computed tomography and magnetic resonance imaging are the most useful imaging methods. These tests allow the evaluation of tumor size, compared to the adjacent anatomical structures and the degree of invasion on the surrounding tissue. CT scan allows for more accurate evaluation of the degree of destruction of bone elements, the evaluation of malignant periosteal reactions. Magnetic resonance imaging allows for more accurate evaluation of the degree of bone marrow infiltration or neural structures [23–25].

Conclusions

Types of cancer in children are a diverse group of diseases characterized by high dynamics and are often different from cancer in adulthood. Imaging examinations, particularly CT scans and magnetic resonance imaging help to reduce the time required to make diagnosis, and thus the implementation of appropriate treatment.

References:

- Kowalczyk JR, Dudkiewicz E, Balwierz W et al: Incidence of childhood cancers in Poland in 1995–1999. *Med Sc. Monit*, 2002; 8(8): CR587–90
- Ferres M, Bidart T, Zubieta M: Importance of images and etiological diagnosis of central nervous system involvement in immunocompromised patient. *Rev Chil Infect*, 2010; 27(6): 541–43
- Chen C-Y, Zimmerman R, Faro S et al: Childhood Leukemia: Central Nervous System Abnormalities during and after Treatment. *AJNR Am J Neuroradiol*, 1996; 17: 295–310
- Glass H, Wirrell E, Sarnat H et al: MRI Findings in an Immunocompromised Boy with CNS Fungal Infection. *Can J Neurol Sci*, 2007; 34: 88–91
- Nicolle M-C, Benet T, Thiebaud A et al: Invasive aspergillosis in patients with hematologic malignancies: incidence and description of 127 cases enrolled in a single institution prospective survey from 204 to 2009. *Haematologica*, 2011; 96(11): 1685–91
- Leventakos K, Levis R, Kontoyiannis D: Fungal infections in Leukemia Patients: How Do We Prevent and Treat Them *Clinical Infectious Diseases*, 2010; 50: 405–15
- Jozalina Z, Wastie M, Ariffin N: Computed tomography of focal splenic lesions in patients presenting with fever. *Singapore Med J*, 2006; 47(1): 37
- Chew F, Smith P, Barboriak D: Candidal Splenic Abscesses. *AJR*, 1991; 156: 474
- Rabushka L, Kawashima A, Fishman E: Imaging of the Spleen: CT with Supplemental MR Examination. *Radio Graphics*, 1994; 14: 307–32
- Tajima K, Kosugi S, Fuyama S et al: Multiple Inflammatory Pseudotumors of the Liver Associated with Acute Myeloblastic Leukemia. *Internal Medicine*, 1998; 37(6): 542–45
- Delbeke D, Stroobants S, Kerviler E et al: Expert Opinions on Positron Emission Tomography and Computed Tomography Imaging in Lymphoma. *Oncologist*, 2009; 14(Suppl. 2): 30–40
- Yu R-S, Zhang W-M, Liu Y-Q: CT diagnosis of 52 patients with lymphoma in abdominal lymph nodes. *World J Gastroenterol*, 2006; 12(48): 7869–73
- Jędrzejewski G: Evaluation of mesenteric lymph nodes in children with abdominal pain. *Pol J Radiol*, 2008; 73(4): 25–27
- Fishman E, Kublan J, Jones R: CT of Lymphoma: Spectrum of Disease. *RadioGraphics*, 1991; 11: 647–69
- Smets A, Kraker J: Malignant tumours of the kidney: imaging strategy. *Pediatr Radiol*, 2010; 40: 1010–18
- Choi EC, Moon W-J, Lim YC: Tuberculous cervical lymphadenitis mimicking metastatic lymph nodes from papillary thyroid carcinoma. *Br J Radiol*, 2009; 82: e208–11
- Madhusudhan KS, Gamanagatti S, Seith A et al: Pulmonary infections mimicking cancer: report of four cases. *Singapore Med J*, 2007; 48(12): e327–31
- Kushner B: Neuroblastoma: A Disease Requiring a Multitude of Imaging Studies. *The Journal of Nuclear Medicine*, 2004; 45(7): 1172–88
- Ilias I, Sahdev A, Reznik R et al: The optimal imaging of adrenal tumors: a comparison of different methods. *Endocrine-Related Cancer*, 2007; 14: 578–99
- Rahman A, Sedera M, Mourad I et al: Posterior Mediastinal Tumors: Outcome of Surgery. *Journal of the Egyptian Nat. Cancer Inst*, 2005; 17(1): 1–8
- Rha SE, Byun JY, Jung SE et al: Neurogenic Tumors in the Abdomen: Tumor Types and Imaging Characteristics. *RadioGraphics*, 2003; 23: 29–43
- Łuczynska E, Anioł J, Stelmach A et al: Bilateral nephroblastoma – case report. *Pol J Radiol*, 2008; 73(4): 40–43
- Kuleta-Bosak E, Kluczevska E, Machnik-Broncel J et al: Suitability of methods (X-ray, CT, MRI) in the diagnostics of Ewing's sarcoma in children – analysis of own material. *Pol J Radiol*, 2010; 75(1): 18–28
- Wytenbach R, Vock P, Tschappeler H: Cross-sectional imaging with CT and/or MRI of pediatric chest tumors. *Eur Radiol*, 1998; 8: 1040–46
- Parikh M, Samujh R, Kanojia R et al: Peripheral Primitive Neuroectodermal Tumor of the Chest Wall in Childhood: Clinico – Pathological significance, management and literature Review. *Chang Gung Med J*, 2011; 34: 213–17