



# New onset of ocular myasthenia gravis in a patient with COVID-19: a novel case report and literature review

Shitiz Sriwastava<sup>1</sup> · Medha Tandon<sup>2</sup> · Saurabh Kataria<sup>3</sup> · Maha Daimée<sup>4</sup> · Shumaila Sultan<sup>1</sup>

Received: 6 September 2020 / Revised: 4 October 2020 / Accepted: 7 October 2020 / Published online: 12 October 2020  
© Springer-Verlag GmbH Germany, part of Springer Nature 2020

## Abstract

The novel coronavirus outbreak of SARS-CoV-2 first began in Wuhan, China, in December 2019. The most striking manifestation of SARS-CoV-2 is atypical pneumonia and respiratory complications; however, various neurological manifestations are now well recognized. Currently, there have been very few case reports regarding COVID-19 in patients with a known history of myasthenia gravis. Myasthenia gravis (MG) causes muscle weakness, especially respiratory muscles, in high-risk COVID-19 patients, which can lead to severe respiratory compromise. There are few reported cases of severe myasthenia crisis following COVID-19, likely due to the involvement of the respiratory apparatus and the use of immunosuppressive medication. We report the first case of ocular MG developing secondary to COVID-19 infection in a 65-year-old woman. Two weeks prior to hospitalization, the patient suffered from cough, fever, and diarrhea and was found to be positive for COVID-19 via a nasopharyngeal RT-PCR swab test. The electrodiagnostic test showed decremental response over more than 10% on repetitive nerve stimulation test of orbicularis oculi. She tested positive for antibodies against acetylcholine receptor. COVID-19 is known to cause the release of inflammatory cytokines, leading to immune-mediated damage. MG is an immune-mediated disorder caused by molecular mimicry and autoantibodies against the neuromuscular junction.

**Keywords** SARS-CoV-2 · COVID-19 · Myasthenia gravis · Ocular myasthenia · Neuromuscular disorder

## Abbreviations

COVID-19	Coronavirus infectious disease 2019
gMG	Generalized myasthenia gravis
MG	Myasthenia gravis
oMG	Ocular myasthenia gravis
Anti-MuSK	Anti-muscle-specific tyrosine kinase
AchRs	Acetylcholine receptor
MERS	Middle East respiratory syndrome
SARS-CoV-2	Severe acute respiratory distress syndrome coronavirus 2
IDSA/ATS	Infectious Disease Society of America/ American Thoracic Society

IVIG	Intravenous immunoglobulin
IL	Interleukin
EMG	Electromyography
MRI	Magnetic resonance imaging
RT-PCR	Reverse transcriptase polymerase chain reaction
CRP	C-reactive protein

## Introduction

Myasthenia gravis (MG) is a common autoimmune disorder caused by the production of autoantibodies against nicotinic acetylcholine receptors at the neuromuscular junction [1, 2]. The disruption of the neuromuscular pathway causes reduced stimulation of the muscles manifesting as fatigable muscle weakness, which may be generalized or focal, specifically involving ocular and bulbar regions, and in severe cases, leading to respiratory compromise [1, 3].

In general, 80% of generalized myasthenia gravis (gMG) patients and 55% of ocular myasthenia gravis (oMG) patients have autoantibodies against acetylcholine receptor blocking, binding and modulating receptors (AChR-Abs) (1).

✉ Shitiz Sriwastava  
sks00002@hsc.wvu.edu

<sup>1</sup> Department of Neurology, Rockefeller Neuroscience Institute, West Virginia University, One Medical Center Dr., Suite 1310, Morgantown, WV 26506-9180, USA

<sup>2</sup> Safdarjung Hospital, New Delhi, India

<sup>3</sup> Department of Neurology, University of Missouri Healthcare at Columbia, Columbia, MO, USA

<sup>4</sup> Department of Neurology, MedStar Georgetown University, Washington, DC, USA

Anti-MuSK antibodies tend to be positive in approximately one-third of patients who are seronegative in generalized myasthenia gravis [1].

Viral and bacterial infections are established triggers for a myasthenic crisis in patients with pre-existing myasthenia gravis. However, there is yet to be a clear consensus regarding infections causing myasthenia gravis in otherwise healthy patients.

With the outbreak of the novel coronavirus SARS-CoV-2, scientists and researchers around the world are trying to gain information regarding its effects and complications with regard to various pre-existing comorbidities on different subgroups of people. While atypical pneumonia and respiratory compromise are the primary features of COVID-19, various neurological manifestations are now well recognized, and many others are being extensively studied. There is also a concern that neuromuscular disorders affecting swallowing and breathing will predispose patients to a more severe infection [4].

Additionally, coronaviruses other than SARS-CoV-2, such as MERS and SARS, are well recognized to cause myopathies and neuropathies in addition to other neuromuscular disorders [5, 6]. A case series by Kim et al. reported critical illness neuropathy and acute sensory neuropathy in a group of patients with MERS [5]. Another case series by Tsai L. et al. of 4 cases of SARS-CoV infection was reported with coexistent neuropathy and myopathy [6]. Recently, these complications have also been recognized among patients with COVID-19.

A few case reports have described COVID-19 infection in patients with pre-existing myasthenia gravis [2, 7–13]. However, to the best of our knowledge, there have been no reported cases of ocular myasthenia gravis being triggered by COVID-19 infection. Here, we describe the first such case and attempt to describe the clinical course, possible pathophysiological manifestations behind this presentation and briefly review the present literature on COVID-19 in Myasthenia patients.

## Case report

We present a case of a 65-year-old woman with a significant history of left renal cell carcinoma status post partial nephrectomy in 2018, pituitary adenoma with acromegaly status post partial resection in 1993 (on chronic prednisone replacement therapy), lung carcinoid, meningioma and history of pulmonary embolism on apixaban. She presented from an outside facility with 2 weeks of diarrhea, myalgia, and extreme fatigue and with 3 days of left eyelid ptosis. She tested positive for COVID-19 by nasopharyngeal RT-PCR testing and was found to have prior exposure to a COVID-19

positive family member. She denied any dyspnea, dysphagia, chewing fatigue or proximal weakness.

On examination, she had left eye ptosis that was fatigable and diplopia with vertical up-gaze after 20 s. She also had mild eye closure weakness. She reported generalized fatigue but there was no focal weakness on neurological examination. She had normal strength and normal reflexes. MG composite score was 4 (3 for ptosis and 1 for eye closure weakness).

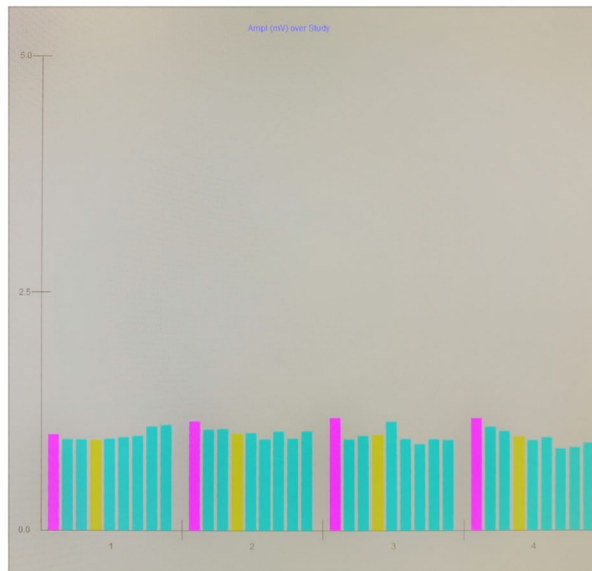
Extensive laboratory work revealed elevated inflammatory markers, including interleukin-6 at 3 pg/ml (normal  $\leq 1.8$ ), serum CRP 88.4 mg/l (normal  $< 0.8$ ), serum ferritin 966 ng/ml (normal 10–200 ng/ml), serum fibrinogen 546 mg/dl (normal 200–400 mg/dl), and D-dimer 521 ng/ml (normal  $< 232$  ng/ml). Acetylcholine receptor (AChR)-binding antibody (Ab) was positive with high titer 7.39 nmol/L (normal  $< 0.02$  nmol/l), striational Ab was positive with high titer 1:960 (normal  $< 1:120$ ), and AChR modulating Ab 78% (0–20% reported as normal percentage loss of AChR) along with negative anti-MuSK Ab.

EMG was performed on day 2 of hospitalization and was consistent with a neuromuscular transmission deficit with a decremental response on repetitive nerve stimulation test of left orbicularis oculi greater than 10% (seen on the fourth run) (refer to Fig. 1). The ice-pack test was positive. CT chest showed no pulmonary infiltrates and was negative for thymoma. Normal MRI of orbits ruled out infiltrative etiologies, and brain MRI was unremarkable. The paraneoplastic panel was negative and included antibodies against P/Q-type calcium channels and N-type calcium channels.

Based on the combination of findings from history, laboratory investigations and electrodiagnostic testing, she was diagnosed with seropositive ocular myasthenia gravis. The MG composite score for first admission was 3 (2 for ptosis and 1 for eye closure weakness). MG composite score during second admission was 0.

The patient was started on pyridostigmine 60 mg every 6 h on the third day of admission and she reported a subjective improvement in her diplopia and ptosis on day 4 of admission. However, she was still positive for COVID-19 at this time. She was discharged on pyridostigmine 60 mg q 6 h as home medications and with recommendations to home-quarantine and follow up at the neuromuscular clinic in 6 weeks.

Few days after discharge, the patient complained of nausea and diarrhea and also developed loss of taste and smell, presumably because of her COVID-19 infection. Eventually, she was transferred from an outside hospital for septic shock and had received ceftriaxone and azithromycin. She consistently required 4 L of oxygen due to respiratory compromise and received 1-unit convalescent plasma on day 4 after the second admission. A Neurology consult was placed with concerns of worsening myasthenia



### L Orbicularis oculi

Train	Amp mV	4-1 %	Time
Baseline	1.0	-5.8	0:00:00
@0:05	1.1	-12.2	0:01:37
@0:30	1.2	-15.2	0:02:11
@1:00	1.2	-16.4	0:03:16

**Fig. 1** EMG repetitive nerve stimulation test of the left orbicularis oculi (facial nerve). The fourth run of the repetitive nerve stimulation of the left orbicularis oculi (facial nerve) demonstrated reproducible decrement of greater than 10% consistent with neuromuscular junction transmission defect. *EMG* electromyography test

or an adverse reaction to pyridostigmine due to her gastrointestinal symptoms and respiratory compromise. However, absence of diarrhea during her initial hospital stay when she had started on pyridostigmine along with new findings on her chest X-ray of opacity in the left lung base and central consolidation within the right lung periphery, pointed more towards COVID-19-related symptoms than due to MG. She was placed in the prone position for 1 h at a time for 4 days, started on IV dexamethasone 6 mg and ultimately received 4 doses of IV dexamethasone. Her pyridostigmine dosage was reduced to 60 mg q 8 hours. She continued to have mild ptosis but no diplopia or any fatigable weakness.

She was eventually weaned to room air on day 10 of admission and no longer had any shortness of breath or cough. She had some episodes of asymptomatic sinus bradycardia with a heart rate approaching the low 40 s, which was likely due to dysautonomia that can be seen with COVID-19 [14]. Upon re-evaluation a month later, she had residual symptoms of COVID-19 and ocular MG.

## Discussion

There have been various case reports of COVID-19 infections in patients with pre-existing MG that have been published [7, 9]. To the best of our knowledge, currently there is only one reported case series of MG developing as a complication following COVID-19 infection [15]. However, the three patients described in this case series were that of generalized MG. In our case report, we describe a novel case of ocular MG developing after COVID-19 infection who responded well to a standard dose of pyridostigmine.

In our brief literature review, we reviewed 17 patients with known MG who were infected with COVID-19. All patients except one [10] were seropositive myasthenic patients on varying immunosuppressive therapies (majority on at least 2 agents, including pyridostigmine) and with varying disease status at the time of infection [7–9, 11–13, 16]. The patients were either continued on the same medication regimen during their COVID-19 infection or given an extra pulse dose of steroids or IVIG, depending on whether they were suffering from acute worsening of bulbar respiratory symptoms warranting further aggressive therapy. The majority of patients were discharged home or to rehab facilities, while two patients remained on mechanical ventilation [2, 7] (refer Table 1). Three patients, as described by Camelo-Filho et al. had a fatal outcome [16].

The patient described in our case report suffered from ocular symptoms and showed improvement with the pyridostigmine trial, which indicated that these findings were secondary to myasthenia, with an indirect perpetuation from COVID-19. During the COVID-19 pandemic, it has been established that neurological complications in the form of autoimmune reactions, such as Guillain-Barré syndrome (GBS) and MG, may be provoked. Along with the patient's underlying predilection for the disease due to genetic factors, environmental factors may also play a role, further instigated by the viral infection.

The underlying mechanism of the disease pathology has not been clearly established and requires further investigation. However, it is well known that there is a decrease in the availability of AchRs at the postsynaptic neuromuscular junction due to destruction by the antibodies and the inflammatory response, which plays a key role in the pathogenesis [3]. Antibodies produced by an inflammatory reaction to an external agent, such as a virus, can result in a triggered immune response that cross-reacts with the AchRs due to molecular resemblance leading to damage. COVID-19 has affinity to ACE-2 receptors, directly causing the formation of autoantibodies and leading to a significant inflammatory cascade [17]. The ACE-2 receptor is expressed in multiple different organs, such as

**Table 1** Review of published cases of COVID-19 and myasthenia gravis

Author	Article type	No. of pt	Lab tests	Management	Outcomes
Aksoy et al.	Case report	1	AchR Ab +ve, CRP/WBC elevation	Pyridostigmine (increased to 60 mg QID), favipiravir, MEM, OTV, HCQ (400 mg BID first day, afterwards 200 BID)—D/c then worsening symptoms added linezolid and IV methyl-prednisone 40 mg daily and plasma therapy	Complete recovery
Kushlaf et al.	Case report	1	MuSK Ab +ve	HCQ×5 days, TOZ, and IVIG 1 g/kg daily×2 consecutive days	Intermittent hemodialysis for renal failure. No symptoms suggestive of worsening of MG
Ramaswamy et al.	Case report	1	AchR Ab +ve, elevated WBC	pred 30 mg daily and MMF1000 mg BID (no changes in meds during COVID)	Complete recovery
Rein et al.	Case report	3	Not reported	PT 1: HCQ, lopinavir, ritonavir, increased pred dose and IVIG PT 2: PLEX switched for IVIG PT 3: No change in treatment	PT 1: non-invasive respiratory support. Discharged home PT 2: complete recovery PT 3: recovered at home
Hubers et al.	Case report	4	PT 1: AchR Ab +ve PT 2: AchR Ab +ve PT 3: negative PT 4: AchR Ab +ve	PT 1: AZA stopped; IVIG×5 days PT 2: no change in treatment PT 3: no change in treatment PT 4: increase in Pyridostigmine	PT 1: discharged home; anosmia, ageusia at 4 weeks PT 2: fluctuating headaches and respi symptoms over 6 weeks PT 3: resolved after 3 weeks PT 4: mechanical ventilation> 14 days, tracheostoma×9 weeks
Singh et al.	Case report	1	Elevated WBC, AST, ALT, LDH, ferritin, D-dimer	PLEX + stress steroids	Discharged after 1 month, persistent anosmia
Delly et al.	Case report	1	AchR Ab +ve	HCQ, steroids, IVIG	Discharged to SAR
Anand et al.	Short report	5	PT 1: AchR Ab +ve PT 2: AchR Ab +ve PT 3: AchR Ab +ve PT 4: MuSK Ab +ve PT 5: AchR Ab +ve	PT 1: HCQ 400 mg BID×1 day, 200 mg OD×2 days; AZM 500 mg OD×1 day, 250 mg OD×2 days; TOZ 300 mg×1 dose + AZA PT 2: HCQ 400 mg BID×1 day, 400 mg OD×4 days; AZM 500 mg OD×1 day, 250 mg OD×4 days; CTX 2 g OD×2 days, 1 g OD×3 days + pred 10 mg OD to 5 mg PT 3: HCQ 400 mg BID×1 day, 200 mg BID×4 days; AZM 500 mg OD×5 days, CTX 1 g OD×5 days; continued IVIG and reduced pred PT 4: pred increased, IVIG added PT 5: no change	PT 1: discharged home on day 9 PT 2: continued mechanical ventilation PT 3: discharged to skilled nursing facility on day 19 PT 4: discharged home on day 5 PT 5: discharged home on day 9

**Table 1** (continued)

Author	Article type	No. of pt	Lab tests	Management	Outcomes
Camelo-Filho et al.	Brief report	15	PT 1–4, 7–9, 11, 14,15: AchR Ab +ve PT 10: MuSK Ab +ve PT 5, 6, 12, 13: N/A	PT 1: pred 20 mg QD continued, CTX, AZM, OTV, AMK, TEC PT 2: pred 30 mg QD continued, CTX, AZM, TZP PT 3: pred 60 mg QD, AZA 250 mg QD, IVIg 2 g/kg added, CTX PT 4: pred increased to 40 mg/day, MTX 15 mg weekly, CTX PT 5: pred 5 mg QD, MTX withheld, CTX, OTV, MEM, CST, LZD PT 6: CLR, CTX, AZM,OTV PT 7: pred increased, 5 PLEX sessions, CCP withheld, CTZ AZM, TZP, MEM PT 8: pred increased, 4 PLEX sessions, AZA withheld, CTX, AZM, TZP PT 9: pred 5 mg QD, 5 PLEX sessions, AZA withheld, CTX, AZM PT 10: pred 60 mg QD, 5 PLEX sessions, CTX, AZM PT 11: pred increased to 20 mg/day, AZA 150 mg QD, AZM PT 12: pred increased, CTX, CLR, MEM, VAN PT 13: pred increased to 60 mg/day, AZA withheld, CTZ, AZM PT 14: pred increased, CTX, AZM, MEM, LZD, AMK, PMB PT 15: pred increased, CTX	PT 1: deceased PT 2: deceased PT 3: discharged home PT 4: remains hospitalised PT 5: remains hospitalised PT 6: deceased PT 7: discharged home PT 8: discharged home PT 9: discharged home PT 10: discharged home PT 11: I PT 12: deceased PT 13: discharged home PT 14: discharged home PT 15: discharged home
Restivo et al.	Case report	3	PT1-3: AchR Ab +ve	PT 1: Pyridostigmine 60 mg QD, pred 75 mg/day PT 2: IVIG 0.4 g/kg/day × 5 days PT 3: PLEX 3 sessions, Lopinavir/Ritonavir: 400/100 mg BID, HCQ 200 mg BID	N/A

*MEM* Meropenam, *OTV* Oseltamivir, *HCQ* Hydroxychloroquine, *TOZ* Tocilizumab, *MMF* Mycophenolate mofetil, *IVIG* Intravenous Immunoglobulin, *Pred* prednisone, *PLEX* Plasma Exchange, *AZA* Azathioprine, *AZM* Azithromycin, *CTX* Ceftriaxone, *OTV* Oseltamivir, *AMK* Amikacin, *TEC* Teicoplanin, *TZP* Piperacillin-tazobactam, *MTX* Methotrexate, *CST* Colistin, *LZD* Linezolid, *CLR* Clarithromycin, *CCP* Cyclosporin, *VAN* Vancomycin, *PMB* Polymyxin B

the lungs, kidneys, and liver. This produces proinflammatory cytokines and chemokines along with B and T cell depletion with increased levels of interleukins and TNF- $\alpha$ , which correlate with disease severity, and increased risk of cross-reactive autoimmune attack against our own body's receptors [17]. Myasthenia gravis antibody production is a B cell-dependent process and plays an important role in the loss of self-tolerance and dysregulation [3]. IL-6

is an inflammatory marker that is found in COVID-19 and MG which can be associated with a higher mortality rate in COVID-19 [18]. In our case, the patient had mild-to-moderate COVID-19 symptoms based on ATS/IDSA guidelines [19]. The ongoing inflammatory response along with the production of destructive reactive oxygen species can lead to ARDS and long-term pulmonary fibrosis.

There have also been reported cases of post-infectious myasthenia gravis that developed weeks after initial infection, associated with Varicella zoster, West Nile virus, and Zika virus [20–22]. In the literature review, post-COVID-19 infection, neuromuscular manifestations were found after 1 to 3 weeks [6, 23]. Our case had neuromuscular manifestations after 2 weeks of viral prodromal symptoms. It is possible that the MG manifestation in the patient may be a specific complication of the COVID-19 infection or a post-infectious emergence of MG. We expect to develop a better understanding of the pathophysiology behind this manifestation as more cases of COVID-19-associated MG are reported.

Treatment is targeted at symptomatic improvement with pyridostigmine and with immunosuppressive therapies (corticosteroids and long-term steroid-sparing agents) to control the production of antibodies and decrease the severity of disease [2, 4, 9]. Current guidelines from a panel of MG experts recommend tailoring treatment according to each individual patient with underlying comorbidities with the primary care provider and specialists; however, it is encouraged to continue the standard MG protocol during hospitalizations and continue immunosuppressive therapy [2, 4].

However, it should be noted that conclusions drawn from a single case are limited and can only suggest association. Observations from further cases will be needed to consolidate our findings. Another limitation of our study is absence of other immunological studies such a classification of lymphocyte subtypes.

## Conclusion

In summary, to our knowledge, this is the first reported case of ocular MG in a patient infected with COVID-19. Although COVID-19 typically presents with upper or lower respiratory symptoms, there have been reports of significant neurological complications.

Likely mechanisms for the development of MG are the molecular resemblance. An immune response triggered by prior infection cross-reacts with the autoantibody against neuromuscular junctions and causes damage. Some infectious agents are known to be associated mg, such as VZV, WNV, and Zika virus. MG should be considered a neurological complication of infection with COVID-19 that can present with ptosis and fatigability.

It is unclear whether COVID-19 could induce the production of antibodies against neuromuscular junctions triggering myasthenia gravis in COVID-19 patients. Further investigations should be conducted on the mechanism of MG in patients with COVID-19 in the future.

**Author contributions** Conceptualization: MT, SS. Drafting manuscript: MT, SS. Data abstraction: MT, SK, MD. Final edit: SS, SS.

**Funding** None.

**Availability of data and material** None.

## Compliance with ethical standards

**Conflicts of interest** All authors declare no potential conflicts of interest.

**Ethical approval** This is under compliance with institutional review board guidelines and approval IRB protocol number 2004958561.

**Informed consent** Informed consent from the patient was also obtained.

**Consent for publication** Available and IRB approved.

## References

- Meriggioli MN, Sanders DB (2009) Autoimmune myasthenia gravis: emerging clinical and biological heterogeneity. *Lancet Neurol* 8(5):475–490
- Hübers A, Lascano AM, Lalive PH (2020) Management of patients with generalised myasthenia gravis and COVID-19: four case reports. *J Neurol Neurosurg Psychiatry* 91(10):1124–1125
- Konecny I, Herbst R (2019) Myasthenia gravis: pathogenic effects of autoantibodies on neuromuscular architecture. *Cells* 8(7):671
- Guidon AC, Amato AA (2020) COVID-19 and neuromuscular disorders. *Neurology* 94(22):959–969
- Kim J-E et al (2017) Neurological complications during treatment of middle east respiratory syndrome. *J Clin Neurol* 13(3):227–233
- Tsai L-K et al (2004) Neuromuscular disorders in severe acute respiratory syndrome. *Arch Neurol* 61(11):1669–1673
- Anand P, Slama MC, Kaku M, Ong C, Cervantes-Arslanian AM, Zhou L, David WS, Guidon AC (2020) COVID-19 in patients with myasthenia gravis. *Muscle Nerve* 62(2):254–258
- Delly F et al (2020) Myasthenic crisis in COVID-19. *J Neurol Sci* 414:116888
- Rein N, Haham N, Orenbuch-Harroch E, Romain M, Argov Z, Vaknin-Dembinsky A, Gotkine M (2020) Description of 3 patients with myasthenia gravis and COVID-19. *J Neurol Sci* 417:117053
- Kushlaf H (2020) COVID-19 in muscle-specific kinase myasthenia gravis: a case report. *Muscle Nerve* 62(4):E65–E66. <https://doi.org/10.1002/mus.27020>
- Aksoy E, Oztutgan T (2020) COVID-19 presentation in association with myasthenia gravis: a case report and review of the literature. *Case Rep Infect Dis* 2020:1–4. <https://doi.org/10.1155/2020/8845844>
- Ramaswamy SB, Govindarajan R (2020) COVID-19 in refractory myasthenia gravis—a case report of successful outcome. *J Neuromusc Dis* 7(3):361–364. <https://doi.org/10.3233/JND-200520>
- Singh S, Govindarajan R (2020) COVID-19 and generalized myasthenia gravis exacerbation: a case report. *Clin Neurol Neurosurg* 196:106045. <https://doi.org/10.1016/j.clineuro.2020.106045>
- Eshak N, Abdelnabi M, Ball S, Elgwairi E, Creed K, Test V, Nugent K (2020) Dysautonomia: an overlooked neurological

- manifestation in a critically ill COVID-19 patient. *Am J Med Sci* 360(4):427–429. <https://doi.org/10.1016/j.amjms.2020.07.022>
15. Restivo DA, Centonze D, Alesina A, Marchese-Ragona R (2020) Myasthenia gravis associated with SARS-CoV-2 infection. *Ann Intern Med*. <https://doi.org/10.7326/L20-0845>
  16. Camelo-Filho AE et al (2020) Myasthenia gravis and COVID-19: clinical characteristics and outcomes. *Front Neurol* 11:1053
  17. Baig AM et al (2020) Evidence of the COVID-19 virus targeting the CNS: tissue distribution, host–virus interaction, and proposed neurotropic mechanisms. *ACS Chem Neurosci* 11(7):995–998
  18. Herold T et al (2020) Elevated levels of IL-6 and CRP predict the need for mechanical ventilation in COVID-19. *J Allergy Clin Immunol* 146(1):128–136.e4
  19. Metlay JP et al (2019) Diagnosis and treatment of adults with community-acquired pneumonia. An official clinical practice guideline of the American Thoracic Society and Infectious Diseases Society of America. *Am J Respir Crit Care Med* 200(7):e45–e67
  20. Felice KJ, DiMario FJ, Conway SR (2005) Postinfectious myasthenia gravis: report of two children. *J Child Neurol* 20(5):441–444
  21. Hawkes MA, Hocker SE, Leis AA (2018) West Nile virus induces a post-infectious pro-inflammatory state that explains transformation of stable ocular myasthenia gravis to myasthenic crises. *J Neurol Sci* 395:1–3
  22. Molko N et al (2017) Zika virus infection and myasthenia gravis: report of 2 cases. *Neurology* 88(11):1097–1098
  23. Ellul MA et al (2020) Neurological associations of COVID-19. *Lancet Neurol* 19(9):767–783