

Rituximab therapy in steroid-resistant severe hypothyroid Grave's ophthalmopathy

Aditi Pandit, Abhay Gundgurthi, Sandeep Kharb, Karninder S. Brar, M. K. Garg

Department of Endocrinology, Army Hospital (Research and Referral), Delhi Cantt, India

ABSTRACT

Association of Grave's ophthalmopathy with hyperthyroidism is well known, and it has also been reported in euthyroid or hypothyroid autoimmune thyroiditis, which rarely requires treatment. Here, we report a case of bilaterally symmetrical severe corticosteroid-resistant hypothyroid Grave's ophthalmopathy successfully treated with rituximab.

Key words: Grave's ophthalmopathy, hypothyroid ophthalmopathy, rituximab

INTRODUCTION

Grave's ophthalmopathy, also called thyroid associated orbitopathy (TAO), has existed for over centuries with mention found in the 12th century Persian medical writings.^[1] Its association with hyperthyroidism is well known, but 10% subjects have TAO associated with euthyroid or hypothyroid autoimmune thyroiditis.^[2] Euthyroid and hypothyroid TAO is milder and usually presents as asymmetrical eye involvement.^[3] It is a complex autoimmune process related to the orbital autoantigens like thyroid stimulating hormone receptor (TSHR), calsequestrin, collagen XIII, flavoprotein, and insulin like growth factor-1 (IGF-1).^[4,5] The treatment of inflammatory TAO has not advanced appreciably over decades. High dose corticosteroids alone or in combination with orbital radiation remain imperfect option due to recurrences.^[1,2] Rituximab (RTX), a monoclonal B cell antibody targeting CD20, which depletes the B cells, has been used in hyperthyroid Grave's ophthalmopathy.^[6-8] Here, we report a case of bilaterally symmetrical severe corticosteroid

resistant hypothyroid Grave's ophthalmopathy (HypoGO) treated with RTX.

CASE REPORT

A 45-year-old reformed smoker was diagnosed as a case of primary hypothyroidism in 2001. Patient was started on thyroxine replacement therapy. Presently, he reported in May 2011 with swelling and redness of right eye followed by left eye for 2 months, associated with diplopia. He was clinically euthyroid with bilateral congestive TAO. His clinical activity score (CAS) was 6/7 with presence of eyelid edema and erythema, spontaneous retrobulbar pain, conjunctival chemosis, and caruncle injection with edema, with moderate to severe European Groups of Graves' Orbitopathy (EUGOGO) severity [Figure 1]. His NOSPECS score was 5. Hertel's exophthalmometry revealed proptosis of 18 mm and 19 mm, respectively. Lid aperture was 1.4 cm in both eyes. There was restriction of abduction bilaterally with convergence insufficiency. His vision was 6/9 in both eyes with defective green color vision, with normal intraocular pressure (IOP) and normal fundoscopy. Other systemic examination was within normal limits. He had no clinical evidence of any other autoimmune disease. His thyroid function tests were normal (T3, 2.97 pg/ml; T4, 1.44 ng/dl; TSH, 0.492 μ IU/ml) on replacement therapy. His anti-TPO (2226.80 u/ml; normal <9 u/ml) and TSHR (42.3 IU/l; normal <14 IU/l) antibodies were high. All his biochemical and hematological investigations

Access this article online

Quick Response Code:



Website:
www.ijem.in

DOI:
10.4103/2230-8210.109669

Corresponding Author: Prof. Col. M. K. Garg, Department of Endocrinology, Army Hospital (Research and Referral), Delhi Cantt-10, India.
E-mail: mkgargs@gmail.com

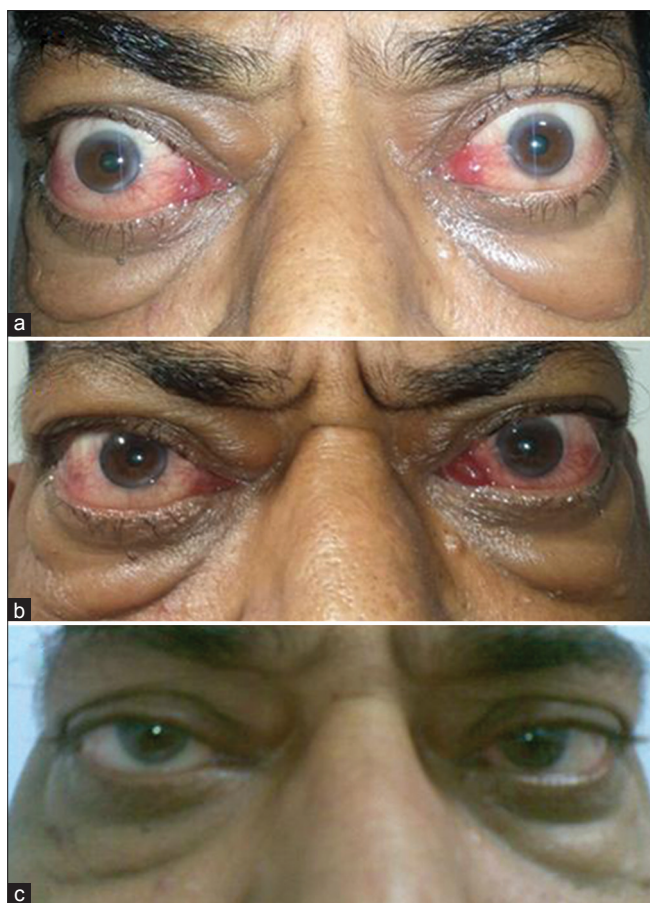

Figure 1: (a) Eye signs in pre-steroid stage. (b) Minimal change post-steroid. (c) Regression of eye signs following rituximab therapy

were normal. Magnetic resonance imaging (MRI) orbit revealed symmetrically diffuse increased bulk of bilateral extraocular muscles involving the muscle bellies with evidence of bilateral axial proptosis with sparing of tendons and with increased signal intensity. In view of severe active eye disease, he was given 12 doses of injection methylprednisolone. (1st 6 weeks 500 mg weekly followed by 250 mg weekly for 6 weeks).^[9] After 12 weeks of steroid therapy, the patient reported with worsening of visual acuity (right eye – 6/18, left eye – 6/12) and CAS of 5/7 [Figure 1] and NOSPECS score of 6. His IOP in both eyes had increased to 18 mm Hg. His repeat MRI orbit showed compression at the orbital apex due to crowding. T2 relaxometry measurements in the muscles were on average 175 ms on the right and 145 ms on the left. Ratio with the temporalis muscle was 4.26 on the right side and 4.02 on the left side [Figure 2]. In view of his worsening clinical status after 12 weeks of steroid therapy, the options left were orbital radiotherapy or orbital decompressive surgery. Since there were reports of utility of RTX in hyperthyroid Grave's ophthalmopathy,^[6-10] we decided to give the patient a trial of RTX therapy with oral prednisolone after informed consent was obtained from the

patient. Patient was screened for hepatitis B, C, and human immunodeficiency virus (HIV), and any underlying active infection and tuberculosis before RTX therapy. Patient was given two infusions of 1 g infusion of RTX 2 weeks apart with prednisolone (60 mg/day). Two weeks after the RTX therapy, the CAS improved to 1/7 in both eyes (only mild caruncle edema was present) with subjective improvement in visual acuity [Figure 1]. During the follow-up, 2 months post-RTX therapy, the patient had a CAS score of 1/7. The patient developed community-acquired pneumonia 2 months after therapy when he was due for re-evaluation. He was admitted and diagnosed as *Pneumocystis jirovecii* infection. He did not respond to therapy and developed type-1 respiratory failure requiring ventilatory support. He died on the seventh day of admission due to multi-organ system failure. Hence, post-RTX evaluation could not be completed.

DISCUSSION

About 10% of TAO is seen in euthyroid and hypothyroid patients.^[2] However, T'jiang, *et al.*^[11] reported high prevalence of eye signs (34%) in patients with Hashimoto's thyroiditis. Involvement of eye has also been reported in subjects with hypothyroidism on various drugs, namely thiazolidinedione,^[12] lithium,^[13] ipilimumab alone or combined with bevacizumab therapy.^[14] Most patients of hypothyroid and euthyroid Grave's ophthalmopathy present as asymmetrical ophthalmopathy with little soft tissue involvement with low titers of TSHR antibodies and anti-TPO antibodies.^[3] But our patient presented with bilaterally symmetrical eye disease with prominent soft tissue involvement, high titers of TSHR and anti-TPO antibodies in euthyroid state, and no history of drug intake except thyroxine. However, a recent study reported no difference in demographic, clinical characteristics and severity among TAO patients with hyperthyroidism or hypothyroidism.^[15]

TAO is thought to be due to the immunological cross-reactivity between thyroid and orbital tissue antigens like TSHR, caldesmon, collagen XIII, and flavoprotein, IGF-1. Circulating TSHR antibodies have been found to be correlated with the clinical activity of TAO. This probably explains the clinically severe eye disease in our patient who had high circulating levels of TSHR antibodies.^[4]

HypoGO rarely requires therapy except thyroxine replacement therapy.^[3,16] After extensive review of literature; we could find few case reports of HypoGO requiring therapy.^[17-21] Similar to our case, Ciric, *et al.*^[17] described a case who developed ophthalmopathy with slight proptosis, moderate palpebral edema, conjunctival

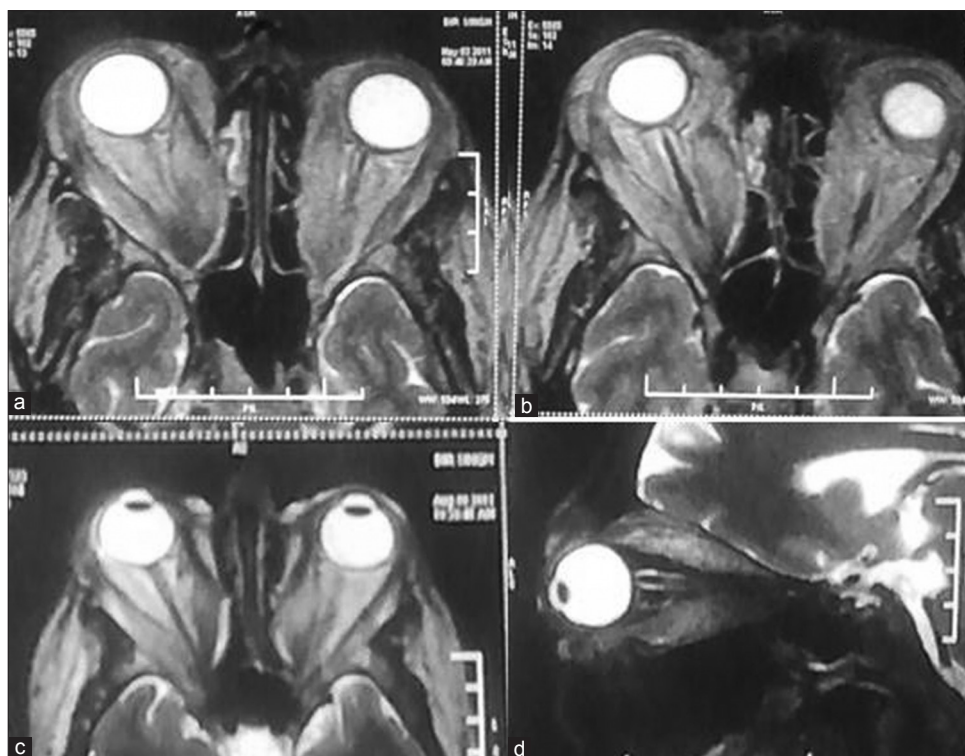


Figure 2: (a and b) MRI orbit showing symmetrically diffuse increased bulk of extraocular muscles with increased signal intensity in pre-steroid stage. (c and d) Minimal change post-steroid with compression at the orbital apex due to crowding

injection and chemosis, reduction of visual acuity, diplopia, and secondary glaucoma in euthyroid stage following thyroxine replacement therapy for primary hypothyroidism. They treated him with two doses of 0.5 g intravenous methylprednisolone for 3 days, followed by oral prednisone 40 mg/day tapered to 10 mg/day in 4 weeks. Patients responded with six courses of therapy. One of the earliest reports of treatment of HypoGO was by Hiromatsu, *et al.*^[13] in which they reported improvement of eye signs after pulse methylprednisolone therapy and decrease in anti-TSH receptor antibodies. Grzesiuk, *et al.*^[18] observed remission of ophthalmic symptoms with methylprednisolone pulse therapy and levothyroxine in a case of HypoGO with extremely high titers of TSHR antibodies. Rajput, *et al.*^[19] reported two cases of infiltrative ophthalmopathy with primary hypothyroidism treated with levothyroxine alone or in combination with steroids. Tambe, *et al.*^[20] described two hypothyroid patients with Grave's ophthalmopathy in a series of 38 patients treated with oral prednisolone over 1 month following intravenous methylprednisolone. Recently, Razenberg, *et al.*^[21] reported four cases of HypoGO; among them, two required steroid therapy. Our patient had a high CAS, hence was given intravenous methylprednisolone pulse therapy according to the current EUGOGO guidelines.^[9] Despite this, the patient, rather than showing improvement in CAS, had deteriorated with

decrease in the visual acuity and increase in IOP. His repeat MRI also suggested deterioration. The established methods of treatment with oral or intravenous glucocorticoids, orbital radiation, and surgical decompression do not halt the natural progression of this disease and improvement of quality of life after therapy remains modest.^[22] Considering adverse impact of orbital radiation and surgery, we decided to offer him RTX therapy.

RTX, a mouse human chimeric monoclonal antibody against CD20 protein on pre-B cells and mature B lymphocytes, blocks the B cell activation and differentiation without affecting B cell regeneration from stem cells or immunoglobulin production by plasma cells.^[23] Initially used in the treatment of B cell lymphomas, it subsequently proved useful in a variety of autoimmune diseases.^[24] The rationale behind the use of RTX in these diseases was the putative role of autoantibodies in the pathogenesis of these diseases. The possible mechanisms in the mostly T cell mediated TAO is probably that RTX abolishes the antigen presenting function of B cells. Natural history of TAO consists of an active phase lasting a relatively limited duration (6-18 months) and followed by clinical stabilization.^[10] RTX causes a transient B cell depletion for 4-6 months, which may affect the clinically active phase of TAO and the further clinical course. Chong, *et al.* in a retrospective

case series reported the beneficial effects of RTX in six patients of glucocorticoid-resistant hyperthyroid TAO with improvement in orbital inflammation and dysthyroid optic neuropathy without effect on proptosis and strabismus, suggesting the potential use of RTX as salvage therapy.^[6] RTX with systemic steroid therapy has been shown to reduce TAO activity and severity over 30 weeks in an open label study.^[10] The side effects of RTX reported in studies examining RTX therapy in TAO are of varying prevalence and severity. Few of the patients developed hypotension, febrile illness, sinus tachycardia, and serum sickness. Some of the late side effects reported were polyarthritis, ulcerative colitis, and urinary tract infection. One death has been reported following sudden cardiac arrest 3 months post second infusion.^[8] A series of six cases of *Pneumocystis jirovecii* pneumonia (PCP) in 46 lymphoma patients treated with RTX and chemotherapy was reported by Kolstad, *et al.*^[25] However, fatal results due to PCP have been reported after RTX therapy in a patient with rheumatoid arthritis who was also on steroid and methotrexate therapy^[26] and a patient with posterior scleritis.^[27] Another study reported no increase in the incidence of PCP in patients of lymphoma receiving RTX on adequate PCP prophylaxis.^[28]

Armed with these reports, we had given RTX with oral prednisolone dose in the present case with remarkable improvement in CAS; however, even though the patient reported improvement in CAS, he succumbed to *P. jirovecii* infection prior to repeat investigations, 2 months post-RTX therapy. A repeat MRI, which could not be done, may have indicated improvement in the form of decrease in the signal intensity ratio, T2 relaxometry, and extraocular muscle edema.^[29,30] Recently, one phase I/II clinical trial assessed the efficacy and safety of RTX-mediated B-lymphocyte depletion as treatment for thyroid eye disease.^[31] To the best of our knowledge, this is the first case where RTX has been used in steroid-resistant HypoGO. However, sudden demise due to community-acquired infection with underlying immune compromised status has dampened our enthusiasm and indicated caution against its use.

CONCLUSIONS

Current therapies are less than satisfactory for the treatment of Grave's ophthalmopathy. The improvement in the quality of life after the established therapy remains less than satisfactory. Hence, we suggest that RTX therapy can be used in treatment of thyroid associated ophthalmopathy in severe corticosteroid resistant eye disease as a second line of therapy, though one should be aware of the side effects and risk associated with the therapy.

REFERENCES

- Burch H, Wartofsky L. Grave's ophthalmopathy: Current concepts regarding pathogenesis and management. *Endocr Rev* 1993;14:747-93.
- Bartelena L, Tanda ML. Grave's ophthalmopathy. *N Engl J Med* 2009;360:994-1001.
- Eckstein AK, Losch C, Glowacka D, Schott M, Mann K, Esser J, *et al.* Euthyroid and primarily hypothyroid patients develop milder and significantly more asymmetrical Grave's Ophthalmopathy. *Br J Ophthalmol* 2009;93:1052-6.
- Lahooti H, Parmar KR, Wall JR. Pathogenesis of thyroid-associated ophthalmopathy: Does autoimmunity against caldesmon and collagen XIII play a role? *Clin Ophthalmol* 2010;4:417-25.
- Douglas RS, Naik V, Hwang CJ, Afifiyan NF, Gianoukakis AG, Sand D, *et al.* B cells from patients with Graves' disease aberrantly express the IGF-1 receptor: Implications for disease pathogenesis. *J Immunol* 2008;181:5768-74.
- Chong KL, Khanna D, Afifiyan NF, Hwang CJ, Lee DK, Garneau HC, *et al.* Rituximab treatment of patients with severe, corticosteroid-resistant thyroid-associated Ophthalmopathy. *Ophthalmology* 2010;117:133-9.
- El Fassi D, Nielsen CH, Bonnema SJ, Hasselbalch HC, Hegedus L. B Lymphocyte depletion with the monoclonal antibody rituximab in Graves' disease: A controlled pilot study. *J Clin Endocrinol Metab* 2007;92:769-1772.
- Hegedus L, Smith T, Douglas RS, Nielsen CH. Targeted biological therapies for Graves' disease and thyroid-associated ophthalmopathy. Focus on B-cell depletion with Rituximab. *Clin Endocrinol (Oxf)* 2011;74:1-8.
- Bartelena L, Baldeschi L, Dickinson A, Eckstein A, Kendall-Taylor P, Marcocci C, *et al.* Consensus statement of the European Group on Graves' orbitopathy (EUGOGO) on management of GO. *Eur J Endocrinol* 2008;158:273-85.
- Salvi M, Vannucchi G, Campi I, Currò N, Dazzi D, Simonetta S. Treatment of Graves' disease and associated Ophthalmopathy with the anti-CD20 monoclonal antibody rituximab: An open study. *Eur J Endocrinol* 2007;156:33-40.
- Tjiang H, Lahooti H, McCorquodale T, Parmar KR, Wall JR. Eye and eyelid abnormalities are common in patients with Hashimoto's thyroiditis. *Thyroid* 2010;20:287-90.
- Menaka R, Sehgal M, Lakshmi M, Bhattacharyya A. Thiazolidinedione precipitated thyroid associated ophthalmopathy. *J Assoc Physicians India* 2010;58:255-7.
- Hiromatsu Y, Sato M, Tanaka K, Nonaka K, Kojima K, Sato K, *et al.* Anti-eye muscle antibodies and hypothyroid Graves' disease: A case report. *Endocrinol Jpn* 1992;39:593-600.
- Min L, Vaidya A, Becker C. Thyroid autoimmunity and ophthalmopathy related to melanoma biological therapy. *Eur J Endocrinol* 2011;164:303-7.
- Kashkoul MB, Pakdel F, Kiavash V, Heidari I, Heirati A, Jam S. Hyperthyroid vs hypothyroid eye disease: The same severity and activity. *Eye (Lond)* 2011 Aug 5. doi: 10.1038/eye.2011.186pubmed, assessed on 08 November 2011.
- Brownlie BE, Newton OA, Singh SP. Ophthalmopathy associated with primary hypothyroidism. *Acta Endocrinol (Copenh)* 1975;79:691-9.
- Ciric J, Zarkovic M, Beleslin B, Stojkovic M, Savic S, Trbojevic B. Hypothyroid Graves' ophthalmopathy: A case report. *Endocrine Abstracts* 2007;14:P370.
- Grzesiuk W, Szydlarska D, Pragacz A, Bar-Andziak E. Thyroid-associated orbitopathy in patients with Hashimoto's thyroiditis: A case report. *Pol Arch Med Wewn* 2008;118:318-21.
- Rajput R, Dhingra A, Kumar K, Sen J. Infiltrative ophthalmopathy and

- primary hypothyroidism: A rare clinical manifestation of a common disease. *Postgrad Med J* 2009;85:40-2.
20. Tambe K, Bhargava J, Tripathi A, Gregory M, Burns J, Sampath R. The role of intravenous methylprednisolone immunosuppression in the management of active thyroid eye disease. *Orbit* 2010;29:227-31.
 21. Starrenburg-Razenberg AJ, Cabezas CM, Gan IM, Njo TL, Rietveld AP, Elte JW. Four patients with hypothyroid Graves' disease. *Neth J Med* 2010;68:178-80.
 22. Watt T, Groenvold M, Rasmussen AK, Bonnema SJ, Hegedu L, Bjorner JB, *et al.* Quality of life in patients with benign thyroid disorders. A review. *Eur J Endocrinol* 2006;154:501-10.
 23. Silverman GJ, Weisman S. Rituximab therapy and autoimmune disorders: Prospects for anti-B cell therapy. *Arthritis Rheum* 2003;48:1484-92.
 24. Nielsen CH, El Fassi D, Hasselbalch HC, Bendtzen K, Hegedüs L. B-cell depletion with rituximab in the treatment of autoimmune diseases. Graves' ophthalmopathy the latest addition to an expanding family. *Expert Opin Biol Ther* 2007;7:1061-78.
 25. Kolstad A, Holte H, Fossa A, Lauritzen GF, Gaustad P, Torfoss D. *Pneumocystis jirovecii* pneumonia in B-cell lymphoma patients treated with the rituximab-CHOEP-14 regimen. *Haematologica* 2007;92:139-40.
 26. Teichmann LL, Woenckhaus M, Vogel C, Salzberger B, Scholmerich J, Fleck M. Fatal *Pneumocystis* pneumonia following rituximab administration for rheumatoid arthritis. *Rheumatology* 2008;47:1256-7.
 27. Stilling-Vinther MK, Pedersen BS. Fatal *Pneumocystis jirovecii* pneumonia following immunosuppressive therapy with rituximab and prednisolone for posterior scleritis. *Acta Ophthalmol* 2011 Jun 8. doi: 10.1111/j. 1755-3768.2011.02127.x. pubmed assessed on 8 November 2011.
 28. Isidori A, Merli F, Angrilli F, Ferrara F, Alesiani F, Visani G. The incidence of *Pneumocystis jirovecii* pneumonia is not higher in patients receiving dose-dense therapy with rituximab, cyclophosphamide, non-pegylated liposomal doxorubicin, vincristine, and prednisolone and adequate *Pneumocystis jirovecii* pneumonia prophylaxis. *Leuk Lymphoma* 2011;52:148-9.
 29. Endre VN, Judit T, Kaldi I, Damjanovich J, Mezosi E, Lenkey A, *et al.* Graves' ophthalmopathy: Eye muscle involvement in patients with diplopia. *Eur J Endocrinol* 2000;142:591-7.
 30. Kirsch E, Hammer B, Arx G. Graves' orbitopathy: Current imaging procedures. *Swiss Med Wkly* 2009;139:618-23.
 31. Silkiss RZ, Reier A, Coleman M, Lauer SA. Rituximab for thyroid eye disease. *Ophthal Plast Reconstr Surg* 2010;26:310-4.

Cite this article as: Pandit A, Gundgurthi A, Kharb S, Brar KS, Garg MK. Rituximab therapy in steroid-resistant severe hypothyroid Grave's ophthalmopathy. *Indian J Endocr Metab* 2013;17:344-8.

Source of Support: Nil, **Conflict of Interest:** No.