

## Successful surgical management of an extrahepatic biliary cystadenocarcinoma

Sergio Renato Pais-Costa,<sup>1</sup>  
Sandro J. Martins,<sup>1,2</sup> Sergio L. M. Araújo,<sup>1</sup>  
Olímpia A. T. Lima,<sup>1,2</sup> Marcio A. Paes,<sup>1</sup>  
Marcio L. Guimarães,<sup>1</sup>

<sup>1</sup>Hospital Santa Lucia and <sup>2</sup>Medical School at the University of Brasília, Brasília, Brazil

### Abstract

Extrahepatic bile duct cancer is an uncommon disease, and few cases are curable by surgery. We report a case of extrahepatic biliary cystadenocarcinoma (BCAC) associated with atrophy of the left hepatic lobe. A 54-year old male was admitted with painless obstructive jaundice and a hepatic palpable mass noticed one month before presentation. Liver functions tests were consistent with cholestatic damage and serum carbohydrate antigen 19.9 (CA 19-9) was increased before treatment. Magnetic resonance imaging (MRI) disclosed dilatation of the left hepatic bile duct with irregular wall thickening close to the hepatic confluence, and atrophy of left hepatic lobe. The patient was submitted to en bloc extended left hepatectomy with resection of caudate lobe, hilar lymphadenectomy, and suprapancreatic biliary tree resection. All surgical margins were grossly negative, and postoperative course was uneventful, except for a minor bile leak. The patient was discharged on the 15th postoperative day; he is alive without tumor recurrence one year after primary therapy. Although technically challenging, extended en bloc resection is feasible in adults with extrahepatic BCAC and can improve survival with acceptable and manageable morbidity.

### Introduction

Extrahepatic bile duct cancer is an uncommon disease, and few cases are curable by surgery. Prognosis depends in part on the tumor's anatomic location, which affects its resectability with complete resection feasible in 25% to 30% of lesions from distal bile duct, a resectability rate clearly better than attained in lesions at more proximal sites.<sup>1-3</sup> Adenocarcinoma comprises the most common histology of bile duct cancer, and biliary cystadenocarcinoma (BCAC) is a quite rare entity.<sup>4</sup>

BCAC often occurs as slow growing lesion in the liver parenchyma and is difficult to distin-

guish from its benign counterpart, biliary cystadenoma. In addition, BCAC radiologically resembles simple hepatic cysts, mainly when unilocular, hydatid cysts, and a number of metastatic tumors that undergo cystic degeneration. Extrahepatic BCAC have unique traits with specialized treatment needs.<sup>2,5,6</sup>

We describe a case of extrahepatic BCAC localized close to the hepatic duct confluence. The patient successfully underwent successfully an en bloc suprapancreatic biliary tract resection with left hepatectomy plus caudate lobectomy.

### Case Report

An otherwise healthy 54-year-old Caucasian male was admitted to the surgical ward due to painless obstructive jaundice and a hepatic palpable mass which was noticed one month before presentation. Serum bilirubin (241 µmol/L), alkaline phosphatase (1067 U/L) and gamma glutamyl transferase (550 U/L) were markedly elevated; serum aspartate aminotransferase (175 U/L) and alanine aminotransferase (143 U/L) were only mildly elevated. Serum levels of carcinoembryonic antigen and alpha-fetoprotein were normal, but CA 19-9 was elevated (345 U/L). A CT scan showed a cystic lesion with irregular wall thickening near the hepatic hilum, dilated intrahepatic bile ducts, and atrophy of the left hepatic lobe. A magnetic resonance cholangiogram showed dilatation of intrahepatic biliary tree, predominantly at the left side, absence of duct stones, and bile duct with irregular wall thickening close to the hepatic confluence (Figure 1).

There were no suspicious findings of locoregional or systemic dissemination in imaging studies. Provisional diagnoses of biliary cystadenoma, hilar cholangiocarcinoma (T3N0M0, stage IIIA) or extrahepatic bile duct cancer (T3N0M0, stage IIA) were made, and the lesion was deemed resectable. Surgery consisted of suprapancreatic biliary tree resection, including hepatic duct confluence, hilar lymphadenectomy, and en bloc extended left hepatectomy with caudate lobectomy. All surgical margins were negative. A histopathological examination showed cystadenocarcinoma arising from the left hepatic duct (Figure 2). The immunohistochemical analysis for CEA, cytokeratin 19 and CA 19-9 showed positive staining at the tumor level. Postoperative course was uneventful, except for a minor bile leak requiring no therapy. The patient was discharged on the 15th postoperative day and no postoperative adjuvant therapy was necessary. He is alive without tumor recurrence one year after the primary therapy.

Correspondence: Sandro J. Martins, AOS 2, Bl B, apt 202, CEP 70660-022, Brasília – DF, Brazil.  
Fax: +55.21.3956.9426.  
E-mail: sjmartins@yahoo.com

Key words: biliary tract neoplasms, biliary tract surgical procedure, cystadenocarcinoma.

Received for publication: 8 January 2011.

Accepted for publication: 4 August 2011.

This work is licensed under a Creative Commons Attribution NonCommercial 3.0 License (CC BY-NC 3.0).

©Copyright S.R. Pais-Costa et al., 2011  
Licensee PAGEPress, Italy  
Rare Tumors 2011; 3:e36  
doi:10.4081/rt.2011.e36

### Discussion

Biliary cystoadenocarcinoma is a rare, indolent disease typically diagnosed in middle-aged people. It predominantly affects women and has a less favorable outcome among men.<sup>4,7</sup> At diagnosis, patients with intrahepatic BCAC often present for evaluation of an abdominal mass or regional pain, but cholestasis is a frequent and early feature in extrahepatic BCAC.<sup>8-11</sup> Extrahepatic BCAC can cause asymmetric bile duct dilatation and secondary segmental hepatic atrophy due to adjacent tumor compression or invasion of the left portal vein, pressure atrophy of hepatic cells, or bile salt toxicity.<sup>12,13</sup>

Tumor arises more frequently from the hepatic confluence or sectoral bile ducts than from the gallbladder.<sup>7,10,14</sup> Endoscopic retrograde cholangiopancreatography (ERCP) ERCP is no longer a decisive component in diagnostic work-up as non-invasive modalities clearly elucidate location and extent of disease. Imaging studies usually reveal multilocular cystic lesions with internal septations and nodularities, but a unilocular lesion may be observed as in this case.<sup>5,15,16</sup> Some authors have suggested that presence of nodules or coarse calcifications along the duct wall or septa increases the odds in favor of BCAC.<sup>15,17</sup>

CA19-9 and CEA serum levels can be used in conjunction with radiological methods to determine tumor resectability: normal marker levels assure resectability in half of cases, while elevated CA 19-9 (>1000 U/mL) and CEA (>14.4 ng/mL) strongly suggest unresectable disease.<sup>18</sup> The differential diagnosis includes biliary cystadenoma, cholangiocarcinoma and, less commonly, benign papilloma, carcinoma tumor, villous tumor, neurofibroma, and plasmacytoma. Besides intraductal neoplasm, the differential diagnosis of regional biliary

Table 1. Surgical management of extrahepatic biliary cystadenocarcinoma in the literature.

Author	Cases (n)	Age/gender	Presentation	Procedure	Follow-up
Owono <i>et al.</i> <sup>9</sup>	3	62-67 y/ 2F:1M	Cholangitis	Hepatectomy	21-134 mo, two recurrences.
Tseng <i>et al.</i> <sup>13</sup>	1	68 y/ F	Cholangitis	Hepatectomy + BDR	Not informed.
Devaney <i>et al.</i> <sup>7</sup>	3	59 y/ 2F:1M	Jaundice	Hepatectomy + BDR	18-40 mo, two recurrences.
Erdogan <i>et al.</i> <sup>8</sup>	1	39 y/ F	Jaundice	Hepatectomy + BDR	59 mo, no recurrence.
Present case	1	54 y/ M	Jaundice	Hepatectomy + BDR	12 mo, no recurrence.

BDR, bile duct resection plus intra-hepatic bilioenteric bypass.

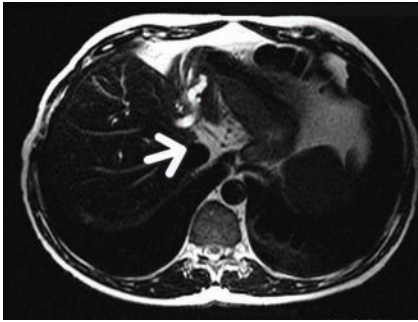


Figure 1. Magnetic resonance imaging showed predominant dilatation of the left biliary tree, atrophy of left hepatic lobe particularly lateral segment, and wall thickening near hepatic duct confluence (arrow).

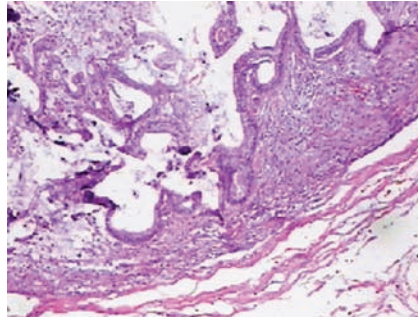


Figure 2. Neoplastic epithelia with acidophilic cytoplasm cover the papillary structure of this tumor, and the stroma of these papillae are edematous and myxoid. The neoplastic epithelia are artificially desquamated. HE, x150.

ductal obstruction includes calculus disease, sclerosing cholangitis, metastatic disease, hepatoma, and hepatic cysts.<sup>4,9,19</sup> In this case, radiological findings of asymmetric bile duct dilatation in the absence of identifiable calculi and segmental hepatic atrophy favor a diagnosis of an intraductal neoplasm, such as hilar cholangiocarcinoma or extrahepatic bile duct cancer.

Histology of BCAC is characterized by moderate mitotic activity seen in papillary projections of stratified cells lining the foci of dysplasia.<sup>7,10</sup> Tumor specimen may show areas of frank stromal invasion, oncocytic differentiation, have an endocrine cell component, and coexist with benign cystic structures.<sup>20,21</sup> Almost exclusively in females the underlying layer of connective tissue shows a distinctive aspect with increased stromal cellularity, closely resembling ovarian stroma.<sup>7,17</sup> Rarely the malignant epithelial cells exhibit a spindle-shaped pseudosarcomatous morphology.<sup>22</sup> Most tumor cells are positive on immunohistochemical staining for tissue polypeptide antigen, cytokeratin, CA 19-9, and CEA.<sup>7,10,23</sup> Devaney *et al.*<sup>7</sup> noticed a favorable prognosis for tumors with *ovarian-like* stroma, when compared to those predominantly seen in males having notably inconspicuous stromal features and increased propensity for locoregional dissemination.

Surgery is the mainstay of curative treatment in localized extrahepatic bile duct cancer.<sup>1,24</sup> The optimum surgical procedure (Table

1) will vary according to tumor location along the biliary tree, involvement of normal liver parenchyma, and the proximity of the tumor to major blood vessels in this region (Table 1). En bloc resection as performed may be necessary to attain free surgical margins and favorable outcome, as partial resection has been associated to high rates of recurrence and dismal prognosis.<sup>1,2,6</sup> Cytotoxic chemotherapy, targeted therapy, and radiation therapy have no proven role in the management of BCAC patients.

## Conclusions

Although technically challenging, extensive hepatobiliary resection is feasible in adults with extrahepatic BCAC, and can offer long-term survival with acceptable and manageable morbidity. Early recognition of clinical and radiological features of rare tumors arising in bile ducts enables the early diagnosis and successful treatment.

## References

1. Chouillard E, Gumbs A, Fangio P, et al. Liver resection for cystic lesions: a 15-year experience. *Minerva Chir* 2010;65:495-506.

2. Hai S, Hirohashi K, Uenishi T, et al. Surgical management of cystic hepatic neoplasms. *J Gastroenterol* 2003;38:759-64.
3. Lauffer JM, Baer HU, Maurer CA, et al. Biliary cystadenocarcinoma of the liver: the need for complete resection. *Eur J Cancer* 1998;34:1845-51.
4. Tucek S, Tomasek J, Halamkova J, et al. Bile duct malignancies. *Klin Onkol* 2010; 23:231-41.
5. Seo JK, Kim SH, Lee SH, et al. Appropriate diagnosis of biliary cystic tumors: comparison with atypical hepatic simple cysts. *Eur J Gastroenterol Hepatol* 2010;22:989-96.
6. Madariaga JR, Iwatsuki S, Starzl TE, et al. Hepatic resection for cystic lesions of the liver. *Ann Surg* 1993;218:610-4.
7. Devaney K, Goodman ZD, Ishak KG. Hepatobiliary cystadenoma and cystadenocarcinoma. A light microscopic and immunohistochemical study of 70 patients. *Am J Surg Pathol* 1994;18:1078-91.
8. Erdogan D, Busch OR, Rauws EA, et al. Obstructive jaundice due to hepatobiliary cystadenoma or cystadenocarcinoma. *World J Gastroenterol* 2006;12:5735-8.
9. Owono P, Scoazec JY, Valette PJ, et al. Hepatobiliary cystic tumors. Clinical, radiological and histopathological study of 7 cases. *Gastroenterol Clin Biol* 2001;25:414-21.
10. Nakajima T, Sugano I, Matsuzaki O, et al. Biliary cystadenocarcinoma of the liver. A clinicopathologic and histochemical evaluation of nine cases. *Cancer* 1992;69:2426-32.
11. Yu Q, Chen T, Wan YL, et al. Intrahepatic biliary cystadenocarcinoma: clinical analysis of 4 cases. *Hepatobiliary Pancreat Dis Int* 2009;8:71-4.
12. Trauner M, Fickert P, Halilbasic E, Moustafa T. Lessons from the toxic bile concept for the pathogenesis and treatment of cholestatic liver diseases. *Wien Med Wochenschr* 2008;158:542-8.
13. Tseng CA, Pan YS, Chen CY, et al. Biliary cystadenocarcinoma associated with atrophy of the left hepatic lobe and hepatolithiasis mimicking intrahepatic cholangiocarcinoma: a case report. *Kaohsiung J Med Sci* 2004;20:198-203.
14. Davies W, Chow M, Nagorney D. Extrahepatic biliary cystadenomas and cystadenocarcinoma. Report of seven cases and

- review of the literature. *Ann Surg* 1995; 222:619-25.
15. Korobkin M, Stephens DH, Lee JK, et al. Biliary cystadenoma and cystadenocarcinoma: CT and sonographic findings. *AJR Am J Roentgenol* 1989;153:507-11.
  16. Choi BI, Lim JH, Han MC, et al. Biliary cystadenoma and cystadenocarcinoma: CT and sonographic findings. *Radiology* 1989; 171:57-61.
  17. Buetow PC, Buck JL, Pantongrag-Brown L, et al. Biliary cystadenoma and cystadenocarcinoma: clinical-imaging-pathologic correlations with emphasis on the importance of ovarian stroma. *Radiology* 1995; 196:805-10.
  18. Juntermanns B, Radunz S, Heuer M, et al. Tumor markers as a diagnostic key for hilar cholangiocarcinoma. *Eur J Med Res* 2010;15:357-61.
  19. Takayasu K, Muramatsu Y, Moriyama N, et al. Imaging diagnosis of bile duct cystadenocarcinoma. *Cancer* 1988;61:941-6.
  20. Terada T, Kitamura Y, Ohta T, Nakanuma Y. Endocrine cells in hepatobiliary cystadenomas and cystadenocarcinomas. *Virchows Arch* 1997;430:37-40.
  21. Wolf HK, Garcia JA, Bossen EH. Oncocytic differentiation in intrahepatic biliary cystadenocarcinoma. *Mod Pathol* 1992;5:665-8.
  22. Unger PD, Thung SN, Kaneko M. Pseudosarcomatous cystadenocarcinoma of the liver. *Hum Pathol* 1987;18:521-3.
  23. Pastolero GC, Wakabayashi T, Oka T, Mori S. Tissue polypeptide antigen--a marker antigen differentiating cholangiolar tumors from other hepatic tumors. *Am J Clin Pathol* 1987;87:168-73.
  24. Marsh JL, Dahms B, Longmire WP Jr. Cystadenoma and cystadenocarcinoma of the biliary system. *Arch Surg* 1974;109:41-3.

## Adult type granulosa cell tumor in adult testis: report of a case and review of the literature

Zhao Song,<sup>1</sup> David J. Vaughn,<sup>2</sup> Zhanyong Bing<sup>3</sup>

<sup>1</sup>Department of Surgery, Jinan Central hospital, Jinan, Shandong, P. R. China;

<sup>2</sup>Abramson Cancer Center of the University of Pennsylvania;

<sup>3</sup>Department of Pathology and Laboratory Medicine, Hospital of the University of Pennsylvania, Philadelphia, PA, USA

### Abstract

Granulosa cell tumors can be classified into juvenile and adult types and more commonly occur in ovaries. Adult testicular granulosa cell tumors are extremely rare and only 29 cases of adult type have previously been reported. We report here a 28-year old Caucasian man with a left testicular adult type granulosa cell tumor. The tumor measured 2.6×2.6×2.5 cm and was mitotically active (10/10 HPF). Immunohistochemical stains showed the tumor diffusely positive for inhibin and vimentin, and negative for epithelial membrane antigen, cytokeratins, synaptophysin, HMB-45, OCT-4, placental-like alkaline phosphatase and lymphoid markers. The reported granulosa cell tumors in adult testis were briefly reviewed.

### Introduction

Granulosa cell tumors can be classified into juvenile and adult types. Juvenile type is usually benign. However, the clinical behavior of adult type granulosa cell tumors is difficult to predict. Testicular granulosa cell tumors are extremely rare. Only 29 adult type granulosa cell tumors in adult testicles have been reported. Analysis of the previous reported cases shows only tumor size of >5 cm reaches statistical significance in association with adverse clinical behavior.<sup>1</sup> We report a new case of adult type granulosa cell tumor in the testis and briefly review the previously published literature.

### Case Report

The patient is a 28-year-old Caucasian male who presented for urological evaluation after noting a firm lump in the left testicle. He com-

plained of mild left sided scrotal discomfort. He denied decreased libido or erectile dysfunction. Physical examination was normal except for an enlarged hard left testicle. Of note, no gynecomastia was noted. A trans-scrotal ultrasound confirmed a solid mass in left testicle. Serum alpha-fetoprotein and human chorionic gonadotropin levels were within normal limits. Computed tomography (CT) scans of chest, abdomen, pelvis showed no evidence of metastatic disease; however, an enhancing mass in left hemiscrotum was identified (Figure 1). The patient underwent a left inguinal orchiectomy. He recovered from his procedure uneventfully. Macroscopically, the testicle and epididymis measured 5×4×4 cm. The spermatic cord measured 5 cm in length and 1 cm in diameter. There was a 2.6×2.5×2.5 cm well-circumscribed mass in the testicle. On cut surface, the tumor was tan with a slight red pallor. No hemorrhage or necrosis was seen.

Microscopically, the tumor was well circumscribed with focal infiltration of testicular parenchyma (Figure 2A,B). No involvement of tunica albuginea was seen. The tumor was composed of solid sheets of cells with fine chromatin and inconspicuous nucleoli. Focal nuclear grooves were seen. The mitosis was brisk and averaged 10/10 high power fields (HPF). No atypical mitosis was seen. No necrosis or lymphovascular invasion was identified. The rete testis, epididymis, and spermatic cord were not involved.

To further characterize the tumor, immunohistochemical stains were performed (Figure 2C/D). The tumor was strongly positive for inhibin and vimentin, negative for epithelial membrane antigen (EMA), cytokeratins (AE1/3, cam5.2), germ cell tumor markers (OCT-4, placental-like alkaline phosphatase), melanocytic markers (S100, HMB45), lymphoma markers (LCA, CD3, CD5, CD20, CD79a, CD21, CD35).

The combined findings of morphology and immunohistochemistry supported the diagnosis of primary testicular adult type granulosa cell tumor.

### Discussion

Granulosa cell tumor is a sex-cord stromal tumor which more commonly occurs in the ovary.<sup>2</sup> Granulosa cell tumor is extremely rare in the adult testicle. Only 29 cases of testicular adult type granulosa cell tumor have been previously reported.<sup>3-11</sup> A testicular granulosa cell tumor usually presents as a painless mass in the testicle. A small portion of patients may present with gynecomastia.<sup>12-15</sup> The average age at presentation is 45 years (range 16-77 years).

Granulosa cell tumor of the testicle, like its

Correspondence: Zhanyong Bing, Department of Pathology and Laboratory Medicine, 6 Founders, Hospital of the University of Pennsylvania 3400 Spruce Street Philadelphia, PA 19104, USA. Tel: +1.215.662.6503 - Fax: +1.215.349-5910. E-mail: bingz@uphs.upenn.edu

Key words: adult type, testicular, granulosa cell tumor.

Received for publication: 21 February 2011.

Accepted for publication: 9 August 2011.

This work is licensed under a Creative Commons Attribution NonCommercial 3.0 License (CC BY-NC 3.0).

©Copyright Z. Song et al., 2011  
Licensee PAGEPress, Italy  
Rare Tumors 2011; 3:e37  
doi:10.4081/rt.2011.e37

ovarian counterpart, can be classified into juvenile or adult types. Juvenile type granulosa cell tumor usually occurs in children, but very rarely it can occur in an adult.<sup>16</sup> The tumor is usually multicystic, and lacks the morphological features of the adult type granulosa cell tumor such as Call-Exner bodies or coffee-bean nuclei. Most testicular granulosa cell tumors in adults are adult type.<sup>17</sup> Testicular granulosa cell tumors usually do not invade the tunica albuginea. Focal infiltration of the testicular parenchyma can be present.<sup>1</sup> No lymphovascular invasion is usually seen. The tumor can grow in multiple patterns, including trabecular, insular, macrofollicular, microfollicular and gyriform patterns. The nuclei are elongated, sometimes with nuclear grooves. No prominent nucleoli are seen. Mitosis is highly variable, ranging from 2 per 50 HPF to 3 per HPF.<sup>17</sup> Call-Exner bodies may be present.

The differential diagnosis for a testicular granulosa cell tumor includes subtyping the tumors into adult or juvenile type; type 2 germ cell tumors, especially yolk sac tumor; metastatic carcinoma; carcinoid tumors; and, non-Hodgkin's lymphoma. Adult type granulosa cell tumors can be differentiated from the juvenile type by the presence of Call-Exner bodies and/or coffee-bean nuclei. In contrast, juvenile type is usually multicystic, and lacks the characteristic features of adult type.

Immunohistochemically granulosa cell tumor is positive for inhibin, vimentin and calretinin, negative for epithelial membrane antigen (EMA), placental alkaline phosphatase, synaptophysin and lymphoid markers. Yolk sac tumor (YST) of mixed malignant germ cell tumors can show multiple growth patterns. However, YST is usually positive for PLAP, cytokeratin and AFP, albeit it can also be positive for inhibin.<sup>18</sup> Granulosa cell tumors need to be differentiated from hematopoietic malignan-