

Contents lists available at [ScienceDirect](#)

International Journal of Surgery Case Reports

journal homepage: www.casereports.com

Small bowel volvulus due to a large intestinal lipoma: A rare case report

Giuseppe Di Buono^{a,*}, Federica Ricupati^a, Giuseppe Amato^a, Leonardo Gulotta^b,
Giorgio Romano^a, Antonino Agrusa^a^a Department of Surgical, Oncological and Oral Sciences, Section of General and Urgent Surgery, University of Palermo, Italy^b Department of Human Pathology of Adult and Evolutive Age, General Surgery Unit, University Hospital of Messina, Italy

ARTICLE INFO

Article history:

Received 4 July 2020

Accepted 17 September 2020

Available online 25 September 2020

Keywords:

Antimesenteric lipoma

Intestinal volvulus

Emergency surgery

Small bowel obstruction

ABSTRACT

INTRODUCTION: A lipoma of the small bowel mesentery is a uncommon clinical entity. It rarely causes obstruction and volvulus of the small bowel.**CASE REPORT:** A 63 year old man was admitted to the emergency department with acute abdominal pain. Contrast-enhanced CT abdominal scan revealed small bowel obstruction due to a large fat density lesion suspected to be a lipoma. We performed a laparotomy in urgent setting that confirmed a small bowel volvulus secondary to a large antimesenteric lipoma. En-bloc resection with antiperistaltic side-to-side ileal anastomosis was done.**DISCUSSION:** Mesenteric lipoma is rare. They are usually asymptomatic but when have large sizes can cause several symptoms related to small bowel obstruction or volvulus. The diagnosis is difficult and is rarely made prior to exploratory laparoscopy or laparotomy. CT scan is the gold-standard imaging technique. It can shows the typical characteristics of tumor and may demonstrate the typical “vortex” pattern of a volvulus. In patients with acute clinical presentation en-bloc resection of the lipoma with the affected small bowel loops is often necessary. This treatment may also be reserved in asymptomatic patients with large mesenteric lipomas to avoid future complications.**CONCLUSION:** Volvulus of the small bowel caused by an antimesenteric lipoma is a very rare entity. It is diagnosed by CT scan and surgery represents the standard treatment.© 2020 Published by Elsevier Ltd on behalf of IJS Publishing Group Ltd. This is an open access article under the CC BY-NC-ND license (<http://creativecommons.org/licenses/by-nc-nd/4.0/>).

1. Introduction

In 1757, Bauer first described gastrointestinal lipomas [1]. These are rare, benign, slow-growing mesenchymal tumors originating from adipose tissue in the bowel wall. Generally, they are detected in the colon, but they can also be found in the oesophagus, stomach, and small intestine [2]. The most frequent site in the small intestine is the ileum (54%), followed by the duodenum (32%) and jejunum (14%) [3]. Histopathologically, there are three kinds of intestinal lipomas: the intermuscular type, the subserosal type, and the submucosal type. The most common is the submucosal type and represents more than 90% of intestinal lipomas. These lipomas can cause intussusception or ulceration with gastrointestinal bleeding and/or iron deficiency anemia. The subserosal types are the less common, but responsible of small bowel volvulus. Lipomas

of mesentery, mesocolon, and antimesenteric side of intestine are extremely rare. We describe a case of small bowel obstruction secondary to volvulus due to an antimesenteric ileal lipoma. This case it is reported in line with the SCARE criteria [4,5].

2. Case report

A 63-year-old Caucasian man was admitted to the emergency department with a typical clinical picture of occlusive syndrome: severe and diffuse abdominal pain, nausea and vomiting and no evacuation of faeces for 3 days. Abdominal examination revealed diffuse distension with increased tympanic bowel sounds. BMI was 26 kg/m² and he had no clinical history of previous abdominal surgery or other diseases. On arrivals WBC count was normal but C-reactive protein levels were high. We performed a contrast-enhanced CT abdominal scan that showed a dilated intestine with multiple air–fluid levels and a volvulus due to a lipoma of the distal middle third of the ileum (Fig. 1). Considering the presence of a limited working space for the distension of the small bowel we preferred a laparotomic rather than laparoscopic approach and we performed an exploratory 10-cm length minilaparotomy through a supra-sub umbilical incision in urgent setting. We chose

* Corresponding author at: Department of Surgical, Oncological and Oral Sciences (Di.Chir.On.S.), University of Palermo, Via L. Giuffrè, 5, 90127, Palermo, Italy.

E-mail addresses: giuseppe.dibuono@unipa.it (G.D. Buono), fede.ricup90@gmail.com (F. Ricupati), amatomed@gmail.com (G. Amato), gulotta.leonardo@gmail.com (L. Gulotta), giorgio.romano@unipa.it (G. Romano), antonino.agrusa@unipa.it (A. Agrusa).

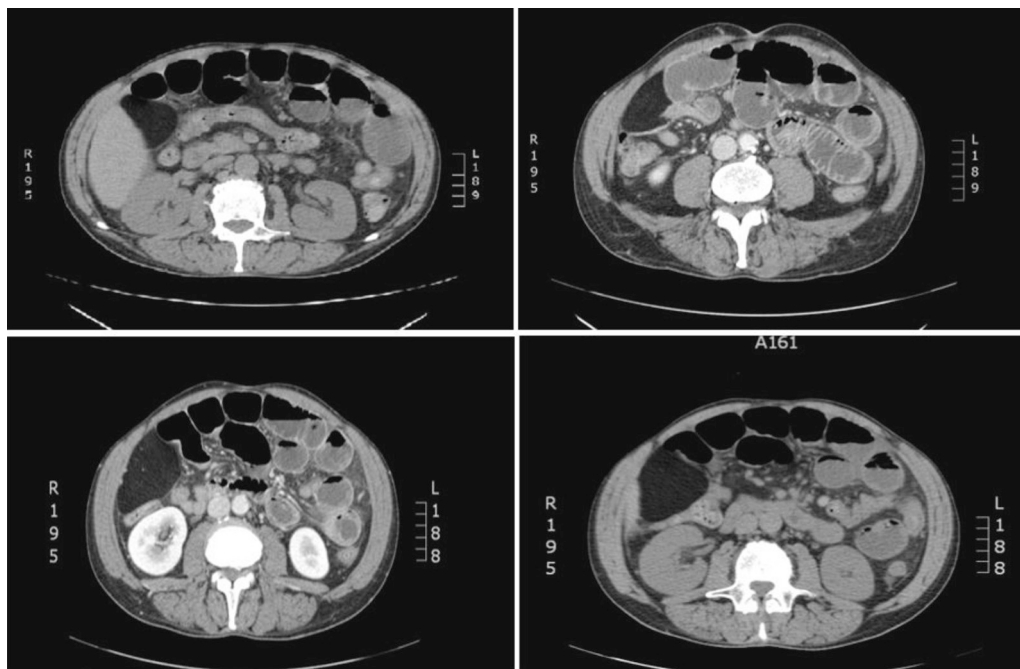


Fig. 1. Contrast-enhanced CT abdominal scan showed a dilated intestine with some air–fluid interfaces and ileal lipomatous mass involving the transition loop.

a minilaparotomy approach for its lower invasiveness, shorter hospitalization, less pain and reduction in typical wall complications of laparotomy. On the contrary in this case laparoscopic exploration was contraindicated for abnormal small bowel dilation with a higher risk of visceral lesions. After initial surgical exploration, we found a volvulated small bowel loop over a large exophytic lipomatous mass (12 cm in diameter) located in the antimesenteric border of the middle ileum with initial sign of vascular distress. The volvulus was easily de-rotated and the mass was resected en-bloc with involved bowel. We did an antiperistaltic side-to-side mechanical anastomosis using linear cutter with blue reload (Proximate™ linear cutter 75 mm, Ethicon). At the end of procedure we placed an abdominal drain in the Douglas space. No other macroscopically evident lesions were observed in the explored peritoneal organs. Our patient had no postoperative complications and was discharged on POD 6. Histopathological examination of surgical specimen showed a tumor composed of mature white adipose tissue with no evidence of nuclear atypia or mitosis, confirming that it was a benign lipoma.

3. Discussion

Mesenteric lipomas are rare clinical entity, with less than 50 cases described in English language literature [6]. The etiopathogenetic mechanism of their appearance and growth is not yet fully understood. It has been reported that there is an increased incidence in adults with obesity, diabetes mellitus, hypercholesterolemia, trauma, radiation, family history, and certain chromosomal abnormalities [7]. In our case, the patient had none of these risk factors. These lipomas are commoner in adults aged between 40 and 60 years and rarely occur in children of less than 10 years [8]. According to their size and location, lipomas can cause different types of symptoms. When mesenteric lipomas are large enough, they can even be palpated like soft masses in physical examination [9]. Because they are soft and mobile masses that do not penetrate into surrounding tissues, are asymptomatic allowing the passage of intestinal contents [10]. When they are larger than 2 cm, may produce abdominal pain, hematochezia and typical signs of intestinal obstruction [11] such as in our case. They

may also cause nonspecific symptoms including anorexia, progressive abdominal distention, constipation, weight loss, and sensation of abdominal fullness [12]. The prognosis depends mostly on the histological subtype of the tumor. Liposarcoma, lymphangioma, lymphangioliipoma, neuroblastoma and lymphoma are important differential diagnosis of mesenteric lipoma that should be considered [13,14]. Although uncommon, the complications of mesenteric lipomas during childhood and adulthood have been reported. In 1936, Hart reported the first cases of volvulus [15]. To our knowledge, a volvulus due to a lipoma emerging from antimesenteric side of the ileum has not been reported before. A study by Yang et al. reported a rare cause of acute abdomen about a torsion of an antimesenteric lipoma of the ileum [16]. In 2012, Watt et al. described a case of mesenteric lipoma causing small bowel perforation that required laparotomy and intestinal resection [17]. Rarely, lipoma can ulcerate and cause clinically apparent bleeding or chronic anemia. Dultz LA et al. [18] reported a rare case of an ulcerated ileocecal valve lipoma associated with lower gastrointestinal bleeding. In asymptomatic patients the diagnosis of small bowel lipomas is typically incidental. X-ray of the abdomen has no diagnostic value. Ultrasound shows a well defined homogenous echogenic mass and can distinguish it from a mesenteric cyst but is usually influenced by visceral fat or bowel gas. For this reason although it represents the first choice examination in the diagnosis of intestinal obstruction by volvulus in children it does not allow to define precisely the limits and location of tumor in relation to the peritoneum [19]. CT scan is the gold standard imaging modality for diagnosis of mesenteric lipoma and other lipomatous abdominal masses [20–22]. It shows homogenous tumor of adipose tissue, gives information about features of the small bowel and if there is evidence of ischemia and can demonstrate the typical “vortex” pattern of a volvulus. Moreover, as reported by Erešué J et al. it allows differential diagnosis with liposarcoma. CT scan of lipoma shows a very hypodense and well circumscribed mass with thin intratumoral septa [23]. Small and asymptomatic lipomas are usually left untreated. There are some reports of ileal lipoma treated by endoscopic mucosal resection [24] but generally, treatment of mesenteric lipoma is mainly done by a complete surgical resection of the tumor sparing the bowel loop if possible. To date, it

does not exist an unanimous agreement on which is the best treatment modality. Watt et al. [17] prefer a laparoscopic approach with resection of small lipoma for shorter hospitalization, less pain and aesthetic advantages than conventional open surgery. For the same advantages Tsushimi et al. [25] consider laparoscopic surgery the treatment of choice for benign tumors of the abdomen. However, in the presence of large size lipoma, as in case described by Kakuchi et al., is required an extended umbilical incision [26]. Often, as in this case report, treatment of large or symptomatic mesenteric lipoma involves surgical en-bloc resection of the adjacent small bowel and side-to-side anastomosis [6]. This management can also be reserved to those asymptomatic patients with large mesenteric lipomas to avoid future complications such as volvulus or obstruction. In urgent setting exploratory laparotomy with en bloc resection of a mesenteric lipoma with or without intestinal resection still remains the more widespread surgical option. In our surgical experience we performed several laparoscopic resection in case of large abdominal masses but in this case we prefer open approach because of clinical and radiological findings of small bowel obstruction with higher risk of visceral lesions with laparoscopic approach [27–29].

4. Conclusion

This is an unusual case of volvulus due to an antimesenteric ileal lipoma in the adult. These benign tumors are frequently revealed by CT scan and the definitive diagnosis is made on the basis of histopathological examination. In patients with acute clinical presentation an en-block intestinal resections are justified. On the other hand only in selected cases a laparoscopic approach can be successfully performed.

Declaration of Competing Interest

Di Buono Giuseppe and other co-authors have no conflict of interest.

Funding

Di Buono Giuseppe and other co-authors have no study sponsor.

Ethical approval

Ethical Approval was not necessary for this study. We obtained written patient consent to publication.

Consent

We obtained written patient consent to publication.

Author contribution

Di Buono Giuseppe: study design, data collections, data analysis and writing.

Ricupati Federica: study design, data collections, data analysis and writing.

Amato Giuseppe: data collections.

Gulotta Leonardo: data collections.

Romano Giorgio: study design, data collections, data analysis and writing.

Agrusa Antonino: study design, data collections, data analysis and writing.

Registration of research studies

Not applicable.

Guarantor

Di Buono Giuseppe.
Agrusa Antonino.

Availability of data and materials

The datasets used and/or analysed during the current study are available from the corresponding author on reasonable request.

Provenance and peer review

Not commissioned, externally peer-reviewed.

Acknowledgement

This article is part of a supplement entitled Case reports from Italian young surgeons, published with support from the Department of Surgical, Oncological and Oral Sciences – University of Palermo.

References

- [1] Amit Agrawal, Maj, K.J. Singh, Col Symptomatic intestinal lipomas: our experience, *MJAFI* 67 (2011) 374–376.
- [2] N.B. Ackerman, S.Q. Chughtai, Symptomatic lipomas of the gastrointestinal tract, *Surg. Gynecol. Obstet.* 141 (1975) 565–568.
- [3] J.M. Wilson, D.B. Melvin, G. Gray, B. Thorbjarnason, Benign small bowel tumor, *Ann. Surg.* 181 (1975) 247–250.
- [4] R.A. Agha, A.J. Fowler, A. Saetta, I. Barai, S. Rajmohan, D.P. Orgill, For the SCARE Group, The SCARE statement: consensus-based surgical case report guidelines, *Int. J. Surg.* 34 (2016) 180–186.
- [5] R.A. Agha, M.R. Borrelli, R. Farwana, K. Koshy, A. Fowler, D.P. Orgill, For the SCARE Group, The SCARE 2018 statement: updating consensus Surgical Case Report (SCARE) guidelines, *Int. J. Surg.* 60 (2018) 132–136.
- [6] (a) Tayeh Christelle, Mneimneh Sirin, El-Masri Rayan, Daoud Nabil, Rajab Mariam, Giant mesenteric lipoma: a case report and a review of the literature, *J. Ped. Surg. Case Rep.* 3 (2015), 166e170; (b) Bansal M. Yashpal, A. Kudva, Small bowel intussusception in an adult due to lipoma: a rare cause of obstruction. Case report and literature review, *Internet J. Surg.* (2020).
- [7] J.D. Wolko, D.L. Rosenfeld, M.J. Lazar, S.J. Underberg-Davis, Torsion of a giant mesenteric lipoma, *Pediatr. Radiol.* 33 (1) (2003) 34–36.
- [8] R.N. Tahlan, P. Garg, P.K. Bishnoi, S.L. Singla, Mesenteric lipoma: an unusual cause of small intestinal volvulus, *Indian J. Gastroenterol.* 16 (4) (1997) 15.
- [9] K.G. Srinivasan, A. Gaikwad, K. Ritesh, K.P. Ushanandini, Giant omental and mesenteric lipoma in an infant, *Afr. J. Paediatr. Surg.* 6 (1) (2009) 68.
- [10] J.M. Cha, J.I. Lee, K.R. Joo, J.W. Choe, S.W. Jung, H.P. Shin, Giant mesenteric lipoma as an unusual cause of abdominal pain: a case report and a review of the literature, *J. Korean Med. Sci. [Internet]* 24 (2) (2009) 333–336.
- [11] B. Kang, Q. Zhang, D. Shang, et al., Resolution of intussusception after spontaneous expulsion of an ileal lipoma per rectum: a case report and literature review, *World J. Surg. Oncol.* 12 (2014) 143.
- [12] J.M. Cha, J.I. Lee, K.R. Joo, J.W. Choe, S.W. Jung, H.P. Shin, Giant mesenteric lipoma as an unusual cause of abdominal pain: a case report and a review of the literature, *J. Korean Med. Sci.* 24 (2) (2009) 333–336.
- [13] I. Ahmed, S. Singh, J.D. Rawat, Chronic abdominal pain in a child Saudi, *J. Gastroenterol.* 17 (2011) 295–296.
- [14] A. Agrusa, G. Romano, L.J. Dominguez, G. Amato, R. Citarrella, L. Vernuccio, G. Di Buono, V. Sorce, L. Gulotta, M. Galia, P. Mansueto, G. Gulotta, Adrenal cavernous hemangioma: which correct decision making process? *Acta Medica Mediterranea.* 32 (2016) 385–389.
- [15] J.T. Hart, Solid tumours of the mesentery, *Ann. Surg.* 104 (1963) 184.
- [16] T.W. Yang, Y.W. Tsuei, C.C. Kao, W.H. Kuo, Y.L. Chen, Y.Y. Lin, Torsion of a giant antimesenteric lipoma of the ileum: a rare cause of acute abdominal pain, *Am. J. Case Rep.* 18 (2017) 589–592.
- [17] D.G. Watt, P. Sanjay, S.V. Walsh, J.A. Young, A. Alijani, Mesenteric lipoma causing small bowel perforation: a case report and review of literature, *Scott. Med. J.* 57 (4) (2012) 247.
- [18] L.A. Dultz, B.W. Ullery, H.H. Sun, T.L. Huston, Ileocecal valve lipoma with refractory hemorrhage, *JSL* 13 (January–March (1)) (2009) 80.

- [19] A. Prando, S. Wallace, R.M. Marins, Pereira: sonographic features of benign intraperitoneal lipomatous tumors in children-report of 4 cases, *Pediatr. Radiol.* 20 (1) (1998) 571–574.
- [20] J.P. Heiken, K.A. Forde, R.P. Gold. Computed tomography as a definitive method for diagnosing gastrointestinal lipomas, *Radiology* 142 (1982) 409–414.
- [21] D. Albano, F. Agnello, F. Midiri, G. Pecoraro, A. Bruno, P. Alongi, P. Toia, G. Di Buono, A. Agrusa, L.M. Sconfienza, S. Pardo, L. La Grutta, M. Midiri, M. Galia, Imaging features of adrenal masses, *Insights Imaging* 10 (January (1)) (2019) 1, <http://dx.doi.org/10.1186/s13244-019-0688-8>, Review.
- [22] M. Galia, D. Albano, A. Bruno, A. Agrusa, G. Romano, G. Di Buono, F. Agnello, G. Salvaggio, L. La Grutta, M. Midiri, R. Lagalla, Imaging features of solid renal masses, *Br. J. Radiol.* 90 (August (1077)) (2017), 20170077, <http://dx.doi.org/10.1259/bjr.20170077>, Epub 2017 Jul 13. Review.
- [23] J. Erešúé, J.C. Philippe, P. Casenave, F. Laurent, N. Grenier, J.M. Simon, J. Drouillard, J. Tavernier, Computed x-ray tomography of abdominal lipoma and liposarcoma in adults. Apropos of 9 cases, *J. Radiol.* 65 (March (3)) (1984) 145–149.
- [24] (a) H. Yoshimura, K. Murata, K. Takase, T. Nakano, Y. Tameda, A case of lipoma of the terminal ileum treated by endoscopic removal, *Gastrointest. Endosc.* 46 (1997) 461–463;
(b) T. Matsumoto, M. Iida, T. Matsui, M. Hirakawa, A. Shiraishi, T. Yao, et al., Submucosal tumors of the terminal ileum managed by endoscopic polypectomy, *Gastrointest. Endosc.* 36 (1990) 505–509.
- [25] T. Tsushimi, N. Matsui, H. Kurazumi, Y. Takemoto, K. Oka, A. Seyama, T. Morita, Laparoscopic resection of an ileal lipoma: report of a case, *Surg. Today* 36 (2006) 1007–1011.
- [26] Kakiuchi, H. Mashima, N. Hori, H. Takashima, A small intestine volvulus caused by strangulation of a mesenteric lipoma: a case report, *J. Med. Case Rep.* 11 (1) (2017).
- [27] A. Agrusa, G. Di Buono, S. Buscemi, B. Randisi, L. Gulotta, V. Sorce, G. Badalamenti, D. Albano, M. Galia, G. Romano, G. Gulotta, Dedifferentiated retroperitoneal large liposarcoma and laparoscopic treatment: is it possible and safe? The first literature case report, *Int. J. Surg. Case Rep.* 57 (2019) 113–117, <http://dx.doi.org/10.1016/j.ijscr.2019.03.023>, Epub 2019 Mar 26.
- [28] A. Agrusa, G. Di Buono, S. Buscemi, G. Cucinella, G. Romano, G. Gulotta, 3D laparoscopic surgery: a prospective clinical trial, *Oncotarget* 9 (April (25)) (2018) 17325–17333, <http://dx.doi.org/10.18632/oncotarget.24669>, eCollection 2018 Apr 3.
- [29] G. Di Buono, S. Buscemi, A.I. Lo Monte, G. Geraci, V. Sorce, R. Citarrella, E. Gulotta, V.D. Palumbo, S. Fazzotta, L. Gulotta, D. Albano, M. Galia, G. Romano, A. Agrusa, Laparoscopic adrenalectomy: preoperative data, surgical technique and clinical outcomes, *BMC Surg.* 18 (April (Suppl 1)) (2019) 128, <http://dx.doi.org/10.1186/s12893-018-0456-6>.

Open Access

This article is published Open Access at [sciencedirect.com](https://www.sciencedirect.com). It is distributed under the [IJSCR Supplemental terms and conditions](#), which permits unrestricted non commercial use, distribution, and reproduction in any medium, provided the original authors and source are credited.