



# Isolated Leptomeningeal Enhancement in Anti-N-Methyl D-Aspartate Receptor Encephalitis: The Diagnostic Value of Contrast-Enhanced Fluid-Attenuated Inversion Recovery Imaging

항-NMDA 수용체 항체와 관련된 뇌염에서  
단독 연수막 조영증강: 조영증강 유체감쇠반전회복기법  
영상의 진단적 가치

Jun Kyeong Park, MD<sup>1</sup> , Eun Ja Lee, MD<sup>1\*</sup> , Kwang Ki Kim, MD<sup>2</sup> 

Departments of <sup>1</sup>Radiology and <sup>2</sup>Neurology, Dongguk University Ilsan Hospital, Goyang, Korea

Anti-N-methyl-D-aspartate receptor (anti-NMDAR) encephalitis is a common autoimmune encephalitis that is noted to be a severe but treatable disease entity. Patients with anti-NMDAR encephalitis often develop psychotic symptoms, including delusions, hallucinations, and paranoia, as well as memory impairment and persistent loss of attention. However, MRI findings in such patients show no abnormalities in most cases. Although typical brain abnormality features, known as T2 hyperintensities, involve the brain parenchyma and contrast enhancement at the cerebral cortex or overlying meninges, isolated leptomeningeal enhancement has been rarely reported in anti-NMDAR encephalitis. Herein, we report a patient with anti-NMDAR encephalitis who presented with isolated leptomeningeal enhancement, additionally showing the diagnostic value of contrast-enhanced fluid-attenuated inversion recovery imaging.

**Index terms** Anti-NMDA Receptor Encephalitis; Magnetic Resonance Imaging; Brain

## INTRODUCTION

Anti-N-methyl-D-aspartate receptor (anti-NMDAR) encephalitis is a common autoim-

Received May 25, 2021  
Revised August 22, 2021  
Accepted August 24, 2021

**\*Corresponding author**

Eun Ja Lee, MD  
Department of Radiology,  
Dongguk University Ilsan Hospital,  
27 Dongguk-ro, Ilsandong-gu,  
Goyang 10326, Korea.


Tel 82-31-961-7827

Fax 82-31-961-8281

E-mail [ejl1048@hanmail.net](mailto:ejl1048@hanmail.net)


This is an Open Access article distributed under the terms of the Creative Commons Attribution Non-Commercial License (<https://creativecommons.org/licenses/by-nc/4.0>) which permits unrestricted non-commercial use, distribution, and reproduction in any medium, provided the original work is properly cited.

**ORCID iDs**

Jun Kyeong Park 


<https://>

[orcid.org/0000-0003-1965-9422](https://orcid.org/0000-0003-1965-9422)

Eun Ja Lee 

<https://>

[orcid.org/0000-0002-3083-9339](https://orcid.org/0000-0002-3083-9339)

Kwang Ki Kim 

<https://>

[orcid.org/0000-0001-5505-1540](https://orcid.org/0000-0001-5505-1540)

mune encephalitis, mediated by antibodies against the NMDA receptor subunit 1 (NR1) and subunit 2 (NR2) heteromers of the NMDA receptor. It results in a characteristic neuropsychiatric syndrome (1). The MRI findings of anti-NMDAR encephalitis have poor specificity. Abnormal MRI findings include parenchymal T2 signal hyperintensity and faint contrast enhancement in the affected area and/or the overlying meninges (2, 3). However, isolated leptomeningeal enhancement has rarely been reported in anti-NMDAR encephalitis (4). Here, we report an unusual presentation of isolated leptomeningeal enhancement in anti-NMDAR encephalitis and show the diagnostic value of contrast-enhanced fluid-attenuated inversion recovery (CE-FLAIR) imaging.

## CASE REPORT

A 23-year-old female showed a history of progressively worsening confusion, disorientation, and behavioral disorders that began with memory impairment 7 days previously. There were no abnormalities in peripheral blood tests. Cerebrospinal fluid (CSF) analyses showed a white blood cell count of 8 cells/mL (98% lymphocytes) with no evidence of bacterial or viral infection. The CSF biochemistry results, including protein, glucose, chloride, and lactate dehydrogenase, were all normal.

A CE MRI was performed on the patient. The contrast agent was administered at the standard dose of 0.1 mmol/kg of body weight. Postcontrast images were obtained shortly after contrast material administration. Axial CE-FLAIR imaging was performed immediately after the routine CE-coronal and axial T1 weighted imaging (T1WI). Scanning of axial CE-T1WI and axial CE-FLAIR imaging was started at 2 minutes 40 seconds, and 5 minutes after the injection of contrast material, respectively. The initial MRI revealed diffuse leptomeningeal enhancement at the left cerebral convexity without any parenchymal abnormalities. Although CE-T1WI can show mild meningeal enhancement, CE-FLAIR imaging is highly superior to it for detecting strengthening lesions (Fig. 1A, B). There were no other findings, including intracranial hemorrhage or diffusion restrictions. Subsequent tests showed that CSF samples tested positive for the anti-NMDA receptor antibody. Ultimately, a diagnosis of anti-NMDAR encephalitis was made. An electroencephalogram showed nonspecific findings. Tumor screening results were negative.

After combination treatment with high-dose intravenous methylprednisolone, intravenous immunoglobulin (IVIg), and plasmapheresis, the patient showed a gradual clinical improvement. The leptomeningeal enhancement was significantly improved according to two follow-up MR images (8 and 25 days later). CE-FLAIR imaging was also far superior to CE-T1WI for detecting improvement in leptomeningeal enhancement (Fig. 1C-F).

The study protocol conformed to the ethical guidelines of the 1975 Declaration of Helsinki.

## DISCUSSION

Anti-NMDAR encephalitis is a common autoimmune encephalitis. Although treatable, it may result in significant disability and death if the diagnosis is delayed. IgG antibodies to the subunit of neuronal NMDA receptors selectively and reversibly reduce NMDA receptor sur-

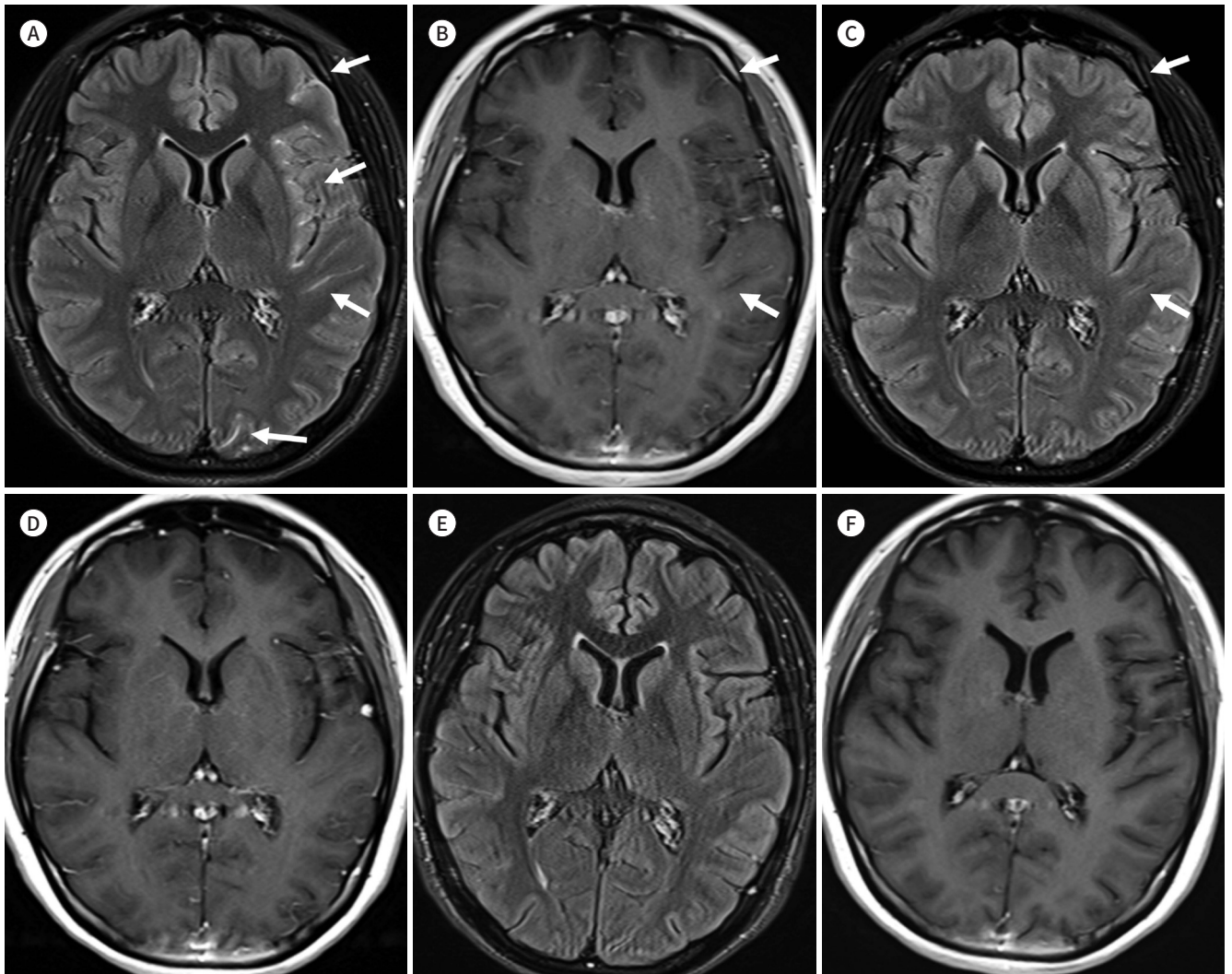
**Fig. 1.** MRI of anti-NMDAR encephalitis in a 23-year-old female.

**A, B.** Initial MR images taken CE-FLAIR imaging (**A**) and CE-T1WI (**B**), show diffuse abnormal leptomeningeal enhancement (arrows) along the left cerebral convexity without significant parenchymal enhancement; however, it is difficult to discriminate between the normally enhanced vessels and the leptomeningeal lesions on CE-T1WI.

**C, D.** Eight-day follow-up MR images after steroid pulse therapy, taken CE-FLAIR imaging (**C**) and CE-T1WI (**D**); unlike CE-T1WI, it shows the remaining leptomeningeal enhancement (arrows on **C**) only on the CE-FLAIR imaging.

**E, F.** Twenty-five-day follow-up MR images after steroid pulse therapy, intravenous immunoglobulin, and plasmapheresis, taken using CE-FLAIR imaging (**E**) and CE-T1WI (**F**), show a gradual improvement in leptomeningeal enhancement on CE-FLAIR imaging; CE-FLAIR imaging is more effective than CE-T1WI for assessing the response to therapy.

CE = contrast-enhanced, FLAIR = fluid-attenuated inversion recovery, NMDAR = N-methyl-D-aspartate receptor, T1WI = T1 weighted imaging



face density and synaptic localization, leading to disruption of synaptic structures and functions.

The disease predominantly affects young people, and a multicenter observational study identified a female predominance (4:1) (5). This predominance is less evident in children under 12 years of age and adults over 45 years old. In that study, half of the young affected female patients had an ovarian teratoma; in men and children, the association with tumors was less frequent.

Many patients present with an early viral-like prodrome, and the characteristic symptoms progress in a multistage manner after a few days, including psychiatric manifestations (anxiety, depression, schizophrenia, and psychosis), temporal lobe dysfunction (amnesia and seizures), and severe neurological deficits (autonomic dysfunction and dystonia/dyskinesia) (6).

MRI findings of anti-NMDAR encephalitis are not specific. Most patients show no abnormalities in MRI. Nonspecific abnormal MRI findings show a wide variation in the degree and distribution of T2/FLAIR signal hyperintensity involving the hippocampi, cerebellar, cerebral cortex, insular regions, periventricular white matter, basal ganglia, brainstem, and the spinal cord, as well as leptomeningeal enhancement with concomitant parenchymal lesions (2, 3). Only one case of anti-NMDAR encephalitis with isolated leptomeningeal enhancement has been reported (4).

Leptomeningeal enhancement occurs when contrast media leaks from blood vessels into the CSF. Recent immunochemistry studies have shown that NR1 is expressed in endothelial cells in the brain, and NMDA receptors are required to increase the permeability of the blood-brain barrier (7, 8). Therefore, the isolated leptomeningeal enhancement seen in anti-NMDAR encephalitis could also be due to this leakage. However, the reported case was of limited value for evaluating abnormal leptomeningeal enhancement, as only CE-T1WIs were obtained. CE-FLAIR imaging does not demonstrate enhancement in the normal vascular structures or normal meninges. Additionally, CE-FLAIR imaging is more sensitive to low gadolinium concentrations as it is extremely sensitive to modification of the CSF composition (9). Therefore, CE-FLAIR imaging is more effective than CE-T1WI for detecting abnormal meningeal enhancement. In the case presented here, CE-FLAIR imaging was vastly superior to CE-T1WI for detecting leptomeningeal lesions in the initial MRI examination and was more helpful for evaluating the response to therapy in follow-up MRI.

When we encounter an isolated leptomeningeal enhancement in patients with psychiatric symptoms that exclude the possibility of infection, although an isolated leptomeningeal enhancement is a rare imaging finding of anti-NMDAR encephalitis, anti-NMDAR encephalitis should be included as a differential diagnosis.

The diagnosis of anti-NMDAR encephalitis was confirmed by identifying antibodies to the NMDA receptor in the CSF, and the presence of an ovarian teratoma had to be confirmed, as that could express the NMDA receptor. Immunotherapy is generally used to manage anti-NMDAR encephalitis, and if a tumor is present, this must be removed to relieve symptoms and reduce recurrence. Steroids, IVIg, and plasmapheresis can be used as first-line immunotherapy, either alone or in combination. Second-line immunotherapy can be used alone or in combination with cyclophosphamide and rituximab in patients who do not respond to first-line immunotherapy. One study found that 53% of patients with anti-NMDAR encephalitis showed clinical improvement within 4 weeks following administration of first-line immunotherapy and tumor removal if a tumor was present (5). In that study, a total of 81% of patients who did not respond to first-line immunotherapy and who received second-line immunotherapy showed substantial recovery (i.e., mild or no residual symptoms) at 24 months, and there was a decrease in the frequency of subsequent recurrence.

In conclusion, the present case suggests that isolated leptomeningeal enhancement could be an imaging finding in patients with anti-NMDAR encephalitis. CE-FLAIR imaging is well

known for being vastly superior to CE-T1WI for detecting leptomeningeal pathology. This case showed that CE-FLAIR imaging can be useful for detecting leptomeningeal enhancement and evaluating treatment response in patient with anti-NMDAR encephalitis. Therefore, CE-FLAIR should be included in the MRI examinations in patients with suspected anti-NMDAR encephalitis.

### Author Contributions

Conceptualization, P.J.K, L.E.J.; data curation, P.J.K, L.E.J.; formal analysis, P.J.K, L.E.J.; investigation, all authors; methodology, P.J.K, L.E.J.; project administration, P.J.K, L.E.J.; resources, all authors; supervision, L.E.J.; validation, P.J.K, L.E.J.; visualization, P.J.K, L.E.J.; writing—original draft, P.J.K; and writing—review & editing, L.E.J.

### Conflicts of Interest

The authors have no potential conflicts of interest to disclose.

### Funding

None

## REFERENCES

1. Dalmau J, Tüzün E, Wu HY, Masjuan J, Rossi JE, Voloschin A, et al. Paraneoplastic anti-N-methyl-D-aspartate receptor encephalitis associated with ovarian teratoma. *Ann Neurol* 2007;61:25-36
2. Dalmau J, Gleichman AJ, Hughes EG, Rossi JE, Peng X, Lai M, et al. Anti-NMDA-receptor encephalitis: case series and analysis of the effects of antibodies. *Lancet Neurol* 2008;7:1091-1098
3. Wang R, Lai XH, Liu X, Li YJ, Chen C, Li C, et al. Brain magnetic resonance-imaging findings of anti-N-methyl-D-aspartate receptor encephalitis: a cohort follow-up study in Chinese patients. *J Neurol* 2018;265:362-369
4. Niu PP, Song B, Xu YM. Isolated leptomeningeal enhancement in anti-N-methyl-D-aspartate receptor encephalitis: a case report. *Research Square* 2019 Apr [Epub]. <https://doi.org/10.21203/rs.2.1810/v1>
5. Titulaer MJ, McCracken L, Gabilondo I, Armangué T, Glaser C, Iizuka T, et al. Treatment and prognostic factors for long-term outcome in patients with anti-NMDA receptor encephalitis: an observational cohort study. *Lancet Neurol* 2013;12:157-165
6. Zhang L, Wu MQ, Hao ZL, Chiang SM, Shuang K, Lin MT, et al. Clinical characteristics, treatments, and outcomes of patients with anti-N-methyl-d-aspartate receptor encephalitis: a systematic review of reported cases. *Epilepsy Behav* 2017;68:57-65
7. Beard RS Jr, Reynolds JJ, Bearden SE. Hyperhomocysteinemia increases permeability of the blood-brain barrier by NMDA receptor-dependent regulation of adherens and tight junctions. *Blood* 2011;118:2007-2014
8. Reijerkerk A, Kooij G, van der Pol SM, Leyen T, Lakeman K, van Het Hof B, et al. The NR1 subunit of NMDA receptor regulates monocyte transmigration through the brain endothelial cell barrier. *J Neurochem* 2010; 113:447-453
9. Lee EK, Lee EJ, Kim S, Lee YS. Importance of contrast-enhanced fluid-attenuated inversion recovery magnetic resonance imaging in various intracranial pathologic conditions. *Korean J Radiol* 2016;17:127-141

## 항-NMDA 수용체 항체와 관련된 뇌염에서 단독 연수막 조영증강: 조영증강 유체감쇠반전회복기법 영상의 진단적 가치

박준경<sup>1</sup> · 이은자<sup>1\*</sup> · 김광기<sup>2</sup>

항-N-메틸 D-아스파르테이트 수용체(anti-N-methyl-D-aspartate receptor; 이하 항-NMDAR) 뇌염은 중증이지만 치료가 가능한 흔한 자가면역뇌염이다. 항-NMDAR 뇌염 환자는 종종 망상, 환각 및 편집증과 같은 정신병적 증상뿐만 아니라 기억력 손상 및 지속적인 주의력 상실과 같은 증상을 호소한다. 항-NMDAR 뇌염 환자의 자기공명영상 소견은 대부분의 경우에서 이상 소견을 보이지 않으나, 이상 소견이 보이는 경우에는 뇌 실질의 T2 고강도 병변과 이와 인접한 연수막에 조영증강이 있는 것으로 알려져 있다. 그러나 항-NMDAR 뇌염에서 단독 연수막 조영증강은 드물게 보고되어 있다. 우리는 항-NMDAR 뇌염에서 단독 연수막 조영증강을 보인 환자의 증례 보고와 함께 조영증강 유체감쇠반전회복기법 영상의 진단 가치를 보여주고자 한다.

동국대학교 일산병원 <sup>1</sup>영상의학과, <sup>2</sup>신경과