

Water-immersion and cap-assisted endoscopic ablation of hemorrhagic radiation proctopathy with a novel 1.9/1.5- μm dual-emission endoscopic laser treatment

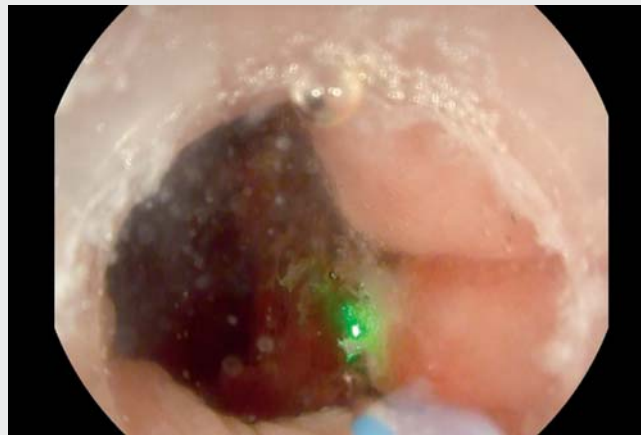


Hemorrhagic radiation proctopathy is a long-lasting side effect of radiotherapy for gynecologic, urologic, and digestive cancers that is characterized by hematochezia from mucosal angioectasia, and a variable degree of rectal pain, tenesmus, urgency, and incontinence [1]. When symptoms or anemia occur despite medical treatment, endoscopic therapy with radiofrequency ablation or argon plasma coagulation represents the first option, with appreciable but still suboptimal endoscopic and clinical long-term results [1, 2].

Here we report the case of a 51-year-old woman with severe chronic hematochezia, moderate-to-severe iron deficiency anemia, tenesmus, and urgency. Her clinical history was remarkable for brachytherapy for cervical cancer in previous years. Ileocolonoscopy showed many angioectasias, with multiple bleeding spots and mucosal friability in the caudal rectum.

A 1.9/1.5- μm wavelength dual-emission endoscopic laser designed for endoscopic therapy (Opera Evo; Quanta System, Samarate, Italy) was employed to achieve complete hemostasis and the ablation of the main rectal angioectasias (► **Video 1**). The water-immersion and cap-assisted techniques improved the visualization of the bleeding spots and helped in conveying the laser beam to the lesions that were close to the dentate line, by avoiding over-insufflation and anoscope insertion. The procedure was conducted using a standard gastroscope and a conventional laser setting, with the patient under conscious sedation. The patient was discharged home 3 hours after the procedure and did not report any endoscopic injuries or other adverse events during follow-up.

This case represents the first video report on the use of the novel 1.9/1.5- μm wavelength dual-emission laser treatment in a real-life case of severe hemor-



► **Video 1** Water-immersion and cap-assisted 1.9/1.5- μm wavelength dual-emission endoscopic laser treatment in a patient with severe hemorrhagic radiation proctopathy of the caudal rectum, with ongoing hematochezia.

rhagic radiation proctopathy. We report an augmented effectiveness and maneuverability when the laser therapy was assisted by water immersion and the use of an endoscopic cap in the terminal rectum. Finally, this report adds to the growing literature on the potential applications of therapeutic laser systems in digestive endoscopy [3–5].

Endoscopy_UCTN_Code_TTT_1AQ_2AZ

Funding

Italian Ministry of Health, Current research IRCCS

Competing interests

The authors declare that they have no conflict of interest.

The authors

Gian Eugenio Tontini^{1,2}, **Alessandro Rimondi**^{1,2}, **Flaminia Cavallaro**¹, **Nicoletta Nandi**^{1,2}, **Lucia Scaramella**¹, **Maurizio Vecchi**^{1,2}, **Luca Elli**¹

- 1 Gastroenterology and Endoscopy Unit, Fondazione IRCCS Ca' Granda Ospedale Maggiore Policlinico, Milan, Italy
- 2 Department of Pathophysiology and Transplantation, University of Milan, Italy

Corresponding author

Alessandro Rimondi, MD

Division of Gastroenterology and Endoscopy, Fondazione IRCCS Ca' Granda Ospedale Maggiore Policlinico, Università degli Studi di Milano, Via F. Sforza 35, 20122 Milan, Italy
alessandro.rimondi@unimi.it

References

- [1] Dray X, Battaglia G, Wengrower D et al. Radiofrequency ablation for the treatment of radiation proctitis. *Endoscopy* 2014; 46: 970–976
- [2] Furtado FS, Furtado GB, Oliveira AT et al. Endorectal formalin instillation or argon plasma coagulation for hemorrhagic radiation proctopathy therapy: a prospective and randomized clinical trial. *Gastrointest Endosc* 2021; 93: 1393–1400
- [3] Tontini GE, Neumann H, Pastorelli L et al. Thulium laser in interventional endoscopy: animal and human studies. *Endoscopy* 2017; 49: 365–370
- [4] Tontini G, Neumann H, Rimondi A et al. Ex vivo experimental study on the Thulium laser system: new horizons for interventional endoscopy (with videos). *Endosc Int Open* 2017; 05: E410–E415
- [5] Dioscoridi L, Forti E, Pugliese F et al. Thulium laser coagulation: a new effective endotherapy to treat gastrointestinal angiodysplasia. *Gastrointest Endosc* 2019; 90: 319–320

Bibliography

Endoscopy 2023; 55: E338–E339

DOI 10.1055/a-1981-2072

ISSN 0013-726X

© 2023. The Author(s).

This is an open access article published by Thieme under the terms of the Creative Commons Attribution-NonDerivative-NonCommercial License, permitting copying and reproduction so long as the original work is given appropriate credit. Contents may not be used for commercial purposes, or adapted, remixed, transformed or built upon. (<https://creativecommons.org/licenses/by-nc-nd/4.0/>)

Georg Thieme Verlag KG, Rüdigerstraße 14,
70469 Stuttgart, Germany



ENDOSCOPY E-VIDEOS

<https://eref.thieme.de/e-videos>



Endoscopy E-Videos is an open access online section, reporting on interesting cases and new techniques in gastroenterological endoscopy. All papers include a high quality video and all contributions are freely accessible online. Processing charges apply (currently EUR 375), discounts and waivers acc. to HINARI are available.

This section has its own submission website at

<https://mc.manuscriptcentral.com/e-videos>