



OPEN ACCESS

Monogenic diabetes: a new pathogenic variant of HNF1A gene

Raquel Vilela Oliveira, Teresa Bernardo, Sandrina Martins, Ana Sequeira

Pediatrics, Unidade Local de Saúde do Alto Minho EPE, Viana do Castelo, Portugal

Correspondence to

Dr Raquel Vilela Oliveira;
Raquelvileira07@gmail.com

Accepted 11 November 2019

SUMMARY

Maturity onset diabetes of the young defines a diabetes mellitus subtype, with no insulin resistance or autoimmune pancreatic β -cells dysfunction, that occurs by mutation in a single gene. A 13-year-old girl hospitalised due to hyperglycemia plus glycosuria without ketosis, and with normal glycated haemoglobin of 6.8%. She started a sugar-free fast-absorption diet and no insulin therapy was required. Fasting glucose was normal, but 2 hours after lunch she presented hyperglycemia as after 2 hours of an oral glucose tolerance test, with 217 mg/dL. Family history was positive for type 2 diabetes mellitus with an autosomal dominant pattern. She was discharged with fast-absorption sugar-free diet and low-dose of sulfonylurea. A genetic test was performed detecting a mutation in heterozygosity of HNF1A gene, compatible with the diagnosis of maturity onset diabetes of the young 3 (MODY3), not reported in the literature. Early recognition of signs and symptoms increase awareness of MODY. Genetic test allows confirmation and leads to optimised treatment.

BACKGROUND

Diabetes mellitus (DM) is one of the most common chronic diseases in childhood. It includes numerous clinical entities that are characterised by chronic hyperglycemia. Although type 1 DM is the most common form among paediatric population, other forms such as type 2 DM and monogenic diabetes must be considered, the latter being responsible for 1%–6% of paediatric diabetes cases.^{1 2}

Monogenic forms of diabetes can be subclassified into neonatal diabetes, mitochondrial diabetes and maturity onset diabetes of the young (MODY).^{2 3} The majority of cases result from mutations in genes causing β -cell loss or dysfunction.^{2–5}

Patients with MODY exhibit mild or none diabetic symptoms, and elevated glucose levels can only be detected in routine blood tests.^{3 6}

MODY has different subtypes depending on the gene involved and the clinical phenotypes.⁶ They differ on age of onset, pattern of hyperglycemia, response to treatment and extra-pancreatic manifestations.^{2–9} The prevalence varies according to the population and it represents approximately 1%–4% of all cases of diabetes diagnosed under the age of 30 years.⁵

There are 14 genes identified associated with MODY. Mutations in each gene lead to the development of different subtypes of MODY. The most prevalent gene mutations are responsible for MODY2 and MODY3, encoding glucokinase and

hepatic nuclear factor 1 alpha (HNF1A), respectively.^{2–4 6 7 10} These subtypes account for up to 90% of all MODY cases.¹⁰

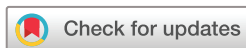One of the challenges is to differentiate MODY from other forms of diabetes. The diagnosis of MODY should be suspected in patients with family history of diabetes of any type, diagnosed at a young age (<25 years), lack of type 1 DM characteristics (the absence of islet autoantibodies, preserved β -cell function with low or no insulin requirements and detectable C-peptide over an extended partial remission phase), the absence of typical type 2 DM characteristics (severe obesity, acanthosis nigricans or other markers of metabolic syndrome) and in cases of mild stable fasting hyperglycemia which does not progress.^{3 4 11 12}

HNF1A-MODY is the most common form of monogenic diabetes that leads to familial symptomatic diabetes and the most probable clinical diagnosis to be considered in families with autosomal dominant symptomatic diabetes.³ In earlier stages of the disease, often evident during adolescence or early adulthood, the fasting blood glucose may be normal, but patients tend to show a large increment in blood glucose (>80 mg/dL) after meals or at 2 hours during an oral glucose tolerance test (OGTT) and glucose intolerance. Patients with HNF1A-MODY typically have low renal threshold for glucose reabsorption due to impaired renal tubular transport of glucose and may present postprandial glycosuria, before developing significant hyperglycemia. In later stages, the patient develops osmotic symptoms such as polydipsia or polyuria, and fasting hyperglycemia appears, but ketosis is not frequent, since some residual insulin secretion is maintained for several years. The occurrence of microvascular and macrovascular complications depends on metabolic control, similar to type 1 and 2 DM.³

As described before, one of the biggest diagnostic challenges is to differentiate between MODY from type 1 and 2 diabetes, as clinical features might be similar and due to a frequent overlap between phenotypes. Genetic testing is crucial to define the aetiology, allowing appropriate and individualised care, accurate prognosis, predict complications and adequate family counselling.^{3 9}

CASE PRESENTATION

A previously healthy 13-year-old girl, with non-consanguineous parents, was admitted to the paediatric emergency department with headache and vomits during the last 48 hours. She was hemodynamically stable and afebrile. Her physical examination was unremarkable, with no acanthosis



© BMJ Publishing Group Limited 2021. Re-use permitted under CC BY-NC. No commercial re-use. See rights and permissions. Published by BMJ.

To cite: Oliveira RV, Bernardo T, Martins S, et al. *BMJ Case Rep* 2021;**14**:e231837. doi:10.1136/bcr-2019-231837

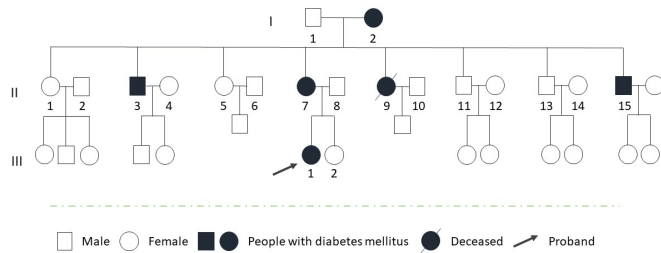


Figure 1 Patient's family history regarding a diabetes mellitus (DM) diagnosis. I 2—Grandmother with DM2 diagnosed in her youth, medicated with oral antidiabetic medication; II 7—Mother with DM2 diagnosed at 21 years old, medicated with slow-acting insulin; II 3, 9, 15—Three uncles with DM2 diagnosed in youth and medicated with oral antidiabetic medication or with long-acting insulin (one deceased). III 1—maturity onset diabetes of the young diagnosed at 13 years old.

nigrans, lipodystrophy or striae and body mass index of 22 kg/m² (85th percentile, according with curves of WHO adjusted for age and sex).

INVESTIGATIONS

Laboratory evaluation showed glycosuria and hyperglycemia of 177 mg/dL without ketosis. The HbA_{1c} was 6.8%. She was admitted for clinical observation. Family history was positive for DM classified as type 2 diagnosed as young adults, with an autosomal dominant pattern among maternal family: grandmother, her mother and three uncles, from a total of eight brothers (figure 1). During hospitalisation no insulin therapy was required and started a sugar-free fast-absorption diet. The fasting glucose remained normal. During postprandial period she presented glycemic values ranging from 150 to 177 mg/dL and glycosuria. An OGTT was performed with 75 g of glucose and 65 mg/dL glycemia was obtained at 0 hours and 217 mg/dL after 2 hours of ingestion. Islet cell antibodies (ICAs) were positive (not dosed) while anti-glutamic acid decarboxylase antibodies and autoantibodies specific to human insulin (IAA) were negative. C-peptide value was normal, 3.74 ng/mL (reference range 0.8–4.2 ng/mL). Liver and renal function tests were normal, with an adequate lipid profile.

Family history of DM with dominant pattern, plus normal fasting glycemia with important increment in blood glucose after meals and at 2 hours during an OGTT plus the absence of characteristic pattern of type 2 diabetes lead to the suspicion of a monogenic disorder, despite the positivity of ICA.

After informed consent, a genetic test for MODY3 was performed, detecting a mutation in allele c.687_707del and protein p.glu230_Cys236del, in heterozygosity of the HNF1A gene, which was not reported in literature, but was compatible with the diagnosis of MODY3. Posteriorly the same variant was detected in her mother and one uncle with diabetes. A disease-free uncle did not carry the mutation.

TREATMENT

Initial treatment with low dose of sulfonylureas (glibenclamide, 1.25 mg/day) before breakfast and fast-absorption sugar-free diet was started, without hypoglycemic events. At day three the patient was discharged with ambulatory follow-up by paediatric endocrinology.

OUTCOME AND FOLLOW-UP

One year after the diagnosis, C-peptide remains normal and ICAs became negative. After 2 years of follow-up the patient presents high-density lipoprotein cholesterol (HDL-C) of 82 mg/dL, maintained normoglycemia with an HbA_{1c} of 5.5% and no comorbidities. Presently she is 19 years old, maintains treatment with low-dose of sulfonylureas (recently adjusted to twice daily to maintain a good metabolic control) and has no evidence of microvascular complications.

DISCUSSION

The main obstacle to the diagnosis of monogenic diabetes is lack of awareness and clinical suspicion. Conjunction of clinical and laboratory features is imperative in order to recognise patients with MODY, commonly misdiagnosed with type 1 or 2 DM.

In this patient, the absence of obesity, acanthosis nigricans or other metabolic syndrome markers were not suggestive of type 2 DM. Despite the positivity of ICAs, which may suggest type 1 DM, the family history of DM with a dominant pattern in non-obese patients, normal fasting glycemia with detectable glycosuria and important increment in blood glucose after meals and at 2 hours during an OGTT, increased clinical suspicion of a monogenic disorder.

Growing evidence suggests that autoantibodies are present in other types of diabetes beyond DM1. However, autoantibodies can rarely be detected in other types of diabetes or in a healthy population. Several case reports described autoantibodies in patients with MODY.¹³ Recent studies have described positivity for at least one β -cell autoantibody in 25% of the HNF1A patients.⁶ It was reported that such patients are associated with delayed diabetes onset and poor glycemic control. As autoantibody expression is not accompanied by a concurrent significant decline in β -cell function, autoantibody expression does not influence the demands of treatment.^{6 13} Therefore, the presence of pancreatic antibodies should not preclude genetic testing in cases of high clinical suspicion.⁶

C peptide level was normal, but normal values can occur in early stages of DM1, while endogenous insulin production is still present, thereby it has no diagnostic value in the initial course of the disease.^{5 6 12} In our patient, persistent normal values, during follow-up, are compatible with MODY diagnosis.

The presence of glycosuria, even with normal values of glycemia, and its frequency in this patient, lead to the suspicion of HNF1A-MODY. MODY subtype patients have a low renal threshold for glucose reabsorption through the proximal convoluted renal tubule due to reduced expression of the renal tubular transport. Prior to diabetes onset, mutation carriers have detectable glycosuria provoked by glucose loading. Testing for glycosuria 2 hours after a glucose load can be used to screen children of mutation carriers and guide the need for further evaluation. Postprandial glycosuria may be present before significant hyperglycemia.^{3 6 9}

Raised HDL-C levels, rather than low, are observed in patients with HNF1A-MODY, however, high levels of HDL-C is not translated into low cardiovascular risk.^{9 12}

The molecular test identified a variant not reported in previous literature, compatible with MODY3. Subsequently confirmed by its presence in the mother, a diabetic uncle and absent in a non-diabetic uncle.

MODY genetic diagnosis has important clinical implications to the patient and relatives.^{2 9 11} Although expensive and time consuming, it allows definitive diagnosis, therapeutic

optimisation plus prevention of micro and macrovascular complications and family counselling.⁹

Apart from fast-absorption sugar-free diet, most patients with HNF1A-MODY will need pharmacological treatment to achieve a better metabolic control and prevent micro and macrovascular complications. The MODY form is extremely sensitive to sulfonylureas.^{3,5,9} In our clinical case, treatment with low dose of glibenclamide allowed optimisation of metabolic control, without hypoglycemia described. According to literature, the initial dose should be low, to avoid hypoglycemia and a good control of fasting blood glucose and HbA_{1c} may be maintained for many years.^{3,4}

With this clinical case we alert to the importance of early recognition of signs and symptoms, which will increase awareness of MODY. Once suspicion is raised, a molecular genetic test should be performed and can provide the diagnosis of HNF1A-MODY, allowing early treatment and accurate family screening.

Learning points

- ▶ Maturity onset diabetes of the young (MODY) is a genetically and clinically heterogeneous group of conditions. Its identification remains a challenge to physicians and is largely underdiagnosed.
- ▶ HNF1A-MODY is the most common form of monogenic diabetes that results in familial symptomatic diabetes, with heterozygous HNF1A mutations.
- ▶ Clinical clues and analytical results will improve its suspicion, allowing a genetic identification of HNF1A-MODY and appropriate patient care and family advice.
- ▶ From a clinical point of view, it should be noted that the presence of pancreatic antibodies can discourage physicians from genetic testing, and diagnosis. In cases of high clinical suspicion we highlight the importance of not preclude genetic testing.
- ▶ Most patients with HNF1A-MODY will need pharmacological treatment as they show progressive deterioration of glycemic control. They are extremely sensitive to low-doses of sulfonylureas, which usually allows a better glycemic control, especially in children and young adults.

Contributors RVO wrote the article. TB design and conceptualisation of the case report, involved in clinical care, acquisition of data, analysis and interpretation of data. RVO, TB, SM and AS planned and conceived the present case report as well as discussed the results and contributed to the final manuscript.

Funding The authors have not declared a specific grant for this research from any funding agency in the public, commercial or not-for-profit sectors.

Competing interests None declared.

Patient consent for publication Obtained.

Provenance and peer review Not commissioned; externally peer reviewed.

Open access This is an open access article distributed in accordance with the Creative Commons Attribution Non Commercial (CC BY-NC 4.0) license, which permits others to distribute, remix, adapt, build upon this work non-commercially, and license their derivative works on different terms, provided the original work is properly cited and the use is non-commercial. See: <http://creativecommons.org/licenses/by-nc/4.0/>.

REFERENCES

- 1 Oliva CY, Domínguez CP, Pérez MPR, *et al.* Hyperglycemia: not just type 1 diabetes. our experience in the last 23 years. *Revista Española Endocrinología Pediátrica* 2018;9:21–9.
- 2 McDonald TJ, Ellard S. Maturity onset diabetes of the young: identification and diagnosis. *Ann Clin Biochem* 2013;50:403–15.
- 3 Hattersley AT, Greeley SAW, Polak M, *et al.* ISPAD clinical practice consensus guidelines 2018: the diagnosis and management of monogenic diabetes in children and adolescents. *Pediatr Diabetes* 2018;19 Suppl 27:47–63.
- 4 Hattersley AT, Patel KA. Precision diabetes: learning from monogenic diabetes. *Diabetologia* 2017;60:769–77.
- 5 Misra S, Owen KR. Genetics of monogenic diabetes: present clinical challenges. *Curr Diab Rep* 2018;18:141.
- 6 Firdous P, Nissar K, Ali S, *et al.* Genetic testing of maturity-onset diabetes of the young current status and future perspectives. *Front Endocrinol* 2018;9:253.
- 7 Stanik J, Dusatkova P, Cinek O, *et al.* De novo mutations of GCK, HNF1A and HNF4A may be more frequent in MODY than previously assumed. *Diabetologia* 2014;57:480–4.
- 8 Isomaa B, Henricsson M, Lehto M, *et al.* Chronic diabetic complications in patients with MODY3 diabetes. *Diabetologia* 1998;41:467–73.
- 9 Ilharco M, Nunes JS. Maturity-Onset diabetes of the young: um tipo de diabetes ainda subdiagnosticado Na prática clínica. *Revista Portuguesa de Diabetes* 2018;13:49–61.
- 10 Ovsyannikova AK, Rymar OD, Ivanoshchuk DE, *et al.* A case of maturity onset diabetes of the young (MODY3) in a family with a novel HNF1A gene mutation in five generations. *Diabetes Ther* 2018;9:413–20.
- 11 Thanabalasingham G, Owen KR. Diagnosis and management of maturity onset diabetes of the young (MODY). *BMJ* 2011;343:d6044–9.
- 12 Gardner D, Tai ES. Clinical features and treatment of maturity onset diabetes of the young (MODY). *DMSO* 2012;5:101–8.
- 13 Urbanová J, Rypáčková B, Procházková Z, *et al.* Positivity for islet cell autoantibodies in patients with monogenic diabetes is associated with later diabetes onset and higher HbA_{1c} level. *Diabet Med* 2014;31:466–71.

Copyright 2021 BMJ Publishing Group. All rights reserved. For permission to reuse any of this content visit <https://www.bmj.com/company/products-services/rights-and-licensing/permissions/>
BMJ Case Report Fellows may re-use this article for personal use and teaching without any further permission.

Become a Fellow of BMJ Case Reports today and you can:

- ▶ Submit as many cases as you like
- ▶ Enjoy fast sympathetic peer review and rapid publication of accepted articles
- ▶ Access all the published articles
- ▶ Re-use any of the published material for personal use and teaching without further permission

Customer Service

If you have any further queries about your subscription, please contact our customer services team on +44 (0) 207111 1105 or via email at support@bmj.com.

Visit casereports.bmj.com for more articles like this and to become a Fellow