

A prospective Phase II study for the efficacy of radiotherapy in combination with zoledronic acid in treating painful bone metastases from gastrointestinal cancers

Jinhyun Choi^{1,2}, Eun Jung Lee¹, Seung Hyun Yang¹, Yoo Ri Im¹
and Jinsil Seong^{1,*}

¹Department of Radiation Oncology, Yonsei Cancer Center, Yonsei University College of Medicine, Seoul, 50–1 Yonsei-ro, Seodaemun-gu, Seoul 03722, Korea

*Corresponding author. Department of Radiation Oncology, Yonsei Cancer Center, Yonsei University College of Medicine, 50–1 Yonsei-ro, Seodaemun-gu, Seoul 03722, Korea. Tel: +82-2-2228-8095; Fax: 82-2-2227-7823; Email: JSSEONG@yuhs.ac

²Present address: Department of Radiation Oncology, Jeju National University Hospital, Jeju National University School of Medicine, Jeju, Korea
(Received 5 June 2018; revised 30 July 2018; editorial decision 4 October 2018)

ABSTRACT

We investigated the efficacy of combined radiotherapy (RT) and zoledronic acid in treating painful bone metastases from gastrointestinal cancers. Sixty patients were prospectively enrolled between November 2014 and July 2016. The most common primary cancer type was hepatocellular carcinoma (HCC, $n = 25$), followed by colorectal cancer ($n = 6$). Patients received external beam RT of 30–54 Gy in 10–17 fractions or 20 Gy in 5 fractions for symptomatic bone metastases. On the first day of RT, patients received 4 mg intravenous zoledronic acid, which was repeated monthly for a total of six cycles. The mean pain score before treatment was 6.7, and it decreased to 2.8 at 1 month and 2.1 at 3 months ($P < 0.001$). The overall pain response rates at 1 and 3 months were 95% and 96%, respectively. Among the 24 patients who underwent magnetic resonance imaging, 71% were responders, with a complete response in 1 patient and partial in 16 patients. Combined treatment significantly decreased levels of macrophage inflammatory protein-1 α and matrix metalloproteinase (MMP)-2 and -3 compared with baseline (all $P < 0.05$). In HCC patients, IL-6 and MMP-9 levels were significantly lower 1 month after treatment ($P < 0.05$). The mean quality of life (QOL) score improved from 66 to 56 at 1 month ($P < 0.001$) and 55 at 3 months ($P = 0.016$). The median survival was 7 months. In conclusion, RT with zoledronic acid decreased bone pain and improved QOL in patients with painful bone metastases from gastrointestinal cancers. Radiographic findings and serum biomarker measurements were closely correlated with therapeutic responses.

Keywords: bone metastasis; gastrointestinal cancer; radiotherapy; zoledronic acid

INTRODUCTION

Bone metastases are responsible for devastating complications, including severe pain, pathologic fractures, hypercalcemia, spinal cord compression, and impaired mobility. Approximately two-thirds of patients with metastatic cancer experience pain, which is often attributable to primary cancers that have metastasized to bone [1]. Furthermore, patient morbidity is essentially due to bone metastases because disease is usually incurable once tumors spread to the bone.

In addition to underlying tumor management, palliative treatment for pain control and neurologic deficits are needed to improve quality of life (QOL) and function in patients with bone metastases [2].

Radiotherapy (RT) can provide significant relief of painful bone metastases in 60–90% of patients, and 33% of patients achieve complete response at the treatment site and reduce analgesic requirements for these patients [3]. Zoledronic acid is the gold standard for the systemic management of metastatic bone disease. Indications

for treatment include prevention of skeletal complications and bone pain relief [4]. Recent studies have shown that RT and zoledronic acid reduce bone pain and skeletal complications individually, and there is evidence of a synergistic effect when they are combined [5, 6]. However, most studies have included patients with metastatic bone disease from breast or prostate cancer, and there is limited data on the efficacy of combined treatment in gastrointestinal cancer patients.

In this prospective Phase II study, we investigated the efficacy and safety of RT combined with zoledronic acid to treat painful bone metastasis from gastrointestinal cancers. To establish a more optimal approach in bone metastases, we assessed whether changes in serum biomarkers and radiologic findings were related to the clinical response to treatment.

MATERIALS AND METHODS

Patients

Eligibility criteria included patients with bone metastases from gastrointestinal cancer, which were identified by X-ray, computed tomography (CT), or magnetic resonance imaging (MRI). Patients were aged 20 years or older with performance status 0–2 according to the Eastern Cooperative Oncology Group (ECOG), and worst pain scores of >3 due to bone metastasis at the treatment site as assessed by the Numeric Rating Scale (NRS) prior to treatment. Patients had no indication for surgical procedures because of pathologic fracture, spinal cord compression, or impending fracture before clinical trial inclusion. Patients were excluded if they had received previous zoledronic acid or other bisphosphonate therapy (or without interruption within 2 years) or surgery to the affected region. Patients with Paget’s disease, primary hyperparathyroidism, psychological disease, severe renal dysfunction, or symptomatic brain metastasis were also excluded. The Institutional Review Board of the Severance Hospital, Korea (IRB No. 4-2014-0440) approved this prospective study in accordance with ethical guidelines and the Declaration of Helsinki. All recruited patients provided written informed consent.

Treatments

The study design is shown in Fig. 1. Patients were treated with external beam RT for symptomatic bone metastases. Radiation was given 5 days per week at a dose of 30–54 Gy in 10–17 fractions or

20 Gy in 5 fractions. Treatment was planned with either a conventional 2D technique or CT-based 3D conformal or intensity-modulated RT techniques. On the first day of RT, patients received an intravenous ZOLENIC® injection (zoledronic acid) of 4 mg during a 15 min infusion. Zoledronic acid treatment was repeated every 4 weeks for a total of six cycles. Upon each cycle of injection initiation, the recommended dose was achieved in patients according to their creatinine clearance (Ccr, ml/min): 4 mg for those with Ccr >60, 3.5 mg for Ccr of 50–60, 3.3 mg for Ccr of 40–49, and 3 mg for Ccr of 30–39. ZOLENIC® injections were provided free of charge by SAMYANG biopharmaceuticals corporation (Seongnam, South Korea). The use of analgesics or other medication was based on the physician’s medical judgment.

Assessments

All patients underwent physical examination including neurologic assessments and performance status using the ECOG criteria at baseline and 1, 3 and 6 months after RT. Pain intensity at the treatment site was evaluated every assessment day using the Brief Pain Inventory (BPI), which assesses pain at its ‘worst,’ ‘least,’ ‘average,’ and ‘now’ (current pain). In this trial, ‘worst’ was used to represent the pain severity experienced for the previous 24 hours by the NRS scale, graded from 0 to 10. Radiologic evaluations using MRI were performed at baseline and 3 months after completing RT. Response rates including CR, partial response (PR), stable disease (SD) and progressive disease (PD) are defined as in the Response Evaluation Criteria in Solid Tumors (RECIST). To assess the QOL of cancer patients participating in this study, the European Organisation for Research and Treatment of Cancer QOL questionnaire (EORTC QLQ-C30) scale in which patient-reported outcomes are collected was used. Serum samples were acquired at baseline, immediately after RT, and 1 month after RT to measure biomarker changes in association with improvement due to osteoclast inhibition. Biomarkers included inflammatory cytokines such as multiple interleukins (IL-1, -6, -7, -8 and -12), receptor activator of nuclear factor- κB ligand (RANKL), osteoprotegerin (OPG), macrophage inflammatory protein-1α (MIP-1α) and matrix metalloproteinases (MMP-1, -2, -3 and -9), which were analyzed by enzyme-linked immunosorbent assays (ELISAs). The Common Terminology Criteria for Adverse Events v4.0 was used for toxicity assessment.

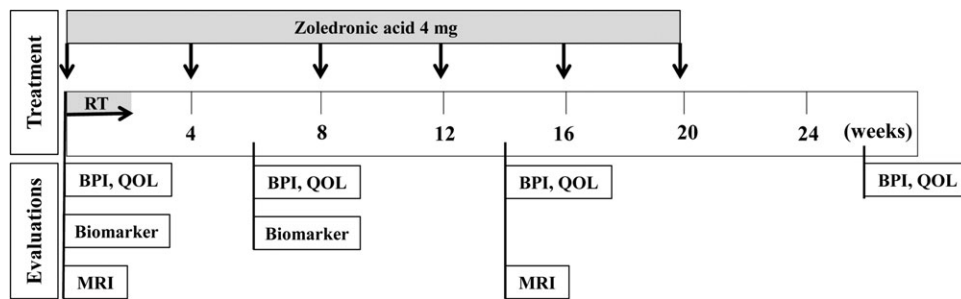


Fig. 1. Study design: sequences of combined treatment and evaluations at baseline and 1, 3 and 6 months after treatment. BPI = Brief Pain Inventory, MRI = magnetic resonance imaging, QOL = quality of life, RT = radiotherapy.

Statistical analyses

The number of samples was calculated according to Simon's two-stage optimal design. The expected therapeutic response rate was assumed to be at least 50% and 70%, and the dropout rate was calculated as 40%. In this case, 15 patients are needed in the first stage. Of these, 8 patients are required to have the response for the next stage. In the second stage, 43 patients are needed, of which more than 26 are considered to be significant when they have responses. Considering the dropout rate, a total of 60 patients are needed. The primary end point was defined as the proportion of patients who had a decreased pain score after treatment compared with baseline. BPI and QOL scores were analyzed using the Wilcoxon signed-rank test for pairwise comparison. Biomarker levels are given as mean values, and comparisons between pre- and post-treatment were analyzed with paired *t*-tests. For MRI evaluations, we defined CR and PR as responders and SD and PD as non-responders. Overall survival was defined from the date of the first combination treatment to the date of the last follow-up or death. Survival data were analyzed using the Kaplan–Meier method. Statistical analyses were performed with SPSS version 20.0 (IBM Corp., Armonk, NY, USA). A *P*-value of ≤ 0.05 was considered statistically significant.

RESULTS

Clinical characteristics

A total of 60 patients were enrolled between November 2014 and July 2016. Nineteen patients withdrew due to disease progression in other visceral organs ($n = 9$) or refusal ($n = 10$). Table 1 lists patient and tumor characteristics. The most common primary cancer type was hepatocellular carcinoma (HCC, $n = 25$), followed by colorectal cancer ($n = 6$) and cholangiocarcinoma ($n = 5$). The median age was 62 years at the time of treatment (range, 41–79). Non-spine sites ($n = 17$, 42%) were most common, and both spine and non-spine lesions were observed in 10 patients (24%). One to 4 bone metastases were observed in 21 patients (72%), and 18 patients (62%) had synchronous metastases in non-bone locations. The mean bone pain score prior to treatment was 6.7 (range, 3–10). The number of patients available for analysis 1, 3 and 6 months after RT completion were 41, 30 and 20, respectively.

Pain response

Figure 2 shows the mean pain scores according to follow-up evaluations. After combined treatment, the mean pain score decreased from 6.7 to 2.8 at 1 month, to 2.1 at 3 months ($P < 0.001$), and to 3 at 6 months after treatment ($P = 0.003$). According to the proportion of patients who had pain relief, the overall pain response rates were 95% at 1 month, 96% at 3 months (Fig. 3A), and 67% at 6 months, respectively. The proportion of patients with worst pain score < 3 were 54%, 60% and 45% at 1 month, 3 months and 6 months, respectively. On the other hand, 2.5%, 3.7% and 17% of patients experienced pain progression at 1, 3 and 6 months after treatment. Of the 20 patients who had completed 6 months of follow-up, the median duration of post-RT pain response was 6.5 months.

Table 1. Characteristics of evaluated patients at 1 month after treatment

Characteristic	Number of patients	Percentage (%)
Age (years)		
Median (range)	62.3 (41–79)	
Sex		
Male	35	85.4
Female	6	14.6
Primary cancer		
Colon/rectum	6	14.6
HCC	25	61
Pancreas	2	4.9
GB	3	7.3
CBD	5	12.2
Location		
Spine	14	34.1
Non-spine	17	41.5
Both	10	24.4
Baseline pain score		
Mean (range)	6.73 (3–10)	
Number of bone metastases		
1–4	28	68.3
>4	13	31.7
Metastasis other than bone		
Yes	23	56.1
No	18	43.9

CBD = common bile duct, GB = gallbladder, HCC = hepatocellular carcinoma.

Radiologic evaluations

MRI at 3 months after treatment revealed a CR in 1 patient, PR in 16 patients and SD in 7 patients. None showed radiologically deteriorated PD (Fig. 3B). As a result, 71% of the 24 patients who underwent MRI were classified as responders (CR+PR).

QOL

The EORTC QLQ-C30 questionnaire consists of 30 items; the lower the score for Items 1 to 28, the better the patient's function. The 29th and 30th items correspond to the overall health status, with a better QOL with a higher score. Therefore, we divided items 1–28 into Category A and 29–30 into Category B to compare QOL

before and after treatment. As shown in Fig. 4, the Category A score improved from 66 to 56 ($P < 0.001$) after 1 month of treatment, to 55 ($P = 0.016$) after 3 months of treatment, and to 61 ($P = 0.446$) after 6 months of treatment. Category B scores also improved from 6.7 to 7.5 ($P = 0.096$), 8.4 ($P = 0.034$) and 7.9 ($P = 0.418$) at 1, 3 and 6 months, respectively.

Serum biomarker evaluations

Biomarker evaluation at baseline, post-RT, and 1 month later is shown in Fig. 5. There were significant changes in levels (mean \pm standard deviation) of osteoclastogenic or tumor metastatic factors, including MIP-1 α and MMP-2 and -3 1 month after RT compared with baseline ($P < 0.05$). The combined treatment significantly decreased MIP-1 α (46.28 ± 18.91 to 8.11 ± 4.24), MMP-2 ($21\ 025.27 \pm 1249.08$ to $16\ 727.54 \pm 1023.88$) and MMP-3 ($34\ 455.91 \pm 3845.49$ to $29\ 996.04 \pm 7742.28$) compared with baseline values. For subgroup analysis to identify bone metastasis-specific biomarkers in HCC patients, we compared the serum collected at baseline between

patients who received RT with or without bone metastases. There were significant differences in levels of IL-6 and MMP-3 and -9 between the two groups at baseline. In HCC patients, IL-6 (268.02 ± 180.25 to 7.12 ± 4.61), MIP-1 α (45.86 ± 20.84 to 4.92 ± 2.0), MMP-2 ($21\ 987.4 \pm 1552.47$ to $16\ 135.27 \pm 1096.7$), MMP-3 ($38\ 544.71 \pm 4816.76$ to $19\ 976.47 \pm 1935.6$) and MMP-9 ($28\ 100.62 \pm 3978.52$ to $20\ 959.96 \pm 3368.57$) expression were also significantly decreased 1 month after treatment ($P < 0.05$).

Overall survival and toxicity

The median and 1-year survival rates of all patients were 7 months and 48%, respectively. The corresponding values in HCC patients were 7.4 months and 61%. Combined treatment was well tolerated in all patients, and Grade III or higher toxicity was not observed during treatment. Two patients experienced transient high fever (39°C) after zoledronic acid injection. Grade II hypocalcemia ($7.0\text{--}7.9\text{ mg/dl}$) was noted in three patients. Renal toxicity was observed in one patient as Grade II, with a 2.7-fold increase in creatinine after 3 months of treatment. No skeletal-related event was observed during treatment or until last follow-up date.

DISCUSSION

Radiation and bisphosphonates are well-established treatment modalities for painful bone metastases. Moreover, recent reports have described a potential radiosensitizing effect of zoledronic acid in various cancers [7, 8]. There have been several investigations of the combined effects of zoledronic acid with radiation [9]. Vassiliou *et al.* [10] published a pilot study of RT combined with ibandronate. Forty-five patients with various solid tumors received 10 cycles of monthly intravenous ibandronate (6 mg) and local RT (30–40 Gy). Combined therapy provided substantial bone pain relief, and bone density assessed by CT increased by 20%, 46% and 73% at 3, 6 and 10 months, respectively. In a Phase II trial by Berning *et al.* [11], 52 patients with various tumors received less than the optimal dose of ibandronate (4 mg), which was associated with a significant reduction in bone pain scores. Several studies reported

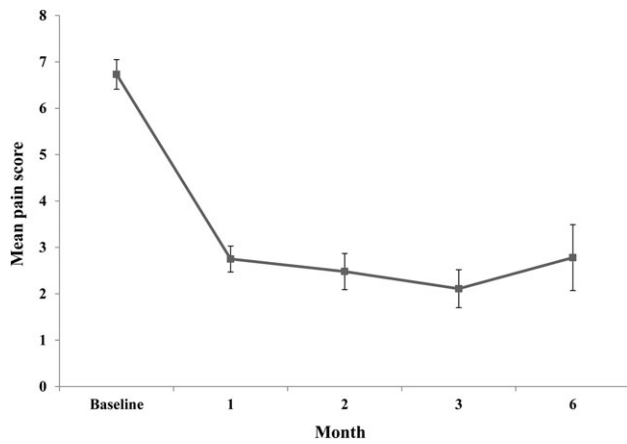


Fig. 2. Mean pain score at baseline and at 1, 2, 3 and 6 months after treatment. All $P < 0.05$ vs baseline.

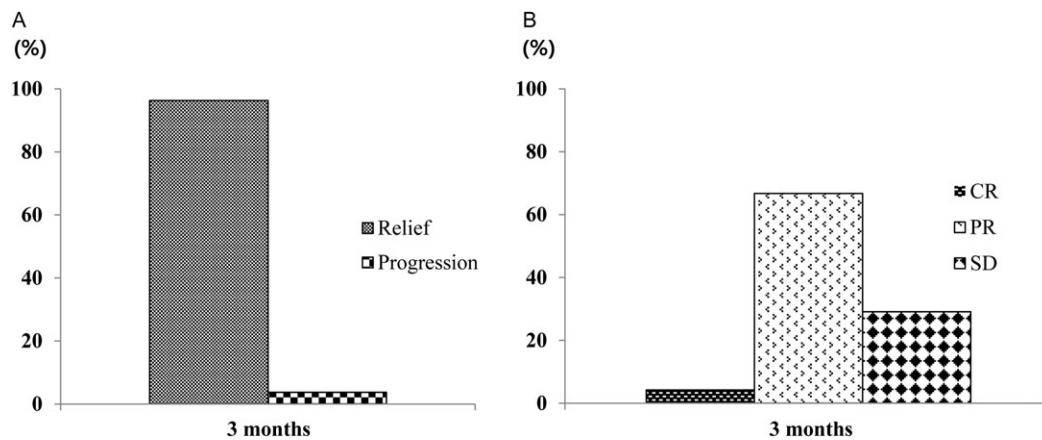


Fig. 3. Overall pain response (A) and radiologic response rate by MRI (B) at 3 months after treatment vs baseline. CR = complete response, MRI = magnetic resonance imaging, PR = partial response, SD = stable disease according to RECIST (Response Evaluation Criteria in Solid Tumors).

significant and substantial reductions in bone pain within 3 months of treatment, although different bisphosphonates were used [12, 13].

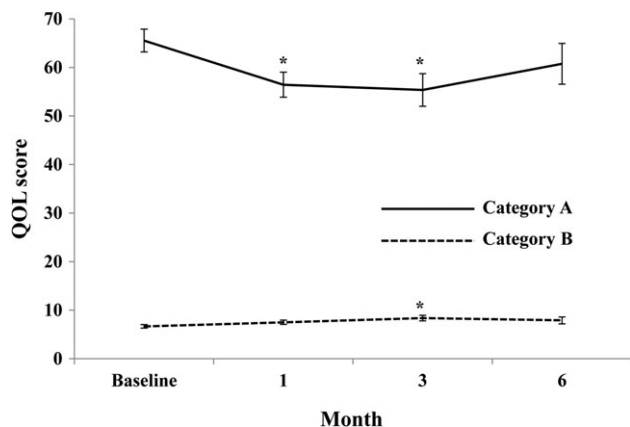


Fig. 4. Quality of life score (Categories A and B) measured with the European Organisation for Research and Treatment of Cancer QLQ-C30 questionnaire at baseline and at 1, 2, 3 and 6 months after treatment. * $P < 0.05$ vs baseline.

Previous studies reported a small number of patients with gastrointestinal cancer. Clinical studies have been quite limited regarding the combined effects of RT and zoledronic acid as well as RT alone for gastrointestinal cancers, with only a few for HCC or for colorectal cancers. Radiation therapy was effective in painful bone metastasis from HCC in 73% of patients with median survival of 4.5 months [14, 15]. A retrospective analysis on stability of bone metastasis in colorectal cancer showed that re-calcification after RT was observed in 3% of patients with median bone survival of 4.2 months [16]. This paucity of data could be attributed to at least two reasons. First, the survival rate of patients with gastrointestinal cancer is poor, so the disease is treated conservatively. Next, bone metastases are classified as osteolytic, osteoblastic or mixed according to the primary mechanism of interference with normal bone remodeling [17]. In the case of gastrointestinal cancer, the pattern of bone metastasis is not one dominant type such as in breast or prostate cancer; rather, it is a mixture of both osteolytic and osteoblastic components. Therefore, it can be assumed that one treatment modality would not improve patient prognosis. The main activity of bisphosphonates is inhibition of osteoclastic bone resorption [18]. RT can shrink tumors due to high levels of cancer cell death, which may allow osteoblasts to repair affected bones [19]. The remarkably high clinical response in the present study may be related to the simultaneous action of both treatment modalities,

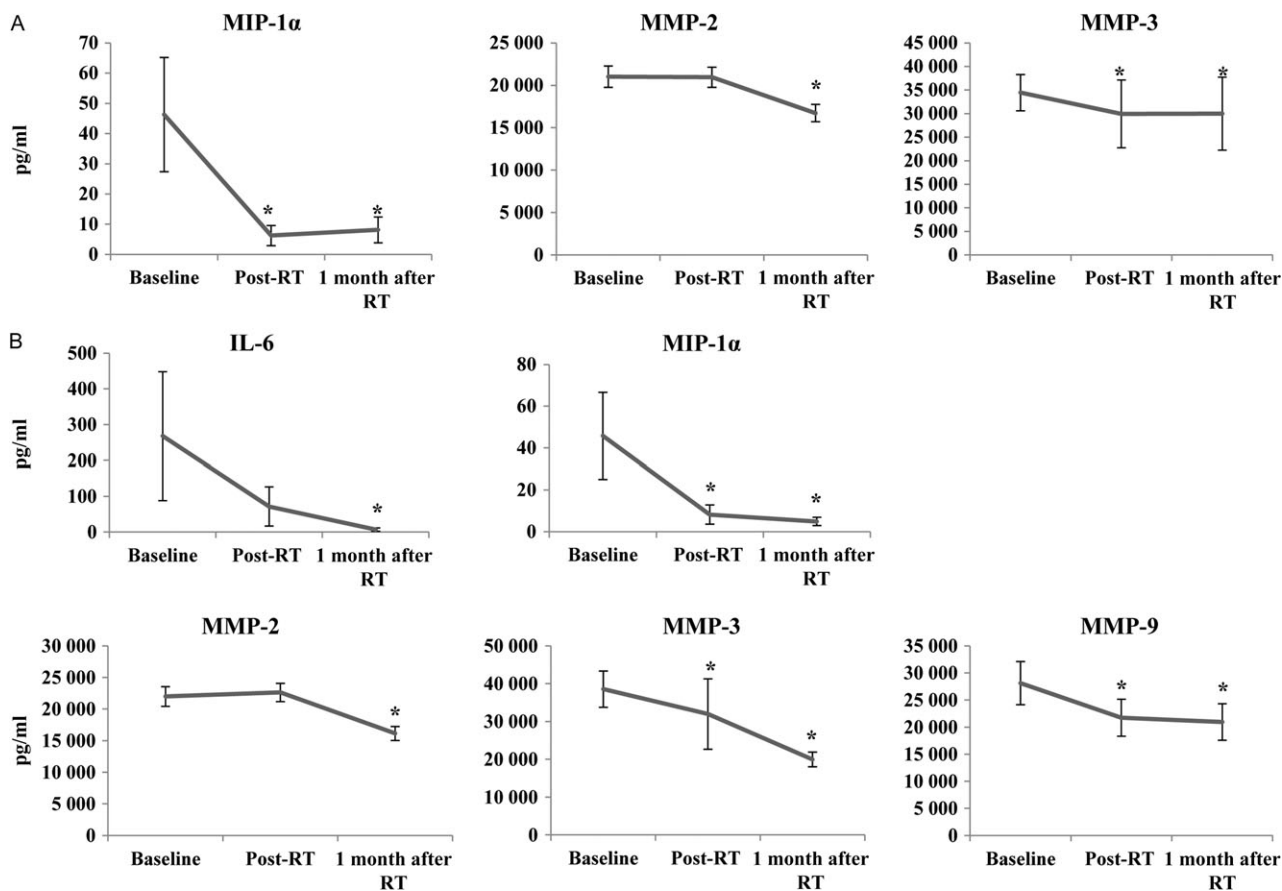


Fig. 5. Changes in biomarker values after treatment in all patients (A) and HCC patients (B). * $P < 0.05$ vs baseline.

suggesting that new strategies are necessary to improve the prognosis of bone metastasis in patients with gastrointestinal cancer. In fact, the median survival time in this study was 7 months, which is higher than the average. To our knowledge, this is the first report of a bone metastatic response using objective methods to clarify the effect of combining therapy in gastrointestinal cancer.

Patients in the present study were treated with combined intravenous zoledronic acid 4 mg and multifraction local RT, which were well tolerated without serious adverse effects. The mean pain score after combination treatment decreased from 6.7 to 2.8 at 1 month and to 2.1 at 3 months, with an overall pain response of 96%. Maximal pain relief was observed within 3 months, although pain scores were significantly reduced below baseline until the end of the study. Radiologically, the response rate was 71% with a CR in 1 patient and PR in 16 patients as assessed by bone lesions on MRI. The response rate typically refers to how frequently a tumor shrinks anatomically. However, changes in tumor size can be minimal in spinal metastases, despite effective treatment, so the remaining patients with SD (29%) can also be considered to have had a therapeutic response. Improved functional scores and measures of QOL correlated with the radiologic response. There were also significant decreases in levels of osteoclast and tumor metastatic factors, which are closely related to the clinical response. Our results are the first scientific evidence that the combined clinical application of zoledronic acid and RT increases therapeutic effects and improves clinical efficacy.

In osteolytic metastases, bone destruction is mediated by osteoclasts rather than tumor cells. Several osteoclastogenic factors such as IL-1, IL-6 and MIP-1, have been implicated in the increased activity of osteoclasts in myeloma [20]. We evaluated biochemical markers of bone turnover, tumor proliferation, and adhesion. According to previous studies, these values vary [21, 22]. We found that changes in MIP-1 α , MMP-2 and MMP-3 levels correlated with the clinical response to combination therapy. Interestingly, the expression levels and changes in IL-6, MMP-3 and MMP-9 were highly associated with bone metastasis and therapeutic response in HCC patients. IL-6, a potent stimulator of osteoclast formation, appears to have an important role in enhancing cancer cell growth or prolonging their survival [20]. High serum IL-6 correlates with tumor aggressiveness and associated tumor factors that affect treatment outcome in patients with HCC who receive locoregional therapy [23, 24]. Chen *et al.* [25] suggested that IL-6 inhibitors could be a potential therapeutic strategy for increasing the radiation response of liver tumors. Our subgroup analysis revealed that IL-6 is a useful indicator for predicting combined treatment outcomes. One of the major effects of MMP activity in cancer progression is extracellular matrix degradation, which allows cancer cells to migrate out of the primary tumor and metastasize [26]. Although clinical trials have yielded disappointing results, MMP inhibitors offer significant potential for improving cancer treatment by slowing the process of cancer cell invasion and metastasis [27]. While we did not investigate the underlying mechanism, our results suggest that reducing MMP expression through combination therapy is associated with less pain and imaging responses. However, different factors are produced by tumor cells or the microenvironment in response to tumor-mediated bone destruction processes [28]. Thus,

the biomarkers identified here must be verified in further large-scale studies.

QOL was assessed using the EORTC QLQ-C30 questionnaire, which is highly sensitive to changes in patient performance status [29]. The bone disease-related functional and global scale scores significantly improved. In general, a 10-point change on the QLQ-C30 is considered clinically significant, and a 20-point or higher improvement on the scale is much more significant, indicating a strong effect [30]. According to the criteria, improvements in all functional scales were >10 points at 3 months after treatment, and the QOL assessment in this study indicated considerable clinical significance.

The main limitation of this study is that primary tumor types were not well balanced, with most patients having HCC. In addition, we did not consider other factors affecting prognosis by including patients with uncontrolled primary sites and those with metastases to extraosseous organs. Nevertheless, the therapeutic effect was significant. Future randomized Phase III trials are required to support the routine use of combined treatment for bone metastases from gastrointestinal cancers.

In conclusion, our results indicate that combined local RT and zoledronic acid relieves pain and increases QOL in patients with painful bone metastases. We objectively and subjectively assessed the response to treatment. Along with high rates of bone pain relief, several clinical outcomes such as QOL, serum biomarkers, and radiologic findings also improved significantly. This study provides a rationale for the clinical application of combination therapy for patients with bone metastases from gastrointestinal cancers.

CONFLICT OF INTEREST

The authors declare that there are no conflicts of interest.

FUNDING

This study was supported by the National Nuclear R&D Program through a National Research Foundation of Korea (NRF) grant funded by the Ministry of Science and ICT (Grant number; NRF 2017M2A2A7A02070426) and the Samyang research fund from Samyang Biopharmaceuticals Corporation of Korea.

Trial registration: ClinicalTrials.gov Identifier: NCT02784652; <https://clinicaltrials.gov/ct2/show/NCT02784652>

REFERENCES

1. von Moos R, Costa L, Ripamonti CI *et al.* Improving quality of life in patients with advanced cancer: targeting metastatic bone pain. *Eur J Cancer* 2017;71:80–94.
2. Yu HH, Tsai YY, Hoffe SE. Overview of diagnosis and management of metastatic disease to bone. *Cancer Control* 2012;19: 84–91.
3. Chow E, Zeng L, Salvo N *et al.* Update on the systematic review of palliative radiotherapy trials for bone metastases. *Clin Oncol* 2012;24:112–24.
4. Saad F, Chi K, Fleshner N. The role of bisphosphonates in the management of bone metastases in prostate cancer. *Can J Urol* 2004;11:2376–82.

5. Rosen LS, Gordon D, Kaminski M et al. Long-term efficacy and safety of zoledronic acid compared with pamidronate disodium in the treatment of skeletal complications in patients with advanced multiple myeloma or breast carcinoma: a randomized, double-blind, multicenter, comparative trial. *Cancer* 2003;98:1735–44.
6. Takeda N, Isu K, Hiraga H et al. Zoledronic acid enhances the effect of radiotherapy for bone metastases from renal cell carcinomas: more than a 24-month median follow-up. *J Orthop Sci* 2012;17:770–4.
7. Machak GN, Tkachev SI, Solovyev YN et al. Neoadjuvant chemotherapy and local radiotherapy for high-grade osteosarcoma of the extremities. *Mayo Clin Proc* 2003;78:147–55.
8. Drake MT, Clarke BL, Khosla S. Bisphosphonates: mechanism of action and role in clinical practice. *Mayo Clin Proc* 2008;83:1032–45.
9. Koto K, Murata H, Kimura S et al. Zoledronic acid significantly enhances radiation-induced apoptosis against human fibrosarcoma cells by inhibiting radioadaptive signaling. *Int J Oncol* 2013;42:525–34.
10. Vassiliou V, Kalogeropoulou C, Christopoulos C et al. Combination ibandronate and radiotherapy for the treatment of bone metastases: clinical evaluation and radiologic assessment. *Int J Radiat Oncol* 2007;67:264–72.
11. Berning D, Schafer U, Willich N et al. Combination of ibandronate and radiotherapy in metastatic bone disease—final results of a randomized phase II trial. *Radiother Oncol* 2004;73:S388–S9.
12. Body JJ, Diel IJ, Bell R et al. Oral ibandronate improves bone pain and preserves quality of life in patients with skeletal metastases due to breast cancer. *Pain* 2004;111:306–12.
13. Diel IJ, Body JJ, Lichinitser MR et al. Improved quality of life after long-term treatment with the bisphosphonate ibandronate in patients with metastatic bone disease due to breast cancer. *Eur J Cancer* 2004;40:1704–12.
14. Seong J, Koom WS, Park HC. Radiotherapy for painful bone metastases from hepatocellular carcinoma. *Liver Int* 2005;25:261–5.
15. Choi C, Seong J. Predictive factors of palliative radiotherapy response and survival in patients with spinal metastases from hepatocellular carcinoma. *Gut Liver* 2015;9:94–102.
16. Bostel T, Forster R, Schlamp I et al. Spinal bone metastases in colorectal cancer: a retrospective analysis of stability, prognostic factors and survival after palliative radiotherapy. *Radiat Oncol* 2017;12:115.
17. Macedo F, Ladeira K, Pinho F et al. Bone metastases: an overview. *Oncol Rev* 2017;11:321.
18. Dumon JC, Journe F, Kheddoumi N et al. Cytostatic and apoptotic effects of bisphosphonates on prostate cancer cells. *Eur Urol* 2004;45:S21–8; discussion 8–9.
19. Hoskin PJ. Bisphosphonates and radiation therapy for palliation of metastatic bone disease. *Cancer Treat Rev* 2003;29:321–7.
20. Roodman GD. Mechanisms of bone metastasis. *N Engl J Med* 2004;350:1655–64.
21. Wada N, Fujisaki M, Ishii S et al. Evaluation of bone metabolic markers in breast cancer with bone metastasis. *Breast Cancer* 2001;8:131–7.
22. Tamada T, Sone T, Tomomitsu T et al. Biochemical markers for the detection of bone metastasis in patients with prostate cancer: diagnostic efficacy and the effect of hormonal therapy. *J Bone Miner Metab* 2001;19:45–51.
23. Jang JW, Oh BS, Kwon JH et al. Serum interleukin-6 and C-reactive protein as a prognostic indicator in hepatocellular carcinoma. *Cytokine* 2012;60:686–93.
24. Cha H, Lee EJ, Seong J. Multi-analyte analysis of cytokines that predict outcomes in patients with hepatocellular carcinoma treated with radiotherapy. *World J Gastroenterol* 2017;23:2077–85.
25. Chen MF, Hsieh CC, Chen WC et al. Role of interleukin-6 in the radiation response of liver tumors. *Int J Radiat Oncol* 2012;84:E621–30.
26. Mook OR, Frederiks WM, Van Noorden CJ. The role of gelatinases in colorectal cancer progression and metastasis. *Biochim Biophys Acta* 2004;1705:69–89.
27. Bjorklund M, Koivunen E. Gelatinase-mediated migration and invasion of cancer cells. *Biochim Biophys Acta* 2005;1755:37–69.
28. Roodman GD. Mechanisms of disease: mechanisms of bone metastasis. *N Engl J Med* 2004;350:1655–64.
29. Aaronson NK, Ahmedzai S, Bergman B et al. The European Organization for Research and Treatment of Cancer QLQ-C30: a quality-of-life instrument for use in international clinical-trials in oncology. *J Natl Cancer Inst* 1993;85:365–76.
30. Osoba D, Rodrigues G, Myles J et al. Interpreting the significance of changes in health-related quality-of-life scores. *J Clin Oncol* 1998;16:139–44.