

**Original article:**

**PROTECTIVE ROLE OF *HIBISCUS SABDARIFFA* CALYX EXTRACT  
AGAINST STREPTOZOTOCIN INDUCED SPERM DAMAGE IN  
DIABETIC RATS**

Muhd Hanis Md Idris<sup>1</sup>, Siti Balkis Budin<sup>1</sup>, Mohamad Osman<sup>2</sup>, Jamaludin Mohamed<sup>1\*</sup>

<sup>1</sup> Programme of Biomedical Science, School of Diagnostic and Applied Health Sciences, Faculty of Health Sciences, Universiti Kebangsaan Malaysia, Jalan Raja Muda Abdul Aziz, 50300 Kuala Lumpur, Malaysia

<sup>2</sup> Faculty of Plantation and Agrotechnology, Universiti Teknologi MARA, 40450 Shah Alam, Selangor, Malaysia

\* corresponding author: Jamaludin Mohamed, Programme of Biomedical Science, School of Diagnostic and Applied Health Sciences, Faculty of Health Sciences, Universiti Kebangsaan Malaysia; E-mail: [jamal3024@yahoo.com](mailto:jamal3024@yahoo.com); Tel. No. : +603-9289 7560; Fax. No.: +603-2692 9032

**ABSTRACT**

Diabetes mellitus contributes to male sexual dysfunction and infertility by modulating oxidative damage. To date, a number of studies have demonstrated antioxidant properties of *Hibiscus sabdariffa* Linn. This study was designed to investigate the effects of *H. sabdariffa* UKMR-2 variety on sperm functioning of streptozotocin-induced diabetic rats. Male Sprague-Dawley rats were allotted into four groups, namely control group (C), *H. sabdariffa* extract (HSE) group, diabetes group (D) and diabetes plus HSE group (D+HSE). HSE (100 mg/kg/body weight) was administered orally for 28 consecutive days. After 28-days of supplementation, the rats were sacrificed to obtain epididymal sperm. Administration of HSE significantly lowered the level of fasting blood glucose and increased plasma insulin level in D+HSE group as compared to D group ( $p < 0.05$ ). Sperm quality in the D+HSE group was improved with significantly higher sperm concentrations ( $p < 0.05$ ) and sperm motility ( $p < 0.001$ ) as well as lower percentage of sperm abnormality ( $p < 0.05$ ) as compared to the diabetic group. Plasma follicle-stimulating hormone (FSH) level was significantly elevated ( $p < 0.05$ ) in D+HSE group than in D group while no significant alteration in plasma testosterone and luteinizing hormone (LH) level were seen between groups. In conclusion, this study suggested that *H. sabdariffa* UKMR-2 variety has a potential protective role against diabetes-induced sperm damage.

**Keywords:** Diabetes, oxidative stress, sperm damage, *Hibiscus sabdariffa* UKMR-2

**INTRODUCTION**

The hallmark feature of diabetes mellitus is constant elevation of blood glucose level which occurs due to destruction of pancreatic  $\beta$ -cell or the loss of cell responsiveness to insulin. Persistent hyperglycaemic condition may cause overproduction of

free radicals by activating polyol and glucose pentose pathway, increasing glucose autooxidation and lipid peroxidation as well as disturbance of the antioxidant defence system. The resultant free radicals bring about intracellular oxidative stress (Baynes, 1991).

Testicular and sperm cells have increased susceptibility to free radical damage due to higher level of polyunsaturated fatty acid (PUFA), low oxygen tension and lack of antioxidant defence mechanism (Aitken and Roman, 2009). This may explain the possible aetiologies for increasing cases of infertility among males (Saalu, 2010). Infertile male diabetics tend to suffer from decreased sex libido, diminishing sperm count, endocrine disturbance, impaired penile erection and ejaculation (Mallik et al., 2007; Zhao et al., 2010). In addition, many experimental studies have reported episodes of testicular dysfunction and sperm abnormalities in diabetic animals (Amaral et al., 2009).

Oxidative stress plays an important role in pathogenesis of diabetic complications. Thus, natural products with antioxidant properties can be useful as alternative or complementary treatment for diabetes and its complications. Among them, *Hibiscus sabdariffa* Linn. (HS) is a valuable source of traditional medicine (Ubani et al., 2010). It is native to tropical Africa and can also be found in India and Southeast Asia including Thailand and Malaysia (Mahadevan and Kamboj, 2009). To date, there are three mutated variants of *H. sabdariffa* which are UKMR-1, UKMR-2 and UKMR-3 with different composition of active compounds (Osman et al., 2011). Aqueous extract of HS is enriched in high antioxidant constituents, mainly flavonoids and vitamin C (Hirunpanich et al., 2006; Tsai et al., 2002).

In particular, anthocyanin from HS was able to protect *tert*-butyl hydroperoxide hepatic damage due to its antioxidant potential (Wang et al., 2000). Whereas, its phenolic compounds were able to inhibit LDL oxidation induced by copper, nitric oxide and oxidative stress from strenuous exercise (Hsieh et al., 2006; Lee et al., 2002). *In vivo* studies in diabetics suggested that HS extract can suppress glucose elevation and alleviate oxidative damage in kidney and liver (Farombi and Ige, 2007). To the point of interest, HS was claimed as aphrodisiac in folk medicine (Perry, 1980). However,

scarce evidence is available on toxicity of HS in experimental models (Abubakar et al., 2010). Also its beneficial effects on the reproductive system in hyperglycaemic subjects have not yet been reported.

Therefore, the aim of this study is to investigate the effects of *H. sabdariffa* aqueous extract (HSE) on sperm function in diabetic animals by examining the level of androgen hormones and sperm quality.

## MATERIALS AND METHODS

### Chemicals

All reagents were purchased from Sigma-Aldrich Chemicals, Saint Louis, MO, USA.

### Plant material and extracts

*H. sabdariffa* UKMR-2 variety was harvested from Plant House, Faculty of Science & Technology (FST), Universiti Kebangsaan Malaysia (UKM), Bangi, Selangor, Malaysia. The fresh calyxes of HS were blended in distilled water (1:2). The juice was boiled and allowed to cool at room temperature. The juice was then filtered using three layers of cheese cloth. Maltodextrin was added to the filtrate (1:9). The filtrate was freeze-dried and stored in dark container at 4 °C.

### Animals

A total of 24 male Sprague-Dawley (SD) rats aged 8 weeks (230 g-240 g) were obtained from Animal Resource Unit, Faculty of Medicine, UKM. The rats were placed in polypropylene cages (2 animals per cage) and kept under ambient condition. Rats were fed with commercial pellet diet and allowed free excess to water *ad libitum* throughout the experiment. Animals were acclimatized to the experimental condition for 1 week prior to experiment. All procedure with animals strictly adhered to the guidelines of UKM Animal Ethics Committee (UKMAEC).

### Experimental design and dosing schedule

Male SD rats were randomized into four groups, each comprising of 6 animals. The

experimental groups include control group (C), *H. sabdariffa* extract group (HSE), diabetes group (DM) and diabetes plus HSE group (DM+HSE). Diabetes was induced with a single intravenous injection of freshly prepared streptozotocin (STZ) (45 mg/kg) in overnight fast rats (Budin et al., 2011). After 72 hours, fasting blood glucose level was measured using glucometer (ACCU-CHEK® Performa, Roche Diagnostics GmbH, Germany) and rats with blood glucose levels above 360 mg/dl were included for this study. Control group received sterile distilled water and HSE group received HSE (100 mg/kg b.w.). HSE was administered orally for 28 consecutive days. Blood glucose level was monitored weekly throughout the study. Fasting blood glucose was determined using glucose oxidase method upon completion of this study (BioSystems SA, Spain).

#### **Sample collection**

At the end of 4<sup>th</sup> week, blood specimen was collected into EDTA tubes via cardiac puncture under light ether anaesthesia. Testicles, epididymis, seminal vesicles and prostate were excised from sacrificed rats and weighed. Caudal epididymis was minced in 2 ml pre-warmed Hank's buffer salt solution (HBSS) at 37 °C and centrifuged at 1,000 rpm, 4 °C for 3 minutes to obtain epididymal sperm. The supernatant was immediately processed for sperm assessment. Blood sample was centrifuged at 3,000 rpm, 4 °C for 5 minutes after which aliquots of plasma were collected and kept at -40 °C for further analysis.

#### **Sperm count, sperm motility and sperm morphology assay**

A total of 10 µl supernatant with epididymal sperm was used for sperm count and motility using Makler counting chamber (Sefi-Medical Instruments Ltd., USA) under 10× magnifications. A total of 200 sperms were observed for motility and categorized as motile or non-motile. Sperm morphology whereas was studied by preparing freshly sperm smear using 10 µl of

sperm suspension. The dried smear was stained with Diff-Quik staining kit and mounted with DPX. Similarly, 200 sperms were observed under 40× magnifications and scored for morphology abnormalities as described by Kushwaha and Jena (2012).

#### **Determination of plasma hormone level**

Plasma insulin level was analyzed using enzyme-linked immunoassay (ELISA) (Mercodia AB, Sweden). Likewise, androgen hormones were assayed by a commercial ELISA kit. Testosterone ELISA kit was purchased from Abnova (Taipei, Taiwan) while follicle stimulating hormone (FSH) and luteinizing hormone (LH) ELISA kit were obtained from Uscn Life Sciences Inc. (Wuhan, China). All procedures adhered to the standard protocols supplied.

#### **Statistical analysis**

All results were expressed as mean ± standard error of mean (SEM). Statistical analysis was performed using SPSS Statistical Package (version 18). One-way analysis of variance (ANOVA) was used for multiple comparisons, followed by Post-Hoc Tukey test to compare statistical difference between groups. A p value <0.05 was considered significant difference.

## **RESULTS**

#### **Effect of HSE on body weight and organ weight**

Table 1 shows mean body weights and reproductive organ weights of rats by week throughout treatment period. Body weights were decreased significantly in both diabetic groups compared to control in every week of treatment (p<0.05). HSE administration to healthy animals resulted in a significantly decreasing body weight compared to control group on day-14 and at the end of treatment (p<0.05). On the other hand, administration of HSE to healthy animals did not cause a significant effect on absolute and relative weight of reproductive organs in comparison to control group (p<0.05). Contrarily, diabetes resulted in a significant reduction in absolute weights of

reproductive organs in comparison with control group ( $p < 0.05$ ). In fact, diabetes significantly reduced relative weight of testis compared to normal ( $p < 0.05$ ). However, relative weight of diabetic group showed no significant difference as compared to control. Administration of HSE in diabetic rats resulted in absolute reproductive organ weights to increase significantly compared to diabetic group except for seminal vesicle ( $p < 0.05$ ). A significant reduction of absolute seminal vesicle weight in D+HSE group was observed compared to control ( $p < 0.05$ ). In addition, D+HSE showed significantly increased relative weight in cauda epididymis and epididymis compared to diabetic group ( $p < 0.05$ ). Prostate absolute

and relative weights were not affected by HSE treatment.

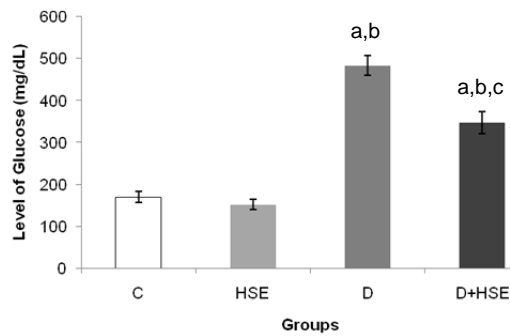
#### **Effect of HSE on glucose and insulin level**

Figure 1 shows that the blood glucose level was significantly higher in both diabetic groups than in the control group ( $p < 0.05$ ). Nevertheless, HSE administration led to a significant reduction of blood glucose level compared to the diabetic group ( $p < 0.05$ ). This was followed by a significant increase of insulin level in diabetic administered with HSE in comparison with diabetic group as shown in Figure 2 ( $p < 0.05$ ). Whereas, diabetes caused a significant decline of insulin level compared to the control ( $p < 0.05$ ).

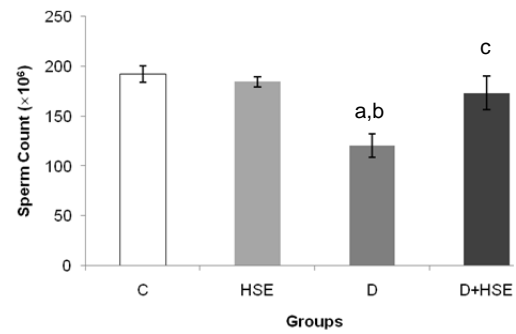
**Table 1:** The difference of body weights and organ weights between the groups after 28 days of treatment

Groups (parameters)	Control	HSE	Diabetes	Diabetes + HSE
<b>Body weights (g)</b>				
Day-0	231.57 ± 2.10	228.71 ± 1.49	230.14 ± 4.37	230.57 ± 2.76
Day-7	278.42 ± 5.38	267.00 ± 2.63	229.71 ± 4.22 <sup>a,b</sup>	228.71 ± 2.97 <sup>a,b</sup>
Day-14	300.00 ± 5.82	277.86 ± 4.55 <sup>a</sup>	227.00 ± 5.42 <sup>a,b</sup>	228.43 ± 4.85 <sup>a,b</sup>
Day-21	315.57 ± 8.18	297.43 ± 5.55	214.14 ± 2.99 <sup>a,b</sup>	219.29 ± 4.79 <sup>a,b</sup>
Day-28	330.29 ± 5.18	303.57 ± 7.01 <sup>a</sup>	196.43 ± 4.25 <sup>a,b</sup>	214.29 ± 2.52 <sup>a,b</sup>
<b>Absolute weights (g)</b>				
Testis	2.74 ± 0.26	2.85 ± 0.12	2.35 ± 0.05 <sup>a,b</sup>	2.72 ± 0.08 <sup>c</sup>
Cauda epididymis	0.41 ± 0.01	0.42 ± 0.01	0.22 ± 0.01 <sup>a,b</sup>	0.38 ± 0.05 <sup>c</sup>
Epididymis	0.88 ± 0.11	0.90 ± 0.09	0.50 ± 0.10 <sup>a,b</sup>	0.77 ± 0.05 <sup>c</sup>
Prostate	0.31 ± 0.00	0.40 ± 0.11	0.18 ± 0.05 <sup>b</sup>	0.20 ± 0.05 <sup>b</sup>
Seminal vesicles	0.64 ± 0.04	0.82 ± 0.16	0.22 ± 0.02 <sup>a,b</sup>	0.43 ± 0.13 <sup>a,b,c</sup>
<b>Relative weights (g/100 g)</b>				
Testis	0.93 ± 0.16	0.91 ± 0.11	1.23 ± 0.09 <sup>a,b</sup>	1.32 ± 0.12 <sup>a,b</sup>
Cauda epididymis	0.14 ± 0.01	0.14 ± 0.02	0.12 ± 0.01	0.18 ± 0.03 <sup>a,b,c</sup>
Epididymis	0.30 ± 0.06	0.29 ± 0.04	0.26 ± 0.06	0.37 ± 0.04 <sup>b,c</sup>
Prostate	0.10 ± 0.01	0.13 ± 0.03	0.90 ± 0.03	0.10 ± 0.03
Seminal vesicles	0.22 ± 0.02	0.26 ± 0.06	0.12 ± 0.02 <sup>b</sup>	0.20 ± 0.07

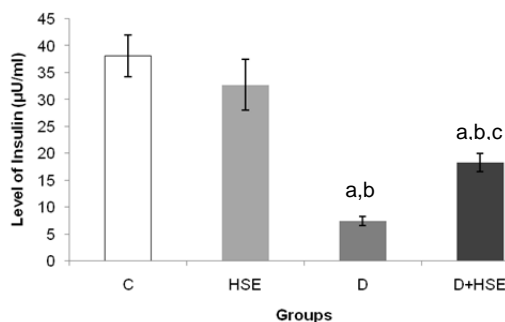
Values were expressed as mean ± SD where mean significant at  $p < 0.05$ . <sup>a</sup>compared with control group; <sup>b</sup>compared with HSE group; <sup>c</sup>compared with D group



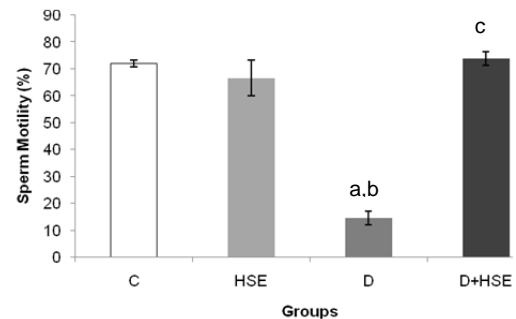
**Figure 1:** Level of glucose between the groups. Values were expressed as mean  $\pm$  SEM where mean significant at  $p < 0.05$ . <sup>a</sup>compared with control group; <sup>b</sup>compared with HSE group; <sup>c</sup>compared with D group.



**Figure 3:** Comparison of sperm count between the groups. Values were expressed as mean  $\pm$  SEM where mean significant at  $p < 0.05$ . <sup>a</sup>compared with control group; <sup>b</sup>compared with HSE group; <sup>c</sup>compared with D group.



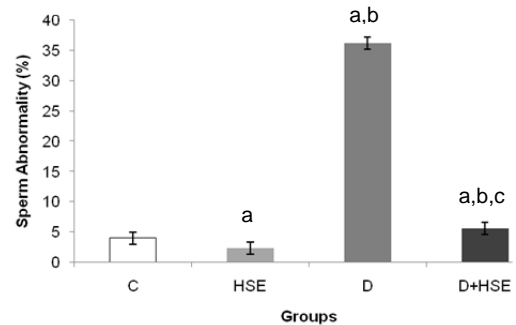
**Figure 2:** Level of insulin between the groups. Values were expressed as mean  $\pm$  SEM where mean significant at  $p < 0.05$ . <sup>a</sup>compared with control group; <sup>b</sup>compared with HSE group; <sup>c</sup>compared with D group.



**Figure 4:** Percentage of sperm motility in different groups. Values were expressed as mean  $\pm$  SEM where mean significant at  $p < 0.001$ . <sup>a</sup>compared with control group; <sup>b</sup>compared with HSE group; <sup>c</sup>compared with D group.

### Effect of HSE on sperm quality assessment

Figures 3 and 4 respectively demonstrate that administration of HSE in diabetic group significantly increased sperm count ( $p < 0.05$ ) and motility ( $p < 0.001$ ) compared to diabetic group. The frequency of sperm abnormalities in D+HSE group was significantly reduced in comparison with diabetic group as shown in Figure 5 ( $p < 0.05$ ). Additionally, a significant reduction of sperm abnormalities was observed in HSE group compared to control group ( $p < 0.05$ ).

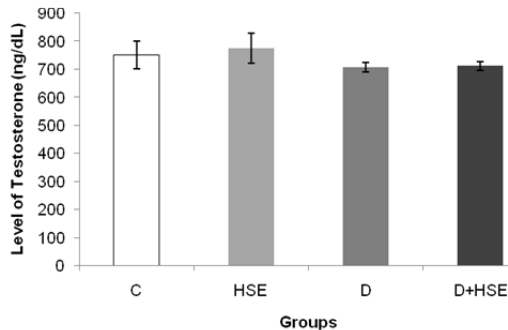


**Figure 5:** Percentage of sperm abnormality in different groups. Values were expressed as mean  $\pm$  SEM.

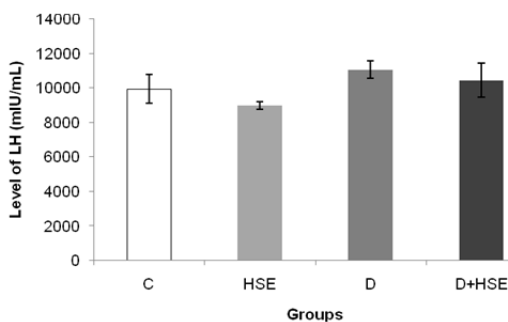
### Effect of HSE on testosterone, FSH and LH level

Figures 6 and 7 show that there is no significant difference among the groups in plasma testosterone and LH level. In contrast, level of plasma FSH in diabetic animals was significantly higher than control group as observed in Figure 8 ( $p < 0.05$ ).

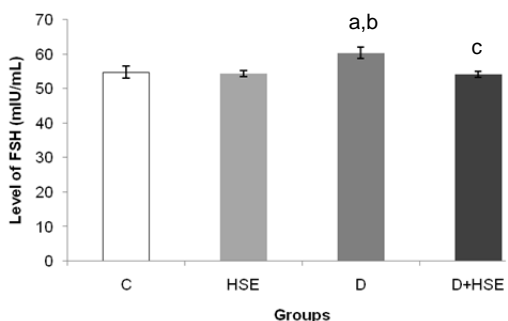
Administration of HSE was significantly reduced plasma FSH level in hyperglycaemic condition compared to diabetes group ( $p < 0.05$ ).



**Figure 6:** Level of testosterone between the groups. Values were expressed as mean  $\pm$  SEM.



**Figure 7:** Level of LH between the groups. Values were expressed as mean  $\pm$  SEM.



**Figure 8:** Level of FSH between the groups. Values were expressed as mean  $\pm$  SEM where mean significant at  $p < 0.05$ . <sup>a</sup>compared with control group; <sup>b</sup>compared with HSE group; <sup>c</sup>compared with D group.

## DISCUSSION

Diabetes mellitus (DM) is a metabolic endocrine disorder which affects multiple organs through its complications. With global prevalence, DM will become a major non-communicable disease in about 20 years (WHO, 2011). Diabetes has brought about reproductive impairments in both males and females (Ramalho-Santos et al., 2008). In the current study, the occurrence of male reproductive disorders in diabetic condition was proven using animal models. The study also investigated UKMR-2, a new mutated variety of *H. sabdariffa* as potential therapeutic drug for treating sperm and testicular dysfunction in hyperglycaemic state using type 1 diabetes model. UKMR-2 was chosen as it has the highest anthocyanin content among the three variants and has high value for commercialization.

In present work, intravenous administration of streptozotocin concurrently elevated fasting blood glucose level with a reduction in plasma insulin level as reported earlier (Shrilatha and Muralidhara, 2007). Streptozotocin is a specific  $\beta$ -cell destructor which alters glucose homeostasis. Absence of insulin hormone disturbs glucose transportation across the cell membrane, thereby decreasing body weight of diabetic animals. Interestingly, administration of HSE significantly recovered fasting blood glucose and plasma insulin level in diabetic rats. This is in accordance with the findings of Wisetmuen (2008). HSE most probably has the ability to regenerate pancreatic  $\beta$ -cells. However, recovery of insulin level in diabetic animals following HSE treatment may not necessarily increase body weight as reported before (Ballester et al., 2004).

The excised reproductive organs from diabetic rats were also of lower weight. Since testosterone level was unaffected, the physical alterations possibly resulted from metabolic disturbances due to insulin deficiency and inadequate food intake. In fact, insulin therapy was shown to recover body weight and weight of the reproductive organs in previous studies (Jackson and Hut-

son, 1984). Reduction in testicular weight and size could also be due to testicular atrophy. During atrophy, the size of testicular lumen reduces with seminiferous tubular diameter. Thinning of epithelial lining thus increases intratubular spaces, resulting in reduced organ weight (Seethalakshmi et al., 1987). Anyhow, prostate, being an androgenic sensitive organ, was unaffected in this study despite remarkable increment in FSH level. Decreased reproductive organ weight could have been the culprit for reduced body weight in diabetic rats (Bal et al., 2011). HSE was capable of maintaining the reproductive organ weights, by which it was also able to prevent substantial weight loss in diabetic rats.

In addition, streptozotocin-induced diabetic rats also had poor sperm quality. Epididymal sperm count was low with remarkable abnormalities in sperm motility and morphology. These were consistent with previous finding on male reproductive system in diabetic condition which indicates infertility (Bal et al., 2011). Oxidative stress plays a key role in pathogenesis of DM induced male reproductive defects (La Vignera et al., 2012). In diabetics, cellular respiration is accelerated due to hyperpolarization of mitochondrial membrane potential (Ramalho-Santos et al., 2008). More mitochondrial reactive oxygen species are generated. Resulting mitochondrial dysfunction impairs spermatogenesis and decreases sperm motility (Shamsi et al., 2008).

Apart from that, sperm head membrane is also highly sensitive to oxidative stress due to rich polyunsaturated fatty acid content. Constant exposure to free radicals in diabetes renders sperm cellular organelles to damage via lipid peroxidation and protein oxidation. The oxidative damage initiates sperm plasma membrane destruction, apoptosis and germ cell death (Gobbo et al., 2012). Current situation is worsened by lack of transcription machinery and highly condensed DNA in sperm, where free radicals induce genotoxicity by initiating sperm DNA denaturation and fragmentation with

limited DNA repair. Damage of genetic material in spermatogonia and spermatocytes has been related to the increased sperm abnormalities. These alterations bring about possibilities of genetic disorders if passed down to offspring (Silva and Gadella, 2006).

Androgenic hormones are another factor that can regulate spermatogenesis. In present work, plasma testosterone and LH level were unaffected in diabetic rats while FSH level was remarkably high. It was noted that diabetes did not alter the functions of pituitary glands and Leydig cells but affected Sertoli cell functions owing to reduction in FSH receptors. FSH plays a predominant role in proliferation and differentiation of Sertoli cells. Impaired regulation of FSH thus affects the metabolic capacity of Sertoli cells leading to a marked reduction in Sertoli cell numbers and decrease in germ cells. Since Sertoli cells are involved in developing sperm cells and regulating internal environment of seminiferous tubules through blood-testis barrier, reduction in their number further decreases spermatogenic output (Niewoehner, 2004). Another possible reason for low sperm count is low testicular glucose utilization in streptozotocin-treated rats. Reduced glucose uptake considerably decreases cellular glycogen contents which serve as energy source for sperm development. Thereby, glycogen depletion inhibits generation of lactate by Sertoli cell (Hamden et al., 2010).

The present findings showed that HSE administration resulted in marked restoration in epididymal sperm count, sperm motility and sperm abnormalities towards control levels. The protective effects of this extract may be due to its free radical scavenging properties. Anthocyanin, the most abundant constituent in HSE, enhanced activities of antioxidant enzymes and prevented lipoperoxidative as well as hemolytic damage induced by 2,4-diphenylhydrazine in red blood cells (Ologundudu et al., 2009). HSE was also able to inhibit leakage of lactate dehydrogenase, formation of malondialdehyde and unscheduled synthe-

sis of DNA repair, by which it prevented cytotoxicity in *tert*-butyl hydroperoxide induced hepatic damage. Furthermore, recent studies confirmed antimutagenic activity of HSE modulated by its phenolic acid constituents (Olvera-García et al., 2008). Its antioxidant actions could also restore the impaired vascular responses (Ajay et al., 2007).

Other studies also proved that antioxidant therapy increased sperm quality. Kushwaha and Jena (2012) revealed that antihypertensive drug can induce the amelioration of sperm DNA damage, reduces the oxidative stress and down-regulates the expression of NFκB and COX-2 expression in streptozotocin-induced diabetic rat. In other way, quercetin can improve epididymal sperm quality and decrease serum ROS and ox-LDL in diabetic condition. Vitamin C treatment also demonstrated that derangement of epididymal tissue components (stroma, epithelium and lumen) can be prevented and attenuated oxidative damage noted in diabetic condition (Glaura et al., 2011). Further, Mohasseb et al. (2011) reported that intake of a combination of vitamin E, C and alpha lipoic acid can protect from testicular damage and germ cell apoptosis resulting in increased spermatogenesis in diabetic male. Fenugreek (*Trigonella foenum-graecum*), otherwise, prevents sperm alteration by improved steroidogenesis and carbohydrate metabolism in diabetic state (Hamden et al., 2010).

It is noteworthy herein to mention that no general signs of toxicity were observed from body and reproductive organ weight restoration in HSE consumption group. In addition, HSE treatment of diabetic rats caused only a slight increase in body weight during the course of the experiment. Moreover, no animal exhibited noticeable adverse effects from the administration of extract. This finding is quite surprising because previous research found that *H. sabdariffa* has deleterious effects to male reproductive system and possesses spermatotoxic properties (Orisakwe et al., 2004; Mahmoud, 2012). However, the present

work showed that UKMR-2 has not only prevented reproductive defects in diabetics but also improved the quality of sperms. Therefore, we suggest that the difference of phytoconstituents in UKMR-2 from previous variety possesses synergistic effect which gives protection towards male reproductive problems.

The results of the present study revealed that, HSE ameliorated sperm defects in streptozotocin-induced diabetic rats but the protection mechanism of HSE remains unclear. However, this preliminary study opens a new platform for studying HSE as a potential therapeutic agent in treating diabetes and its reproductive complications. For this reason, subsequent study is currently conducted to reveal molecular actions of HSE in reproductive system.

**Acknowledgements:** The authors wish to acknowledge the financial assistance received from prime grant of university (UKM-AP-BPB-13-2009). Special thanks are also conveyed to En. Zainal Mohamad and Pn. Hamidah Mari from FST, UKM for their help in this present study.

## REFERENCES

- Abubakar M, Lawal A, Suleiman B, Abdullahi K. Hepatorenal toxicity studies of sub-chronic administration of calyx aqueous extracts of *Hibiscus sabdariffa* in albino rats. *Bayero J Pure Appl Sci* 2010; 3(1):16-19.
- Aitken RJ, Roman SD. Antioxidant systems and oxidative stress in the testes. *Adv Exp Med Biol* 2009;636:154-71.
- Ajay M, Chai HJ, Mustafa AM, Gilani AH, Mustafa MR. Mechanisms of the antihypertensive effect of *Hibiscus sabdariffa* L. calyces. *J Ethnopharmacol* 2007;109: 388-93.



- Amaral S, Mota PC, Lacerda B, Alves M, Pereira ML, Oliveira PJS et al. Testicular mitochondrial alterations in untreated streptozotocin-induced diabetic rats. *Mitochondrion* 2009;9:41-50.
- Bal R, Türk G, Tuzcu M, Yilmaz O, Ozercan I, Kuloglu T et al. Protective effects of nanostructures of hydrated C<sub>60</sub> fullerene on reproductive function in streptozotocin-diabetic male rats. *Toxicology* 2011;282:69-81.
- Ballester J, Muñoz MC, Domínguez J, Rigau T, Guinovart JJ, Rodríguez-Gil JE. Insulin-dependent diabetes affects testicular function by FSH-and LH-linked mechanisms. *J Androl* 2004;25:706-19.
- Baynes JW. Role of oxidative stress in development of complications in diabetes. *Diabetes* 1991;40:405-12.
- Budin SB, Khairunnisa MY, Muhd Hanis MI, Hamid ZA, Mohamed J. Tocotrienol-rich fraction of palm oil reduced pancreatic damage and oxidative stress in streptozotocin-induced diabetic rats. *Aust J Basic Appl Sci* 2011;5:2367-74.
- Farombi EO, Ige OO. Hypolipidemic and antioxidant effects of ethanolic extract from dried calyx of *Hibiscus sabdariffa* in alloxan-induced diabetic rats. *Fund Clin Pharmacol* 2007;21:601-9.
- Glauro F, Carla F, Kleber C, Débora D, Janete AF, Wilma K. Vitamin C partially attenuates male reproductive deficits in hyperglycemic rats. *Reprod Biol Endocrinol* 2011;9:100.
- Gobbo MG, Ribeiro DL, Taboga SR, de Almeida EA, Góes RM. Oxidative stress markers and apoptosis in the prostate of diabetic rats and the influence of vitamin C treatment. *J Cell Biochem* 2012;113:2223-33.
- Hamden K, Jaouadi B, Carreau S, Aouidet A, El-Fazaa S, Gharbi N et al. Potential protective effect on key steroidogenesis and metabolic enzymes and sperm abnormalities by fenugreek steroids in testis and epididymis of surviving diabetic rats. *Arch Physiol Biochem* 2010;116:146-55.
- Hirunpanich V, Utaipat A, Morales NP, Bunyaphatsara N, Sato H, Herunsale A et al. Hypocholesterolemic and antioxidant effects of aqueous extracts from the dried calyx of *Hibiscus sabdariffa* L. in hypercholesterolemic rats. *J Ethnopharmacol* 2006;103:252-60.
- Hsieh CCC, Lee MY, Chen CC, Hsu JJ, Lu HK, Wang CJ. Hibiscus protocatechuic acid supplementation reduces oxidative stress induced by exhaustive exercise in rat muscle. *J Exerc Sci Fit* 2006;4:58-63.
- Jackson FL, Hutson JC. Altered responses to androgen in diabetic male rats. *Diabetes* 1984;33:819-24.
- Kushwaha S, Jena GB. Enalapril reduces germ cell toxicity in streptozotocin-induced diabetic rat: investigation on possible mechanisms. *N S Arch Pharmacol* 2012;385:111-24.
- La Vignera S, Condorelli R, Vicari E, D'Agata R, Calogero AE. Diabetes mellitus and sperm parameters. *J Androl* 2012;33:145-53.
- Lee MJ, Chou FP, Tseng TH, Hsieh MH, Lin MC, Wang CJ. Hibiscus protocatechuic acid or esculetin can inhibit oxidative LDL induced by either copper ion or nitric oxide donor. *J Agric Food Chem* 2002;50:2130-6.
- Mahadevan N, Kamboj P. *Hibiscus sabdariffa* Linn. – an overview. *Nat Prod Radiance* 2009;8:77-83.
- Mahmoud YI. Effect of extract of Hibiscus on the ultrastructure of the testis in adult mice. *Acta Histochem* 2012;114:342-8.

- Mallick C, Mandal S, Barik B, Bhattacharya A, Ghosh D. Protection of testicular dysfunctions by MTEC, a formulated herbal drug, in streptozotocin induced diabetic rat. *Biol Pharm Bull* 2007;30:84-90.
- Mohasseb M, Ebied S, Yehia MAH, Hussein N. Testicular oxidative damage and role of combined antioxidant supplementation in experimental diabetic rats. *J Physiol Biochem* 2011;67:185-94.
- Niewoehner CB. *Endocrine pathophysiology*. Raleigh, NC: Hayes Barton Press, 2004.
- Ologundudu A, Ologundudu AO, Ololade IA, Obi FO. Effect of *Hibiscus sabdariffa* anthocyanins on 2, 4-dinitrophenylhydrazine-induced hematotoxicity in rabbits. *Afr J Biochem Res* 2009;3:140-4.
- Olvera-García V, Castaño-Tostado E, Rezendiz-Lopez R, Reynoso-Camacho R, González de Mejía E, Elizondo G et al. *Hibiscus sabdariffa* L. extracts inhibit the mutagenicity in microsuspension assay and the proliferation of HeLa cells. *J Food Sci* 2008;73:T75-81.
- Orisakwe OE, Husaini DC, Afonne OJ. Testicular effects of sub-chronic administration of *Hibiscus sabdariffa* calyx aqueous extract in rats. *Reprod Toxicol* 2004;18:295-8.
- Osman M, Golam F, Saberi S, Majid NA, Nagoor NH, Zulqarnain M. Morpho-agronomic analysis of three roselle (*Hibiscus sabdariffa* L.) mutants in tropical Malaysia. *Aust J Crop Sci* 2011;5:1150-6.
- Perry LM. *Medicinal plants of East and Southeast Asia: attributed properties and uses*. Cambridge, MA: MIT Press, 1980.
- Ramalho-Santos J, Amaral S, Oliveira PJ. Diabetes and the impairment of reproductive function: possible role of mitochondria and reactive oxygen species. *Curr Diabetes Rev* 2008;4:46-54.
- Saalu LC. The incriminating role of reactive oxygen species in idiopathic male infertility: an evidence based evaluation. *Pak J Biol Sci* 210;13:413-22.
- Seethalakshmi L, Menon M, Diamond D. The effect of streptozotocin-induced diabetic on the neuroendocrine-male reproductive tract axis of the adult rat. *J Urol* 1987;138:190-4.
- Shamsi MB, Kumar R, Bhatt A, Bamezai R, Gupta NP, Das T et al. Mitochondrial DNA mutations in etiopathogenesis of male infertility. *Indian J Urol* 2008;24:150-4.
- Shrilatha B, Muralidhara. Early oxidative stress in testis and epididymal sperm in streptozotocin-induced diabetic mice: Its progression and genotoxic consequences. *Reprod Toxicol* 2007;23:578-87.
- Silva PFN, Gadella BM. Detection of damage in mammalian sperm cells. *Theriogenology* 2006;65:958-78.
- Tsai PJ, McIntosh J, Pearce P, Camden B, Jordan BR. Anthocyanin and antioxidant capacity in Roselle (*Hibiscus sabdariffa* L.) extract. *Food Res Int* 2002;35:351-6.
- Ubani CS, Joshua PE, Oraeki AN. Influence of aqueous extract of *Hibiscus sabdariffa* calyces on lipid profile of phenobarbitone induces wistar albino rats. *J Pharm Res* 2010;3:319-24.
- Wang CJ, Wang JM, Lin WL, Chu CY, Chou FP, Tseng TH. Protective effect of *Hibiscus* anthocyanins against tert-butyl hydroperoxide-induced hepatic toxicity in rats. *Food Chem Toxicol* 2000;38:411-6.

Wisetmuen E, Pannangpetch P, Kongyinyoes B, Kukongviriyapan U, Itharat A. Antidiabetic effect of ethanolic extract of Roselle (*Hibiscus sabdariffa*) in chronic streptozotocin-induced diabetic rats. Thai J Pharmacol 2008;29:69-73.

Zhao X, Zhong J, Mo Y, Chen X, Chen Y, Yang D. Association of biochemical hyperandrogenism with type 2 diabetes and obesity in Chinese women with polycystic ovary syndrome. Int J Gynecol Obstet 2010;108:148-51.

WHO, World Health Organization. Global status report on noncommunicable diseases 2010. Ed Ala Alawan. Geneva: WHO Press, 2011.