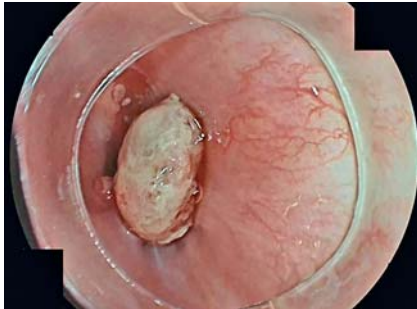
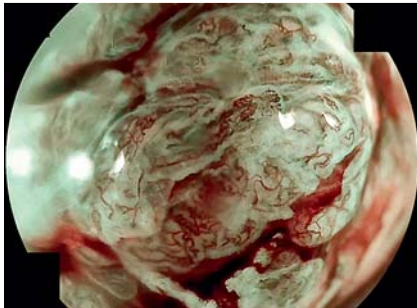


Underwater endoscopic mucosal resection for a protruding lesion in the esophagus

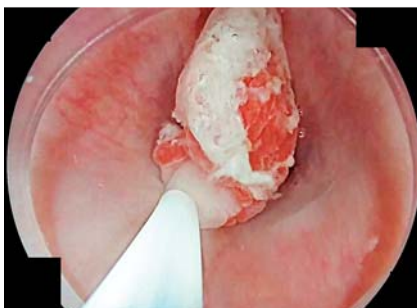OPEN
ACCESS



► **Fig. 1** Sessile lesion in the esophagus.

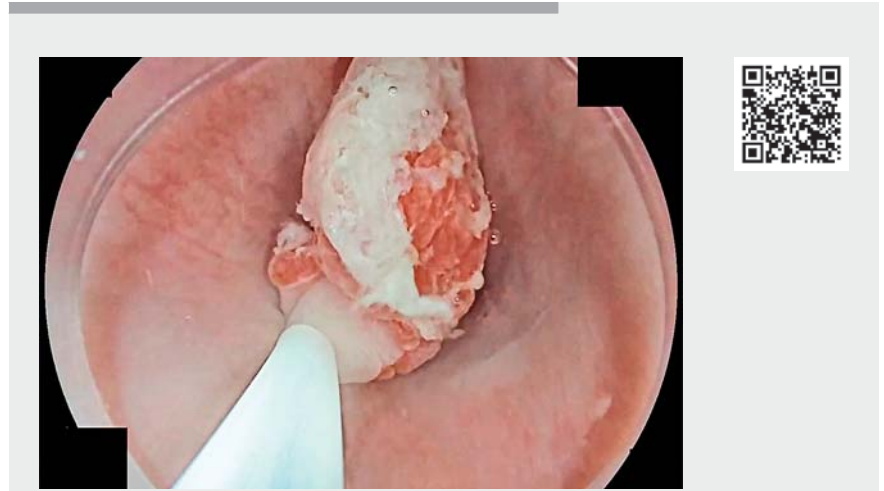


► **Fig. 2** Suspicious vascular and mucosal pattern.



► **Fig. 3** Closing the snare on the lesion.

A 70-year-old man with a history of ischemic cardiopathy, taking clopidogrel as his usual treatment, was referred because of cholangitis. Computed tomography and magnetic resonance imaging scans revealed a dilated bile duct without



► **Video 1** Underwater endoscopic mucosal resection for a sessile esophageal lesion.

any obvious obstruction. Gastroscopy and endoscopic ultrasound were performed in search of an ampulloma, and unexpectedly identified a sessile tumor 2 cm above the gastroesophageal junction (► **Fig. 1**). Gastroscopy performed with a high definition endoscope and magnification (EG-760Z; Fujifilm, Tokyo, Japan) confirmed a 0-Ip esophageal lesion with a suspicious irregular mucosal and vascular pattern (► **Fig. 2**).

In the absence of endoscopic features suggesting deep submucosal invasion, endoscopic resection was chosen. Owing to the sessile shape of the lesion, an underwater endoscopic mucosal resection (UEMR) was performed. We used a water pump to fill the entire esophageal lumen with saline (► **Video 1**). A 15-mm diathermic snare was deployed to encircle the tumor, and was then closed on the polyp (► **Fig. 3**). Safe margins were confirmed endoscopically before resecting the lesion using an Endocut current. After the resection, minor bleeding was successfully treated with the tip of the snare

in soft coagulation mode, and the wound was closed with standard clips.

The resected specimen was 1.5 × 0.8 × 0.6 cm in size. Histological examination revealed a well-differentiated intramucosal adenocarcinoma, with margins free of dysplasia and cancer.


Previous studies have reported colorectal [1-3] and gastric [4] UEMR as an alternative to classic EMR. To the best of our knowledge, this is the first UEMR reported for an esophageal lesion. UEMR can be used for small sessile or pedunculated lesions in the esophagus, and is safe, fast, and efficient.

Endoscopy_UCTN_Code_TTT_1AO_2AC

Competing interests

The authors declare that they have no conflict of interest.

The authors

Paul Doumbe-Mandengue¹ , **Sophie Geyl**¹,
Anne Guyot², **Mathieu Pioche**³, **Rebecca
Rodrigues**¹, **Jérémie Albouys**¹, **Jérémie
Jacques**¹

- 1 Department of Gastroenterology and Hepatology, University Hospital Dupuytren, Limoges, France
- 2 Department of Pathology, University Hospital Dupuytren, Limoges, France
- 3 Department of Gastroenterology and Hepatology, University Hospital Edouard Herriot, Lyon, France

Corresponding author

Paul Doumbe-Mandengue, MD

Gastroenterology, CHU Dupuytren, 2 avenue
Martin Luther King, Limoges 87000, France
paul.mandengue@hotmail.fr

References

- [1] Kamal F, Khan MA, Lee-Smith W et al. Underwater vs conventional endoscopic mucosal resection in the management of colorectal polyps: a systematic review and meta-analysis. *Endosc Int Open* 2020; 8: E1264–E1272
- [2] Li P, Ma B, Gong S et al. Underwater endoscopic mucosal resection for colorectal lesions: a meta-analysis. *Surg Endosc* 2021; 35: 3003–3013
- [3] Binmoeller KF, Weilert F, Shah J et al. “Underwater” EMR without submucosal injection for large sessile colorectal polyps (with video). *Gastrointest Endosc* 2012; 75: 1086–1091
- [4] Maida M, Sferrazza S, Murino A et al. Effectiveness and safety of underwater techniques in gastrointestinal endoscopy: a comprehensive review of the literature. *Surg Endosc* 2021; 35: 37–51

Bibliography

Endoscopy 2022; 54: E869–E870

DOI 10.1055/a-1847-7235

ISSN 0013-726X

published online 24.6.2022

© 2022. The Author(s).

This is an open access article published by Thieme under the terms of the Creative Commons Attribution-NonDerivative-NonCommercial License, permitting copying and reproduction so long as the original work is given appropriate credit. Contents may not be used for commercial purposes, or adapted, remixed, transformed or built upon. (<https://creativecommons.org/licenses/by-nc-nd/4.0/>)

Georg Thieme Verlag KG, Rüdigerstraße 14,
70469 Stuttgart, Germany



ENDOSCOPY E-VIDEOS

<https://eref.thieme.de/e-videos>



Endoscopy E-Videos is an open access online section, reporting on interesting cases

and new techniques in gastroenterological endoscopy. All papers include a high quality video and all contributions are freely accessible online. Processing charges apply (currently EUR 375), discounts and waivers acc. to HINARI are available.

This section has its own submission website at

<https://mc.manuscriptcentral.com/e-videos>