




Genotyping of cerebrospinal fluid in lung cancer patients with leptomeningeal metastasis

Naifu Nie¹  | Haodong Zhou¹ | Kejun Zhang² | Lan liu¹ | Nuo Luo¹ | Renyuan Wang¹ | Xin Li¹ | Mengxiao Zhu¹ | Chen Hu¹ | Yubo Wang¹ | Zhulin Liu¹ | Li Li¹  | Yong He¹ 

¹Department of Respiratory Disease, Daping Hospital, Third Military Medical University (Army Medical University), Chongqing, China

²Department of Outpatients, Daping Hospital, Third Military Medical University (Army Medical University), Chongqing, China

Correspondence

Yong He, Department of Respiratory Disease, Daping Hospital, Third Military Medical University (Army Medical University), Chongqing 400042, China.

Email: heyong@tmmu.edu.cn

Li Li, Department of Respiratory Disease, Daping Hospital, Third Military Medical University (Army Medical University), Chongqing 400042, China.

Email: dpyyxlili@tmmu.edu.cn

Funding information

This work was supported by a National Natural Science Foundation of China (81972189, 82172623), and by a Science Foundation for Outstanding Young People of the Army Medical University (2019CXLCA003, 2019CXLCB011).

Abstract

Background: The prognosis of non-small-cell lung cancer (NSCLC) with leptomeningeal metastasis (LM) is poor. Detection of cell-free DNA (cfDNA) by next generation sequencing (NGS) in cerebrospinal fluid (CSF) may facilitate diagnosis of LM and identification of drug resistance mechanisms, yet its clinical use needs to be further verified.

Methods: We performed a retrospective cohort study to assess the genetic profiles of paired CSF and plasma samples in lung cancer patients with LM. Of 17 patients screened, a total of 14 patients with LM and paired NGS tests were enrolled.

Results: All patients harbor driver gene mutations, including 12 epidermal growth factor receptor (EGFR) activating mutations, 1 anaplastic lymphoma kinase (ALK) rearrangement, and 1 ROS-1 fusion. Genetic mutations were detected in CSF cfDNA from 92.9% patients (13/14), which was significantly higher than that from the plasma (9/14, 64.2%). The mutations were highly divergent between CSF and plasma cfDNA, with a concordance rate of 24.38% and 10 mutations shared by the two media. CSF cfDNA could also benefit the analysis of resistance mechanisms to targeted therapies. In five patients who experienced progression on 1st or 2nd generation EGFR-tyrosine kinase inhibitors (TKIs), RB1 mutation, and amplification of *MET* and *EGFR* were detected in CSF cfDNA only. In eight patients with LM progression on osimertinib resistance, *EGFR* amplification was detected in CSF cfDNA from four patients, whereas no CNVs were detected in the matched plasma samples.

Conclusions: In conclusion, CSF could be superior to plasma in providing a more comprehensive genetic landscape of LM to find out drug resistance mechanisms and guide subsequent treatments.

KEYWORDS

cell-free DNA, cerebrospinal fluid, leptomeningeal metastasis, lung cancer, next generation sequencing

INTRODUCTION

Leptomeningeal metastasis (LM) occurs in 3% to 5% of patients with advanced non-small-cell lung cancer (NSCLC).^{1,2} A significantly higher incidence rate of LM was found in those with targetable mutations with an incidence of about 9%.³ The prognosis of NSCLC patients with LM is poor, but has

Naifu Nie, Haodong Zhou, and Kejun Zhang authors are contributed equally to this work.

This study was approved by the Daping Hospital of Army Medical University (Ethics number 202184) and registered at Chinese Clinical Trial Registry (ChiCTR2100049401).

This is an open access article under the terms of the [Creative Commons Attribution-NonCommercial-NoDerivs](https://creativecommons.org/licenses/by-nc-nd/4.0/) License, which permits use and distribution in any medium, provided the original work is properly cited, the use is non-commercial and no modifications or adaptations are made.

© 2022 The Authors. *Thoracic Cancer* published by China Lung Oncology Group and John Wiley & Sons Australia, Ltd.

improved because of the extensive use of targeted drugs.^{3–5} In NSCLC patients with diver gene mutations and LM, certain tyrosine kinase inhibitors (TKIs), such as osimertinib, alectinib, and lorlatinib, have shown potent central nervous system (CNS) penetration and intracranial tumor control.^{6–8} To identify LM and detect targetable genes would be useful to guide the application of target drugs and improve the prognosis of such patients.

LM can be diagnosed by identifying tumor cells in the cerebrospinal fluid (CSF) or through gadolinium-enhanced magnetic resonance imaging (Gd-MRI).^{9,10} However, the diagnosis is difficult and challenging because of low sensitivity of brain MRI and CSF cytology.^{9–11} A variety of biomarkers have been suggested to assist in achieving an earlier diagnosis of LM, including, CA 125, CA 199, CA724, AFP, NSE, Cyfra 21–1, etc., yet these biomarkers may be nonspecific and show no clear correlation with the type of carcinoma or response to treatment.^{12–16} Another potential diagnostic approach for early diagnosis of LM is the analysis of cell-free DNA (cfDNA) by next generation sequencing (NGS) in CSF. In a study of 28 NSCLC patients with LM, adenocarcinoma cells were found in the CSF of 18 patients and 19 patients had typical imaging for LM, whereas all 26 patients with available CSF supernatant for NGS showed positivity for cfDNA in CSF.¹⁷ In another study involving two breast cancer patients with LM, cytopathologic analyses yielded negative results, whereas CSF cfDNA were positive for both patients.¹⁸ Therefore, positive CSF liquid biopsy has been recommended to diagnose LM, along with CSF positive for tumor cells or positive radiological findings with supportive clinical findings.⁵ Moreover, in epidermal growth factor receptor (EGFR) mutant or anaplastic lymphoma kinase (ALK)-positive NSCLC patients with LM, cfDNA in CSF by NGS facilitated a comprehensive understanding of gene profiles of CSF, which can help identify the mechanisms of drug resistance and adjust therapy strategies.^{17–19} However, only limited number of patients were included in these studies, and the clinical use of CSF cfDNA detection needs to be further verified.

In the current study, we retrospectively assessed the genetic profiles of paired CSF and plasma samples in lung cancer patients with LM, and explored the role of CSF cfDNA in diagnosis of LM, detection of resistance mechanism to targeted therapies, and feasibility to guide subsequent treatment.

METHODS

Study design and patients

This is a retrospective cohort study. From December 2014 to December 2020, a consecutive of 17 lung cancer patients with suspected LM were screened for eligibility at the Department of Respiratory Diseases, Daping Hospital of Army Medical University (Chongqing, China). All patients underwent lumbar puncture, brain MRI, and paired NGS of

CSF and plasma cfDNA. The diagnosis criteria of LM were a positive result on brain MRI or CSF cytology, or the presence of CSF cfDNA. Brain MRI was performed following standard procedures and the typical imaging of LM was identified by experienced radiologists. Patients were excluded if LM diagnosis was not reached. We collected demographic and clinical characteristics of patients including sex, age, histology, treatment history, and molecular information.

NGS of paired CSF and plasma cfDNA

Approximately 10 mL of CSF and 10 mL of paired plasma was collected and submitted for NGS analysis. All NGS tests were performed in a commercial laboratory with College of American Pathologists (CAP)/Clinical Laboratory Improvement Amendments (CLIA) certifications (Burning Rock Company).²⁰ Indexed samples were sequenced on Next-seq500 (Illumina) with paired-end reads using targeted panels consisting of 168 lung cancer-related genes, with a mean sequencing depth of 16 745, spanning 0.273 megabases (Mb) of the human genome.

Outcomes

We primarily compared the genetic profiles of CSF and plasma cfDNA as assessed by NGS. The common and specific genetic variations, as well as the maximum allelic fractions (MaxAFs) from two groups were counted and compared. Patients with disease progression were divided into two groups: systemic progression and LM progression only. Systemic progression was defined as LM progression together with enlargement of primary lung lesions or newly occurring distant metastasis. LM progression only was defined as disease progression happened only in the LM and the primary lung lesion being stable and no other distant metastasis. The plasma CEA dynamics between the two groups were compared.

Statistical analysis

Statistical analysis and graph making were performed using GraphPad Prism 8 for Windows, GraphPad Software (www.graphpad.com). *p* Values were two-sided and considered significant if <0.05.

RESULTS

Patient characteristics

Of 17 patients screened, a total of 14 patients were diagnosed with LM, whereas three patients did not meet the diagnostic criteria. All patients harbor drive gene mutations

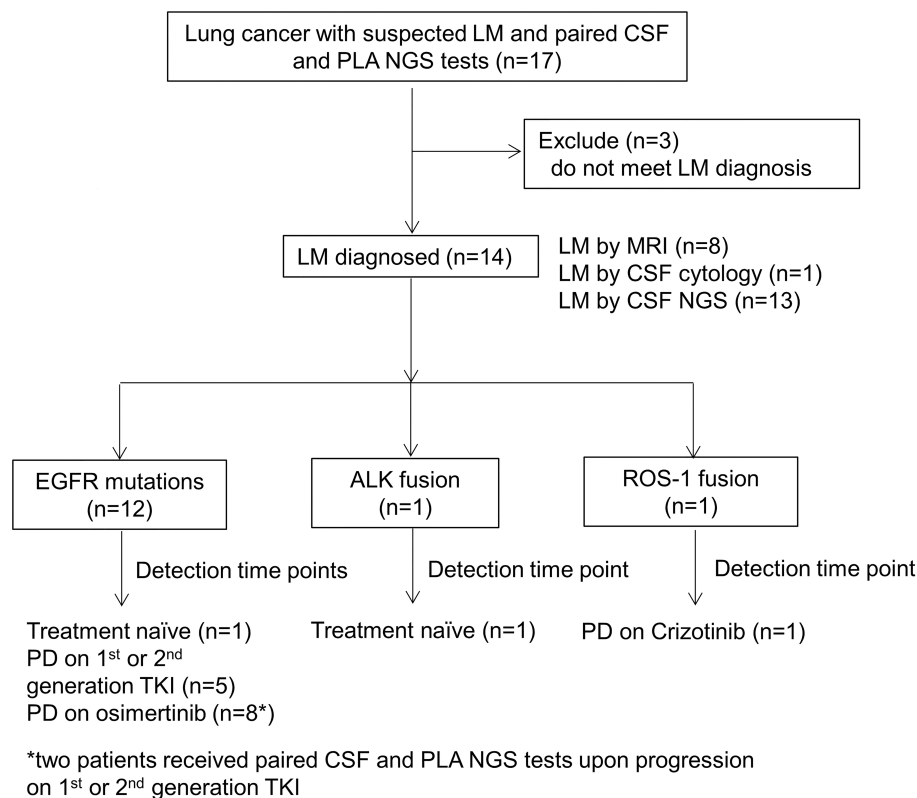


FIGURE 1 Study flow chart. ALK, anaplastic lymphoma kinase; CSF, cerebrospinal fluid; EGFR, epidermal growth factor receptor; LM, leptomeningeal metastasis; MRI, magnetic resonance imaging; NGS, next-generation sequencing; PD, progressive disease; PLA, plasma; TKI, tyrosine kinase inhibitor

(12 EGFR activating mutations, 1 ALK rearrangement, and 1 ROS-1 fusion). Two patients (P1 and P2) failed to obtain pathological diagnosis, so those genotypes of common driver genes were found by NGS of CSF at baseline. Genetic profiles of P5 and P10 were identified by NGS of plasma for insufficient tissue samples at initial diagnosis. The results of genetic mutations of other 10 patients were detected from identified routine tests of primary lung cancer tissues at baseline. The study flow chart was shown in Figure 1. The median age was 57.5 years old (range, 45–74 years), and eight patients were female. Two patients (P1 and P2) failed to obtain pathological diagnosis and received NGS of CSF at baseline before initiation of any therapy (treatment naïve). The other 12 patients were diagnosed with lung adenocarcinoma, and LM was diagnosed on disease progression on TKI therapy. The demographic characteristics of each enrolled patient are summarized in Table 1.

According to previous reports, LM can be diagnosed by identifying tumor cells in the CSF, or brain MRI, or detection of mutations in CSF by NGS. In the current study, CSF cytology was only available in four patients because of limited samples, and adenocarcinoma cells were found in one patient (positive rate of 25%). Typical imaging of LM in brain MRI was identified in 7 of 14 patients with a positive rate of 50%. Genetic mutations were detected in CSF cfDNA from 13 of 14 patients. In seven patients (P1, P2, P3, P6, P8, P12, and P14) with negative CSF cytology and MRI (or cytology not available), positive CSF cfDNA was detected. In contrast, in P13 with negative CSF cfDNA and

cytology was not available, MRI showed typical signs of LM. These results suggest that the diagnostic value of CSF cfDNA in LM may be superior to cytology and MRI, whereas the combination of these approaches can facilitate and complement the diagnosis.

Genetic profiles presented in the matched CSF and plasma cfDNA

We compared the genetic profiles of matched CSF and plasma samples from 14 patients (Figure 2 and Table S1). The detection rates, defined as having any mutation detected, were 92.9% (13/14) and 64.2% (9/14) for CSF and plasma, respectively. In total, we identified 37 and 14 genomic alterations from CSF and plasma samples, respectively (Figure 2(a)). Further comparison revealed a concordance rate of 24.38%, with 10 mutations shared by the two media, which indicated that the mutations were highly divergent between CSF and plasma cfDNA. In total, there were 27 and 4 mutations that were only present in CSF and plasma, respectively. The common or specific mutations of CSF and plasma cfDNA for each patient were shown in Figure 2(b). Next, we compared the MaxAFs between CSF and plasma. The median MaxAF was significantly higher in CSF cfDNA (46.08% vs 0.43% of plasma cfDNA, $p < 0.01$, Figure 2(c)). In a total of 12 EGFR mutant patients, 91.67% (11/12) CSF samples were positive for EGFR sensitive mutations, including EGFR 19del in six samples (50%) and L858R in three

TABLE 1 Characteristic of enrolled patients

No.	Age	Sex	Pathology	Genetic mutation	CSF cytology	Brain MRI	CSF cfDNA NGS	Disease status on NGS tests	CNS involvement	Treatment after LM identified	PFS ^a (month)	OS ^b (month)
P1	54	F	UA	EGFR 19del	N	N	P	Treatment naive	N	Osimertinib	14.1	14.1
P2	46	F	UA	ALK rearrangement	UA	N	P	Treatment naive	P	Alectinib	19.4	24.0
P3	56	M	AD	EGFR L833V EGFR L858R	UA	N	P	PD on afatinib and chemo	P	Afatinib	12.4	22.0
P4	45	M	AD	EGFR 19del	P	P	P	PD on gefitinib	N	Gefitinib+ Crizotinib	1.6	10.9
P5	67	M	AD	EGFR S768I	UA	P	P	PD on afatinib	P	Osimertinib	2.1	6.3
P6	50	F	AD	EGFR 19del	UA	N	P	PD on gefitinib	P	Osimertinib	39.2	63.7
P7	64	M	AD	/	UA	N	P	PD on osimertinib	P	/	/	/
P8	74	F	AD	EGFR 19del	N	P	P	PD on erlotinib	N	Osimertinib	6.7	28.5
P9	46	M	AD	/	UA	P	P	PD on osimertinib	N	/	/	/
P10	66	F	AD	EGFR L858R	UA	N	P	PD on osimertinib	P	Osimertinib	15.6	18.5
P11	66	M	AD	EGFR L858R	UA	P	P	PD on osimertinib	P	Osimertinib	13.7	28.5
P12	49	F	AD	EGFR 19del	UA	N	P	PD on gefitinib, osimertinib, and chemo	N	Osimertinib	23.9	61.8
P13	59	F	AD	EGFR S768I EGFR L858R	UA	P	N	PD on gefitinib, osimertinib, and chemo + Pembro	P	UA	UA	22.4
P14	68	F	AD	EGFR G719A	UA	N	P	PD on osimertinib	P	UA	UA	61.3
P15	59	F	AD	EGFR 19del	UA	P	N	PD on gefitinib, osimertinib, and chemo	P	UA	UA	63.3
P16	68	F	AD	ROS-1 fusion	UA	N	P	PD on erlotinib, and osimertinib	P	UA	UA	19.4

Abbreviations: ALK, anaplastic lymphoma kinase; AD, adenocarcinoma; cfDNA, cell-free DNA; Chemo, chemotherapy; CNS, central nervous system; CSF, cerebrospinal fluid; EGFR, epidermal growth factor receptor; F, female; LM, leptomeningeal metastasis; M, male; MRI, magnetic resonance imaging; N, negative; NGS, next-generation sequencing; OS, overall survival; P, positive; PD, progression of disease; Pembro, pembrolizumab; PFS, progression-free survival; UA, unavailable.

^aFrom LM identified to first PD.

^bThe date of last follow-up was August 1, 2021.

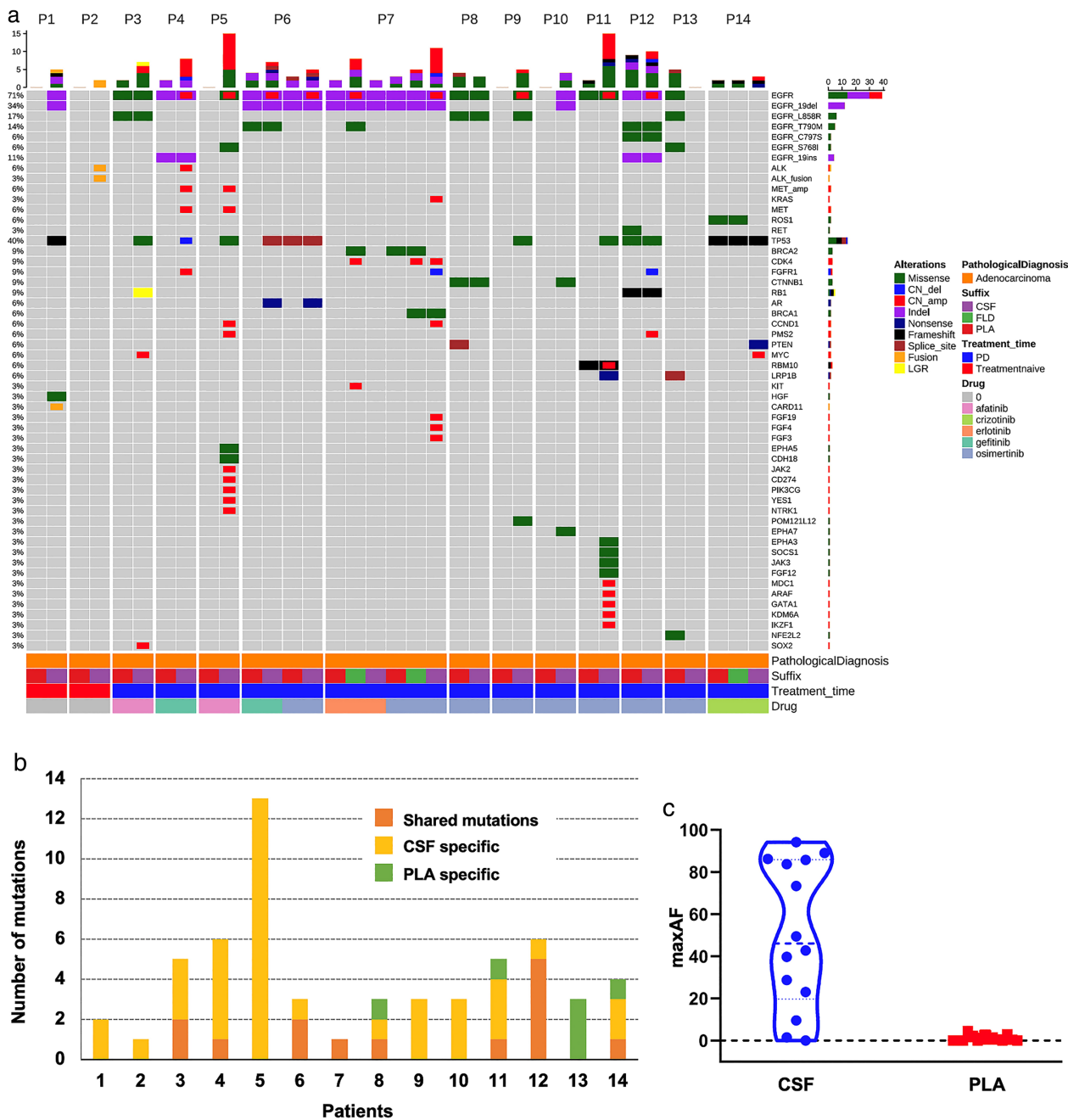


FIGURE 2 Comparison of genetic profiles of paired CSF and PLA tests. (a), mutation spectrum of the 14 patients. The patient number was indicated on the top of the oncoprint. columns represent patients and rows represent genes. Numbers on the left represent the percentage of patients with mutations in a specific gene. Top plot represents the overall number of mutations a patient carried different colors denote different types of mutations. (b), number of CSF specific, PLA specific, or shared mutations; (c), maximum mutation allelic fractions (maxAFs) of CSF and PLA, respectively; CN_del, copy number deletion; CN_amp, copy number gain; CSF, cerebrospinal fluid; FLD, pleural effusion; LGR, large genome rearrangement; PD, progressive disease; PLA, plasma

samples (20%). Moreover, EGFR mutations were found in 66.6% (8 of 12) of plasma samples, including four EGFR 19del (33.3%) and three L858R (20%). EGFR L833V was detected in P3 and G719A in P11, in both CSF and plasma. EGFR S768I was detected in CSF sample from P5, and plasma from P13, respectively. Collectively, our data demonstrate that CSF is superior to plasma in providing a more comprehensive genetic landscape of LM.

CSF cfDNA genotyping revealed resistance mechanisms of LM

A total of five EGFR-mutated LM patients received matched CSF and plasma genotyping after they experienced progression on 1st or 2nd generation EGFR-TKIs (Figure 2(a) and Table S1). For P6, EGFR T790M was detected in both CSF and plasma cfDNA. For P7, only EGFR 19del was detected

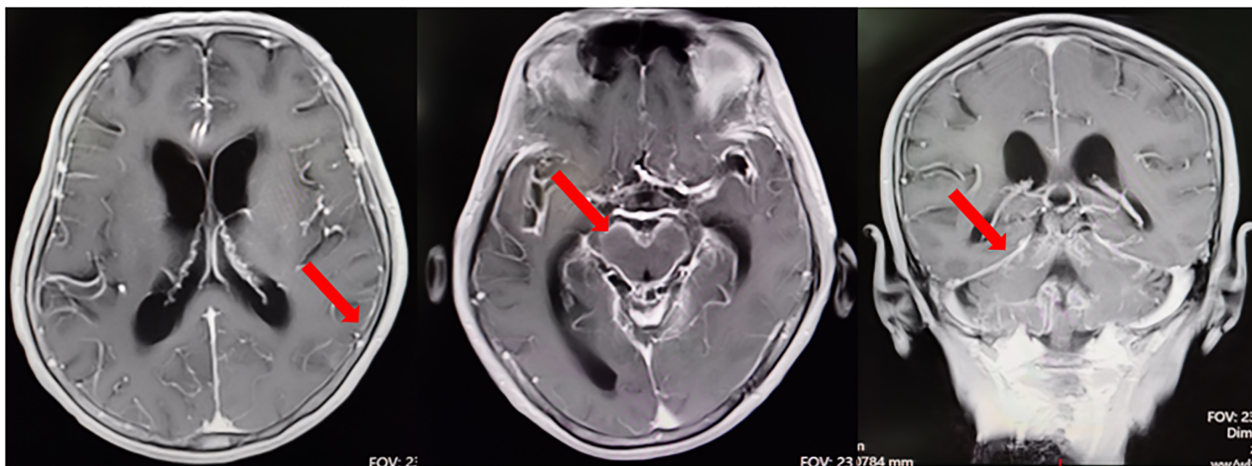


FIGURE 3 A representative case with typical images of brain MRI from patient 10 with leptomeningeal metastasis (LM). There were multiple abnormal signals in the occipital lobe, cerebellar hemisphere, and brainstem (red arrow). Multiple leptomeningeal metastasis was considered.

in both media, whereas EGFR T790M was detected in matched pleural effusion sample. For the other three patients (P3, P4, and P5), plasma cfDNA failed to find any resistance mechanisms. In contrast, matched CSF cfDNA found RB1 mutation in P3, and amplification of both *MET* and *EGFR* in P4 and P5. Hence, we deduced that CSF cfDNA could benefit the analysis of resistance mechanisms to targeted therapies and guide the treatment.

Of the eight patients who experienced LM progression during treatment with osimertinib, the detection of EGFR mutations by CSF and plasma genotyping was 87.5% (7/8) and 75% (6/8), respectively (Figure 2(a) and Table S1). TP53 was the most frequently detected concurrent gene in both CSF and plasma. Concurrent genes were much more likely to be detected in CSF than in plasma (Figure 2(a)). EGFR pathway-related resistance mechanism of C797S mutation was found in only one patient (P12) in both CSF and plasma samples. *EGFR* amplification was detected in CSF cfDNA from four patients (P6, P7, P9, and P11), whereas no CNVs were detected in the matched plasma samples. Possible EGFR-independent resistant mechanism of PTEN mutation was detected in plasma, but not CSF cfDNA, in P8. No *MET* amplification was detected in CSF or plasma in any of the eight patients. Taken together, these results suggest that NGS test of CFS cfDNA was much better at providing a more comprehensive genetic landscape of resistance mechanisms of LM than plasma samples. A representative case with typical images of brain MRI from P10 was shown in Figure 3.

The resistance mechanism of LM in ROS-1 fusion NSCLC has not been reported. In P14 with ROS-1 fusion, drug resistance to crizotinib occurred after 10 months of treatment, reflected by enlargement of the primary tumor and metastasis to the brain, pericardial, and pleura. NGS tests in matched CSF, pleural effusion, and plasma cfDNA were performed. ROS-1 p.G2032R and TP53 were found in plasma and pleural effusion, whereas *MYC* amplification, PTEN, and TP53 were found in CSF cfDNA (Figure 2 (a) and Table S1). These results suggest heterogeneous

resistance mechanisms between the primary tumor and LM on disease progression.

Relationship between CEA dynamic changes, disease progression modes, and cfDNA detection

We next studied the relationship between plasma CEA levels and disease progression modes. CEA levels on and before disease progression (intervals 1–3 months) were available in 11 patients (excluding P1 and P2 being treatment naïve and P13 for whom CEA not measured). A total of five patients experienced systemic progression, including enlargement of primary lung lesions, or disease spread to distant sites. The other six patients experienced LM progression only, with primary lung lesion stable and no newly occurring distant metastasis. As shown in Figure 3, CEA levels increased in four of five patients with systemic progression, whereas three of six patients with LM progression only showed CEA increase and the other three patients showed CEA decrease. These results suggest that increase of CEA happened more frequently in patients with systemic progression, whereas patients with LM progression only were not always accompanied by the increase of plasma CEA levels.

We next assessed the relationship of CEA dynamics and cfDNA detection results. In patients with LM progression only and CEA increase, the cfDNA results in plasma and CFS were highly concordant for driver gene mutations. However, in the other three patients with LM progression only and CEA decrease, drug resistance mechanisms were only found in CSF cfDNA, not plasma cfDNA. In patients with systemic progression, despite that the majority of patients experienced CEA increase, CSF cfDNA revealed a more comprehensive genetic profile than plasma cfDNA. Taken together, these results again highlight the importance of CSF cfDNA genotyping in discovering drug resistance mechanisms of targeted therapies.

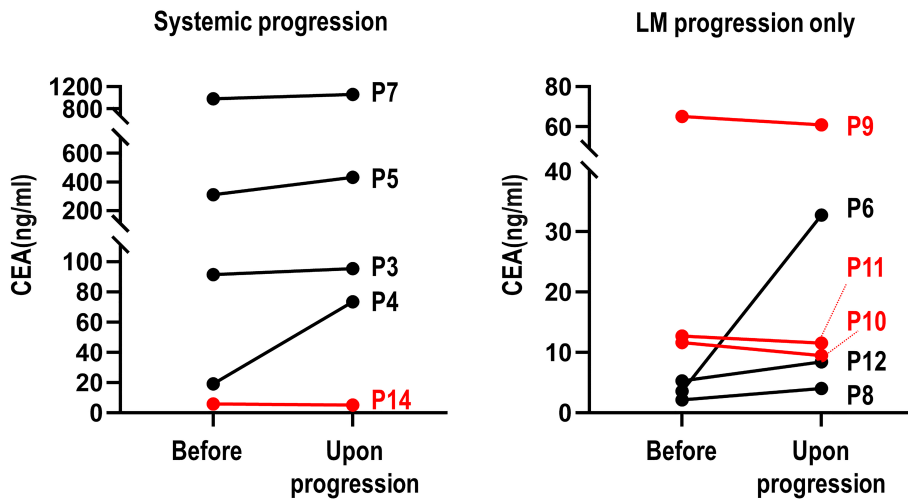


FIGURE 4 CEA dynamics of individual patients as grouped by disease progression modes. Left, patients with systemic progression; LM, leptomeningeal metastasis; Right, patients with LM progression only

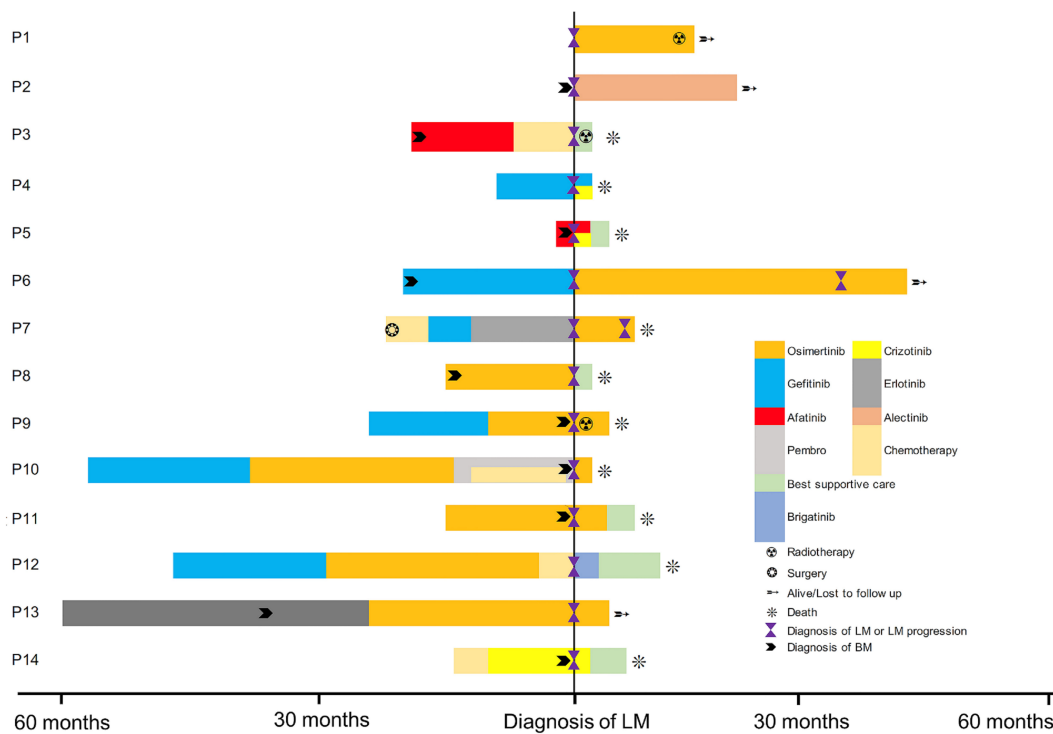


FIGURE 5 Treatment of individual patients with leptomeningeal metastasis (LM). BM, brain metastasis; Pembro, pembrolizumab

Therapeutic indications of CSF cfDNA genotyping

The treatments and prognosis of 14 patients before and after LM diagnosis were shown in Figure 4. For P1 and P2, LM was diagnosed at baseline. Both patients experienced neurologic symptoms yet no LM signs were found by MRI. CSF cytology was negative for P1 and not available for P2. Pathology was not available for these two patients. However, EGFR 19del and ALK rearrangement were detected by NGS of CSF cfDNA in these two patients, respectively. Osimertinib was given to P1 and alectinib to P2, which resulted in a progression-free survival (PFS) of 14 and 15 months, respectively. For the other

12 patients, LM was diagnosed after disease progression on prior therapies. The median overall survival (OS) of these 12 patients was only 4.1 months after LM diagnosis, with a total of 58.3% patients died within 6 months. For P4 and P5, crizotinib was given to both patients after *MET* amplification was detected in CSF cfDNA, yet both patients experienced disease progression and died several months later (Figure 5).

DISCUSSIONS

In the current study, we explored the potential role of CSF as liquid biopsy medium in NSCLC patients with LM.

These findings suggested that NGS detection of CSF cfDNA may be a more sensitive and effective way to diagnose LM and may serve as a liquid biopsy medium to reveal a more comprehensive genetic profile of LM, to elucidate drug resistance mechanisms and to guide subsequent therapeutic strategies.

Because of the urge for earlier diagnosis of LM and limited sensitivities of cytopathology and Gd-MRI, novel diagnostic tests to improve the detection rate of LM are urgently needed. The identification of tumor cells in the CSF remains the gold standard for the diagnosis of LM, despite low sensitivity (~50% at the first lumbar puncture).²¹ In addition to CSF cytology, Gd-MRI of the neuroaxis has also been used to detect LM.⁵ However, it remains difficult to appreciate the diagnostic accuracy of Gd-MRI. Reported sensitivities and specificities range from 53% to 80% and 77% to 93%, respectively.²² In the current study, CSF cytology was successfully performed in only 4 of 14 patients, and tumor cells were found in only one patient. Brain MRI was performed in all 14 patients, and the positive rate was 50%. These results, together with previous findings from other studies, suggest that novel diagnostic tests are needed to improve the detection rate of LM.

A liquid biopsy of the CSF by NGS is fast emerging as an important approach to diagnose LM in lung cancer. In a previous study, sensitivity of LM detection by cfDNA and cytopathology was 84.6% and 53.9%, respectively.²³ In the current study, we also found that NGS of CSF cfDNA showed a significantly higher positive rate than cytopathology or brain MRI. Moreover, the detection rate of cfDNA in CSF was significantly higher than that in the plasma. Similarly, it was reported that in ALK-rearranged NSCLC with LM, the detection rate of driver genes was 81.8% in the CSF, than that of 45.5% of the plasma.²⁴ Another study also reported that in 26 lung adenocarcinoma cancer patients with LM, the detection rate of mutations in CSF cfDNA was significantly higher than that in the plasma (80.0% vs. 30.77%).²⁵ Of note, the current study reported that in two LM patients for whom biopsy of primary lung lesion was difficult to perform, activating driver mutations were identified in CSF cfDNA only, which successfully guided subsequent treatments. Moreover, CEA is an important biochemical marker in metastatic NSCLC patients. The dynamic changes of plasma CEA level is related with disease development. We retrospectively collected the plasma CEA level data of patients with LM. Our study revealed the relationship between CEA dynamic changes, disease progression modes, and cfDNA detection. The plasma CEA level usually appeared to be increased in patients with systemic progression. However, patients with LM progression only were not always accompanied by increase of CEA level. Moreover, for patients with only LM progression, but whose plasma CEA level decreased, CSF cfDNA gene detection is particularly important and may be the only way to find the mechanism of drug resistance. Altogether, these results suggest that LM and extracranial tumors may arise from branched tumor evolution, underscoring the importance of profiling mutations using NGS of CSF cfDNA to identify driver mutations and optimize therapies. In the

previous articles that found discrepancies between CSF and plasma, CSF had more mutations detected, which was confirmed in our study. Several reasons might be considered. First, owing to the blood–brain barrier, CSF cfDNA is unable to circulate fully within the blood system, resulting in a limited amount of cfDNA from CNS being released to plasma. Second, tumor-derived DNA typically constitutes a small fraction of all cfDNA in plasma, whereas the proportion of such DNA in CSF is much higher because of the lower background of normal DNA.¹⁷ Of course, the sensitivity also depends on the input DNA and effective sequencing depth of NGS. Theoretically and technically, the sensitivity of plasma cfDNA could be increased by increasing the performance of plasma NGS if the mutations of LM were also released into blood. On the other side, if the mutations were unique in LM and constrained biologically only in CSF, then the CSF will be a preferred material for genotyping.

In the current study, one important finding is that a large number of CNVs were detected in the CSF, yet no CNV was detected in the plasma. Similarly, in a previous study involving EGFR mutant NSCLC with LM who received paired NGS tests of CSF, tissue and plasma samples, the majority of CNVs were only detected in CSF cfDNA, which were not identified in primary tissue or plasma.¹⁷ It has been reported that CNVs may evolve from genomic instability processes at the chromosomal and mutational levels.²⁶ Moreover, CNVs at a certain combination of gene loci (such as *c-Myc*, *TERT*, and *HLA*) could lead to alteration of the gene expression of different signaling pathways, therefore, conferring a selective advantage for metastasis.²⁷ Therefore, the presence of multiple unique CNVs in CSF cfDNA may be the key events during the development of LM in lung cancer.

Among the CNVs detected in the current study, *MET* copy number gain and *EGFR* copy number gain were the most clinically relevant CNVs, both of which were important mechanisms of acquired resistance to EGFR-TKIs.^{28,29} We and others have reported that *MET* amplification was associated with EGFR-TKI resistance, which responded to the combination of EGFR-TKI and crizotinib clinically and in preclinical models.^{28,30–33} However, in the current study, crizotinib did not bring benefit for patients with *MET* amplification on disease progression on EGFR-TKIs. As previously reported, crizotinib has limited CNS penetration.³⁴ Other *MET* inhibitors, such as tepotinib, capmatinib, or savolitinib, may have better brain activity to cross the blood–brain barrier.^{35–37} Future studies are needed to test the combination of EGFR-TKIs with those *MET* inhibitors in LM NSCLC with *MET* amplification after disease progression on EGFR-TKIs. Moreover, *EGFR* amplification also constituted a mechanism of EGFR-TKI resistance.^{28,38} Currently, there is no standard targeted therapy to treat NSCLC with *EGFR* amplification. In a phase I study, nimotuzumab combined with gemcitabine and cisplatin led to a better prognosis in NSCLC with *EGFR* amplification.³⁹ Several studies have tested the combination of cetuximab in combination with chemotherapy in NSCLC, and EGFR-expressing tumors were enrolled in some trials.^{40–43} However, currently

there is no available data regarding whether cetuximab can be used to overcome TKI resistance in EGFR mutant NSCLC with *EGFR* amplification as resistance mechanism.

The current study has several limitations. First, this was a retrospective study with small samples. Second, primary cancer tissues of the patients were unavailable. Because CSF cytology was only available in four patients and only two patients underwent NGS test of matched malignant fluids, more information about the evolution of genetic alterations in CSF counterpart was unable to be shown. Third, CSF CEA levels were not available for most patients so we did not analyze CSF CEA levels with genetic detections. Moreover, 168-genes NGS panel size might be not competent for TMB calculation.

In conclusion, CSF cfDNA provided comprehensive profiles of genetic mutations of LM, supporting the importance of CSF cfDNA as a liquid biopsy medium, especially in patients with LM progression only and did not experience plasma CEA increase. CNVs may be the potential metastasis mechanisms of LM in EGFR-mutant NSCLC.

ACKNOWLEDGMENTS

Thanks to the help of Burning Rock Biotech company.

CONFLICT OF INTEREST

The authors declare no conflict of interest.

ORCID

Naifu Nie  <https://orcid.org/0000-0003-1511-6228>

Li Li  <https://orcid.org/0000-0003-3499-8465>

Yong He  <https://orcid.org/0000-0002-9404-798X>

REFERENCES

- Barnholtz-Sloan JS, Sloan AE, Davis FG, Vignea FD, Lai P, Sawaya RE. Incidence proportions of brain metastases in patients diagnosed (1973 to 2001) in the metropolitan Detroit cancer surveillance system. *J Clin Oncol*. 2004;22(14):2865–72.
- Remon J, Le Rhun E, Besse B. Leptomeningeal carcinomatosis in non-small cell lung cancer patients: a continuing challenge in the personalized treatment era. *Cancer Treat Rev*. 2017;53:128–37.
- Li YS, Jiang BY, Yang JJ, Tu HY, Zhou Q, Guo WB, et al. Leptomeningeal metastases in patients with NSCLC with EGFR mutations. *J Thorac Oncol*. 2016;11(11):1962–9.
- Le Rhun E, Galanis E. Leptomeningeal metastases of solid cancer. *Curr Opin Neurol*. 2016;29(6):797–805.
- Cheng H, Perez-Soler R. Leptomeningeal metastases in non-small-cell lung cancer. *Lancet Oncol*. 2018;19(1):e43–55.
- Yang JCH, Kim SW, Kim DW, Lee JS, Cho BC, Ahn JS, et al. Osimertinib in patients with epidermal growth factor receptor mutation-positive non-small-cell lung cancer and leptomeningeal metastases: the BLOOM study. *J Clin Oncol*. 2020;38(6):538–47.
- Hida T, Nokihara H, Kondo M, Kim YH, Azuma K, Seto T, et al. Alectinib versus crizotinib in patients with ALK-positive non-small-cell lung cancer (J-ALEX): an open-label, randomised phase 3 trial. *Lancet*. 2017;390(10089):29–39.
- Choo JR, Soo RA. Lorlatinib for the treatment of ALK-positive metastatic non-small cell lung cancer. *Expert Rev Anticancer Ther*. 2020;20(4):233–40.
- Glass JP, Melamed M, Chernik NL, Posner JB. Malignant cells in cerebrospinal fluid (CSF): the meaning of a positive CSF cytology. *Neurology*. 1979;29(10):1369–75.
- Clarke JL, Perez HR, Jacks LM, Panageas KS, Deangelis LM. Leptomeningeal metastases in the MRI era. *Neurology*. 2010;74(18):1449–54.
- Le Rhun E, Taillibert S, Chamberlain MC. Carcinomatous meningitis: leptomeningeal metastases in solid tumors. *Surg Neurol Int*. 2013;4(Suppl 4):S265–88.
- Chamberlain MC. Cytologically negative carcinomatous meningitis: usefulness of CSF biochemical markers. *Neurology*. 1998;50(4):1173–5.
- Corsini E, Bernardi G, Gaviani P, Silvani A, de Grazia U, Ciusani E, et al. Intrathecal synthesis of tumor markers is a highly sensitive test in the diagnosis of leptomeningeal metastasis from solid cancers. *Clin Chem Lab Med*. 2009;47(7):874–9.
- Kang SJ, Kim KS, Ha YS, Huh SY, Lee JH, Kim JK, et al. Diagnostic value of cerebrospinal fluid level of carcinoembryonic antigen in patients with leptomeningeal carcinomatous metastasis. *J Clin Neurol*. 2010;6(1):33–7.
- Shi Q, Pu CQ, Huang XS, Tian CL, Cao XT. Optimal cut-off values for tumor markers in cerebrospinal fluid with ROC curve analysis. *Front Biosci (Elite Ed)*. 2011;3:1259–64.
- Shingyoji M, Kageyama H, Sakaida T, Nakajima T, Matsui Y, Itakura M, et al. Detection of epithelial growth factor receptor mutations in cerebrospinal fluid from patients with lung adenocarcinoma suspected of neoplastic meningitis. *J Thorac Oncol*. 2011;6(7):1215–20.
- Li YS, Jiang BY, Yang JJ, Zhang XC, Zhang Z, Ye JY, et al. Unique genetic profiles from cerebrospinal fluid cell-free DNA in leptomeningeal metastases of EGFR-mutant non-small-cell lung cancer: a new medium of liquid biopsy. *Ann Oncol*. 2018;29(4):945–52.
- De Mattos-Arruda L, Mayor R, Ng CKY, et al. Cerebrospinal fluid-derived circulating tumour DNA better represents the genomic alterations of brain tumours than plasma. *Nat Commun*. 2015;6:8839.
- Zheng MM, Li YS, Tu HY, Jiang BY, Yang JJ, Zhou Q, et al. Genotyping of cerebrospinal fluid associated with Osimertinib response and resistance for leptomeningeal metastases in EGFR-mutated NSCLC. *J Thorac Oncol*. 2021;16(2):250–8.
- Deveson IW, Gong B, Lai K, LoCoco JS, Richmond TA, Schageman J, et al. Evaluating the analytical validity of circulating tumor DNA sequencing assays for precision oncology. *Nat Biotechnol*. 2021;39:1115–28.
- Grossman SA, Krabak MJ. Leptomeningeal carcinomatosis. *Cancer Treat Rev*. 1999;25(2):103–19.
- Hyun JW, Jeong IH, Joung A, Cho HJ, Kim SH, Kim HJ. Leptomeningeal metastasis: clinical experience of 519 cases. *Eur J Cancer*. 2016;56:107–14.
- Naidoo J, Schreck KC, Fu W, Hu C, Carvajal-Gonzalez A, Connolly RM, et al. Pembrolizumab for patients with leptomeningeal metastasis from solid tumors: efficacy, safety, and cerebrospinal fluid biomarkers. *J Immunother Cancer*. 2021;9(8):e002473.
- Zheng MM, Li YS, Jiang BY, Tu HY, Tang WF, Yang JJ, et al. Clinical utility of cerebrospinal fluid cell-free DNA as liquid biopsy for leptomeningeal metastases in ALK-rearranged NSCLC. *J Thorac Oncol*. 2019;14(5):924–32.
- Ge M, Zhan Q, Zhang Z, Ji X, Zhou X, Huang R, et al. Different next-generation sequencing pipelines based detection of tumor DNA in cerebrospinal fluid of lung adenocarcinoma cancer patients with leptomeningeal metastases. *BMC Cancer*. 2019;19(1):143.
- Jiang BY, Li YS, Guo WB, Zhang XC, Chen ZH, Su J, et al. Detection of driver and resistance mutations in leptomeningeal metastases of NSCLC by next-generation sequencing of cerebrospinal fluid circulating tumor cells. *Clin Cancer Res*. 2017;23(18):5480–8.
- Nanjo S, Hata A, Okuda C, Kaji R, Okada H, Tamura D, et al. Standard-dose osimertinib for refractory leptomeningeal metastases in T790M-positive EGFR-mutant non-small cell lung cancer. *Br J Cancer*. 2018;118(1):32–7.
- Leonetti A, Sharma S, Minari R, Perego P, Giovannetti E, Tiseo M. Resistance mechanisms to osimertinib in EGFR-mutated non-small cell lung cancer. *Br J Cancer*. 2019;121(9):725–37.
- Fuchs V, Roisman L, Kian W, Daniel L, Dudnik J, Nechushtan H, et al. The impact of osimertinib' line on clonal evolution in EGFRm NSCLC through NGS-based liquid biopsy and overcoming strategies for resistance. *Lung Cancer*. 2021;153:126–33.

30. Zou HY, Li Q, Lee JH, Arango ME, McDonnell SR, Yamazaki S, et al. An orally available small-molecule inhibitor of c-met, PF-2341066, exhibits cytoreductive antitumor efficacy through antiproliferative and antiangiogenic mechanisms. *Cancer Res.* 2007;67(9):4408–17.
31. Wang Y, Tian P, Xia L, Li L, Han R, Zhu M, et al. The clinical efficacy of combinatorial therapy of EGFR-TKI and crizotinib in overcoming MET amplification-mediated resistance from prior EGFR-TKI therapy. *Lung Cancer.* 2020;146:165–73.
32. Wang W, Wang H, Lu P, Yu Z, Xu C, Zhuang W, et al. Crizotinib with or without an EGFR-TKI in treating EGFR-mutant NSCLC patients with acquired MET amplification after failure of EGFR-TKI therapy: a multicenter retrospective study. *J Transl Med.* 2019;17(1):52.
33. Solomon B. Trials and tribulations of EGFR and MET inhibitor combination therapy in NSCLC. *J Thorac Oncol.* 2017;12(1):9–11.
34. Costa DB, Shaw AT, Ou SH, et al. Clinical experience with Crizotinib in patients with advanced ALK-rearranged non-small-cell lung cancer and brain metastases. *J Clin Oncol.* 2015;33(17):1881–8.
35. Wu YL, Zhang L, Kim DW, Liu X, Lee DH, Yang JCH, et al. Phase Ib/II study of Capmatinib (INC280) plus Gefitinib after failure of epidermal growth factor receptor (EGFR) inhibitor therapy in patients with EGFR-mutated, MET factor-dysregulated non-small-cell lung cancer. *J Clin Oncol.* 2018;36(31):3101–9.
36. Wu YL, Cheng Y, Zhou J, Lu S, Zhang Y, Zhao J, et al. Tepotinib plus gefitinib in patients with EGFR-mutant non-small-cell lung cancer with MET overexpression or MET amplification and acquired resistance to previous EGFR inhibitor (INSIGHT study): an open-label, phase 1b/2, multicentre, randomised trial. *Lancet Respir Med.* 2020;8(11):1132–43.
37. Sequist LV, Han JY, Ahn MJ, Cho BC, Yu H, Kim SW, et al. Osimertinib plus savolitinib in patients with EGFR mutation-positive, MET-amplified, non-small-cell lung cancer after progression on EGFR tyrosine kinase inhibitors: interim results from a multicentre, open-label, phase 1b study. *Lancet Oncol.* 2020;21(3):373–86.
38. Knebel FH, Bettoni F, Shimada AK, Cruz M, Alessi JV, Negrão MV, et al. Sequential liquid biopsies reveal dynamic alterations of EGFR driver mutations and indicate EGFR amplification as a new mechanism of resistance to osimertinib in NSCLC. *Lung Cancer.* 2017;108:238–41.
39. Wang HQ, Ren Y, Qian ZZ, Fu K, Zhang HL, Li W, et al. Nimotuzumab combined with gemcitabine and cisplatin as second-line chemotherapy for advanced non-small-cell lung cancer. *Thorac Cancer.* 2012;3(1):72–8.
40. Rosell R, Robinet G, Szczesna A, Ramlau R, Constenla M, Mennecier BC, et al. Randomized phase II study of cetuximab plus cisplatin/vinorelbine compared with cisplatin/vinorelbine alone as first-line therapy in EGFR-expressing advanced non-small-cell lung cancer. *Ann Oncol.* 2008;19(2):362–9.
41. Pirker R, Pereira JR, Szczesna A, von Pawel J, Krzakowski M, Ramlau R, et al. Cetuximab plus chemotherapy in patients with advanced non-small-cell lung cancer (FLEX): an open-label randomised phase III trial. *Lancet.* 2009;373(9674):1525–31.
42. Herbst RS, Kelly K, Chansky K, Mack PC, Franklin WA, Hirsch FR, et al. Phase II selection design trial of concurrent chemotherapy and cetuximab versus chemotherapy followed by cetuximab in advanced-stage non-small-cell lung cancer: southwest oncology group study S0342. *J Clin Oncol.* 2010;28(31):4747–54.
43. Lynch TJ, Patel T, Dreisbach L, McCleod M, Heim WJ, Hermann RC, et al. Cetuximab and first-line taxane/carboplatin chemotherapy in advanced non-small-cell lung cancer: results of the randomized multicenter phase III trial BMS099. *J Clin Oncol.* 2010;28(6):911–7.

SUPPORTING INFORMATION

Additional supporting information can be found online in the Supporting Information section at the end of this article.

How to cite this article: Nie N, Zhou H, Zhang K, liu L, Luo N, Wang R, et al. Genotyping of cerebrospinal fluid in lung cancer patients with leptomeningeal metastasis. *Thorac Cancer.* 2022; 13(18):2574–83. <https://doi.org/10.1111/1759-7714.14592>