


Pre- and postoperative offset and femoral neck version measurements and validation using 3D computed tomography in total hip arthroplasty

Acta Radiologica Open
9(10) 1–10
© The Foundation Acta Radiologica
2020
DOI: 10.1177/2058460120964911
journals.sagepub.com/home/arr


Mats Geijer^{1,2,3} , Sverrir Kiernan⁴, Martin Sundberg⁴ and Gunnar Flivik⁴

Abstract

Background: Restoration of a correct biomechanical situation after total hip arthroplasty is important.

Purpose: To evaluate proximal femoral symmetry of acetabular and femoral offset and femoral neck anteversion pre- and postoperatively in hip arthroplasty by semi-automated 3D-CT and to validate the software measurements by inter- and intraobserver agreement calculations.

Material and Methods: In low-dose CT on 71 patients before and after unilateral total hip arthroplasty, two observers used a digital 3D templating software to measure acetabular offset, true and functional femoral offset, and femoral neck anteversion. Observer agreements were calculated using intraclass correlation. Hip measurements were compared in each patient and between pre- and postoperative measurements.

Results: Preoperatively, acetabular offset (2.4 mm), true (2.2 mm), and functional global offset (2.7 mm) were significantly larger on the osteoarthritic side without side-to-side differences for true and functional femoral offset or femoral neck anteversion. Postoperatively, acetabular offset was significantly smaller on the operated side (2.1 mm) with a concomitantly increased true (2.5 mm) and functional femoral offset (1.5 mm), resulting in symmetric true and functional global offsets. There were no differences in postoperative femoral neck anteversion. Inter- and intraobserver agreements were near-perfect, ranging between 0.92 and 0.98 with narrow confidence intervals (0.77–0.98 to 0.94–0.99).

Conclusion: Acetabular and concomitantly global offset are generally increased in hip osteoarthritis. Postoperative acetabular offset was reduced, and femoral offset increased to maintain global offset. 3D measurements were reproducible with near-perfect observer agreements. 3D data sets should be used for pre- and postoperative measurements in hip arthroplasty.

Keywords

Hip arthroplasty, femoral neck anteversion, femoral offset, acetabular offset, proximal femoral symmetry, 3D-measurements

Received 2 September 2020; accepted 15 September 2020

Introduction

In total hip arthroplasty (THA), restoration of anatomy and seeking for a correct biomechanical situation is crucial for function.^{1–4} Global offset (GO; the sum of acetabular offset (AO) and femoral offset (FO)) and femoral neck anteversion (FNA) are measurements that may be used to evaluate postoperative outcome regarding implant position and degree of restored anatomy in THA. Imbalance in GO may lead to limping.

¹Department of Radiology, University of Gothenburg, Gothenburg, Sweden

²Department of Radiology, Sahlgrenska University Hospital, Gothenburg, Sweden

³Department of Clinical Sciences, Lund University, Lund, Sweden

⁴Department of Orthopedics, Clinical Sciences, Lund University and Skåne University Hospital, Lund, Sweden

Corresponding author:

Mats Geijer, Department of Radiology, Sahlgrenska University Hospital, Bruna Stråket 11 b, Plan 02, S-41345 Gothenburg, Sweden.
Email: mats.geijer@gu.se



Reduced FO may increase acetabular polyethylene wear.⁵ FNA below 10° appears deleterious to the long-term outcome for cemented stems.⁶

To make as good anatomical restoration and biomechanical situation as possible during THA, it is common to make a preoperative plan on conventional radiographs, so-called templating, to know what implant to use and in what position to insert it. If the affected side, planned for surgery, is too deformed, the planning can be made on the contralateral, hopefully, more normal side. The goal of surgery is to deepen the acetabular socket and reduce the AO to make room for the acetabular component and, at the same time, increase FO to keep GO constant. Asymmetry of the different elements or measurements of the hip joints may, however, render the contralateral hip unsuitable to use for templating, and several articles have reported significant asymmetry of different measurements.⁷⁻⁹ Contrarily, a high degree of hip joint symmetry has also been reported.^{10,11}

FO is traditionally measured on anteroposterior (AP) pelvic radiographs,¹² where several methods of measurement exist.^{12,13} It has been shown that measurements on AP pelvic radiographs (here called functional FO) underestimate the true FO^{14,15} (Fig. 1) and that it is influenced by hip rotation¹⁶ and flexion.¹⁷ The need for more exact measurement techniques has been suggested for more exact templating methods and navigational assistance¹⁸ at surgery. 3D measurements using CT have provided measurements with high reproducibility.¹⁹

Measurements of FNA have traditionally been done using conventional radiographs with various methods,²⁰⁻²² which has been seen as sufficiently exact to provide measurements for manual templating and manual orientation of the implants. Calculations in three dimensions (3D)²³ have provided more precise

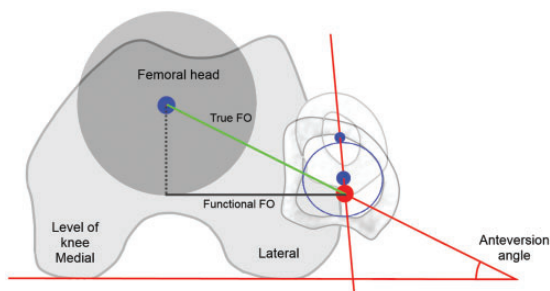


Fig. 1. Illustration of the true femoral offset (TFO), which is the true perpendicular distance from the proximal femoral long axis and the rotational center of the femoral head, and the functional femoral offset (FFO), which is the horizontal distance from the proximal femoral long axis and the rotational center of the femoral head.

FO: femoral offset.

measurements. Initial CT measurements of FNA differed considerably from measurements done on radiographs,²⁴ and different CT measuring methods gave widely different results.^{25,26} It has been shown that FNA measurements are dependent on the positioning of the femur for radiographic analysis as well as for two-dimensional CT analysis.²⁷ Measurements performed using 3D data sets have shown high consistency for both intra- and interobserver agreements.²⁸

The current study aimed to evaluate pre- and postoperative proximal femoral symmetry by semi-automated 3D CT measurements of FNA and the different offsets in a cohort scheduled for THA. A secondary aim was to validate the software measurements by inter- and intraobserver agreement calculations.

Material and Methods

Patients

The Regional Ethical Review Board approved the study (2009/369). The current cohort was based on a clinical study, reported elsewhere.²⁹ In that study, 75 patients were recruited for THA after informed consent and operated with the uncemented ABG II prosthesis (Stryker Orthopedics, Mahwah, NJ, USA). Due to incomplete imaging for various reasons, there were missing data for two patients preoperatively and two other patients postoperatively. For 71 patients with complete pre- and postoperative CT (45 males, 26 females), mean age was 59.1 years (SD 8.1 years).

CT examinations

Pre- and postoperative imaging included CT of the hips and knees for 3D assessment of AO, true and functional FO, and FNA. CT was performed on a multidetector helical Brilliance 64 CT scanner (Philips, Eindhoven, The Netherlands). Low-dose settings were used for the preoperative study (hips, CTDIvol by volume (CTDIvol) 4.8; knees, 4.2) and slightly higher dose settings for the postoperative study to compensate for the implant (hips, CTDIvol 16.4; knees, unchanged).³⁰ Helical CT was performed from the mid-pelvis, including the anterior superior iliac spine to about 6 cm distal to the lesser trochanter, and from directly proximal to the femoral condyles to directly distal to the knee joint. Postoperative imaging covered the same area. Images were archived in the local picture archiving and communication system.

Image evaluation—3D assessments

The pre- and postoperative 3D-CT examinations were evaluated using a CT-based 3D templating software (Ortoma PlanTM, Ortoma AB, Gothenburg, Sweden),

giving measurements for AO, true and functional FO, and FNA. The templating software assigned the pelvis and knees CT scan volumes to a combined 3D volume. Thick slab multiplanar reformations (MPRs) were provided in the orthogonal planes by the software (Fig. 2). The pelvis volume was rotated to the anterior pelvic plane³¹ by first defining the bi-ischial line as a horizontal line between the inferior points of the ischial tuberosities or the teardrops on an AP thick slab MPR, secondly the sagittal plane as perpendicular to a line drawn between the anterior superior iliac spines on an axial reconstruction, and thirdly the anterior pelvic plane as a line between the anterior superior iliac spines and the anterior point of the symphysis pubis on a lateral reconstruction. The reconstructed volume was stepwise automatically rotated to the described planes.

The long axis of the proximal femur was defined by assigning best-fit spheres on the AP MPR at the level of the distal border of the lesser trochanter in the CT volume (Figs 2 and 3(a), point i), touching the inner surface of the medial and lateral cortices, and one in the proximal femur about 6 cm distal to the first, proximal to any visible bowing (Fig. 3(a), point ii). The position of the spheres was then adjusted on the lateral and axial views. The rotational center of the femoral head was defined by assigning a best-fit circle on all three thick slab MPRs (Fig. 3(a), point iii). The condylar line of the knee was found by assigning a line tangential to the posterior subchondral joint surface of both femoral condyles (Fig. 3). Both points were then adjusted in the craniocaudal direction on the lateral view to the most dorsal point of the femoral condyles. The condylar plane was defined by the condylar line and the intersection on the long axis for true FO

(Fig. 3(a), point iv). A central point in the knee was found at the midpoint of a line drawn between the lateral and medial femoral epicondyle, with the point adjusted in height to the same level as the posterior condylar line. The software then calculated the respective measurements.

AO was defined as the distance from the midline of the symphysis pubis to the rotational center of the femoral head. True FO was defined as the perpendicular distance from the long axis of the proximal femur to the rotational center of the femoral head measured in 3D¹² (Fig. 1). Functional FO was defined as the

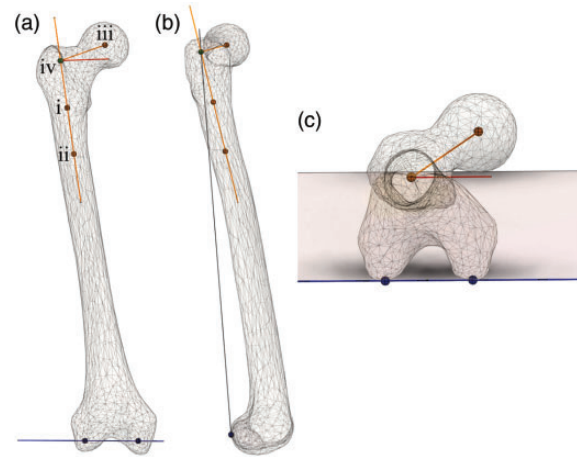


Fig. 3. Schematic 3D illustration of the definition of femoral neck anteversion (FNA) in the current study. The long axis of the femur is defined by two points in the proximal femur: (i) at the inferior border of the lesser trochanter and (ii) at a point about 6 cm distal in the femoral shaft. The FNA is the angle between a perpendicular line between the proximal femoral long axis and (iii) the femoral head and a line between the femoral condyles.

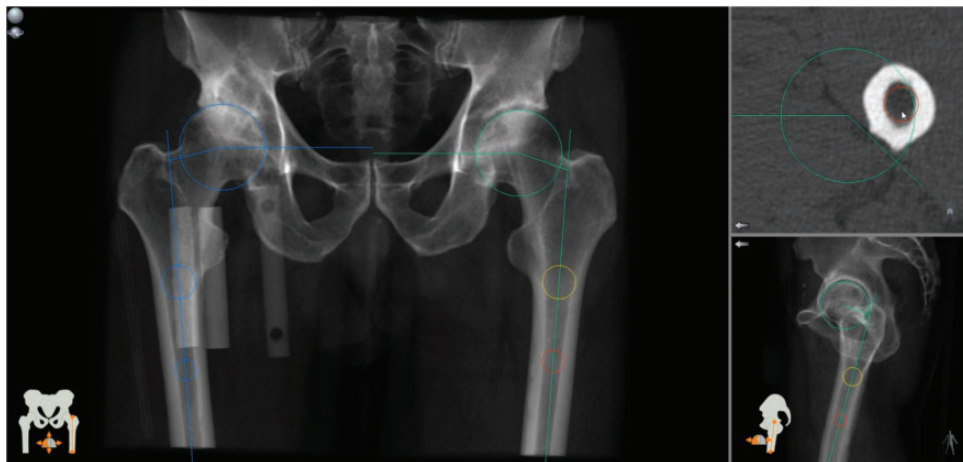


Fig. 2. Screen capture showing the best-fit circles defining the femoral head, the definition of the long axis of the proximal femur, acetabular offset, and femoral offset (FO). Functional FO was measured on the coronal reformation, true FO was measured in three dimensions. The external objects at the right hip are bone density phantoms.

perpendicular distance from the long axis of the proximal femur to the rotational center of the femoral head on the coronal MPR, i.e. not taking into account the shortening of the offset due to the FNA, rotation, or flexion of the femur, corresponding to the “classical” FO as measured on conventional radiographs.³² FNA was defined as the angle (Fig. 3(c)) between the true FO line and the condylar plane.

Side-to-side comparisons of AO, true and functional FO, and FNA between the non-affected and the osteoarthritic sides were performed on all patients. Postoperatively, the same measurements were repeated to evaluate the surgical outcome.

The measurement technique was validated by performing an interobserver agreement analysis on all pre- and postoperative measurements. For interobserver agreement measurements, two observers (MG and SK) performed the above-mentioned measurements on 71 pairs of hips on all pre- and postoperative studies, 284 measurements per observer. For intraobserver measurements, both observers repeated the measurements on both hips on the pre- and postoperative CT of 15 randomly selected patients after about two months; 60 measurements per observer.

Statistics

Continuous data are expressed as means and standard deviation. Qualitative data are expressed as frequency and percentage. Observer agreement was analyzed with intraclass correlation (ICC) with 95% confidence intervals (CI). The strength of observer agreement was translated according to definitions proposed by Landis and Koch for kappa values,³³ as 0.00–0.20, slight; 0.21–0.40, fair; 0.41–0.60, moderate; 0.61–0.80, substantial; and 0.81–1.00, almost perfect. Furthermore, Lee et al.³⁴ stated that the lower 95% CI should be above 0.75 for an agreement to exist. The software package R version 3.5.3 was used for statistical computations.³⁵

Results

Preoperatively, there was a significantly larger AO on the osteoarthritic side of 2.5 mm (95% CI: 1.97–2.95), resulting in correspondingly larger true and functional GO of 2.2 (CI: 1.52–2.88) and 2.6 mm (CI: 1.83–3.47), respectively. There were no significant differences in preoperative true or functional FO or FNA between the non-affected and the osteoarthritic sides (Table 1, Fig. 4).

Postoperatively, there was a significantly smaller AO on the operated side (–2.0 mm, CI: –2.58 to –1.52) with a concomitantly increased true FO (2.5 mm, CI: 1.82–3.10) and functional FO (1.4 mm, CI: 0.47–2.24)

Table 1. Preoperative differences between non-arthritic and osteoarthritic hips in 71 patients. Combined data for two observers.

	Mean	95% CI
Femoral anteversion angle (degrees)	–0.86	–2.14 to 0.42
Acetabular offset (mm)	2.46	1.97 to 2.95
True femoral offset (mm)	–0.26	–0.76 to 0.25
True global offset (mm)	2.20	1.52 to 2.88
Functional femoral offset (mm)	0.19	–0.53 to 0.91
Functional global offset (mm)	2.65	1.83 to 3.47

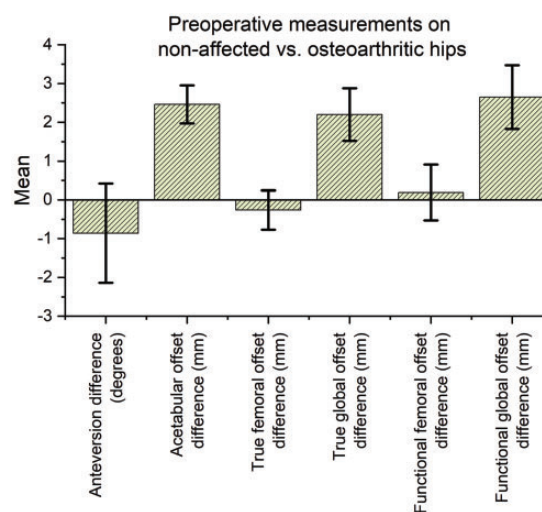


Fig. 4. Bar chart showing the differences in measurements between the non-affected side and the side planned for total hip arthroplasty for femoral neck anteversion, acetabular offset, true femoral offset, true global offset, functional femoral offset, and functional global offset. Data for the two observers combined.

(Table 2, Fig. 5). This resulted in symmetry for both true GO and functional GO, without significant side-to-side differences. There were no significant side-to-side differences in FNA.

Observer agreements measured by ICC for the two observers were high. Observer agreement for 213 native hips, i.e. 71 pairs of hips on the preoperative CT and the 71 non-operated hips on the postoperative examination, was good with almost perfect ICC scores and narrow CI (Table 3). Observer agreement for the 71 operated hips was equally good with almost perfect ICC scores and narrow CI (Table 3), without differences between pre- and postoperative results. Thus, the results showed no increased difficulty in measuring on postoperative hip examinations. Intraobserver agreements were almost perfect for both observers, with narrow CI (Table 4).

Measurements for pre- and postoperative CT of the non-operated hips were compared to evaluate the

Table 2. Postoperative differences between non-arthritic and osteoarthritic hips in 71 patients. Combined data for two observers.

	Mean	95% CI
Femoral anteversion angle (degrees)	0.52	-1.65 to 2.68
Acetabular offset (mm)	-2.05	-2.58 to -1.52
True femoral offset (mm)	2.46	1.82 to 3.10
True global offset (mm)	0.41	-0.29 to 1.10
Functional femoral offset (mm)	1.35	0.47 to 2.24
Functional global offset (mm)	-0.70	-1.61 to 0.26

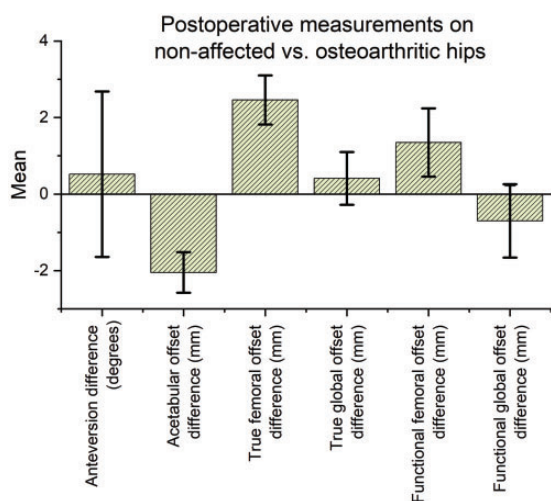


Fig. 5. Bar chart showing the differences in measurements between the non-affected side and the postoperative values for the operated side for femoral neck anteversion, acetabular offset, true femoral offset, true global offset, functional femoral offset, and functional global offset. Data for the two observers combined.

robustness of the method, i.e. to determine whether repeated CT examinations and measurements on the same hip would yield comparable results. The ICC scores were almost perfect for both observers, with narrow CI (Table 5), and linear regression analyses showed a significant correlation for AO, true and functional FO, and FNA ($p < 0.001$; Fig. 6).

Discussion

In the current study, measurements of AO, true GO, and functional GO showed expected results with significant side-to-side differences between the non-affected and the osteoarthritic hips. Postoperatively, AO had been reduced with normalization of true GO and functional GO. The inter- and intraobserver agreements in measuring AO, true FO, functional FO, and FNA with a new hip arthroplasty templating software

Table 3. Interobserver agreement assessed with intraclass correlation (ICC) for measurements of acetabular, femoral anteversion angle, true and functional femoral offset, and true and functional global offset on 213 non-operated hips and 71 operated hips in 71 patients.

Type	Measurement	ICC	95% CI
213 non-operated hips	Acetabular offset	0.94	0.88–0.96
	Femoral anteversion angle	0.93	0.90–0.95
	True femoral offset	0.94	0.92–0.96
	True global offset	0.97	0.96–0.98
	Functional femoral offset	0.96	0.94–0.97
	Functional global offset	0.97	0.97–0.98
71 operated hips	Acetabular offset	0.97	0.96–0.98
	Femoral anteversion angle	0.95	0.93–0.97
	True femoral offset	0.96	0.94–0.98
	True global offset	0.98	0.96–0.98
	Functional femoral offset	0.97	0.95–0.98
	Functional global offset	0.98	0.96–0.98

were generally near-perfect with narrow CI. Measurements on repeated CT examinations were close to identical.

Offset measurements have traditionally been done on AP pelvis or hip radiographs,¹² where femoral rotation¹⁶ and flexion¹⁷ have been shown to influence measurements. In the current study, also true FO was measured, which is the perpendicular distance from the long axis of the femur to the center of the femoral head, measured in 3D. This measurement is always longer than the AP measurement of functional FO and nonaffected by patient positioning.

Measurements of FNA differ between studies, depending on how the measurements were made. Distally, four different methods may be used to define the femoral condylar axis; a line drawn between the most posterior points of the condyles, a line drawn between the most medial and lateral points on the condyles, a line drawn between the center of the centroids of the condyles in cross-section,³⁶ or a line bisecting a line through the most posterior points of the femoral condyles and a line through the most anterior points of the distal femur in the same section.³⁷ In the current study, the most posterior points of the femoral condyles were used to define the condylar line.

The method for measurements of FNA used in the current analysis is not identical to the definition by Billing.³⁸ Billing defined anteversion based on the long axis of the femur as defined by a point centrally in the distal femur. In the current study, anteversion was measured relative to the long axis of the femur proximally, to better correspond to the true insertion

Table 4. Intraobserver agreement assessed by intraclass correlation coefficient (ICC) in pre- and postoperative computed tomography in 15 patients, i.e. totally 45 non-operated and 15 operated hips.

Type	Measurement	ICC	95 % CI
Observer 1, 45 non-operated hips	Acetabular offset	0.94	0.90–0.97
	Femoral anteversion angle	0.97	0.95–0.98
	True femoral offset	0.97	0.94–0.98
	Functional femoral offset	0.98	0.96–0.99
15 operated hips	Acetabular offset	0.99	0.97–1.00
	Femoral anteversion angle	0.95	0.85–0.98
	True femoral offset	0.93	0.81–0.98
	Functional femoral offset	0.96	0.88–0.98
All 60 hips	Acetabular offset	0.97	0.93–0.98
	Femoral anteversion angle	0.97	0.95–0.98
	True femoral offset	0.96	0.94–0.98
	Functional femoral offset	0.97	0.96–0.98
Observer 2, 45 non-operated hips	Acetabular offset	0.96	0.93–0.98
	Femoral anteversion angle	0.94	0.90–0.97
	True femoral offset	0.93	0.87–0.96
	Functional femoral offset	0.96	0.93–0.98
15 operated hips	Acetabular offset	0.97	0.92–0.99
	Femoral anteversion angle	0.95	0.85–0.98
	True femoral offset	0.92	0.77–0.97
	Functional femoral offset	0.98	0.95–0.99
All 60 hips	Acetabular offset	0.97	0.94–0.98
	Femoral anteversion angle	0.95	0.91–0.97
	True femoral offset	0.93	0.87–0.96
	Functional femoral offset	0.96	0.94–0.98

Table 5. Comparison of pre- and postoperative assessments in 71 non-operated hips by two observers by intraclass correlation coefficient (ICC).

Type	Measurement	ICC	95% CI
Observer 1, 71 non-operated hips pre- vs. postoperative examination	Acetabular offset	0.94	0.91–0.96
	Femoral anteversion angle	0.93	0.84–0.96
	True femoral offset	0.96	0.93–0.97
	True global offset	0.99	0.98–0.99
	Functional femoral offset	0.97	0.95–0.98
Observer 2, 71 non-operated hips pre- vs. postoperative examination	Functional global offset	0.98	0.97–0.99
	Acetabular offset	0.94	0.91–0.96
	Femoral anteversion angle	0.92	0.88–0.95
	True femoral offset	0.93	0.89–0.96
	True global offset	0.97	0.96–0.98
	Functional femoral offset	0.94	0.90–0.97
	Functional global offset	0.97	0.94–0.98

site and final position of a femoral prosthetic stem, and not having to compensate for the physiological bowing of the femoral shaft at templating. The proximal point for defining the long axis of the femur has also been defined in different ways. Billing, despite a detailed description of the geometry of the femur and the definition of FNA,³⁸ did not define this point.

Murphy et al.²⁵ defined it as “a centroid of a cross section of the femur at the base of the femoral neck” on an axial CT section “3 per cent” distal to the middle of the lesser trochanter. In the current study, the condylar plane was defined by the condylar line and the intersection of the proximal long axis line and the line for the true FO measurement.

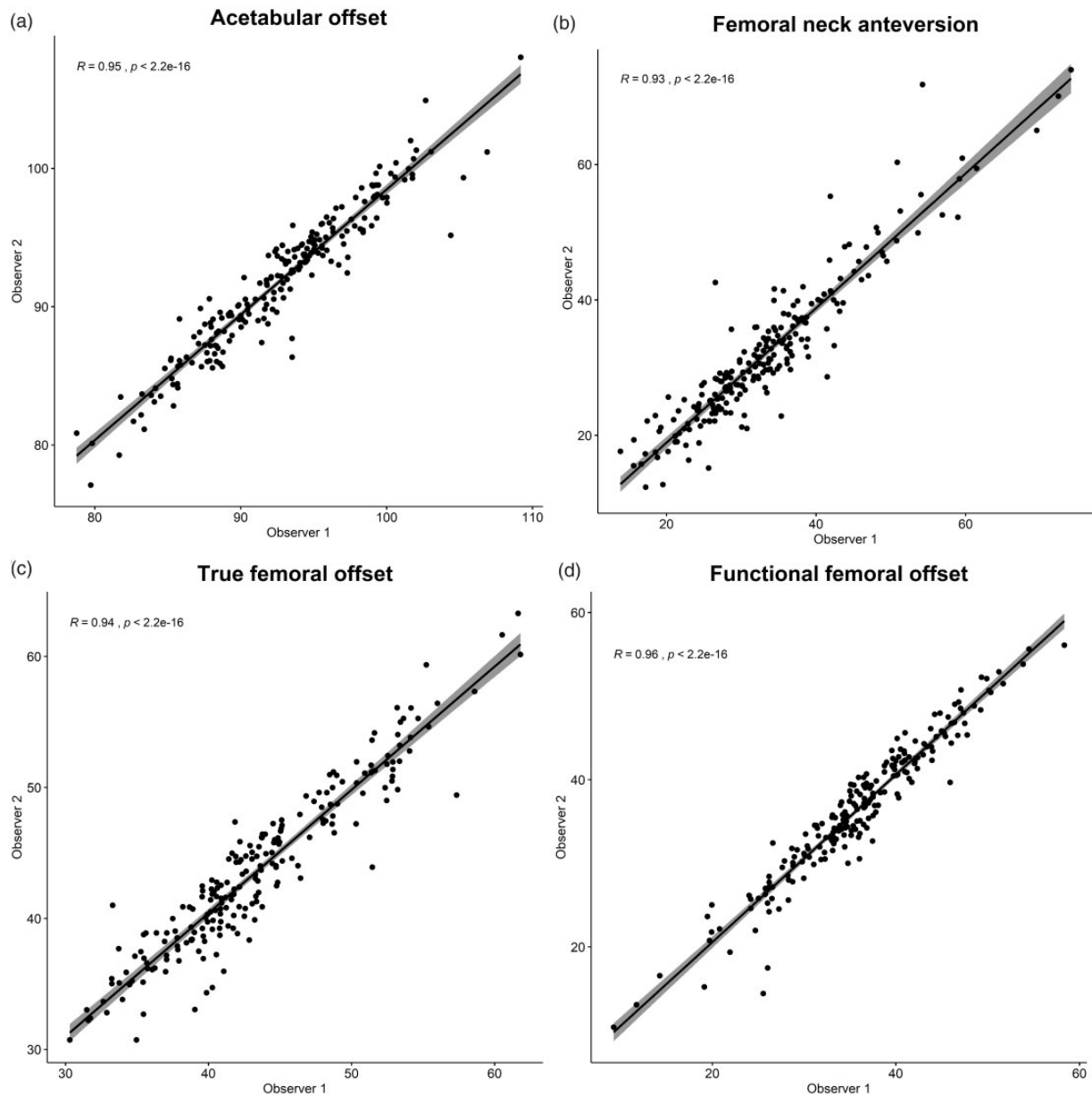


Fig. 6. Correlation plots for measurements of acetabular offset, femoral neck anteversion, true and functional femoral offset for two observers in 213 non-operated hips.

When using conventional CT images, measurements are improved if the sections are corrected for hip and knee flexion as well as adduction of the hip.³⁹ This has up until recently been problematic and one reason why previous comparisons of radiography and CT measurements of FNA have not shown superiority for CT.²⁷

Since previous studies have used slightly different techniques and measuring points for FNA, the comparison of measurements between studies is difficult (Fig. 7). The most crucial issue, however, is to develop a measuring method with high reproducibility and low observer variation such as in the current study.

The high observer agreement rates are consistent with other studies reporting on CT assessment of measurements using 3D images. In one study, reporting on FNA in children using CT and MRI,²⁸ ICC values were also near-perfect with narrow CI. In another study measuring FNA directly on 3D reconstructions,⁴⁰ ICC values were high but slightly lower than in the current study. In the current study, CT was performed using a low-dose technique,³⁰ with an effective dose close to that of radiography,³⁰ showing that even with increased image noise, excellent results can be achieved. The results from the current study further

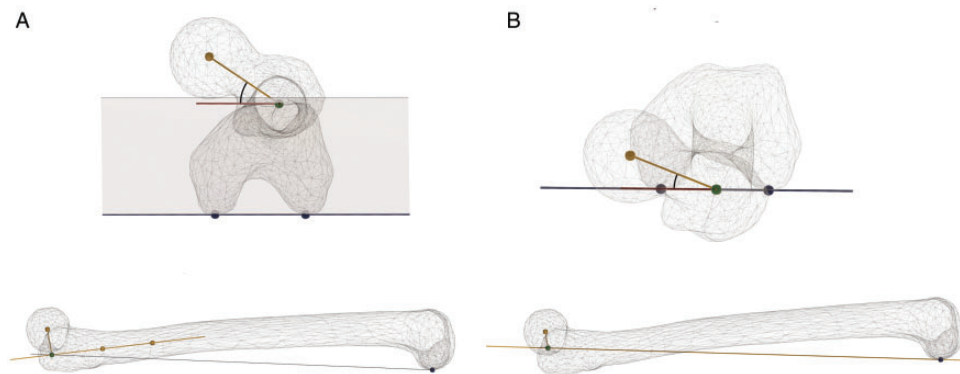


Fig. 7. Femoral neck anteversion (FNA) is different depending on the choice of long axis of the femur. (a) In the current study, the proximal part of the femur was chosen for the long axis definition since that corresponds to the length of the femoral stem in hip arthroplasty. FNA is 35°. (b) In previous definitions, e.g. by Billing³⁸ and Murphy et al.,²⁵ the long axis was defined by a point in the knees and a point in the proximal femur, giving a different measurement value of FNA, 20°.

support the use of 3D data sets. With the use of 3D data sets, the need for exact patient positioning is practically eliminated.

Various levels of symmetry in normal (non-arthritic) populations have previously been reported regarding femoral hip orientation measurements, seemingly dependent on the evaluated populations. Previously, an asymmetry > 2% has been reported for the femoral neck-shaft angle, FO, FNA, femoral length, and femoral head radius⁸ with substantial differences reported for FNA, FO, and femoral head center location,⁷ all being important measurements for contralateral templating of THA. On the other hand, another study, using high-resolution photographs on cadaveric specimens, reported no significant side-to-side differences for proximal femoral measurements of the femoral head diameter, the minimal neck diameter, and the femoral shaft diameter.¹⁰

In osteoarthritic hips, reactive bone formation in the acetabular socket often leads to an increase in AO but does not affect FO or FNA. The surgical aim in the current study was to decrease AO with a compensatory increase in FO to restore symmetry in GO. Increasing FO has been suggested to improve abductor strength, reduce limping, and counteract polyethylene wear.⁴¹ In the current study GO symmetry was achieved according to this principle.

The limitation of the study is mainly the small number of observers. However, the high ICC and narrow CI showed high inter- and intraobserver agreements. There was no reference standard for the measurements, but due to the use of different reference points for measurements in the literature, this was impossible to find.

In conclusion, using low-dose CT with 3D measurements with a templating software yielded excellent

repeatability of measurements with near-perfect observer agreement. The study supports the use of 3D data sets for measurements in the pre- and postoperative evaluation in THA.

Acknowledgments

We thank Tomasz Czuba, RC Syd, Department of Research and Education, Lund University for statistical assistance.

Declaration of Conflicting Interests

The author(s) declared the following potential conflicts of interest with respect to the research, authorship, and/or publication of this article: Mats Geijer, Sverrir Kiernan and Gunnar Flivik have served as advisory consultants for Ortoma AB during software development.

Funding

The author(s) received no financial support for the research, authorship, and/or publication of this article.

ORCID iD

Mats Geijer  <https://orcid.org/0000-0003-0529-7723>

References

1. Cassidy KA, Noticewala MS, Macaulay W, et al. Effect of femoral offset on pain and function after total hip arthroplasty. *J Arthroplasty* 2012;27:1863–1869.
2. Iversen MD, Chudasama N, Losina E, et al. Influence of self-reported limb length discrepancy on function and satisfaction 6 years after total hip replacement. *J Geriatr Phys Ther* 2011;34:148–152.
3. Rösler J, Perka C. The effect of anatomical positional relationships on kinetic parameters after total hip replacement. *Int Orthop* 2000;24:23–27.

4. Terrier A, Levrero Florencio F, Rüdiger HA. Benefit of cup medialization in total hip arthroplasty is associated with femoral anatomy. *Clin Orthop* 2014;472:3159–3165.
5. Little NJ, Busch CA, Gallagher JA, et al. Acetabular polyethylene wear and acetabular inclination and femoral offset. *Clin Orthop* 2009;467:2895–2900.
6. Kiernan S, Hermann KL, Wagner P, et al. The importance of adequate stem anteversion for rotational stability in cemented total hip replacement: a radiostereometric study with ten-year follow-up. *Bone Joint J* 2013;95-B:23–30.
7. Dimitriou D, Tsai T-Y, Yue B, et al. Side-to-side variation in normal femoral morphology: 3D CT analysis of 122 femurs. *Orthop Traumatol Surg Res OTSR* 2016;102:91–97.
8. Laumonerie P, Ollivier M, LiArno S, et al. Which factors influence proximal femoral asymmetry?: a 3D CT analysis of 345 femoral pairs. *Bone Jt J* 2018;100-B:839–844.
9. Croom WP, Lorenzana DJ, Auran RL, et al. Is contralateral templating reliable for establishing rotational alignment during intramedullary stabilization of femoral shaft fractures? A study of individual bilateral differences in femoral version. *J Orthop Trauma* 2018;32:61–66.
10. Young EY, Gebhart J, Cooperman D, et al. Are the left and right proximal femurs symmetric? *Clin Orthop* 2013;471:1593–1601.
11. Reikerås O, Høiseth A, Reigstad A, et al. Femoral neck angles: a specimen study with special regard to bilateral differences. *Acta Orthop Scand* 1982;53:775–779.
12. Lecerf G, Fessy MH, Philippot R, et al. Femoral offset: anatomical concept, definition, assessment, implications for preoperative templating and hip arthroplasty. *Orthop Traumatol Surg Res OTSR* 2009;95:210–219.
13. Kjellberg M, Englund E, Sayed-Noor AS. A new radiographic method of measuring femoral offset. The Sundsvall method. *Hip Int J Clin Exp Res Hip Pathol Ther* 2009;19:377–381.
14. Merle C, Waldstein W, Pegg E, et al. Femoral offset is underestimated on anteroposterior radiographs of the pelvis but accurately assessed on anteroposterior radiographs of the hip. *J Bone Joint Surg Br* 2012;94:477–482.
15. Weber M, Woerner ML, Springorum H-R, et al. Plain radiographs fail to reflect femoral offset in total hip arthroplasty. *J Arthroplasty* 2014;29:1661–1665.
16. Lechler P, Frink M, Gulati A, et al. The influence of hip rotation on femoral offset in plain radiographs. *Acta Orthop* 2014;85:389–395.
17. O'Connor JD, Rutherford M, Hill JC, et al. Effect of combined flexion and external rotation on measurements of the proximal femur from anteroposterior pelvic radiographs. *Orthop Traumatol Surg Res OTSR* 2018;104:449–454.
18. Beckmann J, Stengel D, Tingart M, et al. Navigated cup implantation in hip arthroplasty. *Acta Orthop* 2009;80:538–544.
19. Sariali E, Mouttet A, Pasquier G, et al. Three-dimensional hip anatomy in osteoarthritis. Analysis of the femoral offset. *J Arthroplasty* 2009;24:990–997.
20. Dunn DM. Anteversion of the neck of the femur; a method of measurement. *J Bone Joint Surg Br* 1952;34-B:181–186.
21. Magilligan DJ. Calculation of the angle of anteversion by means of horizontal lateral roentgenography. *J Bone Joint Surg Am* 1956;38-A:1231–1246.
22. Ogata K, Goldsand EM. A simple biplanar method of measuring femoral anteversion and neck-shaft angle. *J Bone Joint Surg Am* 1979;61:846–851.
23. Hermann KL, Egund N. Measuring anteversion in the femoral neck from routine radiographs. *Acta Radiol Stockh Swed* 1998;39:410–415.
24. Ruby L, Mital MA, O'Connor J, et al. Anteversion of the femoral neck. *J Bone Joint Surg Am* 1979;61:46–51.
25. Murphy SB, Simon SR, Kijewski PK, et al. Femoral anteversion. *J Bone Joint Surg Am* 1987;69:1169–1176.
26. Sugano N, Noble PC, Kamaric E. A comparison of alternative methods of measuring femoral anteversion. *J Comput Assist Tomogr* 1998;22:610–614.
27. Hermann KL, Egund N. CT measurement of anteversion in the femoral neck. The influence of femur positioning. *Acta Radiol Stockh Swed* 1997;38:527–532.
28. Mao C, Liang Y, Ding C, et al. The consistency between measurements of the femoral neck anteversion angle in DDH on three-dimensional CT and MRI. *Acta Radiol Stockh Swed* 2016;57:716–720.
29. Kiernan S, Geijer M, Sundberg M, et al. Effect of symmetrical restoration for the migration of uncemented total hip arthroplasty: a randomized RSA study with 75 patients and 5-year follow-up. *J Orthop Surg* 2020;15:225.
30. Geijer M, Rundgren G, Weber L, et al. Effective dose in low-dose CT compared with radiography for templating of total hip arthroplasty. *Acta Radiol Stockh Swed* 2017;58:1276–1282.
31. Hausselle J, Moreau PE, Wessely L, et al. Intra- and extra-articular planes of reference for use in total hip arthroplasty: a preliminary study. *Int Orthop* 2012;36:1567–1573.
32. Houcke JV, Khanduja V, Pattyn C, et al. The history of biomechanics in total hip arthroplasty. *Indian J Orthop* 2017;51:359–367.
33. Landis JR, Koch GG. The measurement of observer agreement for categorical data. *Biometrics* 1977;33:159–174.
34. Lee J, Koh D, Ong CN. Statistical evaluation of agreement between two methods for measuring a quantitative variable. *Comput Biol Med* 1989;19:61–70.
35. “R Core Team.” R: A language and environment for statistical computing. R Foundation for Statistical Computing, Vienna, Austria, www.R-project.org/ (2017, accessed 25 September 2020).
36. Weiner DS, Cook AJ, Hoyt WA, et al. Computed tomography in the measurement of femoral anteversion. *Orthopedics* 1978;1:299–306.

37. Hernandez RJ, Tachdjian MO, Poznanski AK, et al. CT determination of femoral torsion. *AJR Am J Roentgenol* 1981;137:97–101.
38. Billing L. Roentgen examination of the proximal femur end in children and adolescents; a standardized technique also suitable for determination of the collum-, anteversion-, and epiphyseal angles; a study of slipped epiphysis and coxa plana. *Acta Radiol Suppl* 1954;110:1–80.
39. Olesen TH, Torfing T, Overgaard S. MPR realignment increases accuracy when measuring femoral neck anteversion angle. *Skeletal Radiol* 2013;42:1119–1125.
40. Byun HY, Shin H, Lee ES, et al. The availability of radiological measurement of femoral anteversion angle: three-dimensional computed tomography reconstruction. *Ann Rehabil Med* 2016;40:237–243.
41. De Fine M, Romagnoli M, Toscano A, et al. Is there a role for femoral offset restoration during total hip arthroplasty? A systematic review. *Orthop Traumatol Surg Res* 2017;103:349–355.