




Case Report

Arteriovenous fistula of the filum terminale masqueraded as a failed back surgery syndrome – A case report and review of literature

Nuno Cubas Farinha¹, Joaquim Cruz Teixeira², José Hipólito Reis¹, Domingos Coiteiro¹

¹Department of Neurosurgery, Centro Hospitalar Universitário Lisboa Norte EPE, Avenida Professor Egas Moniz, ²Department of Neurosurgery, CUF Infante Santo Hospital, Travessa do Castro, Lisbon, Portugal.

E-mail: *Nuno Cubas Farinha - nuno.cubas.farinha@gmail.com; Joaquim Cruz Teixeira - joaquimcruzteixeira@hotmail.com; José Hipólito Reis - josehipolitoreis@gmail.com; Domingos Coiteiro - dcoiteiro@gmail.com



*Corresponding author:

Nuno Cubas Farinha,
Department of Neurosurgery,
Centro Hospitalar Universitário
Lisboa Norte EPE, Avenida
Professor Egas Moniz, Lisbon,
Lisbon, Portugal.

nuno.cubas.farinha@gmail.com

Received : 17 September 2020

Accepted : 15 January 2021

Published : 10 February 2021

DOI

10.25259/SNI_651_2020

Quick Response Code:



ABSTRACT

Background: The filum terminale arteriovenous fistulas (FTAVFs) are a very rare type of spinal vascular malformation. Clinically, these lesions could present with a progressive ascending myelopathy also called Foix-Alajouanine syndrome. Due to the rarity of these vascular malformation, some can be misdiagnosed, submitted to unnecessary spinal surgery, and even masqueraded as a failed back surgery syndrome. Based on the present case and related literature, we review all the cases with similar history and describe factors that should raise awareness for diagnosis of this spinal vascular malformation.

Case Description: We present a case of a patient with a FTAVF at the level of L5-S1 that presented with a Foix-Alajouanine syndrome. He had been previously submitted to a lumbar decompressive laminectomy without sustained improvement. After the identification and surgical treatment of the vascular malformation, he had progressive neurological improvement.

Conclusion: FTAVF is a very rare spinal intradural spinal vascular malformation that can be masqueraded as a failed back surgery syndrome. In these cases, signs of ascending myelopathy should prompt awareness and vascular voids must be carefully evaluated in MRI.

Keywords: Failed back surgery syndrome, Filum terminale, Microsurgery, Myelopathy, Spinal arteriovenous fistula

INTRODUCTION

The filum terminale arteriovenous fistulas (FTAVFs) are a very rare type of spinal vascular malformation accounting for approximately 3% of cases.^[2,6,9,22] They are generally characterized by a single direct shunt between the artery of the filum terminale (distal prolongation of anterior spinal artery [ASA]) and a draining vein.^[6,9,24,27] These lesions cause a congestive myelopathy and progressive spinal cord ischemia due to spinal cord venous congestion, vascular hypertension, and a putative chronic steal phenomenon.^[6,14,24] Clinically, these lesions could present with a progressive ascending myelopathy also called Foix-Alajouanine syndrome.^[3,6,9,14,16] This syndrome can encompass motor weakness, sensory disturbances, back pain, sphincter disturbances, and sexual dysfunction.^[3,6,14,16,18] Due to the rarity of FTAVF and the nonspecific clinical

This is an open-access article distributed under the terms of the Creative Commons Attribution-Non Commercial-Share Alike 4.0 License, which allows others to remix, tweak, and build upon the work non-commercially, as long as the author is credited and the new creations are licensed under the identical terms.

©2020 Published by Scientific Scholar on behalf of Surgical Neurology International

manifestations, some of these cases have been misdiagnosed, undergone lumbosacral surgery, and subsequently, labeled as failed back surgery syndrome.^[10,11,14,15,25,28,29,31,32]

We describe a case of a patient with a FTAVF presented with a Foix-Alajouanine syndrome that had been previously misdiagnosed and had undergone a lumbar laminectomy for lumbar stenosis. We review all the FTAVF with similar history described in the literature. This literature search was performed on PubMed using the key words “arteriovenous fistula of the filum terminale,” “FTAVF,” “previous surgery,” “lumbosacral surgery,” and “failed back surgery syndrome.” We also describe factors that should raise awareness for diagnosis of this spinal vascular malformation.

CASE DESCRIPTION

A 73-year-old man was evaluated at the neurosurgical outpatient clinic with an 18-month history of intermittent back pain and progressive gait disturbance due to diminished strength in both legs. Seven years before, the patient had similar neurogenic claudication as main symptom and a lumbar CT scan was done solely, which showed stenosis at the L4-L5 level as the key feature. He underwent lumbar decompressive laminectomy in another institution, with transient improvement at that time.

During the following months, the symptoms slowly progressed and the patient became unable to walk without assistance. He also developed urinary sphincter disturbance with incontinence episodes. The neurological examination showed a bilateral lower extremity motor weakness with a motor strength grade 3/5 bilateral in hip flexion and extension, and a Grade 4/5 bilateral in knee extension, ankle dorsiflexion, knee flexion, great toe extension, and ankle plantar flexion. The patient also had hypoesthesia from L4 dermatome downward bilaterally, abnormally increased patellar and ankle reflexes bilaterally, and extensor plantar reflexes.

A lumbar MRI was performed, demonstrating prominent vascular voids near conus medullaris but no significant high T2 signal involving the spinal cord [Figure 1a and b]. Further evaluation was undertaken with CT angiogram and digital subtraction angiography (DSA). These examinations identified a FTAVF which was fed by the filum terminale artery that arose from the ASA and were supplied by the left D10 segmental artery [Figure 1c and d]. The patient also had an electromyographic study done that reveals chronic neurogenic changes of L3, L4, L5, and S1 bilaterally.

Therapeutic options were discussed with the patient, who decided to undergo surgery. Reopening and extension of the previous laminectomy down to S1 was performed, to expose the fistula. After durotomy, the direct connection between the artery of the filum terminale and the arterialized vein was evident, forming the arteriovenous fistula (AVF) at the

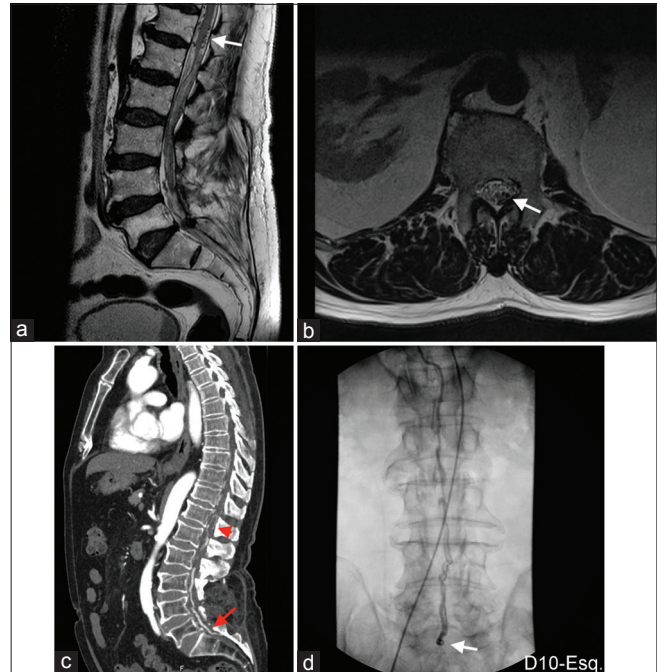

Figure 1: Preoperative images: (a) MRI T2 sagittal showing multiple vascular voids near conus medullaris (arrow). (b) MRI T2 axial revealing two hypointense structures on the left (arrow) that were confirmed to be the arterial feeder and draining vein of the filum terminale arteriovenous fistula (FTAVF) after the DSA. (c) CT angiogram showing the contrast enhancement of the FTAVF (arrow) and multiple vascular voids around the conus medullaris and lower spinal cord (arrow head). (d) Dorsolumbar DSA showing the FTAVF at L5-S1 (arrow) with a descending arterial feeder from left D10 and an ascending draining vein.

level of L5-S1 [Figure 2a]. With the aid of intraoperative neurophysiological monitoring, we confirm the filum terminale due to the absence of sensory-motor potentials on it [Figure 2b and c]. An intraoperative angiography with indocyanine green (ICG) was performed to identify the exact shunt location [Figure 2d]. After confirmation of the AVF, a clip was placed interrupting the fistulous path, followed by the observation that the draining vein was no longer arterIALIZED [Figure 3a]. This interruption was confirmed with the ICG video angiography [Figure 3b].

Surgery and immediate postoperative period were uneventful. Over the following weeks, both sensory and motor deficits, progressively improved. Ten days after surgery, the patient recovered the voluntary control of the urinary sphincter and the urinary catheter was removed. He underwent physiotherapy and was able to walk unassisted 6 months after surgery.

DISCUSSION

Spinal intradural AVFs represent a rare spinal vascular malformation category.^[25] According to Kim and Spetzler

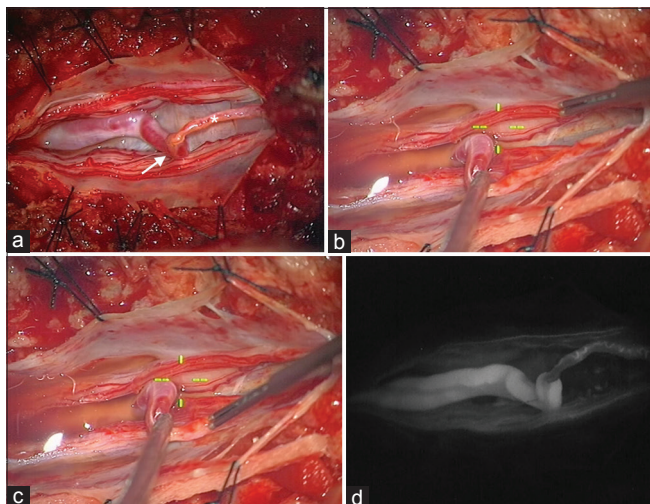


Figure 2: Intraoperative images: (a) image of the artery of the filum terminale directly connected to an arterialized vein, which corresponds to the arteriovenous fistula (arrow). The normal filum terminale (asterisk) is seen distally (left correspond to cranial and right is caudal). (b) Intraoperative neurophysiological examination testing a cauda equina root and (c) the filum terminale. (d) Intraoperative ICG video angiography confirming the exact shunt location of the filum terminale arteriovenous fistula.

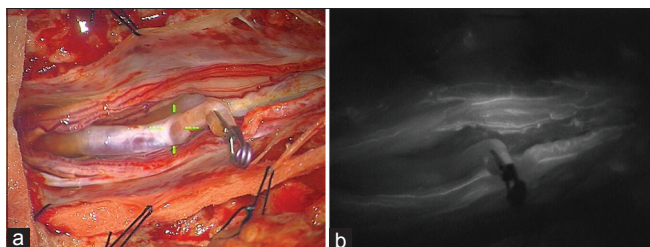


Figure 3: (a) After clip placement on the filum terminale arteriovenous fistula, the draining vein is no longer arterialized. (b) Intraoperative indocyanine green video angiography confirming the interruption of the fistulous shunt.

classification, those can be divided into dorsal and ventral intradural AVFs, being the last one further subclassified into type A, B, and C depending on their size, arterial feeders, and dilatation of draining veins.^[13] The FTAVFs are a rare type of spinal intradural AVFs, accounting for approximately 3% of spinal intradural vascular malformations.^[2,6,9,22] These are generally characterized by a single direct shunt between the artery of the filum terminale (distal prolongation of ASA) and a draining vein.^[1,3,6,8,9,12,18,29,33] Rarely, these FTAVF can have multiple shunt points.^[6,8,9] Because of its different morphology and the unique location along the filum terminale, some authors advocate that FTAVF should be classified as a distinct form of intradural arteriovenous shunt.^[6]

The etiology of FTAVFs is unknown. Some authors consider it as a congenital malformation,^[11,23] others believe that it is an

acquired lesion.^[16,31,32] Supporting the congenital nature is that some FTAVFs are associated with neural tube defects such as tethered cord,^[28] diastematomyelia,^[19] syringomyelia,^[1] hypoplastic sacrum,^[1] and spina bifida^[18] suggesting an association of these during the embryonic period. In our review, we found 20 cases associated with neural tube defects.^[5,19,28] The acquired etiology is supported by the fact that most patients are too old to consider FTAVF a congenital lesion.^[28,31,32] In fact, some consider that the neural tube defects are contributing factors for the formation of this malformation at older ages.^[28] Noteworthy that 21 of the cases reported have concomitant lumbar degenerative changes like spinal canal stenosis or lumbar disc herniation according to our review.^[2,7,8,10,14,24,25,30] It is postulated that the repetitive microtrauma and chronic inflammation within the filum terminale, caused by long-standing degenerative stenosis, can induce a positive feedback loop and eventual fistula formation.^[10,24] In the remaining cases of FTAVF reported, we found neither congenital nor acquired lesions described that can be associated with this vascular malformation. We conclude that probably FTAVFs are caused by an association of factors that can be congenital, acquired, or an aggregation of both.

FTAVFs can present with an ascending congestive myelopathy,^[3,5,16,27] as was seen in our case. Theoretically, first, there is an increased venous pressure secondary to the augmented blood flow through the fistulous shunt. This will cause a venous hypertension which is highlighted by the venous varices. Second, a prolonged steal phenomenon, driven by the chronic low-pressure shunt through the fistula, will induce a chronic arterial steal and decreased cord perfusion. The persistent venous congestion and spinal cord ischemia will induce a progressive spinal cord dysfunction.^[6] Regardless of the location of the spinal intradural AVF, it is the lower part of the cord that is commonly affected first.^[14] This phenomenon is explained by two motives: on the one hand, the intraspinal venous system is valveless, and due to gravity, the conus and lower cord are more congested; on the other hand, lower cord has physiologically less collateral vascularity.^[11]

The ascending congestive myelopathy caused by spinal AVF is also known as Foix-Alajouanine syndrome.^[11,14,16] This syndrome was initially described in 1926 by Charles Foix and Théophile Alajouanine and originally called subacute ascending necrotizing myelitis.^[4] It is clinically expressed by lower limb weakness, ascending hypoesthesia, loss of sphincter control, and areflexia or hyperreflexia.^[16] Due to the rarity of these vascular malformations, particularly FTAVF, and the low specificity of its presenting clinical manifestations, they are often misdiagnosed as polyradiculopathy, polyneuropathy, intramedullary tumor, or even masqueraded as lumbosacral degenerative disease or neural tube defects.^[11,14,15,25,26] This can lead to delayed diagnosis or unnecessary spinal surgery.^[24,25]

According to our review, there are 66 cases of FTAVF reported in the literature.^[6,10,17,24] Reviewing all FTAVF cases reported,

11 cases were submitted to previous lumbosacral surgery and subsequently masqueraded as a failed back surgery syndrome [Table 1]. Of these, 10 had lumbar degenerative pathologies and 1 had a tethered cord syndrome with a sacral lipoma (the youngest of all). Ten patients were male and one female; they had a median age of 59 years old. The average length of symptoms was 37 months. All cases presented with motor symptoms that impaired autonomous gait, hypoesthesia, and sphincter dysfunction (not stated sensory symptoms in 1 case and sphincter functionality in 2 cases). In most cases (7 cases), the reflexes were not mentioned. After the first surgery, only 3 cases had partial improvement. MRI and selective arteriography were diagnostic exams in all cases. After the treatment of FTAVF, most cases showed sustained improvement, excepting 2 cases (patient previous submitted to partial removal of sacral lipoma; patient that was submitted to unsuccessful embolization and then refused the surgery). Our case was initially misdiagnosed as lumbar stenosis, having been submitted to a decompressive laminectomy. Besides being the oldest patient reported, he meets the other clinical features. He had transient improvement after the first surgery, but sustained improvement was only verified after the FTAVF disconnection.

Like the other cases with similar history, our case highlights the importance of clinical awareness to signs such as paraparesis with gait disturbance and sphincter disturbance, in patients with previous surgery for lumbar degenerative disease. Due to the fact that these neurological signs are very rare in this type of pathology, the MRI scans must be carefully analyzed, especially the T2 sequence to search for vascular voids. Although rare, FTAVF is a diagnose that should be considered in cases of failed back surgery syndrome.

The interruption of the FTAVF can be done by both surgical and endovascular techniques.^[10,20] The type of treatment depends on numerous factors such as the patient preoperative morbidity, functional status, angioarchitecture and anatomy of the fistula, local expertise, and patient preference.^[6] In general, microsurgical interruption of FTAVF has been the favored intervention.^[27] Since these malformations are fed by a small caliber, long tortuous, and low-lying ASA, with fistulous point close to the arterial supply of spinal cord, microsurgical treatment is considered to be safer for avoiding arterial ischemic complications.^[5,28,31,34] Another advantage of the surgical treatment is the possibility to treat both the fistulous shunt and the lumbar degenerative disease in the same surgical session in cases where both are concomitant.^[10] It should be noted that in cases with multiple feeding vessels, endovascular treatment may not be a viable curative option.^[9,21,27] The treatment key factor is safe isolation of the feeding artery, fistulous point, and draining vein to interrupt the arteriovenous shunt and preserve the normal vascularization of the nervous structures.^[6]

Table 1: Patients with filum terminale arteriovenous fistulas previously operated for lumbar degenerative disease reported in the literature.

Case report (year)	Sex	Age	Length of symptoms (months)	Sensory symptoms (level)	Motor symptoms	Walk without assistance	Sphincters dysfunction	Pain	Reflexes
Tender et al. (2005) ^[31]	M	70	84	Y (L4)	Y	N	Y	Y	NA
Trinh and Duckworth (2011) ^[32]	M	58	12	Y (D10)	Y	N	Y	Y	↑
	M	57	24	Y (L4)	Y	N	Y	Y	NA
Kumar et al. (2011) ^[15]	M	63	48	Y (L4)	Y	N	NA	Y	NA
	M	44	8	Y (L4)	Y	N	Y	Y	↓
Takami et al. (2012) ^[29]	M	63	36	Y (U)	Y	N	Y	Y	NA
Chanthanaphak et al. (2013) ^[1]	F	70	6	Y (U)	Y	N	NA	Y	NA
Krishnan et al. (2013) ^[14]	M	54	36	Y (L3)	Y	N	Y	Y	Absent
Sharma et al. (2014) ^[25]	M	48	132	Y (D10)	Y	N	Y	Y	Absent
Takai et al. (2018) ^[28]	M	40	24	Y (U)	Y	N	Y	Y	NA
Iampreechakul et al. (2020) ^[10]	M	70	12	NA	Y	N	Y	Y	NA
Present case	M	73	18	Y (L3)	Y	N	Y	Y	↑

M: Male, F: Female, U: Undetermined, NA: Not available, MRI: Magnetic resonance imaging, DSA: Digital subtraction angiography, ASA: Anterior spinal artery, I: Improved, S: Stable, NI: Not improved. *Patient had unsuccessful FTAVF embolization and refused to have later surgical treatment

(Contd...)

Table 1: (Continued)

Case report (year)	First diagnosis	First surgery	Partial improvement	Diagnostic exam	Feeders	Location	Treatment	Length of follow-up (months)	Outcome
Tender et al. (2005) ^[31]	Lumbar stenosis	Decompressive laminectomy	Y	Lumbar myelography + selective arteriography	ASA (D11)	L4	Surgical excision of AVF	12	I
Trinh and Duckworth (2011) ^[32]	Lumbar stenosis	Decompressive laminectomy	Y	MRI + selective arteriography	ASA (D9)	L2	Surgical excision of AVF	12	I
	Lumbar listhesis	Lumbar fusion	N	DSA	ASA	NA	Surgical excision of AVF	3	I
Kumar et al. (2011) ^[15]	Lumbar instability	Lumbar fusion	Y	MRI + selective arteriography	NA	L4-L5	Surgical excision of AVF	NA	I
	Cauda equina syndrome	Microdiscectomy	N	MRI + selective arteriography	ASA (D9)	L4-L5	Surgical disconnection	3	I
Takami et al. (2012) ^[29]	Lumbar stenosis	Decompressive laminectomy	N	DSA	ASA (D11)	L3-L4	Surgical excision of AVF	6	I
Chanthanaphak et al. (2013) ^[11]	Lumbar stenosis	Decompressive laminectomy + lumbar fusion	N	Lumbar myelography + MRI + DSA	ASA (Left D12)	L5	Embolization	12	I
Krishnan et al. (2013) ^[14]	Disc bulge	Microdiscectomy	N	MRI + DSA	ASA (D12)	L4	Surgical disconnection	14	I
Sharma et al. (2014) ^[25]	Lumbar stenosis	Decompressive laminectomy	N	MRI + DSA	ASA (D9)	L4-L5	Surgical disconnection	12	I
Takai et al. (2018) ^[28]	Tethered cord syndrome with sacral lipoma	Partial removal of lipoma	N	MRI + DSA	ASA (Left L3)	S1	Surgical disconnection	102	S
Iampreechakul et al. (2020) ^[10]	Lumbar stenosis	Decompressive laminectomy	N	MRI + DSA	ASA (Left D9)	L4-L5	Embolization (unsuccessful)*	NA	NI
Present case	Lumbar stenosis	Decompressive laminectomy	Y	MRI + DSA	ASA (Left D10)	L5-S1	Surgical disconnection	6	I

M: Male, F: Female, U: Undetermined, NA: Not available, MRI: Magnetic resonance imaging, DSA: Digital subtraction angiography, ASA: Anterior spinal artery, I: Improved, S: Stable, NI: Not improved. *Patient had unsuccessful FTAVF embolization and refused to have later surgical treatment

The outcome of interrupted FTAVF is dependent on several factors such as duration of symptoms, pretreatment disability, and success of the procedure to close the fistula.^[11] After shunt obliteration, the venous congestion tends to decrease and results in progressive improvement or, at least, symptoms stabilization.^[1] In our review, almost all the patients that were successfully treated to the FTAVF had neurological improvement. The exception was the case with a tethered cord syndrome with a lipoma that had only symptomatic stabilization,^[28] probably due to inherent spinal cord compromise.

CONCLUSION

FTAVF is a very rare spinal intradural spinal vascular malformation that can be misdiagnosed, submitted to unnecessary spinal surgery, and even masqueraded as a failed back surgery syndrome. Signs of ascending myelopathy should prompt awareness and the MRI must be carefully evaluated for vascular voids in these cases.

Declaration of patient consent

Patient's consent not required as patients identity is not disclosed or compromised.

Financial support and sponsorship

Nil.

Conflicts of interest

There are no conflicts of interest.

REFERENCES

- Chanthanaphak E, Pongpech S, Jiarakongmun P, Kobkitsuksakul C, Chi CT, Terbrugge KG. Filum terminale arteriovenous fistulas: The role of endovascular treatment. *J Neurosurg Spine* 2013;19:49-56.
- Ding D, Law AJ, Scotter J, Brew S. Lumbar disc herniation exacerbating venous hypertension from a spinal perimedullary arteriovenous fistula of the filum terminale. *J Neurol Sci* 2016;369:276-7.
- Fischer S, Perez MA, Bassiouni H, Hopf N, Bätzner H, Henkes H. Arteriovenous fistula of the filum terminale: Diagnosis, treatment, and literature review. *Clin Neuroradiol* 2013;23:309-14.
- Foix C, Alajouanine T. La myélite nécrotique subaiguë. *Rev Neurol* 1926;33:1-42.
- Giordan E, Bortolotti C, Lanzino G, Brinjikji W. Spinal arteriovenous vascular malformations in patients with neural tube defects. *AJNR Am J Neuroradiol* 2018;39:597-603.
- Giordan E, Brinjikji W, Ciceri E, Lanzino G. Arteriovenous fistulae of the filum terminale. *J Neurointerv Surg* 2018;10:191-7.
- Giordan E, Brinjikji W, Lanzino G. Coexistence of perimedullary arteriovenous fistula and arteriovenous fistula of filum terminale in the same patient. *J Neurosurg Sci* 2019;63:237-8.
- Hong T, Park JE, Ling F, Terbrugge KG, Tymianski M, Zhang HQ, *et al.* Comparison of 3 different types of spinal arteriovenous shunts below the conus in clinical presentation, radiologic findings, and outcomes. *AJNR Am J Neuroradiol* 2017;38:403-9.
- Hong T, Yu JX, Liu W, Bian LS, Yang F, Ma YJ, *et al.* Filum terminale arteriovenous fistulas with multiple shunt points: A report of two exceptional cases. *World Neurosurg* 2018;118:235-9.
- Iampreechakul P, Tirakotai W, Wangtanaphat K, Lertbutsayanukul P, Siriwimonmas S. Filum terminale arteriovenous fistula in association with degenerative lumbosacral spinal canal stenosis: Report of 3 cases and review of the literature. *World Neurosurg* 2020;138:231-41.
- Jellema K, Tijssen CC, van Gijn J. Spinal dural arteriovenous fistulas: A congestive myelopathy that initially mimics a peripheral nerve disorder. *Brain* 2006;129:3150-64.
- Jin YJ, Kim KJ, Kwon OK, Chung SK. Perimedullary arteriovenous fistula of the filum terminale: Case report. *Neurosurgery* 2010;66:E219-20; discussion E220.
- Kim LJ, Spetzler RF. Classification and surgical management of spinal arteriovenous lesions: Arteriovenous fistulae and arteriovenous malformations. *Neurosurgery* 2006;59:195-201.
- Krishnan P, Banerjee TK, Saha M. Congestive myelopathy (foix-alajouanine syndrome) due to intradural arteriovenous fistula of the filum terminale fed by anterior spinal artery: Case report and review of literature. *Ann Indian Acad Neurol* 2013;16:432-6.
- Kumar A, Deopujari C, Mhatre M. Misdiagnosis in a case of non-compressive myelopathy due to a lumbar spinal intradural fistula supplied by the artery of adamkiewicz. *Surg Neurol Int* 2011;2:12.
- Lagman C, Chung LK, Chitale RV, Yang I. Dural arteriovenous fistula and foix-alajouanine syndrome: Assessment of functional scores with review of pathogenesis. *World Neurosurg* 2017;106:206-10.
- Lakhdar F, Benzagmout M, Chakour K, Chaoui ME. Spinal arteriovenous fistulas of the filum terminale: Case report and literature. *Asian J Neurosurg* 2019;14:1277-82.
- Lim SM, Choi IS, David CA. Spinal arteriovenous fistulas of the filum terminale. *AJNR Am J Neuroradiol* 2011;32:1846-50.
- Macht S, Chapot R, Bieniek F, Hänggi D, Turowski B. Unique sacral location of an arteriovenous fistula of the filum terminale associated with diastematomyelia and lowered spinal cords. *Neuroradiology* 2012;54:517-9.
- Meisel HJ, Lasjaunias P, Brock M. Modern management of spinal and spinal cord vascular lesions. *Minim Invasive Neurosurg* 1995;38:138-45.
- Mourier KL, Gobin YP, George B, Lot G, Merland JJ. Intradural perimedullary arteriovenous fistulae: Results of surgical and endovascular treatment in a series of 35 cases. *Neurosurgery* 1993;32:885-91.
- Rodesch G, Hurth M, Alvarez H, Tadié M, Lasjaunias P. Classification of spinal cord arteriovenous shunts: Proposal for a reappraisal-the bicêtre experience with 155 consecutive patients treated between 1981 and 1999. *Neurosurgery*

- 2002;51:374-9; discussion 379-80.
23. Rosenblum B, Oldfield EH, Doppman JL, di Chiro G. Spinal arteriovenous malformations: A comparison of dural arteriovenous fistulas and intradural AVM's in 81 patients. *J Neurosurg* 1987;67:795-802.
 24. Scullen T, Mathkour M, Amenta PS, Dallapiazza RF. Arteriovenous fistula of the filum terminale: A case report and review of the literature. *World Neurosurg* 2019;130:42-9.
 25. Sharma P, Ranjan A, Lath R. Arteriovenous fistula of the filum terminale misdiagnosed and previously operated as lower lumbar degenerative disease. *Asian Spine J* 2014;8:365-70.
 26. Shin MJ, Kim W, Baik SK, Kim SY, Kim SN. Cauda equina syndrome caused by spinal dural arteriovenous fistula. *Ann Rehabil Med* 2011;35:928-33.
 27. Singh R, Lucke-Wold B, Gyure K, Boo S. A review of vascular abnormalities of the spine. *Ann Vasc Med Res* 2016;3:1-17.
 28. Takai K, Komori T, Taniguchi M. Angioarchitecture of filum terminale arteriovenous fistulas: Relationship with a tethered spinal cord. *World Neurosurg* 2019;122:e795-804.
 29. Takami T, Yamagata T, Mitsuhashi Y, Hayasaki K, Ohata K. Direct surgery for spinal arteriovenous fistulas of the filum terminale with intraoperative image guidance. *Spine (Phila Pa 1976)* 2012;37:E1524-8.
 30. Tanioka S, Toma N, Sakaida H, Umeda Y, Suzuki H. A case of arteriovenous fistula of the cauda equina fed by the proximal radicular artery: Anatomical features and treatment precautions. *Eur Spine J* 2018;27:281-6.
 31. Tender GC, Vortmeyer AO, Oldfield EH. Spinal intradural arteriovenous fistulas acquired in late adulthood: Absent spinal venous drainage in pathogenesis and pathophysiology. Report of two cases. *J Neurosurg Spine* 2005;3:488-94.
 32. Trinh VT, Duckworth EA. Surgical excision of filum terminale arteriovenous fistulae after lumbar fusion: Value of indocyanine green and theory on origins (a technical note and report of two cases). *Surg Neurol Int* 2011;2:63.
 33. Wajima D, Nakagawa I, Park HS, Haku T, Wada T, Kichikawa K, *et al.* A case of filum terminale arterial venous fistula needed a long arterial access for trans-arterial shunt obliteration. *Interv Neuroradiol* 2017;23:221-7.
 34. Witiw CD, Fallah A, Radovanovic I, Wallace MC. Sacral intradural arteriovenous fistula treated indirectly by transection of the filum terminale: Technical case report. *Neurosurgery* 2011;69:E780-4; discussion E784.

How to cite this article: Farinha NC, Teixeira JC, Reis JH, Coiteiro D. Arteriovenous fistula of the filum terminale masqueraded as a failed back surgery syndrome – A case report and review of literature. *Surg Neurol Int* 2021;12:53.