

CASE REPORT

Dystopic retrohepatic gallbladder and cholecysto-cholecho lithiasis: the rendez-vous and indocyanine green fluorescence

Edoardo Mattone¹ , Saverio Latteri¹, Michele Teodoro¹ , Antonio Pesce², Maurizio Mannino¹, Giulia Romano³, Domenico Russello¹ & Gaetano La Greca¹

¹U.O.C. di Chirurgia Generale, Azienda Ospedaliera per l'Emergenza Cannizzaro, Catania, Italy

²U.O.C. di Chirurgia Generale, Azienda Ospedaliera - Universitaria Policlinico - Vittorio Emanuele, Catania, Italy

³Ospedale Guzzardi Vittoria – U.O. di Medicina Interna, Vittoria, Italy

Correspondence

Edoardo Mattone, U.O.C. di Chirurgia Generale, Azienda Ospedaliera per l'Emergenza Cannizzaro, Catania, Sicilia, Italy. Tel: +390957263233; Fax: +390957263234; E-mail: edoardomattone@gmail.com

Funding Information

No sources of funding were declared for this study.

Received: 25 November 2016; Revised: 22 March 2017; Accepted: 3 April 2017

Clinical Case Reports 2018; 6(3): 522–526

doi: 10.1002/ccr3.1130

The patient signed informed consent and written permission to use data and images for scientific purposes.

Introduction

Laparoscopic cholecystectomy is a well-known procedure for the treatment of most gallbladder diseases. The gold standard treatment for cholelithiasis is laparoscopic cholecystectomy, whereas the gold standard treatment for isolated common bile duct stones is endoscopic clearance [1]. The management of patients affected by gallstones complicated by common bile duct (CBD) stones and/or problems at the papilla of Vater is anyway a challenge as there are many available options for treatment, all being effective but which is the best practice is still unknown [2]. The gallbladder may have abnormal position, be intrahepatic, have anomalous form, or be duplicated [3]. Fluorescent cholangiography with indocyanine green is a safe procedure performed to help surgeons for the

Key Clinical Message

Laparoscopic cholecystectomy is a well-known procedure for the treatment of most gallbladder diseases. Sometimes, it could be very difficult, in the presence of aberrations regarding the cystic duct, the cystic artery, or the gallbladder itself. Fluorescence laparoscopy using indocyanine green could be very useful for all the situations of anatomy aberrations.

Keywords

Dystopic, gallbladder, green indocyanine, laparoscopic cholecystectomy, rendez-vous, retrohepatic.

identification of the biliary tree anatomy, reducing the risk of biliary iatrogenic injuries [4, 5]. We report an extremely rare case about cholelithiasis in dystopic gallbladder placed on Morrison's pouch. In our knowledge, this is the first report of laparoscopic cholecystectomy performed on a dystopic gallbladder using fluorescence imaging of indocyanine green.

Review of Literature

Chou et al. [6] reported eight cases of retrohepatic gallbladder, two associated with agenesis of the right hepatic lobe, and six associated with atrophy of right hepatic lobe, and they showed that the absence of visualization of all of the right hepatic vein, right portal vein and its branches, and dilated right intrahepatic ducts is a prerequisite of the

diagnosis of agenesis of the right hepatic lobe. Naganuma *et al.* [7] observed 18 patients with gallbladder anomalous position and tried to determine its ultrasound findings in order to avoid misdiagnosis: Nine patients presented left-side gallbladder with the narrow neck clearly detected by US in the usual location before the main portal vein, four patients presented retrohepatic gallbladder associated with marked atrophy of the right lobe of the liver, four patients presented suprahepatic gallbladder with marked atrophy of the anterior segment of the right hepatic lobe, and one patient presented floating gallbladder that appeared like a cystic mass in the anterior abdominal wall. Greaves *et al.* [8] also diagnosed a retrohepatic gallbladder by sonography and scintigraphy. Hsu *et al.* [9] published a case report about hypoplastic right hepatic lobe with retrohepatic gallbladder complicated by left hepatolithiasis and liver abscess pre-operatively diagnosed by computed tomography. Kakitsubata *et al.* [10] reported two cases of suprahepatic gallbladder and one case of retrohepatic gallbladder associated with hypoplasia of the right lobe of the liver showed that gallbladder position could be a good indicator of right hepatic lobe anomaly. Liessi *et al.* [11] also reported three cases of retrohepatic gallbladder. Moschopoulos *et al.* [12] observed a case of agenesis of the right lobe of the liver associated with retrohepatic gallbladder. Radin [13] performed a percutaneous cholecystostomy of a retrohepatic gallbladder. Feldman and Venta [14], instead, performed a percutaneous cholecystostomy on a retrohepatic gallbladder in a patient with sclerosing cholangitis diagnosed by computed tomography, ultrasound, percutaneous transhepatic cholangiography, and sulfur colloid liver scan. Nardi *et al.* [15] observed two cases of retrohepatic gallbladder on ultrasound and CT in severe hepatic cirrhosis and marked morphological distortion of the liver. Principe *et al.* [16] published a case of ectopic gallbladder located retrohepatically in the coronary ligament which escaped observation at a first explorative laparotomy, marked the importance of attentive intra-operative exploration, including cholangiography. Ehman and Morrish [17] published a case report about retrorenal gallbladder revealed by computed tomography. Bort Marti *et al.* [18] reported a case of posterior gallbladder with cholelithiasis. Youngwirth *et al.* [19] described a case of ectopic gallbladder founded lying posterior to the liver in the subdiaphragmatic space and they maintained that this condition should be considered whenever the right lobe of the liver is hypoplastic, and the gallbladder cannot be visualized on hepatobiliary scans (Table 1).

Case Report

A 79-year-old woman presented to our hospital with right upper quadrant abdominal pain, especially referred after

meals, associated with nausea and vomiting. At the physical examination, no fever, no yellow skin, and sclera and negative Murphy's sign. The laboratory findings revealed impaired liver function with an increase in alanine amino-transferase (208 U/I), aspartate amino-transferase (173 U/I), total bilirubin (11.10 mg/dL), direct bilirubin (6.97 mg/dL). Blood work also showed mild elevation of the white blood cell (WBC) count (12.90 K/aeL), especially neutrophils (84.20%), and high C-reactive protein

Table 1. Gallbladder anatomical aberrations in the literature.

Anatomical aberrations	Cases
Retrohepatic	27
Retrohepatic-suprahepatic	7
Retrorenal	1

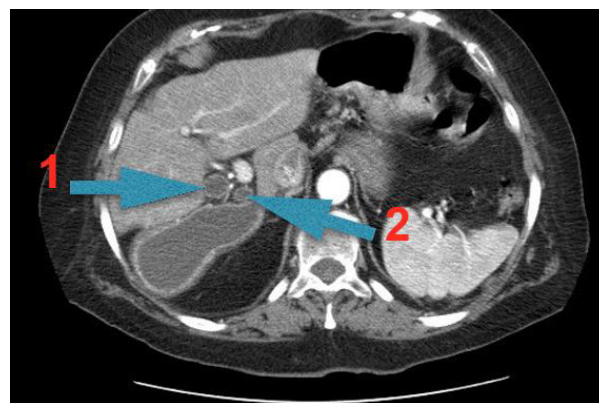


Figure 1. CT image. 1: choledocho. 2: cystic duct.

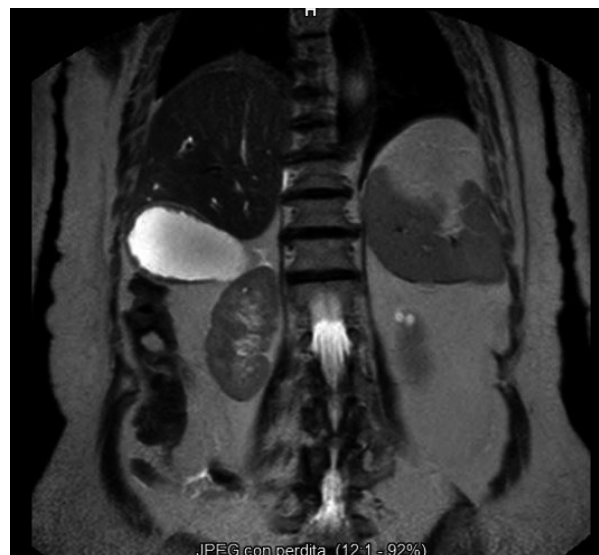

Figure 2. Magnetic resonance image.

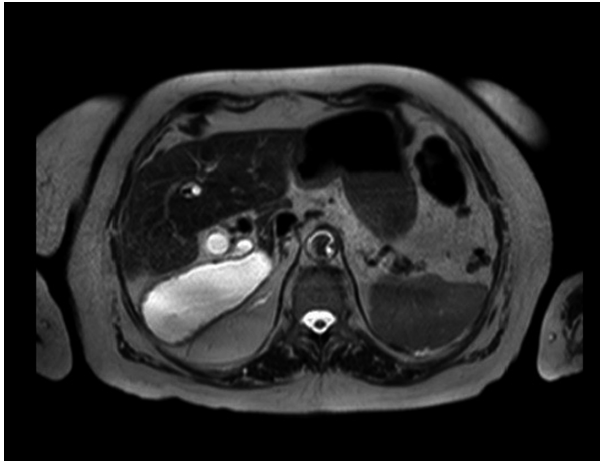


Figure 3. Magnetic resonance image.

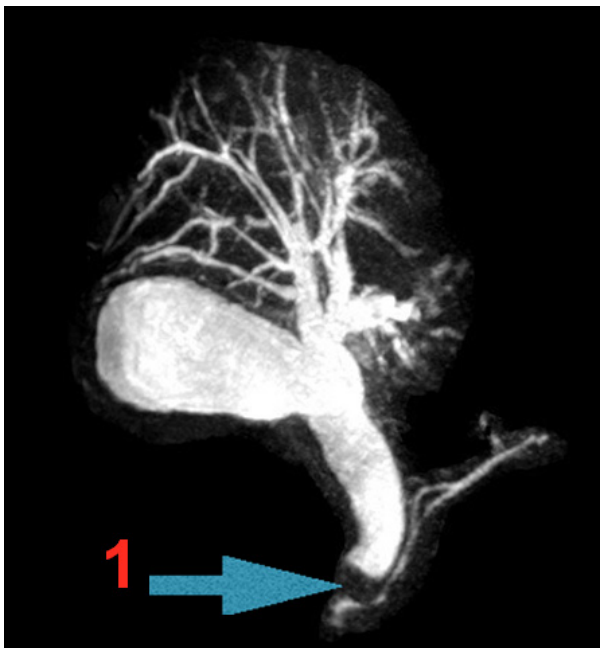

Figure 4. Magnetic resonance image. 1: stone.

(CRP) level (17.67 mg/dL). An abdominal ultrasonography revealed the presence of multiple gallstones inside the gallbladder, pericholecystic fluid, marked gallbladder wall thickening, and dilatation of hepato-cholecho. The abdominal computed tomography (CT) study also showed gallstones inside the posterior dystopic gallbladder that was placed on Morrison's pouch, a dilatation of hepato-cholecho (about 2 cm in diameter) with proximal multiples gallstones and an abnormal position of the cystic duct, that was medial, and the choledocho, that was lateral (Fig. 1). One of this caused complete obstruction of the duct. Magnetic Resonance Imaging (MRI)

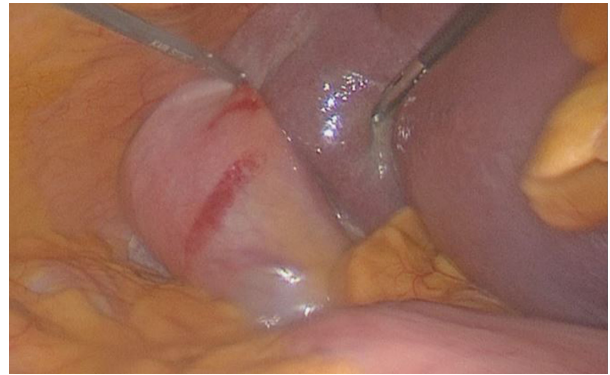

Figure 5. Intra-operative image of retrohepatic gallbladder.

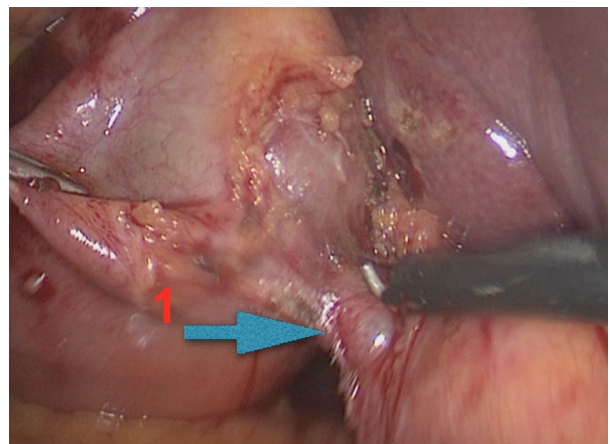


Figure 6. Intra-operative image. 1: cystic duct.

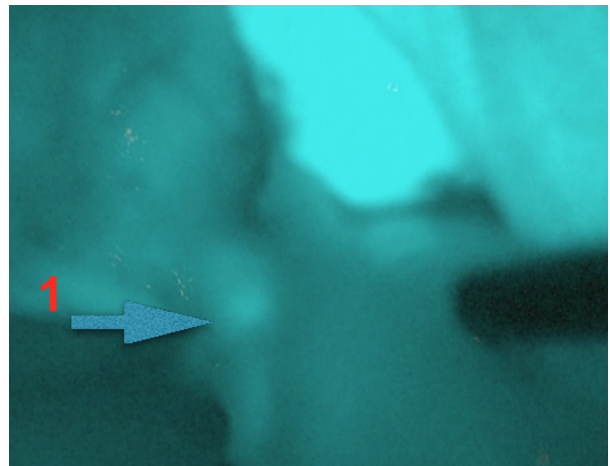


Figure 7. Intra-operative fluorescence image. 1: cystic duct.

confirmed the presence of gallstones inside the gallbladder and the hepato-cholecho (Figs 2–4). The patient was diagnosed with acute calculous cholecystitis associated

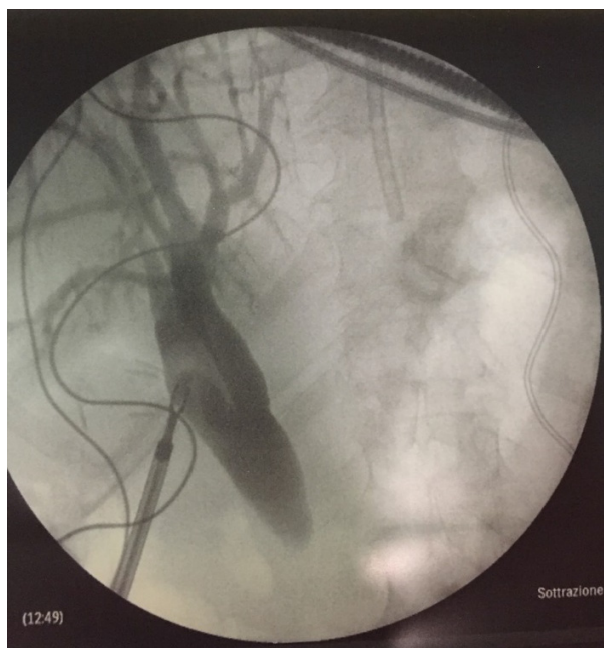


Figure 8. Intra-operative cholangiography image.

with choledocholithiasis, and laparoendoscopic “rendez-vous” procedure was proposed for treatment. The patient was taken to the operating room on, and 35 mL of indocyanine green was injected intravenously 60 min before surgery. Laparoscopic cholecystectomy was performed via four ports. The liver was identified with retrohepatic gallbladder (Fig. 5). Fluorescence helped the surgeon to identify the Calot’s element, especially the cystic duct that was accurately isolated (Figs 6 and 7). The “critical view of safety” was verified before ligating the cystic duct and the cystic artery using a endoscopic clips. Then intra-operative cholangiography was performed that confirmed the dilatation of the hepato-choledochus and the presence of two big gallstones (Fig. 8). Next ERCP was performed by endoscopist with lithotripter, clearing the hepato-choledochus. Then, the cystic duct and the cystic artery were dissected and thanks to the fluorescence images the boundary between the liver and the gallbladder could be clearly visualized, and the gallbladder was detached easily from the liver bed. The operative time was 2 h and 30 min.

Discussion

Many cases of abnormal gallbladder position were reported in the literature but, to our knowledge, none about retrohepatic gallbladder that is extremely rare, cholelithiasis treated by rendez-vous and indocyanine green fluorescence. Fortunately, ultrasonography,

computed tomography (CT), and Magnetic Resonance Imaging (MRI) help us to identify the anatomical aberrations before the surgical treatment. In our case, the major risk was to damage the biliary extrahepatic ducts and the gallbladder itself. Furthermore, the CT images helped us to distinguish the cystic duct that was medial, from the choledochus that was lateral, with high risk to dissect the choledochus instead of cystic duct. Another technical problem was to detach the gallbladder from the liver bed without damage the liver or the gallbladder but this risk was reduced by the assistance of fluorescence images.

Conclusion

Although laparoscopic cholecystectomy is considered safe and well-known procedure for the treatment of gallbladder disease and it was widely performed especially by young surgeons, it could be very difficult in the presence of anatomical aberrations. Fluorescence cholangiography can help surgeons to the correct visualization of the gallbladder and the biliary tree and so reduce the risk of iatrogenic damage. Furthermore, pre-operative diagnosis of gallbladder anatomical aberrations is necessary for the correct approach to the surgical operation. However, in extremely rare case like this one, surgeon’s experience is critical and he must consider, if in doubt, the conversion to open procedure, in order to avoid serious intra- and post operative complications.

Authorship

EM: first author, he was responsible for writing and reviewing the manuscript and literature review. SL: involved in making the study conception and design and critical review of the manuscript. MT: responsible for literature search and data acquisition. AP: responsible for literature search and data acquisition. MM: responsible for literature search and data acquisition. GR: responsible for literature search and data acquisition. DR: designed and coordinated the research study and approved the final version of the manuscript to be published. GLG: performed the surgical operation, designed and coordinated the research study and approved the final version of the manuscript to be published.

Conflict of Interest

None declared.

References

1. La Greca, G., F. Barbagallo, M. Sofia, S. Latteri, and D. Russello. 2009. Simultaneous laparoendoscopic rendezvous

- for the treatment of cholecystocholedocholithiasis. *Surg. Endosc.* 24:769–780.
2. La Greca, G., F. Barbagallo, M. Di Blasi, A. Chisari, R. Lombardo, R. Bonaccorso, et al. 2008. Laparo-endoscopic “Rendezvous” to treat cholecysto- choledocolithiasis: effective, safe and simplifies the endoscopist’s work. *World J. Gastroenterol.* 14:2844–2850.
 3. Pham, T. H., J. G. Hunter. 2015. Gallbladder and extrahepatic biliary sistem. Pp. 1312 *in* F. C. Brunicaudi, D. K. Andersen, T. R. Billiar, et al., eds. *Schwartz’s principles of surgery*. McGraw-Hill, New York.
 4. Tagaya, N., M. Shimoda, M. Kato, A. Nakagawa, A. Abe, Y. Iwasaki, et al. 2010. Intraoperative exploration of biliary anatomy using fluorescence imaging of indocyanine green in experimental and clinical cholecystectomies. *J. Hepatobiliary Pancreat. Sci.* 17:595–600.
 5. Pesce, A., G. Piccolo, G. La Greca, and S. Puleo. 2015. Utility of fluorescent cholangiography during laparoscopic cholecystectomy: a systematic review. *World J. Gastroenterol.* 21:7877–7883.
 6. Chou, C. K., C. W. Mak, M. B. Lin, W. S. Tzeng, and J. M. Chang. 1998. CT of agenesis and atrophy of the right hepatic lobe. *Abdom. Imaging* 23:603–607.
 7. Naganuma, S., H. Ishida, K. Konno, Y. Hamashima, T. Hoshino, H. Naganuma, et al. 1998. Sonographic findings of anomalous position of the gallbladder. *Abdom. Imaging* 23:67–72.
 8. Greaves, F. W., K. T. Nguyen, and E. E. Sauerbrei. 1983. Retrohepatic gallbladder diagnosed by sonography and scintigraphy. *J. Can. Assoc. Radiol.* 34:319–320.
 9. Hsu, K. L., Y. F. Cheng, and S. F. Ko. 1997. Hypoplastic right hepatic lobe with retrohepatic gallbladder complicated by hepatolithiasis and liver abscess: a case report. *Hepatogastroenterology* 44:803–807.
 10. Kakitsubata, Y., S. Kakitsubata, and K. Watanabe. 1997. Gallbladder abnormalities associated with hypoplasia of the right lobe of the liver. *Radiat. Med.* 15:71–74.
 11. Liessi, G., B. Spaliviero, S. Cesari, P. Avventi, F. Sandini, C. Dell’Antonio, et al. 1993. Sonographic picture, with computed tomography and magnetic resonance in 3 cases of “retrohepatic” gallbladder. *Radiol. Med.* 86:544–547.
 12. Moschopoulos, C., J. M. Bailly, G. Bruninx, and C. Delcour. 1993. Agenesis of the right lobe of the liver. Apropos of a case. *Ann. Radiol. (Paris)* 36:323–327.
 13. Radin, D. R. 1989. A patient with a retrohepatic gallbladder. *Gastrointest Radiol.* 14:363.
 14. Feldman, L., and L. Venta. 1988. Percutaneous cholecystostomy of an ectopic gallbladder. *Gastrointest Radiol.* 13:256–258.
 15. Nardi, P. M., J. Yaghoobian, and R. B. Tuchman. 1998. CT demonstration of retrohepatic gallbladder in severe cirrhosis. *J. Comput. Assist. Tomogr.* 12:968–970.
 16. Principe, A., M. Spangaro, A. Lapilli, R. Vecchi, L. Volta, P. De Lorenzi. 1979. Congenital anomalies of the gallbladder. A case of retrohepatic gallbladder contained in the coronary ligament. *Minerva Chir.* 34:879–884.
 17. Ehman, R. L., and H. F. Morris. 1983. Retrorenal gallbladder. A case report. *J. Can. Assoc. Radiol.* 34:321–322.
 18. Bort Marti, J., J. Ferrando Cucarella, J. Berenguer Lapuerta, E. Nogués Pelayo, and F. Parrilla Paricio. 1971. A case of posterior gallbladder with cholelithiasis. *Rev. Clin. Esp.* 122:53–56.
 19. Youngwirth, L. D., J. C. Peters, and M. C. Perry. 1983. The suprahepatic gallbladder. An unusual anatomical variant. *Radiology* 149:57–58.