



Brain structural correlates of autistic traits across the diagnostic divide: A grey matter and white matter microstructure study

Varun Arunachalam Chandran^{a,b,*}, Christos Pliatsikas^{c,d}, Janina Neufeld^e, Garret O'Connell^f, Anthony Haffey^a, Vincent DeLuca^g, Bhismadev Chakrabarti^{a,h,i}

^a Centre for Autism, School of Psychology and Clinical Language Sciences (SPCLS), University of Reading, UK

^b Center for Mind and Brain, University of California Davis, Davis, CA, USA

^c School of Psychology and Clinical Language Sciences, University of Reading, Harry Pitt Building, Earley Gate, Whiteknights Road, Reading RG6 6AL, UK

^d Centro de Ciencia Cognitiva, Facultad de Lenguas y Educación, Universidad Antonio de Nebrija, Calle de Sta. Cruz de Marcenado, 27, 28015 Madrid, Spain

^e Center of Neurodevelopmental Disorders (KIND), Centre for Psychiatry Research, Department of Women's and Children's Health, Karolinska Institutet & Stockholm Health Care Services, Stockholm, Sweden

^f School of Mind and Brain, Humboldt University, Berlin, Germany

^g Department of Language and Culture, UiT- The Arctic University of Norway, Hansine Hansens veg 18, 9019 Tromsø, Norway

^h Department of Psychology, Ashoka University, Sonapat, India

ⁱ India Autism Center, Kolkata, India

ARTICLE INFO

Keywords:

Autism spectrum disorders
Autistic traits
Grey matter
White matter microstructure
Structural MRI
Diffusion Tensor Imaging

ABSTRACT

Autism Spectrum Disorders (ASD) are a set of neurodevelopmental conditions characterised by difficulties in social interaction and communication as well as stereotyped and restricted patterns of interest. Autistic traits exist in a continuum across the general population, whilst the extreme end of this distribution is diagnosed as clinical ASD. While many studies have investigated brain structure in autism using a case-control design, few have used a dimensional approach. To add to this growing body of literature, we investigated the structural brain correlates of autistic traits in a mixed sample of adult participants (25 ASD and 66 neurotypicals; age: 18–60 years). We examined the relationship between regional brain volumes (using voxel-based morphometry and surface-based morphometry) and white matter microstructure properties (using Diffusion Tensor Imaging) and autistic traits (using Autism Spectrum Quotient). Our findings show grey matter differences in regions including the orbitofrontal cortex and lingual gyrus, and suggestive evidence for white matter microstructure differences in tracts including the superior longitudinal fasciculus being related to higher autistic traits. These grey matter and white matter microstructure findings from our study are consistent with previous reports and support the brain structural differences in ASD. These findings provide further support for shared aetiology for autistic traits across the diagnostic divide.

1. Introduction

Autism Spectrum Disorders (ASD) are complex neurodevelopmental conditions characterised by atypical social interaction and communication as well as stereotyped behaviours (American Psychiatric Association, 2013). The origin of differences in brain structure and volume can be traced back to early childhood, as several studies reported early brain overgrowth in younger children (2–5 years old) with ASD (Courchesne et al., 2001; Hardan et al., 2001). It was suggested that the enlarged brain structural abnormalities were indexed by an increase in head circumference (Courchesne et al., 2003). Such brain structural

differences may, in some cases, continue to exist until adulthood in ASD. These differences in brain structure may reflect alternate trajectories of brain development which have consequences for the behavioural manifestations of ASD.

Studies measuring brain structure in autism have traditionally used voxel based morphometry (VBM) (Nickl-Jockschat et al., 2012) and showed reduced regional grey matter volume (GMV) in cortical brain regions including the orbitofrontal cortex (OFC) (Hardan et al., 2006; Mueller et al., 2013), amygdala (Nordahl et al., 2012; Mosconi et al., 2009), fusiform gyrus (FG) (Sato et al., 2017), and superior temporal sulcus (STS) (Boddaert et al., 2004) in individuals with ASD compared to

* Corresponding author at: School of Psychology and Clinical Language Sciences (SPCLS), University of Reading, UK.

E-mail address: v.arunachalamchandran@pgr.reading.ac.uk (V. Arunachalam Chandran).

<https://doi.org/10.1016/j.nicl.2021.102897>

Received 28 May 2021; Received in revised form 25 October 2021; Accepted 22 November 2021

Available online 23 November 2021

2213-1582/© 2021 Published by Elsevier Inc. This is an open access article under the CC BY-NC-ND license (<http://creativecommons.org/licenses/by-nc-nd/4.0/>).

controls (Cauda et al., 2014; Mundy, 2018; Via et al., 2011). These regions are considered to be part of the putative ‘social brain’ circuit and believed to play a significant role in theory of mind abilities, emotional judgement, face recognition and interpreting biological motion cues respectively (Brothers, 1990; Pelphrey et al., 2011; Schultz, 2005). While the majority of structural neuroimaging studies of autism do not make an explicit link to behavioural outcomes (but see Rosenblau et al., 2020 for an exception), there have been several studies linking brain structural features with autism symptom domains (Ecker et al., 2012; Rojas et al., 2006).

Although regional GMV can be measured using VBM, two-third of the cortical structures are hidden and it may be difficult to directly measure other surface based metrics such as cortical thickness, surface area and gyrification (Jiao et al., 2010). Considering this, some previous studies used surface based morphometry (including the regional and inter-regional structural networks) and demonstrated increased cortical thickness in the medial prefrontal cortex and reduced cortical thickness in the posterior cingulate cortex and precuneus in individuals with ASD relative to controls (Valk et al., 2015).

Previous studies have suggested that key brain regions may be poorly connected due to white matter microstructure differences which may affect the social information processing in individuals with ASD (Rippon et al., 2007; Wass, 2011). These differences in the white matter microstructure may be driven by reduced axonal density and myelination in individuals with ASD. Previous studies on ASD have reported white matter microstructure abnormalities (reduced fractional anisotropy and increased mean diffusivity) in the fibre tracts including bilateral superior longitudinal fasciculus (SLF), uncinate fasciculus (UF), inferior longitudinal fasciculus (ILF) and inferior fronto-occipital fasciculus (IFOF) (Boets et al., 2018; Catani et al., 2016; Itahashi et al., 2015; Barnea-Goraly et al., 2004; Groen et al., 2011; Lee et al., 2007; Lisiecka et al., 2015) which connects key social brain regions. These differences in the regional grey matter (including the social brain regions) and white matter microstructure (Aoki et al., 2013) indicate brain structural atypicalities which are believed to play an important role in individuals with ASD.

The majority of the studies discussed above have used a case-control design and reported brain structural differences including regional grey matter volume (GMV) and white matter microstructure in individuals with ASD. These brain structure measurements between the ASD and control group may induce a sampling bias in the analysis and lead to mixed findings. There is considerable variance inherent in the case-control design due to the sampling of the controls. A dimensional approach avoids this source of variance by sampling across the whole population. Growing evidence suggests that autistic traits lie in a continuum across the general population, whilst the higher end of this trait measure is diagnosed as clinical ASD (Whitehouse et al., 2011; Robinson et al., 2011). More importantly, it is very important to understand the brain structure, rather than solely depending upon the behavioural measures assessing the symptoms of autism irrespective of categorising clinical ASD. This is because although ASD is a behaviourally defined condition, from the previous studies, brain structural differences are believed to underlie the atypical behavioural manifestations in ASD. Recent developments within mental health and psychiatry research have led to the Research Domain Criteria (RDoC) which provides a dimensional transdiagnostic framework for investigating individual differences at multiple levels. Our study is aligned with this framework in using a dimensional approach to investigate brain structural differences, irrespective of diagnostic category membership.

We used SBM to measure cortical thickness, surface area and gyrification in the cortical grey matter, as well as VBM to characterise both cortical and subcortical grey matter volume at a whole brain level. Voxel based Morphometry (VBM) is a volumetric analysis that uses a whole brain voxel-by-voxel comparison to compute the local concentration of the regional grey and white matter volume in the brain (Ashburner and Friston, 2000). Surface-based Morphometry (SBM) uses a cortical

Table 1
Sample characteristics.

Characteristics	sMRI sample (N = 91)		DTI sample (N = 53)	
	Mean	SD	Mean	SD
Age	28.14	10.313	32.08	11.440
Gender (m/f)	52/39	N/A	31/22	N/A
AQ	20.76 [3–49]	11.983	25.21 [6–49]	12.402
IQ	N/A	N/A	51.98	24.919

N = Number of participants, SD-Standard Deviation, Range [], m-male; f-female, N/A - Not Applicable. Note: The Raven’s Progressive Matrices percentile ranging between 25 and 75 is considered as average IQ.

surface reconstruction to measure the cortical thickness, surface area, volume and gyrification (Fischl, 2012). SBM helps us to compute the grey matter metrics only in the cortical structures, but not the subcortical structures, whereas VBM helps us to compute the regional GMV for both cortical and subcortical structures. In addition, we also examined the white matter microstructure differences using DTI. We explored the relationship of these brain based metrics with self-reported autistic traits in a mixed sample of adults including neurotypicals and individuals with ASD.

2. Methods and materials

2.1. Participants

Ninety-one adults consisting of 66 neurotypicals and 25 ASD (52 males, 39 females, age 18–60 years, mean AQ: 36.32 ASD and 14.86 neurotypicals), participated in this study. Participants with a clinical diagnosis of ASD were included to enrich the higher end of the score distribution for autistic traits. All neurotypical individuals were recruited from the University of Reading campus and autistic individuals were recruited from a research volunteer database held at the Centre for Autism, University of Reading. All autistic participants had a DSM-IV TR autism spectrum diagnosis from a recognized clinic, and were assessed using the Autism Diagnostic Observation Schedule (ADOS) module-4 (Lord et al., 2000). Subjects with any neurological conditions or head injuries were excluded from the study. Autism Spectrum Quotient (AQ) scores (Baron-Cohen et al., 2001) were also collected from all participants. AQ is a widely used self-report measure of autistic traits in adults, which shows high reliability and validity (Ruzich et al., 2015; Baron-Cohen et al., 2001). This dataset came from two separate phases of data collection (N = 53 originally reported in Neufeld et al., 2019; Hsu et al., 2018a and N = 38 originally reported in Hsu et al., 2018b; both phases used the same protocol for collecting structural MRI). This study was approved by the University Research Ethics Committee (UREC), University of Reading. From the full sample above, a subset of fifty-three adults consisting 28 neurotypicals and 25 ASD matched for age, gender and IQ took part in the diffusion tensor imaging study. The performance IQ was measured using Raven’s Progressive Matrices (Neufeld et al., 2019) because the verbal IQ (VIQ) based matching strategies were not ideal for autism case-control studies (Table 1).

2.2. sMRI and DTI data collection

Siemens Trio 3 T MRI Scanner was used to acquire the high resolution T1-weighted whole brain structural images from all participants using 32-channel head coil including (Voxel size = $1 \times 1 \times 1$ mm; matrix = 256×256 ; TR = 2020 ms; TE = 2 ms) at the Centre for Integrative Neurosciences and Neurodynamics (CINN). The DTI protocol used single-shot spin echo, echo planar imaging (EPI) with 32-gradients including 60 diffusion weighted ($b = 1000$ sec/mm²) and 2 non-diffusion weighted images ($b = 0$ sec/mm²), repetition time = 7200 ms; echo time = 10 ms, matrix = 128×128 , voxel size = $2 \times 2 \times 2$ mm (isotropic).

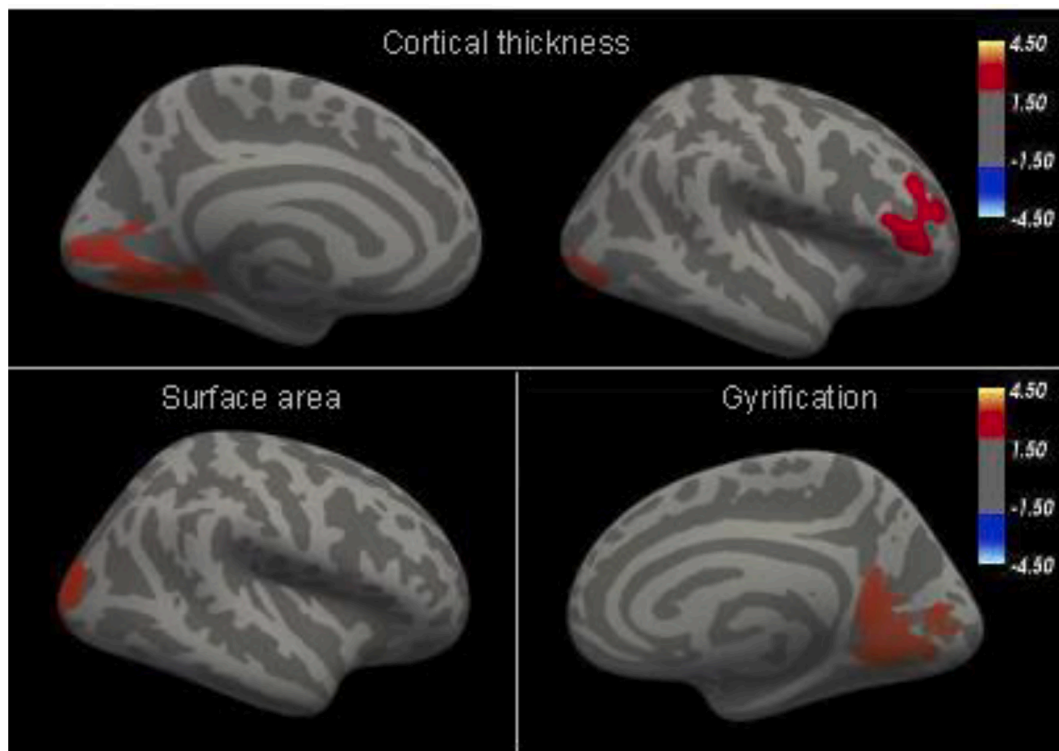


Fig. 1. Cortical thickness: Clusters showing significantly associated brain regions of lingual Gyrus (left), lateral occipital (Right) and pars triangularis (right). Cortical thickness is measured in millimetres (mm). **Surface area:** Clusters showing significantly associated brain regions in lateral occipital cortex (right). The unit of surface area is square millimetre (mm^2). **LGI:** Clusters showing significantly associated brain regions in lingual gyrus (right). Local gyrfication index has no units.

2.3. SBM preprocessing

Freesurfer analysis suite (Fischl, 2012) was used to perform the surface-based morphometry to reconstruct the cortical surface. The MPRAGE images were preprocessed and corrected for head motion, bias field correction, skull-stripping, segmentation, registration, spatial normalisation and smoothing. After the bias-field correction and skull-stripping, the individual structural images were computed to determine the transformation matrix and co-registered to the Talairach space to maximise the possibility that individual images overlap with the study-specific average brain template coordinates. Then, the structural brain images were segmented into pial and white surfaces. Next, the inflated cortical surfaces from the individual images were spatially normalised to the spherical average template, such that each vertex forming multiple triangles across the surface were aligned closely to the corresponding anatomical locations. In the final step, default smoothing was applied to normalise the local neighbourhood voxels across the entire brain. The pial surfaces of each hemisphere were preprocessed to create an outer smoothed pial surface to account for the local gyrfication index (LGI).

All the individual subjects' cortical thickness, surface area and local gyrfication index maps were concatenated together for measuring each metric separately in the group level analysis. Additionally, smoothing (FWHM = 10 mm) was applied to average the close neighbourhood voxels for cortical thickness, surface area, while no additional smoothing was used for measuring the local gyrfication index in this analysis based on its compatibility of the cluster-forming threshold (0.05).

2.4. VBM preprocessing

Voxel-based morphometry was applied for preprocessing and analysis with the Diffeomorphic Anatomical Registration Through Exponentiated Lie algebra (DARTEL) pipeline incorporated in SPM12 toolbox. Initially MRI dataset were visually inspected for head motion

artifacts and signal dropout carefully before proceeding with preprocessing and analysis. Translation (x, y and z-axis) and rotation (pitch, roll and yaw) parameters were used to realign all the MPRAGE dataset subjected to head motion. All T1-weighted structural brain (MPRAGE) images were reoriented for anterior and posterior commissure alignment. In this method, images were segmented into grey matter, white matter and CSF. Then, a study-specific template was created by aligning and averaging the inter-subject grey matter volumes iteratively. The segmented individual grey matter volumes were registered to the template using non-linear registration and normalised to MNI standard space. These normalised images were smoothed using Gaussian kernel (FWHM = 8 mm) for the cortical structures and subcortical structures (FWHM = 4 mm) by averaging the spatial intensity of the local neighbouring voxels (Ashburner, 2010; Coalson et al., 2018).

2.5. Tract-based spatial statistics

Tract-based Spatial Statistics (TBSS), a whole-brain voxel-wise analytical approach incorporated in the FSL software library version 5.0 (Smith et al., 2006) was used for the data analysis. The standard TBSS preprocessing and analysis pipeline was used for eddy current correction, non-brain tissue removal, diffusion tensor modelling, registration, normalisation, thresholding and randomisation as follows: The DTI images were preprocessed for eddy current correction and removal of non-brain tissues, and the diffusion tensor models (FA and MD maps) were derived from all the images. Subsequently, the FA and MD maps were non-linearly registered and transformed to the FA FMRIB (1 mm^3) standard space. Next, the mean FA skeleton, all skeletonised FA and MD 4D concatenated multi-subject maps were derived and transformed using non-linear registration to the MNI152 (1 mm^3) standard space. Then, a white matter thresholding (0.2) was used on the mean FA skeleton to restrict the grey matter partial volume effects.

Table 2

Brain showing association between cortical thickness, surface area, cortical volume and AQ.

Brain regions	Hem	Talairach coordinates			t-value	K
		x	y	z		
Cortical thickness						
Lingual gyrus	L	-14.2	-63.4	-3.5	3.642	2386.74
Lateral Occipital	R	18.3	-100.3	-7	4.255	4388.31
Pars triangularis	R	47	5	4.7	3.679	1480.64
Surface area						
Lateral Occipital	R	16.2	-99.1	-2.5	3.434	4042.26
Local gyrification index						
Lingual gyrus	R	18.6	-64.2	-8.3	2.493	2392.50

Abbreviations: L- Left, R- Right, K-cluster size, t-value - test statistics, Hem-Hemisphere, p-threshold = 0.05, corrected.

3. Statistical analysis

3.1. SBM analysis

In the SBM analysis, the Different Offset Same Slope model was used to test the relationship between cortical thickness, surface area, local gyrification index (separately for each dependent variable at a time) and AQ, including age and gender as covariates. The FreeSurfer Group Descriptor format was used to construct a design matrix. Then, the

precomputed Monte-Carlo Simulation was used to run the tests for multiple comparisons with a cluster-forming threshold (0.05) and the threshold for significance ($p = 0.05$, two-tailed).

3.2. VBM analysis

The general linear model was used to test the relationship between the regional GMV and AQ scores across the combined sample of ASD and neurotypicals after controlling for the effects of age, gender and total brain volume. The covariates including the age and gender were demeaned for the whole sample. We used Family Wise Error (FWE) rate testing for multiple comparisons.

3.3. Tract-based spatial statistics

The general linear model was used to test the relationship between fractional anisotropy and AQ. In addition, the relationship between the mean diffusivity and AQ was also tested, while controlling for age, gender and IQ. This was performed using permutation-based testing ($N = 5000$) and Threshold-free Cluster Enhancement (TFCE) for multiple comparisons.

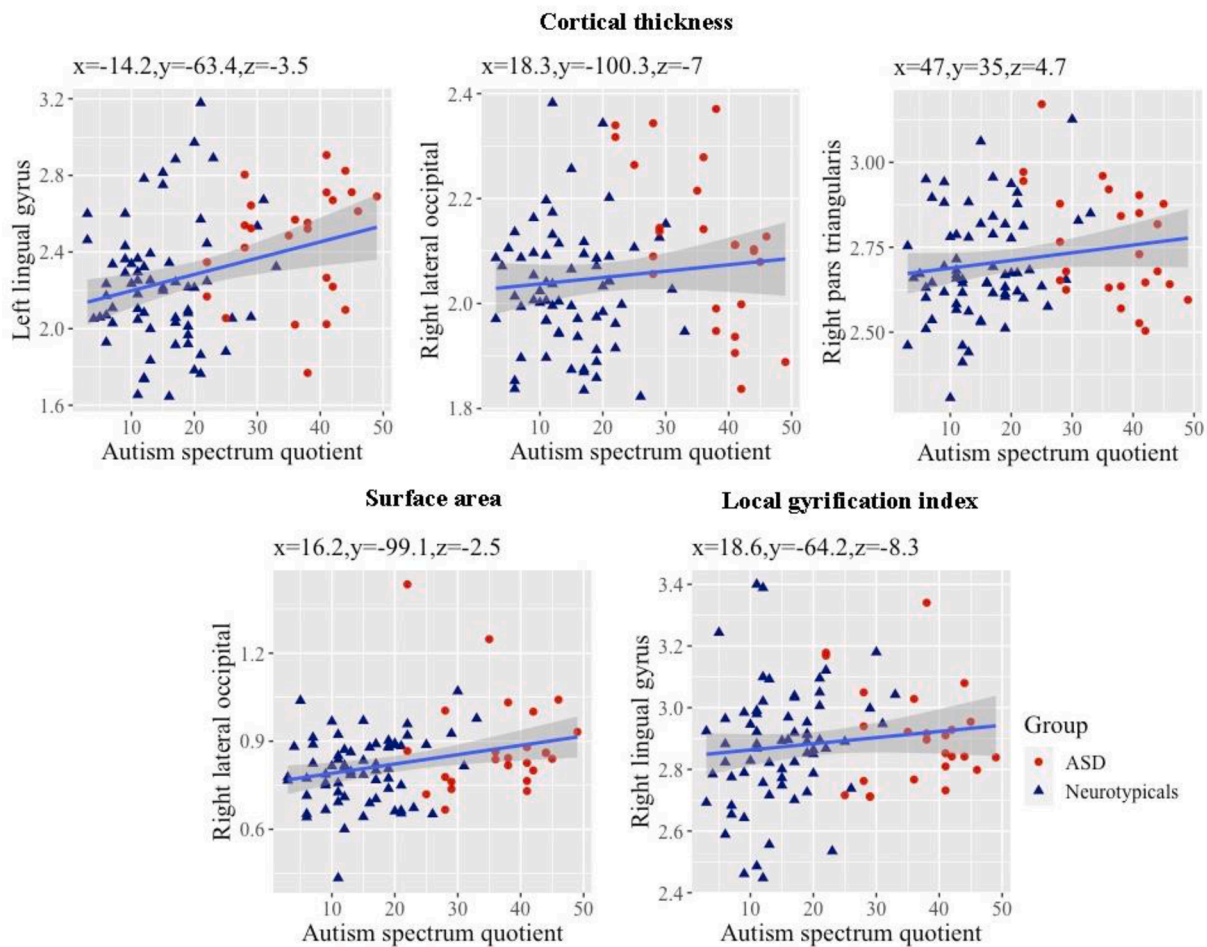


Fig. 2. Scatterplot showing positive association between cortical thickness (first row), surface area (second row, left), gyrification (second row, right) in different brain regions with AQ scores. The coloured triangles in navy blue and red indicate controls and ASD respectively. Note: Autistic and non-autistic participants are marked differently on the scatterplots for the purpose of visual illustration. (For interpretation of the references to colour in this figure legend, the reader is referred to the web version of this article.)

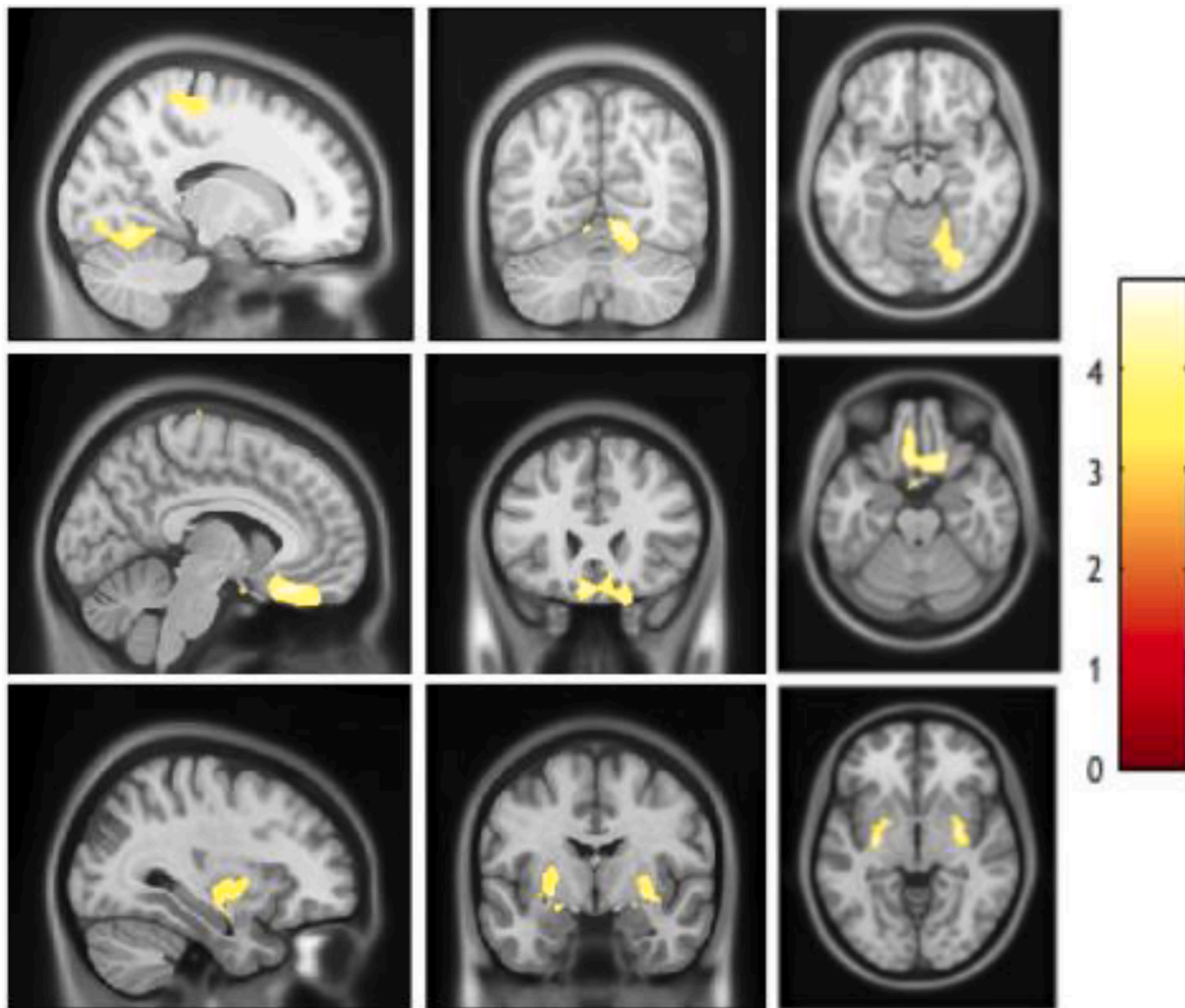


Fig. 3. Row 1: Significantly associated cluster in right lingual gyrus and right precentral gyrus. Row 2: Significantly associated cluster in right orbitofrontal cortex. Row 3: Significantly associated clusters in bilateral putamen.

4. Results

4.1. Surface based morphometry

Our analysis focused on the relationship between surface-based morphometry and autistic traits revealed significant positive association between all four metrics including cortical thickness, surface area, local gyrification index and autistic traits across the combined sample of neurotypicals and individuals with ASD (Fig. 2). Autistic traits were found to be significantly associated with cortical thickness in the left lingual gyrus, right lateral occipital cortex and right pars triangularis, and with surface area in the right lateral occipital cortex. In addition, the significantly associated clusters for local gyrification index were observed in the right lingual gyrus (Fig. 1, Table 2).

4.2. Voxel based morphometry

We found significant positive association between regional GMV and AQ scores in cortical brain regions including the clusters of right lingual gyrus and precentral gyrus. We also found significant positive association between regional GMV and AQ scores in subcortical brain regions including the left putamen and right putamen. Additionally, we found significant negative association between regional GMV and AQ in the right orbitofrontal cortex which also extended to the anterior cingulate gyrus. (Figs. 3 and 4, Table 3).

4.3. Tract based spatial statistics

We found a positive association between MD and AQ in the superior longitudinal fasciculus, inferior longitudinal fasciculus, inferior fronto-occipital fasciculus and corpus callosum (forceps major and splenium). In addition, we also found a negative association between FA and AQ in the superior longitudinal fasciculus, inferior longitudinal fasciculus, inferior fronto-occipital fasciculus and corticospinal tract in the combined sample of neurotypicals and individuals with ASD (Fig. 5). However, none of these clusters survived after correcting for multiple comparisons using threshold-free cluster enhancement (TFCE) ($p < 0.05$, uncorrected) (Table 4).

5. Discussion

In the current study, we tested the relationship between the regional grey matter properties, white matter microstructure and autistic traits in a mixed sample with adults including neurotypicals and individuals with a clinical diagnosis of autism. Our results demonstrated that autistic traits were significantly associated with multiple metrics of regional grey matter (cortical thickness, surface area, gyrification and volume) that spanned the social brain regions. These findings were consistent with brain structural findings from previous studies that used a case-control design (Ecker et al., 2012; Sato et al., 2017; Shukla et al., 2011). Considering ASD as a unitary and rigid category lacks biological

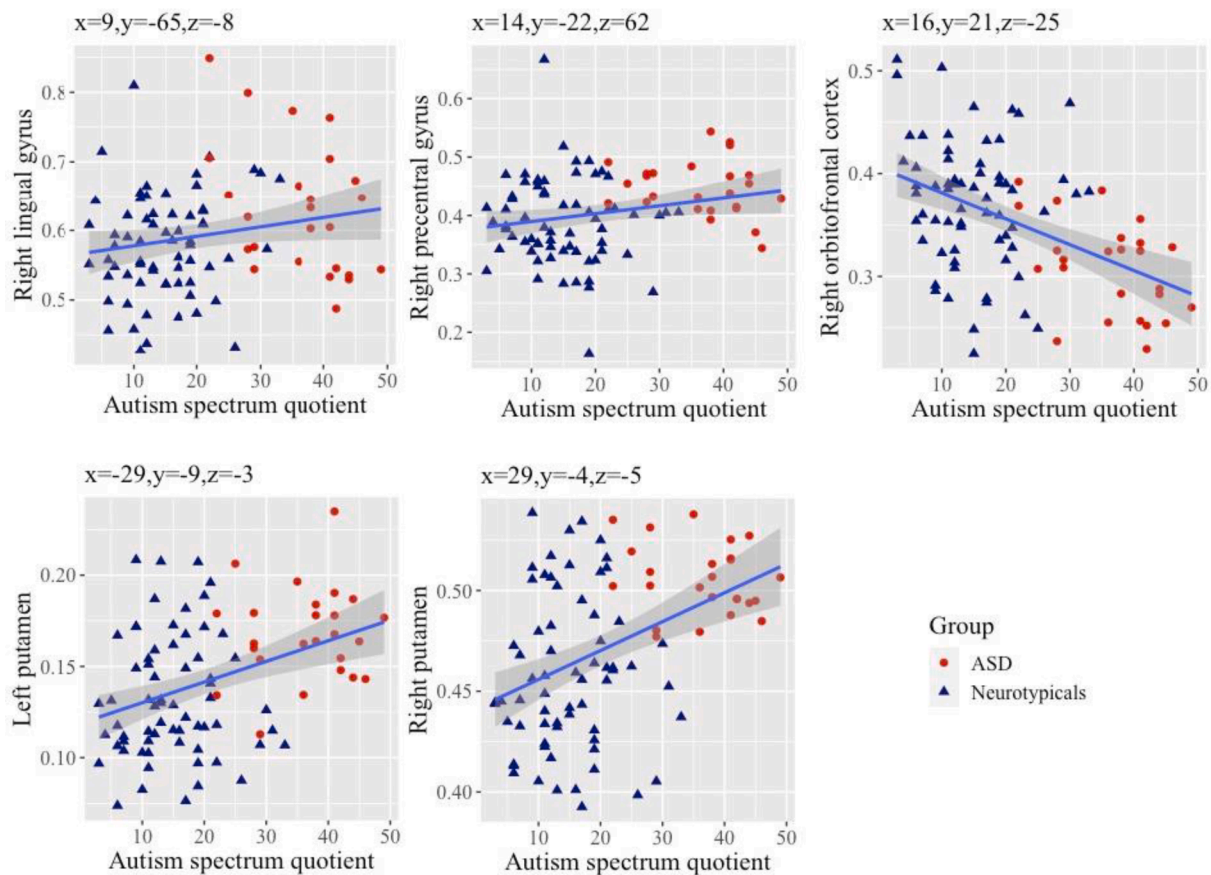


Fig. 4. Scatterplots showing significant positive association between GMV of different brain regions including right lingual gyrus, right precentral gyrus, left and right putamen with AQ scores. Scatterplot showing significant negative association between right orbitofrontal cortex GMV and AQ scores.

Table 3
Brain regions displaying the association between cortical and subcortical GMV and AQ.

Cortical brain regions	Hem	MNI-Coordinates			K	P _{FWE}
		x	y	z		
Positive association						
Lingual gyrus	R	9	-65	-8	8010	<0.001***
Precentral gyrus	R	14	-22	62	6918	0.012**
Negative association						
Orbitofrontal cortex	R	16	21	-25	7888	<0.001***
Subcortical brain regions						
Positive association						
Putamen	L	-29	-9	-3	2837	<0.001***
Putamen	R	29	-4	-5	2459	<0.001***

Abbreviations: Level of significance *p < .05, **p < .01, ***p < .001, Hem - Hemisphere, FWE- Family Wise Error and K- Cluster size.

validity. Some individuals with higher autistic traits may fall short of meeting the cut-off scores to meet the diagnostic criteria for ASD. Nevertheless, such individuals with autistic traits share similar aetiology seen in individuals diagnosed with ASD. A dimensional approach focused on autistic traits distributed through the population offers a more inclusive and potentially more informative approach to investigate the underlying biology.

We discovered significant regional grey matter variations in the key social brain regions in the frontal lobe related to higher autistic traits. These findings include reduced regional GMV in the right orbitofrontal cortex and increased cortical thickness in the right pars triangularis. The reduced regional GMV in the orbitofrontal cortex may be underpinned by fewer minicolumns in the frontal lobes demonstrated in post-mortem

studies (Buxhoeveden et al., 2006; Casanova et al., 2006). The regional GMV differences in the orbitofrontal cortex has previously been suggested to be related to observed behavioural differences in theory of mind (ToM) in individuals with ASD (Frith and Frith, 2001; Lewis et al., 2011; Sabbagh, 2004). Individuals with higher autistic traits might have social skill difficulties such as interpreting self-thoughts and interpreting other's intentions (Girgis et al., 2007; Mundy, 2003). The greater cortical thickness in the pars triangularis may be related to the expressive language deficits noted in some individuals with ASD (Knaus et al., 2018). The pars triangularis may cross-talk with the other social brain region (pars orbitalis) closely located in the frontal lobe, which may also account for the social communication difficulties related to higher autistic traits (Fishman et al., 2014).

Greater GMV in the precentral gyrus (in the right hemisphere) was associated with higher autistic traits. This finding is consistent with previous studies in ASD relative to controls (Bonilha et al., 2008; Ecker et al., 2012; Rojas et al., 2006). The precentral gyrus is believed to be an integral part of an action observation network/mirror neuron system (Hadjikhani et al., 2006). Increased GMV in the precentral gyrus may underlie atypical visuomotor learning in individuals with higher autistic traits (Mahajan et al., 2016; Carper and Courchesne, 2005; Nebel et al., 2014). We also found increased regional GMV in the bilateral putamen related to higher autistic traits. This finding is consistent with regional GMV variations in putamen in ASD from previous studies (Hollander et al., 2005; Langen et al., 2009; Nickl-Jockschat et al., 2012). The putamen, an integral part of the dorsal striatum, plays a key role in restricted and repetitive behaviour in ASD (Langen et al., 2012; Sato et al., 2014). Such regional GMV variations in putamen may influence the striatum volume which may underlie atypical behavioural manifestations such as insistence to sameness and complex motor functions in

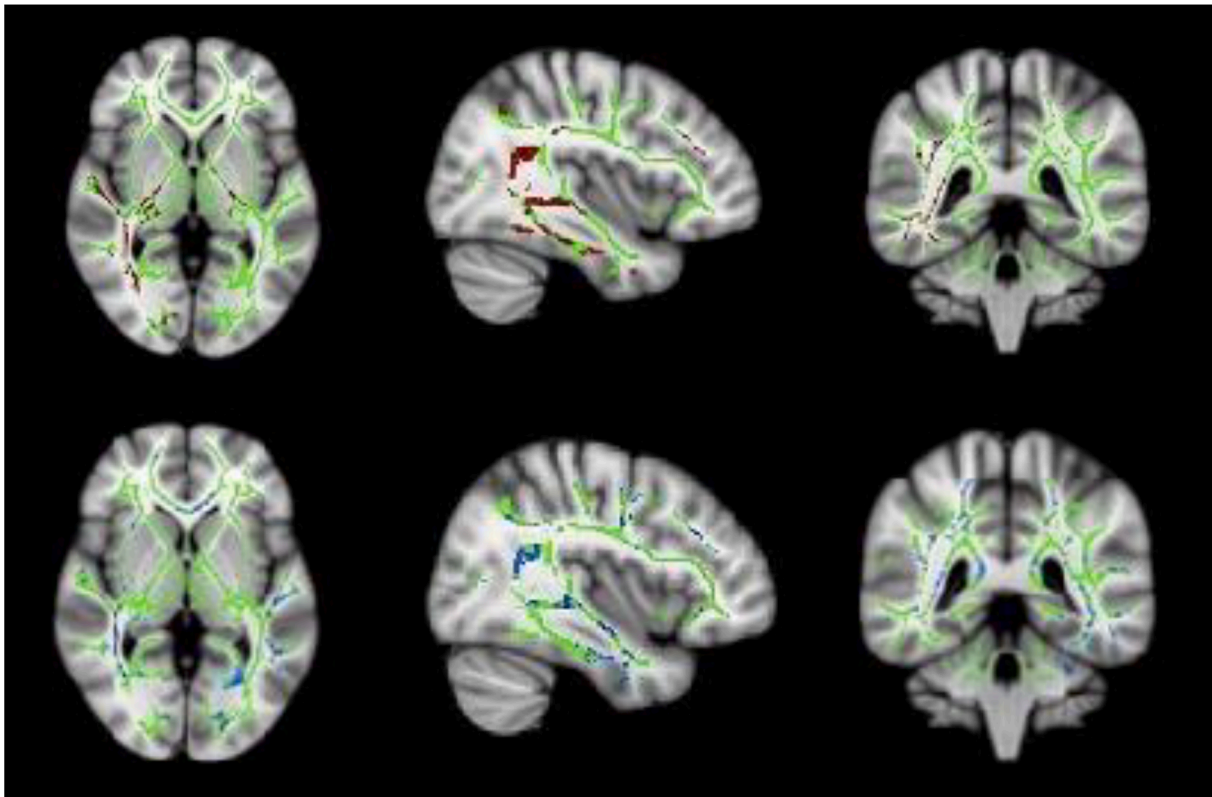


Fig. 5. Whole white matter skeleton (green) display, showing negative association between fractional anisotropy (clusters in red, first row) with AQ and positive association between mean diffusivity (clusters in blue, second row) with AQ (4). (For interpretation of the references to colour in this figure legend, the reader is referred to the web version of this article.)

Table 4
Association between fractional anisotropy and mean diffusivity and AQ.

White matter tracts	Hem	MNI coordinates			K	P-values
		x	y	z		
Fractional anisotropy						
Superior longitudinal fasciculus	R	40	-48	8	266	0.04
Inferior longitudinal fasciculus	R	49	-24	-22	2837	0.04
Inferior fronto-occipital fasciculus	R	26	-24	-5	118	0.03
Corticospinal tract	L	-17	-12	-4	300	0.05
Mean diffusivity						
Superior longitudinal fasciculus	R	57	-42	-7	135	0.05
Inferior longitudinal fasciculus	R	38	5	-36	105	0.03
Inferior fronto-occipital fasciculus	R	36	-54	4	129	0.03
Corpus callosum (Forceps major)		6	-37	13	473	0.03

Abbreviations: K- Cluster size, L- Left, R- Right, FA- Fractional Anisotropy, MD- Mean Diffusivity, Hem-Hemisphere, P-values - uncorrected.

individuals with ASD (Calderoni et al., 2014; Eisenberg et al., 2015; Schuetze et al., 2016). These common sites of brain structural variations in the striatum may underlie the stereotyped behaviours in individuals

with ASD (Eisenberg et al., 2015; Schuetze et al., 2016) which may also be related to higher autistic traits.

The lingual gyrus in the right hemisphere demonstrated increased gyrification and regional grey matter volume related to higher autistic traits. In addition, lingual gyrus in the left hemisphere demonstrated increased cortical thickness. This evidence is consistent with previous reports of structural atypicalities, with greater local gyrification and grey matter volume in lingual gyrus in individuals with ASD (Libero et al., 2019; Peterson et al., 2006). In addition, the right lateral occipital cortex showed cortical thickness and increased surface area which may result in difficulties when modulating the visual perceptual abilities (Ecker et al., 2010a; Ecker et al., 2010b). Lingual gyrus constitutes part of a network, including other brain regions (lateral occipital cortex, fusiform gyrus and posterior superior temporal sulcus) that play a significant role in object/face recognition and following biological motion cues in ASD (Ecker et al., 2015). The lateral occipital cortex is believed to play a significant role in visuospatial attention in individuals with ASD (Ecker et al., 2013; Nickl-Jockschat et al., 2012). The greater volume and gyrification of the lingual gyrus and lateral occipital cortex may underlie the atypical visual processing in individuals with higher autistic symptoms (Keehn et al., 2008).

The regional variations in intrinsic grey matter properties may arise from differences in neuronal migration within the radial minicolumns which may be altered in individuals with ASD/higher autistic traits (Casanova and Trippe, 2009). This aberrant cortical cytoarchitecture may be indexed by an increased number of minicolumns, reduced alignment and increased density of pyramidal neuronal cells - and may be a key factor associated with the atypical cortico-cortical connectivity in ASD. These developmental neurobiological processes may underlie the observed pattern of brain structural metrics in the pars triangularis, lateral occipital and lingual gyrus that are associated with higher autistic traits. Our findings from VBM and SBM study supports the evidence for

variations in regional brain volume and atypical cortico-cortical connectivity hypothesis in ASD.

Notably, there are some methodological differences between VBM and SBM (topographical and voxel-wise comparison respectively) in measuring cortical morphometry (Hyde et al., 2010; Jiao et al., 2010; Pappaiani et al., 2018). These two analytical approaches (VBM and SBM) are incomparable when measuring the cortical thickness, surface area and gyrification because their principles and implementation are distinct from one another. SBM provides us with a higher reliability in measuring the cortical thickness, surface and gyrification, whereas the VBM (DARTEL) provides us with a high dimensional spatial registration for measuring regional grey matter volume in ASD. In addition, VBM helps us to measure the regional GMV in the subcortical structures unlike SBM. Together, VBM and SBM are the two complementary approaches that contribute to the efforts in identifying a neuroimaging endophenotype for ASD.

While none of the DTI results survived a test for multiple comparisons, the findings from the DTI study were convergent with those from the SBM study. The SBM study found atypicalities in the lingual gyrus, which is connected to the ventral visual stream through the ILF and IFOF. These findings suggest that the co-occurrence of grey matter variations of these brain regions (lingual gyrus and lateral occipital cortex) and atypical white matter microstructure integrity of inferior longitudinal fasciculus (ILF) and inferior fronto-occipital fasciculus (IFOF) may underlie the sensory atypicalities in individuals with higher autistic traits (Itahashi et al., 2015). In addition, the white matter microstructure variations in the superior longitudinal fasciculus (SLF) (connected to the pars triangularis and Wernicke's area) may impose difficulties in acquiring language skills may be associated with autistic symptoms (Fitzgerald et al., 2018). Future studies should test these speculations by combining behavioural phenotyping and structural neuroimaging, ideally in longitudinal cohorts.

The results discussed above needs to be interpreted with caveats. Though larger than majority of neuroimaging studies typically reported, sample sizes of $N = 91$ is small/moderate for using a dimensional approach. Second, the DTI data was available only from a subset of the individuals ($N = 53$), thus reducing the power for statistical inferences.

6. Conclusion

The regional grey matter variations in the orbitofrontal cortex and pars triangularis, dorsal striatum and ventral visual stream were found to be associated with higher autistic traits. These observations are consistent with previous results reported in case-control studies of ASD, and demonstrate the value of using a dimensional approach. The approach used in this study is consistent with the framework suggested by the RDoC framework (Insel et al., 2010), and has already shown promise in similar studies on the depression and anxiety spectrum (Besteher et al., 2020). For this approach to be truly transdiagnostic, future studies should extend such studies to include larger samples, including individuals with a greater diversity of clinical diagnoses.

Funding

This research was funded by a grant to BC from the Medical Research Council UK (Ref: G1100359/1). VAC was supported by the Felix Scholarship during the period of this work.

CRedit authorship contribution statement

Varun Arunachalam Chandran: Formal analysis, Investigation, Methodology, Visualization, Writing – original draft. **Christos Pliatsikas:** Supervision, Validation, Methodology, Writing – review & editing. **Janina Neufeld:** Investigation, Resources. **Garret O'Connell:** Investigation, Resources. **Anthony Haffey:** Investigation, Resources. **Vincent DeLuca:** Resources, Methodology. **Bhismadev Chakrabarti:**

Conceptualization, Funding acquisition, Methodology, Project administration, Supervision, Writing – review & editing.

Declaration of Competing Interest

The authors declare that they have no known competing financial interests or personal relationships that could have appeared to influence the work reported in this paper.

References

- American Psychiatric Association, 2013. Diagnostic and Statistical Manual of Mental Disorders (DSM-5®). American Psychiatric Pub. <https://play.google.com/store/boos/details?id=JivBAAQBAJ>.
- Aoki, Y., Abe, O., Nippashi, Y., Yamasue, H., 2013. Comparison of white matter integrity between autism spectrum disorder subjects and typically developing individuals: a meta-analysis of diffusion tensor imaging tractography studies. *Mol. Autism* 4 (1), 1–17. <https://doi.org/10.1186/2040-2392-4-25>.
- Ashburner, J., Friston, K.J., 2000. Voxel-based morphometry—the methods. *Neuroimage* 11 (6), 805–821.
- Ashburner, J., 2010. VBM tutorial. Tech. rep. Wellcome Trust Centre for Neuroimaging, London, UK <https://www.fil.ion.ucl.ac.uk/~john/misc/VBMclass15.pdf>.
- Barnea-Goraly, N., Kwon, H., Menon, V., Eliez, S., Lotspeich, L., Reiss, A.L., 2004. White matter structure in autism: preliminary evidence from diffusion tensor imaging. *Biol. Psychiatr.* 55 (3), 323–326. <https://doi.org/10.1016/j.biopsych.2003.10.022>.
- Baron-Cohen, S., Wheelwright, S., Skinner, R., Martin, J., Clubley, E., 2001. The autism-spectrum quotient (AQ): Evidence from asperger syndrome/high-functioning autism, males and females, scientists and mathematicians. *J. Autism Dev. Disord.* 31 (1), 5–17.
- Besteher, B., Gaser, C., Nenadić, I., 2020. Brain structure and subclinical symptoms: a dimensional perspective of psychopathology in the depression and anxiety spectrum. *Neuropsychobiology* 79 (4-5), 270–283.
- Boddaert, N., Chabane, N., Gervais, H., Good, C.D., Bourgeois, M., Plumet, M.-H., Barthélémy, C., Mouren, M.-C., Artiges, E., Samson, Y., Brunelle, F., Frackowiak, R.S.J., Zilbovicius, M., 2004. Superior temporal sulcus anatomical abnormalities in childhood autism: a voxel-based morphometry MRI study. *NeuroImage* 23 (1), 364–369. <https://doi.org/10.1016/j.neuroimage.2004.06.016>.
- Boets, B., Van Eylen, L., Sitek, K., Moors, P., Noens, I., Steyaert, J., Sunaert, S., Wagemans, J., 2018. Alterations in the inferior longitudinal fasciculus in autism and associations with visual processing: a diffusion-weighted MRI study. *Mol. Autism* 9, 10. <https://doi.org/10.1186/s13229-018-0188-6>.
- Bonilha, L., Cendes, F., Rorden, C., Eckert, M., Dalgallardo, P., Li, L.M., Steiner, C.E., 2008. Gray and white matter imbalance—typical structural abnormality underlying classic autism? *Brain Dev.* 30 (6), 396–401. <https://doi.org/10.1016/j.braindev.2007.11.006>.
- Brothers, L., 1990. The social brain : A project for integrating primate behaviour and neurophysiology in a new domain. *Concepts Neurosci*, 1, 27–51. <https://ci.nii.ac.jp/naid/20000695363/>.
- Buxhoeveden, D.P., Semendeferi, K., Buckwalter, J., Schenker, N., Switzer, R., Courchesne, E., 2006. Reduced minicolumns in the frontal cortex of patients with autism. *Neuropathol. Appl. Neurobiol.* 32 (5), 483–491. <https://doi.org/10.1111/nan.2006.32.issue-510.1111/j.1365-2990.2006.00745.x>.
- Calderoni, S., Bellani, M., Hardan, A.Y., Muratori, F., Brambilla, P., 2014. Basal ganglia and restricted and repetitive behaviours in Autism Spectrum Disorders: current status and future perspectives. *Epidemiol. Psychiatr. Sci.* 23 (3), 235–238. <https://doi.org/10.1017/S2045796014000171>.
- Carper, R.A., Courchesne, E., 2005. Localized enlargement of the frontal cortex in early autism. *Biol. Psychiatr.* 57 (2), 126–133. <https://doi.org/10.1016/j.biopsych.2004.11.005>.
- Casanova, M., Trippe, J., 2009. Radial cytoarchitecture and patterns of cortical connectivity in autism. *Philos. Trans. Royal Soc. Lond. Ser. B Biol. Sci.* 364 (1522), 1433–1436. <https://doi.org/10.1098/rstb.2008.0331>.
- Casanova, Manuel F., van Kooten, Imke A.J., Switala, Andrew E., van Engeland, Herman, Heinsen, Helmut, Steinbusch, Harry W.M., Hof, Patrick R., Trippe, Juan, Stone, Janet, Schmitz, Christoph, 2006. Minicolumnar abnormalities in autism. *Acta Neuropathol.* 112 (3), 287–303. <https://doi.org/10.1007/s00401-006-0085-5>.
- Catani, Marco, Dell'Acqua, Flavio, Budisavljevic, Sanja, Howells, Henrietta, Thiebaut de Schotten, Michel, Froudist-Walsh, Seán, D'Anna, Lucio, Thompson, Abigail, Sandrone, Stefano, Bullmore, Edward T., Suckling, John, Baron-Cohen, Simon, Lombardo, Michael V., Wheelwright, Sally J., Chakrabarti, Bhismadev, Lai, Meng-Chuan, Ruirok, Amber N.V., Leemans, Alexander, Ecker, Christine, Consortium, MRC AIMS, Craig, Michael C., Murphy, Declan G.M., 2016. Frontal networks in adults with autism spectrum disorder. *Brain: A J. Neurol.* 139 (2), 616–630. <https://doi.org/10.1093/brain/awv351>.
- Cauda, F., Costa, T., Palermo, S., D'Agata, F., Diano, M., Bianco, F., Duca, S., Keller, R., 2014. Concordance of white matter and gray matter abnormalities in autism spectrum disorders: a voxel-based meta-analysis study: Concordance of WM and GM Abnormalities in ASD. *Hum. Brain Mapp.* 35 (5), 2073–2098. <https://doi.org/10.1002/hbm.22313>.
- Coalson, T.S., Van Essen, D.C., Glasser, M.F., 2018. The impact of traditional neuroimaging methods on the spatial localization of cortical areas. *PNAS* 115 (27), E6356–E6365. <https://doi.org/10.1073/pnas.1801582115>.

- Courchesne, E., Carper, R., Akshoomoff, N., 2003. Evidence of brain overgrowth in the first year of life in autism. *JAMA: J. Am. Med. Assoc.* 290 (3), 337–344. <https://doi.org/10.1001/jama.290.3.337>.
- Courchesne, E., Karns, C.M., Davis, H.R., Ziccardi, R., Carper, R.A., Tigue, Z.D., Chisum, H.J., Moses, P., Pierce, K., Lord, C., Lincoln, A.J., Pizzo, S., Schreibman, L., Haas, R.H., Akshoomoff, N.A., Courchesne, R.Y., 2001. Unusual brain growth patterns in early life in patients with autistic disorder: an MRI study. *Neurology* 57 (2), 245–254. <https://doi.org/10.1212/wnl.57.2.245>.
- Ecker, C., Bookheimer, S.Y., Murphy, D.G., 2015. Neuroimaging in autism spectrum disorder: brain structure and function across the lifespan. *Lancet Neurol.* 14 (11), 1121–1134. [https://doi.org/10.1016/S1474-4422\(15\)00050-2](https://doi.org/10.1016/S1474-4422(15)00050-2).
- Ecker, Christine, Gineset, Cedric, Feng, Yue, Johnston, Patrick, Lombardo, Michael V., Lai, Meng-Chuan, Suckling, John, Palaniyappan, Lena, Daly, Eileen, Murphy, Clodagh M., Williams, Steven C., Bullmore, Edward T., Baron-Cohen, Simon, Brammer, Michael, Murphy, Declan G.M., MRC AIMS Consortium, for the, 2013. Brain surface anatomy in adults with autism: the relationship between surface area, cortical thickness, and autistic symptoms. *JAMA Psychiatr.* 70 (1), 59. <https://doi.org/10.1001/jamapsychiatry.2013.265>.
- Ecker, Christine, Rocha-Rego, Vanessa, Johnston, Patrick, Mourao-Miranda, Janaina, Marquand, Andre, Daly, Eileen M., Brammer, Michael J., Murphy, Clodagh, Murphy, Declan G., 2010a. Investigating the predictive value of whole-brain structural MR scans in autism: a pattern classification approach. *NeuroImage* 49 (1), 44–56. <https://doi.org/10.1016/j.neuroimage.2009.08.024>.
- Ecker, C., Suckling, J., Deoni, S.C., Lombardo, M.V., Bullmore, E.T., Baron-Cohen, S., Catani, M., Jezzard, P., Barnes, A., Bailey, A.J., Williams, S.C., Murphy, D.G.M., MRC AIMS Consortium, 2012. Brain anatomy and its relationship to behavior in adults with autism spectrum disorder: a multicenter magnetic resonance imaging study. *Arch. Gen. Psychiatr.* 69 (2), 195–209. <https://doi.org/10.1001/archgenpsychiatry.2011.1251>.
- Ecker, C., Marquand, A., Mourao-Miranda, J., Johnston, P., Daly, E.M., Brammer, M.J., Maltzios, S., Murphy, C.M., Robertson, D., Williams, S.C., Murphy, D.G.M., 2010b. Describing the brain in autism in five dimensions—magnetic resonance imaging-assisted diagnosis of autism spectrum disorder using a multiparameter classification approach. *J. Neurosci.* 30 (32), 10612–10623. <https://doi.org/10.1523/JNEUROSCI.5413-09.2010>.
- Eisenberg, I.W., Wallace, G.L., Kenworthy, L., Gotts, S.J., Martin, A., 2015. Insistence on sameness relates to increased covariance of gray matter structure in autism spectrum disorder. *Mol. Autism* 6, 54. <https://doi.org/10.1186/s13229-015-0047-7>.
- Fischl, Bruce, 2012. FreeSurfer. *NeuroImage* 62 (2), 774–781. <https://doi.org/10.1016/j.neuroimage.2012.01.021>.
- Fishman, Inna, Keown, Christopher L., Lincoln, Alan J., Pineda, Jaime A., Müller, Ralph-Axel, 2014. Atypical Cross Talk Between Mentalizing and Mirror Neuron Networks in Autism Spectrum Disorder. *JAMA Psychiatr.* 71 (7), 751. <https://doi.org/10.1001/jamapsychiatry.2014.83>.
- Fitzgerald, J., Leemans, A., Kehoe, E., O'Hanlon, E., Gallagher, L., McGrath, J., 2018. Abnormal fronto-parietal white matter organisation in the superior longitudinal fasciculus branches in autism spectrum disorders. *Eur. J. Neurosci.* 47 (6), 652–661. <https://doi.org/10.1111/ejn.13655>.
- Frith, U., Frith, C., 2001. The Biological Basis of Social Interaction. *Curr. Directions Psychol.* 10 (5), 151–155. <https://doi.org/10.1111/1467-8721.00137>.
- Girgis, R.R., Minshew, N.J., Melhem, N.M., Nutsche, J.J., Keshavan, M.S., Hardan, A.Y., 2007. Volumetric alterations of the orbitofrontal cortex in autism. *Prog. Neuro-Psychopharmacol. Biol. Psychiatr.* 31 (1), 41–45. <https://doi.org/10.1016/j.pnpbp.2006.06.007>.
- Groen, W.B., Buitelaar, J.K., van der Gaag, R.J., Zwiers, M.P., 2011. Pervasive microstructural abnormalities in autism: a DTI study. *J. Psychiatr. Neurosci.: JPN* 36 (1), 32–40. <https://doi.org/10.1503/jpn.091010>.
- Hadjikhani, N., Joseph, R.M., Snyder, J., Tager-Flusberg, H., 2006. Anatomical differences in the mirror neuron system and social cognition network in autism. *Cereb. Cortex* 16 (9), 1276–1282. <https://doi.org/10.1093/cercor/bhj069>.
- Hardan, A.Y., Girgis, R.R., Lacerda, A.L.T., Yorbik, O., Kilpatrick, M., Keshavan, M.S., Minshew, N.J., 2006. Magnetic resonance imaging study of the orbitofrontal cortex in autism. *J. Child Neurol.* 21 (10), 866–871. <https://doi.org/10.1177/08830738060210100701>.
- Hardan, A.Y., Minshew, N.J., Mallikarjun, M., Keshavan, M.S., 2001. Brain Volume in Autism. *J. Child Neurol.* 16 (06), 421. <https://doi.org/10.2310/7010.2001.7113>.
- Hollander, E., Anagnostou, E., Chaplin, W., Esposito, K., Haznedar, M.M., Licalzi, E., Wasserman, S., Soorya, L., Buchsbaum, M., 2005. Striatal volume on magnetic resonance imaging and repetitive behaviors in autism. *Biol. Psychiatr.* 58 (3), 226–232. <https://doi.org/10.1016/j.biopsych.2005.03.040>.
- Hsu, Chun-Ting, Neufeld, Janina, Chakrabarti, Bhismadev, 2018a. Reduced reward-related neural response to mimicry in individuals with autism. *Eur. J. Neurosci.* 47 (6), 610–618.
- Hsu, Chun-Ting, Sims, Thomas, Chakrabarti, Bhismadev, 2018b. How mimicry influences the neural correlates of reward: An fMRI study. *Neuropsychologia* 116, 61–67.
- Hyde, K.L., Samson, F., Evans, A.C., Mottron, L., 2010. Neuroanatomical differences in brain areas implicated in perceptual and other core features of autism revealed by cortical thickness analysis and voxel-based morphometry. *Hum. Brain Mapp.* 31 (4), 556–566. <https://doi.org/10.1002/hbm.20887>.
- Insel, T., Cuthbert, B., Garvey, M., Heinssen, R., Pine, D. S., Quinn, K., et al., 2010. Research domain criteria (RDoC): toward a new classification framework for research on mental disorders.
- Itahashi, T., Yamada, T., Nakamura, M., Watanabe, H., Yamagata, B., Jimbo, D., Shioda, S., Kuroda, M., Toriizuka, K., Kato, N., Hashimoto, R., 2015. Linked alterations in gray and white matter morphology in adults with high-functioning autism spectrum disorder: A multimodal brain imaging study. *NeuroImage: Clin.* 7, 155–169. <https://doi.org/10.1016/j.nicl.2014.11.019>.
- Jiao, Y., Chen, R., Ke, X., Chu, K., Lu, Z., Herskovits, E.H., 2010. Predictive models of autism spectrum disorder based on brain regional cortical thickness. *NeuroImage* 50 (2), 589–599. <https://doi.org/10.1016/j.neuroimage.2009.12.047>.
- Keeshan, B., Brenner, L., Palmer, E., Lincoln, A.J., Müller, R.-A., 2008. Functional brain organization for visual search in ASD. *J. Int. Neuropsychol. Soc.: JINS* 14 (6), 990–1003. <https://doi.org/10.1017/S1355617708081356>.
- Knaus, T.A., Kamps, J., Foundas, A.L., Tager-Flusberg, H., 2018. Atypical PT anatomy in children with autism spectrum disorder with expressive language deficits. *Brain Imag. Behav.* 12 (5), 1419–1430. <https://doi.org/10.1007/s11682-017-9795-7>.
- Langen, M., Leemans, A., Johnston, P., Ecker, C., Daly, E., Murphy, C.M., dell'Acqua, F., Durston, S., Murphy, D.G.M., 2012. Fronto-striatal circuitry and inhibitory control in autism: Findings from diffusion tensor imaging tractography. *Cortex* 48 (2), 183–193. <https://doi.org/10.1016/j.cortex.2011.05.018>.
- Langen, M., Schnack, H.G., Nederveen, H., Bos, D., Lahuis, B.E., de Jonge, M.V., van Engeland, H., Durston, S., 2009. Changes in the developmental trajectories of striatum in autism. *Biol. Psychiatr.* 66 (4), 327–333. <https://doi.org/10.1016/j.biopsych.2009.03.017>.
- Lee, J.E., Bigler, E.D., Alexander, A.L., Lazar, M., DuBray, M.B., Chung, M.K., Johnson, M., Morgan, J., Miller, J.N., McMahon, W.M., Lu, J., Jeong, E.-K., Lainhart, J.E., 2007. Diffusion tensor imaging of white matter in the superior temporal gyrus and temporal stem in autism. *Neurosci. Lett.* 424 (2), 127–132. <https://doi.org/10.1016/j.neulet.2007.07.042>.
- Lewis, P.A., Rezaie, R., Brown, R., Roberts, N., Dunbar, R.I.M., 2011. Ventromedial prefrontal volume predicts understanding of others and social network size. *NeuroImage* 57 (4), 1624–1629. <https://doi.org/10.1016/j.neuroimage.2011.05.030>.
- Libero, L.E., Schaefer, M., Li, D.D., Amaral, D.G., Nordahl, C.W., 2019. A Longitudinal Study of Local Gyrfication Index in Young Boys With Autism Spectrum Disorder. *Cereb. Cortex* 29 (6), 2575–2587. <https://doi.org/10.1093/cercor/bhy126>.
- Lisiecka, D. M., Holt, R., Tait, R., Ford, M., Lai, M.-C., Chura, L. R., Baron-Cohen, S., Spencer, M. D., Suckling, J., 2015. Developmental white matter microstructure in autism phenotype and corresponding endophenotype during adolescence. *Transl. Psychiatr.* 5, e529. <https://doi.org/10.1038/tp.2015.23>.
- Lord, C., Risi, S., Lambrecht, L., Cook, E.H., Leventhal, B.L., DiLavore, P.C., Rutter, M., 2000. The Autism Diagnostic Observation Schedule—Generic: A standard measure of social and communication deficits associated with the spectrum of autism. *J. Autism Dev. Disord.* 30 (3), 205–223.
- Mahajan, R., Dirlikov, B., Crocetti, D., Mostofsky, S.H., 2016. Motor Circuit Anatomy in Children with Autism Spectrum Disorder With or Without Attention Deficit Hyperactivity Disorder. *Aut. Res.: Off. J. Int. Soc. Aut. Res.* 9 (1), 67–81. <https://doi.org/10.1002/aur.1497>.
- Mosconi, M.W., Cody-Hazlett, H., Poe, M.D., Gerig, G., Gimpel-Smith, R., Piven, J., 2009. Longitudinal study of amygdala volume and joint attention in 2-to 4-year-old children with autism. *Arch. Gen. Psychiatr.* 66 (5), 509–516.
- Mueller, Sophia, Keeser, Daniel, Samson, Andrea C., Kirsch, Valerie, Blautz, Janusch, Grothe, Michel, Erat, Okan, Hegenloh, Michael, Coates, Ute, Reiser, Maximilian F., Hennig-Fast, Kristina, Meindl, Thomas, Draganski, Bogdan, 2013. Convergent Findings of Altered Functional and Structural Brain Connectivity in Individuals with High Functioning Autism: A Multimodal MRI Study. *PLoS ONE* 8 (6), e67329. <https://doi.org/10.1371/journal.pone.0067329>.
g00110.1371/journal.pone.0067329.g00210.1371/journal.pone.0067329.g00310.1371/journal.pone.0067329.g00410.1371/journal.pone.0067329.t00110.1371/journal.pone.0067329.t00210.1371/journal.pone.0067329.t00310.1371/journal.pone.0067329.s001.
- Mundy, P., 2003. Annotation: The neural basis of social impairments in autism: The role of the dorsal medial-frontal cortex and anterior cingulate system. *J. Child Psychol. Psychiatr.* 44 (6), 793–809.
- Mundy, P., 2018. A review of joint attention and social-cognitive brain systems in typical development and autism spectrum disorder. *Eur. J. Neurosci.* 47 (6), 497–514. <https://doi.org/10.1111/ejn.13720>.
- Nebel, M.B., Eloyan, A., Barber, A.D., Mostofsky, S.H., 2014. Precentral gyrus functional connectivity signatures of autism. *Front. Syst. Neurosci.* 8, 80. <https://doi.org/10.3389/fnsys.2014.00080>.
- Neufeld, J., Hsu, C.T., Chakrabarti, B., 2019. Atypical reward-driven modulation of mimicry-related neural activity in autism. *Front. Psychiatr.* 10, 327.
- Nickl-Jockschat, Thomas, Habel, Ute, Maria Michel, Tanja, Manning, Janessa, Laird, Angela R., Fox, Peter T., Schneider, Frank, Eickhoff, Simon B., 2012. Brain structure anomalies in autism spectrum disorder—A meta-analysis of VBM studies using anatomic likelihood estimation. *Hum. Brain Mapp.* 33 (6), 1470–1489. <https://doi.org/10.1002/hbm.v33.6.1002/hbm.21299>.
- Nordahl, C.W., Scholz, R., Yang, X., Buonocore, M.H., Simon, T., Rogers, S., Amaral, D. G., 2012. Increased rate of amygdala growth in children aged 2 to 4 years with autism spectrum disorders: a longitudinal study. *Arch. Gen. Psychiatr.* 69 (1), 53–61.
- Pappaiani, E., Siugzdaitė, R., Vettori, S., Venuti, P., Job, R., Grecucci, A., 2018. Three shades of grey: detecting brain abnormalities in children with autism using source-, voxel- and surface-based morphometry. *Eur. J. Neurosci.* 47 (6), 690–700. <https://doi.org/10.1111/ejn.13704>.
- Pelphrey, K.A., Shultz, S., Hudac, C.M., Vander Wyk, B.C., 2011. Research review: Constraining heterogeneity: the social brain and its development in autism spectrum disorder. *J. Child Psychol. Psychiatr.* 52 (6), 631–644. <https://doi.org/10.1111/j.1469-7610.2010.02349.x>.
- Peterson, E., Schmidt, G.L., Tregellas, J.R., Winterrowd, E., Kopeloff, L., Hepburn, S., Reite, M., Rojas, D.C., 2006. A voxel-based morphometry study of gray matter in

- parents of children with autism. *NeuroReport* 17 (12), 1289–1292. <https://doi.org/10.1097/01.wnr.0000233087.15710.87>.
- Rippon, Gina, Brock, Jon, Brown, Caroline, Boucher, Jill, 2007. Disordered connectivity in the autistic brain: challenges for the “new psychophysiology”. *Int. J. Psychophysiol. Off. J. Int. Organization Psychophysiol.* 63 (2), 164–172.
- Robinson, E.B., Koenen, K.C., McCormick, M.C., Munir, K., Hallett, V., Happé, F., Plomin, R., Ronald, A., 2011. Evidence that autistic traits show the same etiology in the general population and at the quantitative extremes (5%, 2.5%, and 1%). *Arch. Gen. Psychiatr.* 68 (11), 1113–1121. <https://doi.org/10.1001/archgenpsychiatry.2011.119>.
- Rojas, D.C., Peterson, E., Winterrowd, E., Reite, M.L., Rogers, S.J., Tregellas, J.R., 2006. Regional gray matter volumetric changes in autism associated with social and repetitive behavior symptoms. *BMC Psychiatr.* 6, 56. <https://doi.org/10.1186/1471-244X-6-56>.
- Rosenblau, Gabriela, O’Connell, Garret, Heekeren, Hauke R., Dziobek, Isabel, 2020. Neurobiological mechanisms of social cognition treatment in high-functioning adults with autism spectrum disorder. *Psychol. Med.* 50 (14), 2374–2384.
- Ruzich, E., Allison, C., Smith, P., Watson, P., Auyeung, B., Ring, H., Baron-Cohen, S., 2015. Measuring autistic traits in the general population: a systematic review of the Autism-Spectrum Quotient (AQ) in a nonclinical population sample of 6,900 typical adult males and females. *Mol. Aut.* 6 (1), 1–12.
- Sabbagh, M.A., 2004. Understanding orbitofrontal contributions to theory-of-mind reasoning: implications for autism. *Brain Cogn.* 55 (1), 209–219. <https://doi.org/10.1016/j.bandc.2003.04.002>.
- Sato, W., Kochiyama, T., Uono, S., Yoshimura, S., Kubota, Y., Sawada, R., Sakihama, M., Toichi, M., 2017. Reduced Gray Matter Volume in the Social Brain Network in Adults with Autism Spectrum Disorder. *Front. Hum. Neurosci.* 11, 395. <https://doi.org/10.3389/fnhum.2017.00395>.
- Sato, W., Kubota, Y., Kochiyama, T., Uono, S., Yoshimura, S., Sawada, R., Sakihama, M., Toichi, M., 2014. Increased putamen volume in adults with autism spectrum disorder. *Front. Hum. Neurosci.* 8, 957. <https://doi.org/10.3389/fnhum.2014.00957>.
- Schuetze, M., Park, M.T.M., Cho, I.Y., MacMaster, F.P., Chakravarty, M.M., Bray, S.L., 2016. Morphological Alterations in the Thalamus, Striatum, and Pallidum in Autism Spectrum Disorder. *Neuropsychopharmacol. Off. Publ. Am. College Neuropsychopharmacol.* 41 (11), 2627–2637. <https://doi.org/10.1038/npp.2016.64>.
- Schultz, R.T., 2005. Developmental deficits in social perception in autism: the role of the amygdala and fusiform face area. *Int. J. Dev. Neurosci. Off. J. Int. Soc. Dev. Neurosci.* 23 (2–3), 125–141. <https://doi.org/10.1016/j.ijdevneu.2004.12.012>.
- Shukla, D. K., Keehn, B., & Müller, R. A. (2011). Tract-specific analyses of diffusion tensor imaging show widespread white matter compromise in autism spectrum disorder. *J. Child Psychol. Psychiatr. Allied Disciplines.*
- Smith, S.M., Jenkinson, M., Johansen-Berg, H., Rueckert, D., Nichols, T.E., Mackay, C.E., Watkins, K.E., Ciccarelli, O., Zhafer Cader, M., Matthews, P.M., Behrens, T.E.J., 2006. Tract-based spatial statistics: Voxelwise analysis of multi-subject diffusion data. *NeuroImage* 31 (4), 1487–1505. <https://doi.org/10.1016/j.neuroimage.2006.02.024>.
- Valk, S.L., Di Martino, A., Milham, M.P., Bernhardt, B.C., 2015. Multicenter mapping of structural network alterations in autism. *Hum. Brain Mapp.* 36 (6), 2364–2373. <https://doi.org/10.1002/hbm.22776>.
- Via, Esther, Radua, Joaquim, Cardoner, Narcis, Happé, Francesca, Mataix-Cols, David, 2011. Meta-analysis of gray matter abnormalities in autism spectrum disorder: should Asperger disorder be subsumed under a broader umbrella of autistic spectrum. *Arch. Gen. Psychiatr.* 68 (4), 409. <https://doi.org/10.1001/archgenpsychiatry.2011.27>.
- Wass, S., 2011. Distortions and disconnections: disrupted brain connectivity in autism. *Brain Cogn.* 75 (1), 18–28. <https://doi.org/10.1016/j.bandc.2010.10.005>.
- Whitehouse, Andrew J.O., Hickey, Martha, Ronald, Angelica, Sirigu, Angela, 2011. Are autistic traits in the general population stable across development? *PLoS ONE* 6 (8), e23029. <https://doi.org/10.1371/journal.pone.0023029>. <https://doi.org/10.1371/journal.pone.0023029.g001>. <https://doi.org/10.1371/journal.pone.0023029.g002>. <https://doi.org/10.1371/journal.pone.0023029.g003>. <https://doi.org/10.1371/journal.pone.0023029.g004>.