

A case report of subacute thyroiditis after inactivated SARS-CoV-2 vaccine

SAGE Open Medical Case Reports
Volume 10: 1–4
© The Author(s) 2022
Article reuse guidelines:
sagepub.com/journals-permissions
DOI: 10.1177/2050313X221140243
journals.sagepub.com/home/sco



Umesha Nuwanrasee Wijenayake^{id}, Gowri Malka Ratnayake,
Dilini Abeyratne^{id} and Uditha Sirimewan Bulughapitiya

Abstract

Subacute thyroiditis is an inflammatory thyroid disorder. It is often triggered following viral infections. Amid the current COVID-19 pandemic, several cases of subacute thyroiditis were reported worldwide related to SARS-CoV-2 infection and vaccines. We report a rare case of subacute thyroiditis possibly related to immunization with inactivated SARS-CoV-2 vaccine Sinopharm BIBP. A 29-year-old previously healthy Sri Lankan woman presented with anterior neck pain, low-grade fever and fatigue appearing 7 days after immunization with the second dose of inactivated SARS-CoV-2 vaccine Sinopharm BIBP. She apparently reported similar symptoms which subsided spontaneously within a few days, following immunization with first dose of vaccine. On examination, she had tenderness over the anterior neck. She was afebrile, not tachycardic and clinically euthyroid. Her inflammatory markers were elevated. An ultrasound scan of the neck demonstrated two low echogenic micronodules of 6 × 3 mm² and 5 × 3 mm² and low background thyroid vascularity. Technetium 99m pertechnetate (Tc – 99m) thyroidal uptake scan shows reduced thyroidal uptake suggestive of subacute thyroiditis. Thyroid function tests were normal at the time of the assessment. The patient was treated symptomatically with non-steroidal anti-inflammatory drugs. Her neck pain and tenderness resolved gradually. Serial measurements of thyroid functions during follow-up were within normal limits. Inflammatory markers normalized over the course of follow-up. Subacute thyroiditis following COVID-19 vaccination is a rare occurrence. However, due to its mild clinical course, it could very well be underreported. It is a mild and self-limiting illness with transient thyroid dysfunction; thus, it should be emphasized that the benefits of COVID-19 vaccination outweigh any rare and mild side effects reported.

Keywords

Subacute thyroiditis, COVID-19, inactivated virus, vaccination

Date received: 23 June 2022; accepted: 2 November 2022

Introduction

Subacute thyroiditis (SAT) is an inflammatory thyroid disorder. It is often triggered 2–8 weeks following a viral infection. Amid, the current COVID -19 pandemic, several cases of SAT related to severe acute respiratory syndrome coronavirus – 2 (SARS-CoV-2) infection were reported. Clinical manifestations of SAT include fever, anterior neck pain and transient thyrotoxic features. Several cases of SAT have been reported following viral vaccines such as hemagglutinin type 1 and neuraminidase type 1 (H1N1), hepatitis B and influenza.^{1,2}

Recently, there was a massive vaccine roll-out worldwide to combat the COVID-19 pandemic. Numerous SARS-CoV-2 vaccines were developed based on different platforms such as mRNA vaccines (Pfizer/BioNTech, Moderna), viral-vector based vaccines (ChAdOx1 nCoV-19 vaccine, Cansino

biologics, Gamaleya Research Institute, Johnson & Johnson), inactivated vaccines (CoronaVac, Sinovac Biotech, Bharat Biotech BBV 152, Sinopharm BIBP) and protein subunit based (Novax, Chinese Academy of Sciences).³

Several reports of thyroid dysfunction following SARS-CoV-2 vaccination have been published including Graves' disease and SAT.^{4–6} SAT is the most common thyroid dysfunction following SARS-CoV-2 vaccination. Globally, there are over 50 reported cases. The majority were due to mRNA-based vaccines (70%). Viral vector-based vaccines accounted for 18% of reported cases. SAT following

National Hospital of Sri Lanka, Colombo, Sri Lanka

Corresponding Author:

Umesha Nuwanrasee Wijenayake, National Hospital of Sri Lanka, Colombo 10230, Sri Lanka.
Email: umeshawijenayake@gmail.com



inactivated vaccines is a rare occurrence with only 6 reported cases following Sinovac Biotech, CoronaVac and Bharat Biotech BBV152.⁶

Females were affected predominantly with SAT following SARS-CoV-2 vaccination. The median age of presentation globally was 39.5 years. Thyrotoxicosis, primarily defined by thyroid stimulating hormone (TSH) suppression was the most common initial thyroid dysfunction (88.2%). During 4–8 weeks of follow-up, 31.6% were thyrotoxic, 42.1% were euthyroid and 26.3% were hypothyroid. Anti-thyroid peroxidase (TPO) antibody was positive in 8.7% of patients and 15.7% had anti-thyroglobulin antibody positivity.⁶

The Sinopharm BIBP vaccine acts as an inactivated vaccine. It has 78.1% efficacy against symptomatic COVID-19 infection in phase III trials.⁷ There is only a single reported case of SAT following the Sinopharm BIBP vaccine.⁸ We report a rare case of SAT possibly related to immunization with the SARS-CoV-2 vaccine Sinopharm BIBP.

Case presentation

Clinical findings

A 29-year-old previously healthy Sri Lankan woman presented to the outpatient Endocrinology clinic at the National Hospital of Sri Lanka. She complained of anterior neck pain, low-grade fever and fatigue appearing 7 days after immunization with the second dose of inactivated SARS-CoV-2 – Sinopharm vaccine in October 2021. She reported similar symptoms which subsided spontaneously within a few days, following immunization with the first dose of vaccine in July 2021.

She denied symptoms of hyperthyroidism such as palpitations, tremors, insomnia, and irritability nor symptoms of hypothyroidism such as fatigue, cold intolerance, or constipation. She has no history of thyroid disease. However, no previous laboratory investigations were available. She denied recent viral infections. COVID-19 infection was excluded during the initial presentation as she had negative serological testing. She was not treated for COVID-19 in the past. She had no family history of thyroid disease. No previous vaccine-related adverse events were noted. No previous evaluation of patients' thyroid status was made.

On examination, she had no thyromegaly. Tenderness was noted over the anterior neck. She was afebrile. Her pulse rate was 88 bpm, and her blood pressure was 110/70 mmHg. She was clinically euthyroid.

Diagnostic assessment

Her laboratory investigations 14 days after second vaccination dose revealed a TSH level of 0.43 mU/L (0.35–4.94) and free T4 of 0.9 ng/dL (0.7–2) using Advia centaur XP.

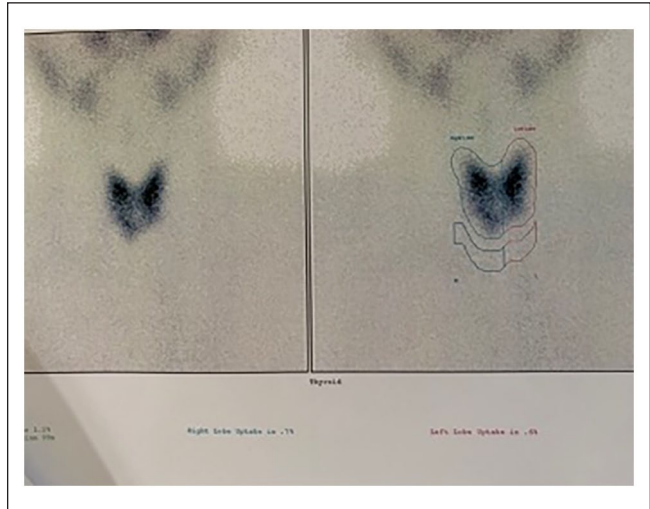


Figure 1. Tc -99 thyroidal uptake scan.

The total T3 level was not measured. Inflammatory markers were elevated. (C-reactive protein 50 mg/dl, Erythrocyte sedimentation rate 65/1st hour). The white blood cell count was normal. Anti-TPO antibody level was 1.74 IU/mL (<5.61). Anti-thyroglobulin and anti-TSH receptor antibodies were not measured. An ultrasound scan of the neck demonstrated two low echogenic micronodules (TIRADS 2) of 6 × 3 mm² and 5 × 5 mm² and low background thyroid vascularity.

Technetium 99m pertechnetate (Tc – 99m) thyroidal uptake scan shows normal tracer uptake in the upper poles of both lobes. Reduced thyroidal uptake in lower poles suggestive of subacute thyroiditis was noted (Figure 1).

Therapeutic interventions and follow-up

The patient was treated symptomatically with non-steroidal anti-inflammatory drugs (NSAIDs). Her neck pain and tenderness resolved gradually. She is currently followed up at our outpatient endocrinology clinic. Serial measurements of thyroid functions during follow-up were within normal limits. Her inflammatory markers normalized over the course of the follow-up. A detailed description of her investigations is as follows (Table 1).

Discussion

SAT is the most common thyroid dysfunction following SARS-CoV-2 vaccination. Our patient had the typical signs and symptoms of thyroiditis except for thyroid dysfunction, along with negative family history and thyroid antibodies. As reduced uptake in Tc-99m thyroidal uptake scan and a temporal association with COVID-19 immunization were noted, a diagnosis of vaccine-associated SAT

Table 1. Laboratory investigations.

Variable	Reference range Adult	Initial visit	Follow-up
Blood			
White cells (per/l)	4500–11,000	6230	5500
Neutrophils%	55–70	69	68
Lymphocytes%	20–40	23	20
Haemoglobin (g/dL)	12–16	12	13
Platelets	150,000–400,000	301,000	324,000
Erythrocyte Sedimentation Rate (first hour)	<20	65	3
C-reactive protein (mg/dl)	<6	50	2
TSH (mU/L)	0.35–4.94	0.43	1.02
Free T4 (ng/dL)	0.7–2	0.9	1.1
Anti-TPO antibody (IU/ml)	<5.61	1.74	

TSH: thyroid stimulating hormone; TPO: thyroid peroxidase.

is highly probable. To the best of our knowledge, this is the second reported case of SAT following inactivated SARS-CoV-2 vaccine Sinopharm BIBP. Thus, we feel that this case should be reported.

Contrary to most of the published cases, our patient had normal thyroid functions at the time of presentation. Notably, a thyroid function test was done 2 weeks post-vaccination. Thus, by this time, she could have very well entered the euthyroid phase of SAT.

Pathogenesis of SAT following SARS-CoV-2 vaccination is poorly understood. Several hypotheses have been postulated ranging from autoimmune inflammatory syndrome induced by adjuvants (ASIA) and molecular mimicry. Adjuvants are components of a vaccine used to increase vaccine responsiveness, and they have a role in producing diverse inflammatory and autoimmune responses in a genetically susceptible individual.⁹ Cross-reactivity between SARS-CoV-2 virus spike protein and thyroid cell antigens is postulated as the underlying mechanism in molecular mimicry. Thus, the induction of antibodies to COVID-19 spike protein with vaccination results in transient thyroiditis.¹⁰

However, it should be emphasized. That SAT following SARS-CoV-2 vaccination is a rare occurrence, in the context of billions of vaccine doses administered worldwide. The benefits of SARS-CoV-2 vaccination outweigh this very uncommon side effect. However, this condition deserves acknowledgement to provide appropriate treatment and follow-up for the affected individuals.

Conclusions

SAT following COVID-19 vaccination is a rare occurrence. However, due to its mild clinical course, it could very well be underreported. It is a mild and self-limiting illness with transient thyroid dysfunction; thus, it should be emphasized that the benefits of COVID-19 vaccination outweigh any rare and mild side effects reported.

Acknowledgements

The author(s) acknowledge the Nuclear Imaging Unit, National Hospital of Sri Lanka, Colombo.

Author contributions

UNW was involved in the preparation of the manuscript and the diagnosis and management of the patients. GMR & DA were involved in manuscript preparation and patient care. UB was involved in the diagnosis and management of the patient and supervision of the manuscript writing process.

Declaration of conflicting interests

The author(s) declared no potential conflicts of interest with respect to the research, authorship, and/or publication of this article.

Funding

The author(s) received no financial support for the research, authorship, and/or publication of this article.

Ethics approval

Our institution does not require ethical approval for reporting individual cases or case series.

Informed consent

Written informed consent was obtained from the patient(s) for their anonymized information to be published in this article.

ORCID iDs

Umesha Nuwanrasee Wijenayake  <https://orcid.org/0000-0001-5628-3749>

Dilini Abeyratne  <https://orcid.org/0000-0003-1529-2782>

References

1. Dworakowska D, Morley S, Mulholland N, et al. COVID-19-related thyroiditis: a novel disease entity? *Clin Endocrinol* 2021; 95(3): 369–377.
2. Brancatella A, Ricci D, Cappellani D, et al. Is subacute thyroiditis an underestimated manifestation of SARS-CoV-2

- infection? Insights from a case series. *J Clin Endocrinol Metab* 2020; 105(10): dgaa537.
3. Francis AI, Ghany S, Gilkes T, et al. Review of COVID-19 vaccine subtypes, efficacy and geographical distributions. *Postgrad Med J* 2022; 98(1159): 389–394.
 4. Ratnayake GM, Dworakoska D and Grossman AB. Can COVID-19 immunisation cause subacute thyroiditis? *Clin Endocrinol* 2022; 97(1): 140–141.
 5. Ruggeri RM, Giovanella L and Campenni A. SARS-CoV-2 vaccine may trigger thyroid autoimmunity: real-life experience and review of the literature. *J Endocrinol Invest* 2022; 45: 2283–2289.
 6. Ippolito S, Gallo D, Rossini A, et al. SARS-CoV-2 vaccine-associated subacute thyroiditis: insights from a systematic review. *J Endocrinol Invest* 2022; 45(6): 1189–1200.
 7. Al Kaabi N, Zhang Y, Xia S, et al. Effect of 2 inactivated SARS-CoV-2 vaccines on symptomatic COVID-19 infection in adults: a randomized clinical trial. *JAMA* 2021; 326(1): 35–45.
 8. Pi L, Lin J, Zheng Y, et al. Case report: subacute thyroiditis after receiving inactivated SARS-CoV-2 vaccine (BBIBP-CorV). *Front Med* 2022; 9: 918721.
 9. İremli BG, Şendur SN and Ünlütürk U. Three cases of subacute thyroiditis following SARS-CoV-2 vaccine: postvaccination ASIA syndrome. *J Clin Endocrinol Metab* 2021; 106(9): 2600–2605.
 10. Vojdani A, Vojdani E and Kharrazian D. Reaction of human monoclonal antibodies to SARS-CoV-2 proteins with tissue antigens: implications for autoimmune diseases. *Front Immunol* 2021; 11: 617089.