



Case Report

Fungal Periprosthetic Knee Joint Infection in a Patient with Metamizole-Induced Agranulocytosis

Sebastian Oenning, Cand Med ^{*}, Burkhard Moellenbeck, MD, Georg Gosheger, MD, Tom Schmidt-Bräkling, MD, Jan Schwarze, MD, Thomas Ackmann, MD, Kristian Nikolaus Schneider, MD, Christoph Theil, MD

Department of General Orthopedics and Tumor Orthopedics, Muenster University Hospital, Muenster, North Rhine-Westphalia, Germany

ARTICLE INFO

Article history:

Received 24 June 2020
Received in revised form
17 July 2020
Accepted 25 July 2020
Available online xxx

Keywords:

Periprosthetic infection
Agranulocytosis
Fungal infection
Candida infection
Total knee arthroplasty
Revision arthroplasty

ABSTRACT

We present the case of a 55-year-old female patient with metamizole-induced agranulocytosis after total knee arthroplasty, leading to septic periprosthetic joint infections (PJIs). Owing to metamizole-induced agranulocytosis, the synovial leukocyte count was negative. Here, we discuss the diagnostic challenges evolving from sepsis and neutropenia in patients with suspected PJIs. We suggest an urgent surgical approach, mainly focusing on the clinical presentation preoperatively. Later, our patient developed candidemia and periprosthetic tissue samples were positive for *Candida albicans*. For fungal PJIs, long-term follow-up studies are lacking and therapeutic recommendations differ. Here, we present our therapeutic approach, including staged revision and 12 weeks of systemic antifungal therapy, and discuss recent findings regarding the therapy of fungal PJIs.

© 2020 The Authors. Published by Elsevier Inc. on behalf of The American Association of Hip and Knee Surgeons. This is an open access article under the CC BY-NC-ND license (<http://creativecommons.org/licenses/by-nc-nd/4.0/>).

Introduction

Periprosthetic joint infection (PJI) is a severe complication after joint arthroplasty that can be associated with multiple revision surgeries, prolonged hospitalization, and poor functional outcome [1]. PJI occurs in about 2% of primary total knee arthroplasty (TKA) [2]. In 50%–60%, PJIs are caused by *Staphylococcus aureus* or coagulase-negative staphylococci, such as *Staphylococcus epidermidis* [3], whereas fungal PJIs are rare, accounting for only 1% of all PJIs [4]. Patients who are immunocompromised or severely comorbid are considered at particular risk for fungal PJIs.

Metamizole is a potent nonopioid analgesic drug, which is widely used for postoperative analgesia after TKA. However, very rarely, patients develop a metamizole-induced agranulocytosis (MIA) as a severe side effect, leading to immune deficiency and making them susceptible to systemic infection. Recent studies among patients treated with metamizole showed an incidence of less than one case of MIA per one million patients per year [5].

The presented case deals with a patient developing fungal PJIs in the context of an MIA after TKA.

Case history

We present the case of a 55-year-old woman with degenerative joint disease who underwent a complex primary TKA, performed in 2017 at an outside hospital using a constrained TKA for varus osteoarthritis. Her comorbidities include asthma and atopic dermatitis. After TKA, she was prescribed metamizole as pain medication and was discharged home. Five weeks after TKA, the patient was readmitted to an external hospital and presented in an acute septic state with pancytopenia, phlegmonous soft-tissue inflammation in both arms, and atrial fibrillation. Bone marrow puncture showed a most likely MIA. In blood cultures, *Staphylococcus epidermidis* was detected, whereas wound swabs from both hands were positive for *Serratia marcescens*. Antibiotic treatment with meropenem and linezolid was established at the outside facility.

Owing to progressive sepsis, the patient was referred to our institution's intensive care unit. At admission, the patient presented with prodromal, warm, and erythematous soft-tissue swellings in both arms and a massively swollen and warm knee, which had undergone TKA as mentioned. She had an elevated serum C-reactive protein (CRP) of 26 mg/dL, elevated ferritin of 188

^{*} Corresponding author. Muenster University Hospital, 48149 Muenster, North Rhine-Westphalia, Germany. Tel.: +4915772023995.

E-mail addresses: oenningsebastian@gmail.com, sebastian.oenning@gmx.net

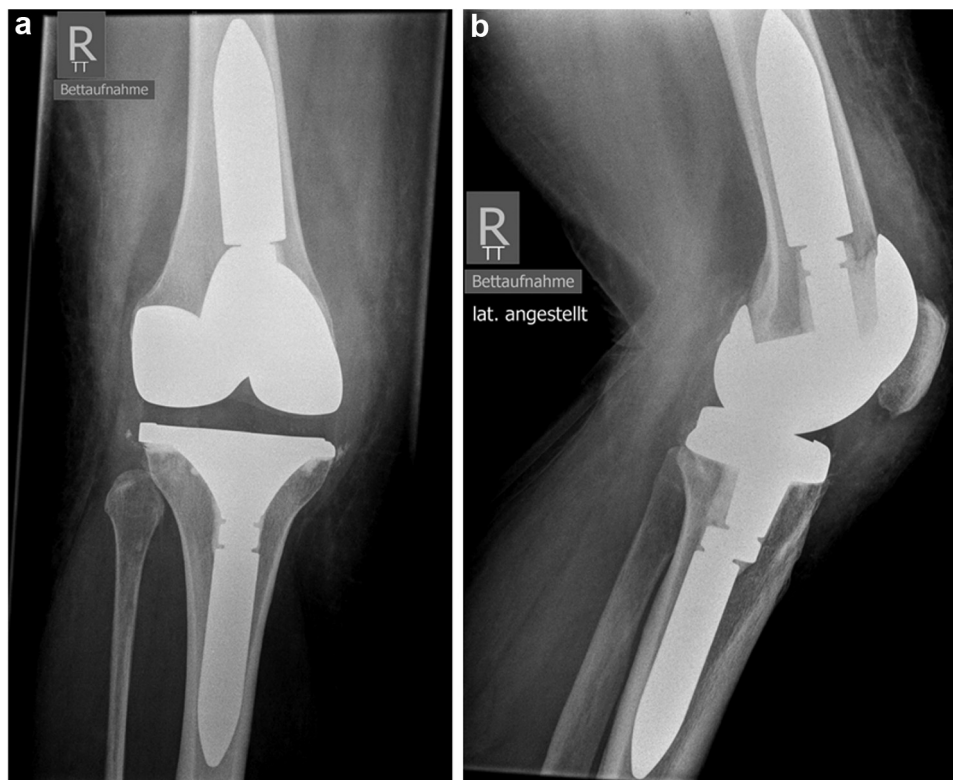


Figure 1. Anteroposterior (a) and lateral (b) radiographs of the right knee at admission. No signs of prosthetic loosening were found.

$\mu\text{g/L}$, and a white blood cell (WBC) count of $0.38 \times 10^3/\mu\text{L}$. Blood differential count revealed a polymorphonuclear leukocyte percentage (PMN%) of 2.6%.

Orthopaedic consultation was urgent because an acute PJI with systemic sepsis was suspected. Joint aspiration from the swollen knee was performed. The synovial WBC count was $0.085 \times 10^3/\mu\text{L}$ with PMN% of 14%. Radiograph imaging showed no signs of prosthetic loosening (Fig. 1). However, owing to the massively swollen, heated, and red knee, explantation of the implant and insertion of a polymethylmethacrylate cement spacer, loaded with gentamicin, clindamycin, and 2 g of vancomycin per 40 g cement, was performed on the same day. Synovial fluid and tissue samples obtained intraoperatively both showed neither bacterial nor fungal growth; however, the patient had positive blood cultures for *Escherichia coli*.

Owing to the suspected fasciitis with both arms being at risk of developing an acute compartment syndrome, we also performed an exploration of the upper extremities and fasciotomy with subsequent application of a vacuum-assisted closure device.

The postoperative antibiotic treatment included meropenem, daptomycin, and clindamycin. Within the following days, blood culture samples were negative. Repeated bone marrow puncture confirmed a most likely sepsis-triggered pancytopenia, developing from MIA. Magnetic resonance imaging of the patient's left forearm showed contrast medium enhancement in both deep and superficial fasciae, falling in line with the phlegmonous clinical appearance. Other infectious foci such as endocarditis and respiratory or urinary tract infections were excluded.

Six days after spacer implantation, *Candida albicans* was first detected in a peripherally obtained blood culture, so that micafungin (100 mg/d) was added to the systemic treatment. Subsequently, the phlegmons in arms and axillae improved clinically, whereas now we observed continuous purulent secretion from the affected knee, as the serum WBC count slowly recovered. Ten days after spacer

implantation, *Candida albicans* was detected in central blood cultures and in wound swabs from the phlegmons in both arms.

Thus, the intensive care unit performed an F18-fluorodeoxyglucose-positron emission tomography/computed tomography (FDG-PET/CT) to identify a potential focus and assess the extent of the patient's infectious lesions. It showed severe soft-tissue infections, mainly in the left forearm and the right knee (Fig. 2), with septic emboli in the soft tissue and spleen. In addition, there were signs of pneumonia with reactive lymphadenopathy. A bronchoalveolar lavage, which was positive for *Candida albicans*, confirmed pulmonary involvement.

As there was persistent wound drainage from the operated knee after spacer implantation and fungal systemic infection was present,

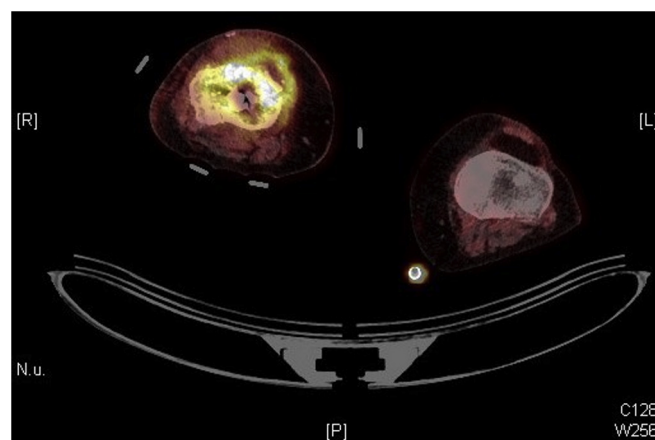


Figure 2. FDG-PET/CT showed increased metabolism in the periprosthetic soft tissues of the right knee.

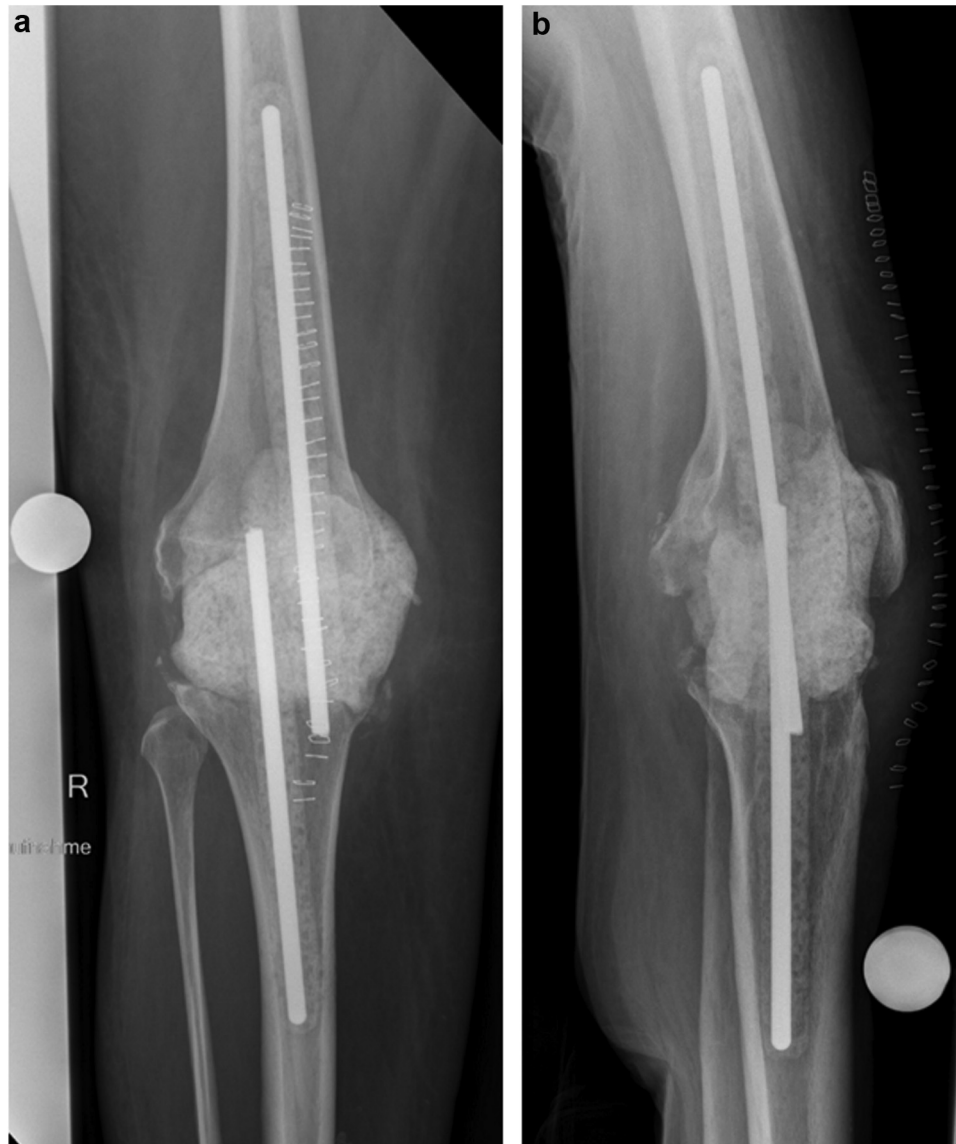

Figure 3. Anteroposterior (a) and lateral (b) radiographs of the spacer impregnated with gentamicin, clindamycin, and voriconazole.

we revised the patient's knee and exchanged the spacer (Fig. 3). The new spacer was loaded with gentamicin, clindamycin, and 600 mg of voriconazole per 40 g of cement. Tissue samples and joint aspirate were positive for fluconazole-sensitive *Candida albicans*. Post-operatively, we adjusted the antifungal treatment, which now included voriconazole (2×200 mg/d) and micafungin (100 mg/d).

From now on, clinical signs of joint and soft-tissue infections were regressive. A week after spacer exchange, our patient left the intensive care unit with a WBC count within the physiological range and continuously decreasing serum CRP levels. A computed tomography scan of the thorax showed regressive pulmonary lesions, and magnetic resonance imaging of the cranium ruled out mycotic cerebral infestation. Two months after admission, the skin lesion of the left forearm was covered by an autologous split skin graft. We discharged the patient under strict immobilization of the affected knee and continuous antimycotic therapy including oral fluconazole (400 mg/d) to complete 12 weeks of antifungal treatment.

Follow-ups after completed antifungal therapy showed continuous clinical improvements with regressive pain, healed surgical wounds, and no signs of persistent infection. Serum interleukin-6 (IL-6) was 8 pg/mL, and serum CRP came down to 0.5 mg/dL. Four

months after completion of antifungal therapy, we reimplanted a rotating-hinge revision TKA (Fig. 4). Micafungin (100 mg/d) was given intravenously for 3 weeks after reimplantation until the final long-term cultures obtained intraoperatively remained negative. Eventually, all wounds healed uneventfully and there is an event-free follow-up of 2 years after reimplantation. Currently, flexion of the affected knee is limited to 60°, while full active extension is possible with mild pain. The patient shows no signs of reinfection.

Discussion

The preoperative diagnosis of PJI can be a challenge and is based on multiple parameters. The European Bone and Joint Infection Society and Musculoskeletal Infection Society both have published reliable criteria that can be considered a diagnostic standard [6,7]. Although serum parameters such as CRP, D-dimers, and the erythrocyte sedimentation rate can be used as a first diagnostic step, their sensitivity and specificity are quite low. Despite serum CRP being the most important serum marker for PJIs [6], it was shown that serum CRP levels alone do not allow an accurate diagnosis because of a high rate of false-negative results [8]. In

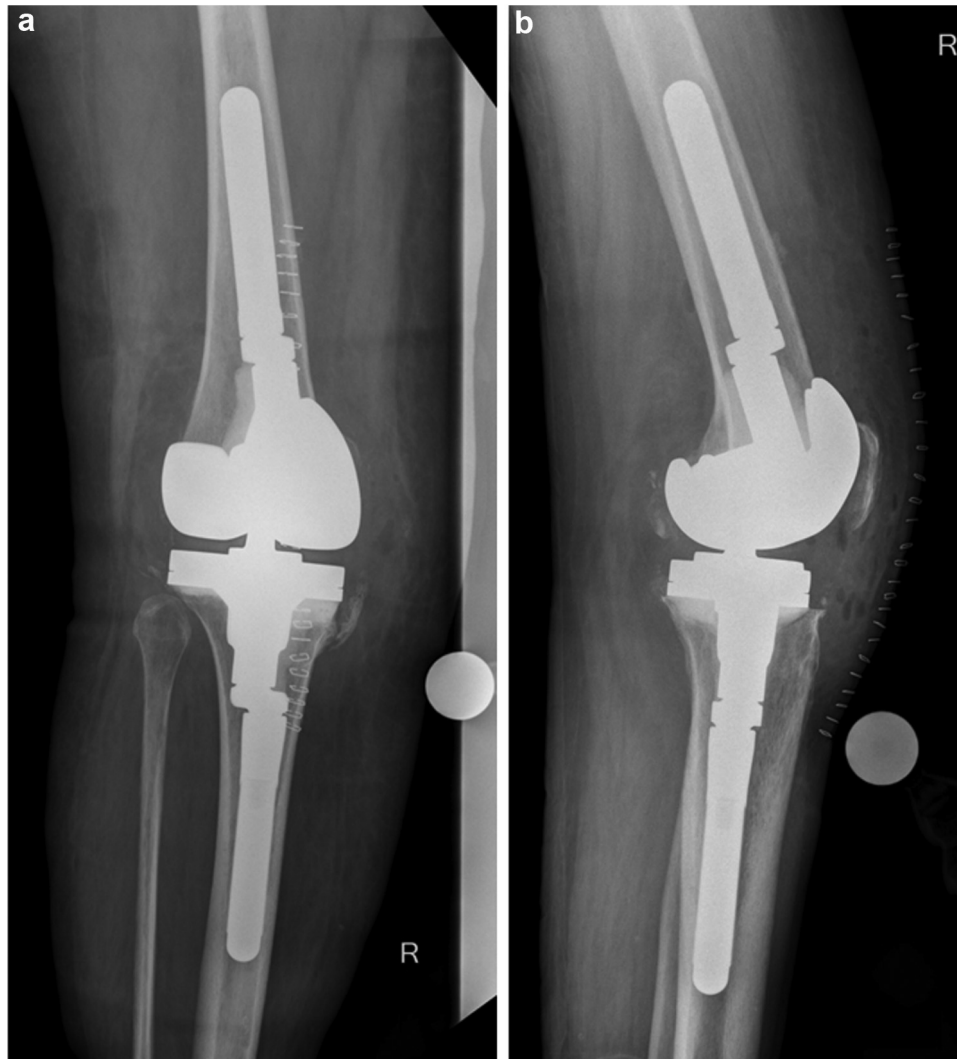

Figure 4. Anteroposterior (a) and lateral (b) radiographs of the right knee after reimplantation of a rotating-hinge revision TKA.

recent studies, serum IL-6 levels in PJI were analyzed and a cutoff value of 13 pg/mL indicating PJI was suggested [9]. However, further studies with a higher number of cases are needed to assess the diagnostic value of IL-6.

To diagnose PJI, preoperative joint aspiration is usually necessary. As per the Musculoskeletal Infection Society, positive periprosthetic microbiological cultures are a major criterion confirming PJI [6]. However, cultures from joint aspirate were shown to have high rates of false-negative results so that their sensitivity is limited [10]. In addition, culture results are sensitive to previous antibiotic treatment [11,12]. Because in septic patients such as the one mentioned previously it is inevitable to immediately initiate broad antimicrobial therapy [13], the risk of false-negative cultures is further increased. Based on this, several studies showed high rates of culture-negative PJI, ranging from 5% to 42% [12].

Leukocyte and neutrophil counts from joint aspirates have been shown to have the highest sensitivity preoperatively [6,12]. However, in a state of agranulocytosis, such as that in the presented case, both synovial WBC count and synovial PMN% show false-negative results so that PJI cannot be ruled out by joint aspiration. This diagnostic challenge can occur in all neutropenic patients. Although MIA is rare, neutropenia or functional impairment of neutrophils can be both the cause and consequence of sepsis [14,15]. Septic patients with prosthetic joints are at high risk of

developing a hematogenous microbial contamination of their implants, with that risk being further increased by neutropenia. At the same time, the number of patients with prosthetic joints rises continuously [16]. Thus, diagnostic challenges in patients with suspected PJI and coexisting sepsis and neutropenia will become more relevant in future clinical practice and, as described, we can expect interference with serological, synovial, and microbiological parameters. In this case, we therefore suggest focusing on clinical findings preoperatively. If there is any doubt regarding a possible PJI, we recommend a fast surgical approach to confirm the diagnosis and to remove the infected implant [17].

Later, the patient developed candidemia, possibly originating from pneumonia and secondary infection of the spacer. In retrospect, it remains unclear whether the fungal organism was present at the beginning, as the culturing of fungal organisms from joints can be difficult [18,19]. Because fungal PJI only account for 1%–2% of all PJI, it is debatable to what degree the established diagnostic criteria can be used [4]. In our orthopaedic department, we treat around 70 cases of PJI per year, with about 1–2 of those being caused by fungal organisms.

Based on the few studies published on this issue, staged revision using a spacer and long-term antifungal systemic treatment is the most promising approach [20]. Local antifungal treatment must be considered to ensure high antifungal doses at the site of infection. Based on this, we immediately started intravenous antimycotic

therapy with micafungin and implanted a voriconazole-impregnated polymethylmethacrylate spacer. However, some *Candida* strains are azole resistant, so that in those cases, spacers impregnated with amphotericin, ideally in liposomal formulations for optimal release properties, can be used [21]. Although liposomal amphotericin was shown to have local antifungal efficacy, our case supports the suggestion of voriconazole also having high local antifungal potency [22–24].

Postoperatively, we covered the patient with a dual systemic antimycotic therapy including voriconazole and micafungin, according to the microbiological resistance testing. At discharge, antifungal treatment was switched to oral fluconazole, so that antifungal therapy after spacer exchange lasted for 12 weeks. While the optimal period of systemic antifungal therapy after spacer implantation is still unclear, some studies discussed a prolonged treatment with recommendations ranging from at least 6 weeks to 12 weeks [20,25].

Because therapeutic algorithms and large groups of patients with fungal PJs are lacking, treatment success rates after 2 years vary from 50% [25] to 100%, with the latter only including staged revisions after fungal PJs after TKA [23]. In general, the outcome in fungal PJs is worse and complication rates are higher than those in bacterial PJs [20]. In studies by Brown et al. [26], the reinfection rate was 24% after 2 years. Possible explanations include high rates of polymicrobial infections among fungal PJs and high-risk comorbidities making patients susceptible to fungal PJs [24]. However, risk factors for fungal PJs have hardly been investigated. Although long-term follow-up studies have not been published yet, our patient has been treated successfully with the aforementioned therapeutic protocol.

Summary

Diagnostic challenges in patients with suspected PJs will become more relevant. Coexisting sepsis and neutropenia can interfere with serological, synovial, and microbiological parameters. In this case, we suggest focusing on clinical findings preoperatively, and if there is any doubt, we recommend an urgent surgical approach and removal of the implant whenever possible.

Fungal PJs were successfully treated with staged revision arthroplasty, implanting a voriconazole-impregnated spacer followed by 12 weeks of antifungal therapy. Long-term follow-up studies are needed to establish therapeutic algorithms and improve patients' outcome.

Conflict of interests

The authors declare there are no conflicts of interest.

Acknowledgments

The authors acknowledge funding from the Open Access Publication Fund of the Westphalia Wilhelm University, Muenster, for paying the publication fee.

References

[1] Kurtz SM, Lau EC, Son MS, Chang ET, Zimmerli W, Parvizi J. Are we winning or losing the battle with periprosthetic joint infection: trends in periprosthetic

- joint infection and mortality risk for the medicare population. *J Arthroplasty* 2018;33(10):3238.
- [2] Koh CK, Zeng I, Ravi S, Zhu M, Vince KG, Young SW. Periprosthetic joint infection is the main cause of failure for modern knee arthroplasty: an analysis of 11,134 knees. *Clin Orthop Relat Res* 2017;475(9):2194.
- [3] Papalia R, Vespasiani-Gentilucci U, Longo UG, et al. Advances in management of periprosthetic joint infections: an historical prospective study. *Eur Rev Med Pharmacol Sci* 2019;23(2):129.
- [4] Nace J, Siddiqi A, Talmo CT, Chen AF. Diagnosis and management of fungal periprosthetic joint infections. *J Am Acad Orthop Surg* 2019;27(18):e804.
- [5] Huber M, Andersohn F, Sarganas G, et al. Metamizole-induced agranulocytosis revisited: results from the prospective berlin case-control surveillance study. *Eur J Clin Pharmacol* 2015;71(2):219.
- [6] Parvizi J, Tan TL, Goswami K, et al. The 2018 definition of periprosthetic hip and knee infection: an evidence-based and validated criteria. *J Arthroplasty* 2018;33(5):1309.
- [7] Renz N, Yermak K, Perka C, Trampusz A. Alpha defensin lateral flow test for diagnosis of periprosthetic joint infection. *J Bone Joint Surg Am* 2018;100(9):742.
- [8] Akgün D, Müller M, Perka C, Winkler T. The serum level of C-reactive protein alone cannot be used for the diagnosis of prosthetic joint infections, especially in those caused by organisms of low virulence. *Bone Joint J* 2018;100-B(11):1482.
- [9] Hoell S, Borgers L, Gosheger G, et al. Interleukin-6 in two-stage revision arthroplasty. *Bone Joint J* 2015;97–B(1):71.
- [10] Karczewski D, Winkler T, Perka C, Müller M. The preoperative microbial detection is no prerequisite for the indication of septic revision in cases of suspected periprosthetic joint infection. *Biomed Res Int* 2018;2018:1729605.
- [11] Al-Mayahi M, Cian A, Lipsky BA, et al. Administration of antibiotic agents before intraoperative sampling in orthopedic infections alters culture results. *J Infect* 2015;71(5):518.
- [12] Abdel Karim M, Andrawis J, Bengoa F, et al. Hip and knee section, diagnosis, algorithm: proceedings of international consensus on orthopedic infections. *J Arthroplasty* 2019;34(2):S339.
- [13] Rhodes A, Evans LE, Alhazzani W, et al. Surviving sepsis campaign: international guidelines for management of sepsis and septic shock: 2016. *Intensive Care Med* 2017;45(3):304.
- [14] Hotchkiss RS, Monneret G, Payen D. Sepsis-induced immunosuppression: from cellular dysfunctions to immunotherapy. *Nat Rev Immunol* 2013;13(12):862.
- [15] Singer M, Deutschman CS, Seymour C, et al. The third international consensus definitions for sepsis and septic shock (sepsis-3). *JAMA* 2016;315(8):801.
- [16] Sloan M, Premkumar A, Sheth NP. Projected volume of primary total joint arthroplasty in the u.s., 2014 to 2030. *J Bone Joint Surg Am* 2018;100(17):1455.
- [17] Strony J, Brown S, Choong P, Ghert M, Jeys L, O'Donnell RJ. Musculoskeletal infection in orthopaedic oncology. *J Bone Joint Surg Am* 2019;101(20):e107.
- [18] Jakobs O, Schoof B, Klatter TO, et al. Fungal periprosthetic joint infection in total knee arthroplasty: a systematic review. *Orthop Rev (Pavia)* 2015;7(1):1.
- [19] Yoon H-K, Cho S-H, Lee D-Y, et al. A review of the literature on culture-negative periprosthetic joint infection: epidemiology, diagnosis and treatment. *Knee Surg Relat Res* 2017;29(3):155.
- [20] Kuiper JWP, Van Den Bekerom MPJ, Van Der Stappen J, Nolte PA, Colen S. 2-Stage revision recommended for treatment of fungal hip and knee prosthetic joint infections. *Acta Orthop* 2013;84(6):517.
- [21] Cunningham B, McLaren AC, Pauken C, McLemore R. Liposomal formulation increases local delivery of amphotericin from bone cement: a pilot study infection. *Clin Orthop Relat Res* 2012;470(10):2671.
- [22] Miller RB, McLaren AC, Pauken C, Clarke HD, McLemore R. Voriconazole is delivered from antifungal-loaded bone cement. *Clin Orthop Relat Res* 2013;471(1):195.
- [23] Kim JK, Lee DY, Kang DW, Ro DH, Lee MC, Han HS. Efficacy of antifungal-impregnated cement spacer against chronic fungal periprosthetic joint infections after total knee arthroplasty. *Knee* 2018;25(4):631.
- [24] Theil C, Schmidt-Braekling T, Gosheger G, Moellenbeck B, Dieckmann R, Idelevich EA. Fungal prosthetic joint infection in total hip or knee arthroplasty. *Bone Joint J* 2019;101 B(5):589.
- [25] Ueng SWN, Lee CY, Hu CC, Hsieh PH, Chang Y. What is the success of treatment of hip and knee candidal periprosthetic joint infection? *Clin Orthop Relat Res* 2013;471(9):3002.
- [26] Brown TS, Petis SM, Osmon DR, et al. Periprosthetic joint infection with fungal pathogens. *J Arthroplasty* 2018;33(8):2605.