

Case Report

AA amyloidosis in a patient with Langerhans cell histiocytosis

Peter C. Thomson¹, Alison H.M. Taylor¹, Scott T.W. Morris¹, David Kipgen² and Robert A. Mactier¹

¹Renal Unit, Glasgow Royal Infirmary, Glasgow, UK and ²Department of Pathology, Western Infirmary, Glasgow, UK

Correspondence and offprint requests to: Peter C. Thomson; E-mail: peter.thomson@nhs.net

Abstract

We report the case of a 37-year-old woman who presented with progressive renal dysfunction and proteinuria, in whom renal biopsy confirmed a diagnosis of AA amyloidosis. No evidence of chronic suppurative infection, connective tissue disease or malignancy was found. A past history of Langerhans cell histiocytosis (LCH) diagnosed in childhood was noted for which the patient had been successfully treated with surgical excision, corticosteroids, radiotherapy and chemotherapy. Renal disease in LCH is not widely recognized and thus we describe a patient with LCH in whom AA amyloidosis developed in the absence of any other established cause.

Keywords: amyloid; histiocytosis; Langerhans; proteinuria

Background

Langerhans cell histiocytosis (LCH), the contemporary term for Histiocytosis X, describes a collective group of myeloid dendritic cell disorders, namely eosinophilic granuloma of bone, Hand–Schuller–Christian disease and Letterer–Siwe disease. These disorders may present with single or multi-organ involvement commonly involving skin, bone, the reticuloendothelial system and the central nervous system. Incidence is higher in children than in adults [1, 2] and the prognosis varies with the type and extent of organ involvement [3]. Various therapeutic regimens have been reported, many of which have been based on the use of corticosteroids, various chemotherapeutic agents, radiotherapy and surgical excision of isolated lesions and all with only limited success.

AA amyloidosis is closely associated with inflammatory disorders, such as chronic suppurative infection, connective tissue disease and malignancy. An association between renal disease and LCH has not previously been widely recognized. We report the case of a patient with LCH who developed renal AA amyloidosis in the absence of any other established cause.

Case report

A 37-year-old woman was referred with progressive renal dysfunction concurrent with heavy proteinuria. At the age of 2 years, she had been found to have a brainstem tumour, which was neither biopsied nor removed due to its location. She had received treatment with chemotherapy, radiotherapy and insertion of a ventriculoperitoneal shunt and her health had subsequently stabilized. At the age of 7 years, she was found to have eosinophilic granuloma of the bone affecting her right humerus and left femur, both of which were successfully resected, raising the question of whether her initial brain lesion may also have been a Langerhans cell histiocytoma.

The patient was noted to have enjoyed stable health until December 2009 when she developed a blockage of her ventriculoperitoneal shunt. This was replaced successfully. However, her neurological recovery was slower than expected with subsequent cranial imaging demonstrating local haemorrhage around the area of shunt replacement with a small area of infarction in the right plantar occipital region. Her original brainstem tumour was noted to be of consistent size with no evidence of progression. Serial lumbar punctures were performed, which demonstrated no evidence of infection. Slowly her condition improved and she was transferred to her local hospital for rehabilitation.

Over the ensuing period, the patient developed progressive renal dysfunction with serum creatinine rising from 99 $\mu\text{mol/L}$ in December 2009 to 400 $\mu\text{mol/L}$ by May 2010. Progressively worsening proteinuria was noted with a urinary protein-to-creatinine ratio (PCR) of 319 mg/mmol in December 2009 increasing to 4020 mg/mmol in May 2010. Serum albumin decreased progressively from 37 g/L in December 2009 to 22 g/L by May 2010. Transfer to the renal unit for further investigation was arranged.

On transfer, blood pressure was 132/78 mmHg without antihypertensive therapy. Serum anti-neutrophil cytoplasm antibodies, anti-nuclear antibodies, anti-glomerular basement membrane antibodies, C3, C4 and serum and urine electrophoresis were all within accepted limits. Serum immunoglobulin levels were normal. Ultrasound scanning of the renal tract was unremarkable and the patient proceeded to renal biopsy, which demonstrated AA amyloidosis (Figure 1).

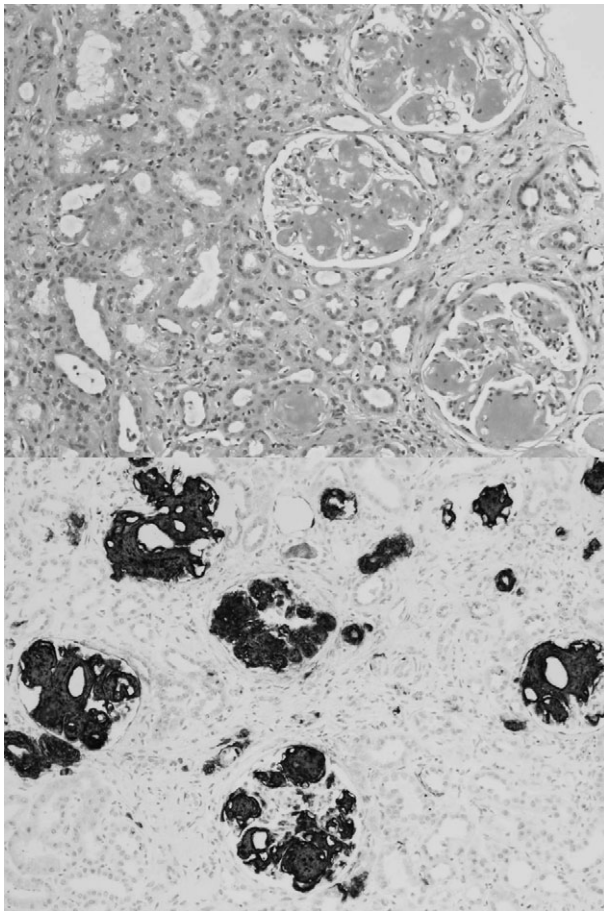


Fig. 1. Diffuse and global nodular increase in mesangial matrix (top image) and positive immunoperoxidase staining for AA amyloid protein (bottom image).

Serial blood, urine and stool cultures were negative and there was no clinical or biochemical evidence to support chronic suppurative infection. Plain chest and abdominal radiography, an abdominal ultrasound and computed tomography and magnetic resonance imaging of the brain failed to demonstrate evidence of any other concurrent disease. Skeletal survey demonstrated no evidence of recurrent bony eosinophilic granulomata.

Following a period of successful rehabilitation, feeding and rehydration, an angiotensin-converting enzyme inhibitor was commenced and the patient discharged to outpatient renal clinic follow-up with a serum creatinine of 246 $\mu\text{mol/L}$, equating to an estimated GFR of 20.4 mL/min/1.73 m^2 , and urinary PCR of 1353 mg/mmol. The patient's blood pressure remained well controlled at 130/80 mmHg on ACE-inhibitor therapy.

Discussion

In the early 1950s, Histiocytosis X was proposed as the collective term for eosinophilic granuloma of the bone, Hand-Schuller-Christian disease (a clinical triad of exophthalmos, diabetes insipidus and bony skull lesions) and Letterer-Siwe disease (a clinicopathological conglomerate

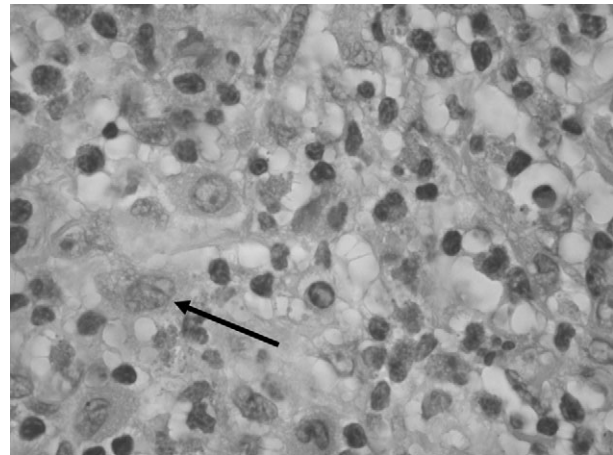


Fig. 2. LCH: high power H + E showing Langerhans histiocytes with folded or grooved nuclei and eosinophilic cytoplasm (arrow).

of fever, rash, lymphadenopathy with hepatosplenomegaly and haematological abnormalities) [4]. Subsequent work proposed the Langerhans cell to be the common cell type underpinning each of these conditions [5] (Figure 2). However, more recent work suggests that circulating myeloid progenitor cells are the likely origin behind the LCH disorders [6].

The precise pathophysiological mechanism behind LCH has yet to be elucidated. The Langerhans cells of those affected have been shown to be immature, demonstrate atypical expression of cell surface markers and to be less efficient at presenting antigens [7]. Characteristic Birbeck granules are usually seen within LCH lesions [8], yet how these features all relate to the development of Langerhans cell histiocytomas remains unknown.

In this case, a patient with LCH diagnosed in childhood presented in later life with AA amyloidosis manifested with progressive loss of renal excretory function and proteinuria. No other inflammatory process was identified on clinical, biochemical, immunological and radiological assessment. We are aware of one other case in which renal AA amyloidosis arose in a patient with LCH, specifically developing progressive renal excretory loss and proteinuria some 20 years after the initial presentation with LCH and thus demonstrating a clinical course very similar to our case [9].

We suggest that secondary amyloidosis be considered in a patient with a previous history of LCH who presents with proteinuria and progressive renal dysfunction.

Acknowledgements. We thank Dr Fiona Roberts, Consultant Pathologist, Department of Pathology, University of Glasgow, Western Infirmary, Dumbarton Road, Glasgow, UK, for providing images in Figure 2

Conflict of interest statement. The authors report no conflict of interest and the results presented in this paper have not been published previously in whole or part, except in abstract format.

References

- Carstensen H, Ornvold K. The epidemiology of LCH in children in Denmark, 1975–89. *Med Pediatr Oncol* 1993; 21: 387–388
- Baumgartner I, von Hochstetter A, Baumert B *et al.* Langerhans'-cell histiocytosis in adults. *Med Pediatr Oncol* 1997; 28: 9–14

3. Arico M, Egeler RM. Clinical aspects of Langerhans cell histiocytosis. *Hematol Oncol Clin North Am* 1998; 12: 247–258
4. Lichtenstein L. Histiocytosis X; integration of eosinophilic granuloma of bone, Letterer-Siwe disease, and Schuller-Christian disease as related manifestations of a single nosologic entity. *AMA Arch Pathol* 1953; 56: 84–102
5. Nezelof C, Basset F, Rousseau MF. Histiocytosis X histogenetic arguments for a Langerhans cell origin. *Biomedicine* 1973; 18: 365–371
6. Allen CE, Li L, Peters TL *et al.* Cell-specific gene expression in Langerhans cell histiocytosis lesions reveals a distinct profile compared with epidermal Langerhans cells. *J Immunol* 2010; 184: 4557–4567
7. Yu RC, Morris JF, Pritchard J, Chu TC. Defective alloantigen-presenting capacity of 'Langerhans cell histiocytosis cells'. *Arch Dis Child* 1992; 67: 1370–1372
8. Bogunovic M, Ginhoux F, Wagers A *et al.* Identification of a radio-resistant and cycling dermal dendritic cell population in mice and men. *J Exp Med* 2006; 203: 2627–2638
9. Perez-Martinez J, Marques M, Kilmurray L *et al.* Secondary amyloidosis associated with histiocytosis X. *Amyloid* 2008; 15: 69–71

Received for publication: 7.10.10; Accepted in revised form: 9.11.10