



Original Research

Spontaneous Pneumomediastinum: Analysis of 11 Cases

Miktat Arif Haberal,¹ Ozlem Sengoren Dikis,² Erkan Akar¹

¹Department of Thoracic Surgery, University of Health Sciences Turkey, Bursa Yuksek Ihtisas Training and Research Hospital, Bursa, Turkey

²Department of Pulmonary Diseases, University of Health Sciences Turkey, Bursa Yuksek Ihtisas Training and Research Hospital, Bursa, Turkey

Abstract

Objectives: The presence of free air in mediastinum is defined as pneumomediastinum. The incidence is between 1/7000-1/32000. In this study, our aim is to discuss our cases with spontaneous pneumomediastinum (SPM), which has low incidence, in the light of the literature.

Methods: The files of 11 cases who were diagnosed with SPM in pulmonary diseases and thoracic surgery department and followed up and treated in thoracic surgery clinic between 2012-2018 were retrospectively analyzed. Patients' age, sex, etiological factors, diagnosis and treatment methods and hospital stay were evaluated.

Results: Between the years of 2012-2018, 11 cases with SPM who were not related to trauma were detected. Nine (81.8%) of the patients were male; the median age was 38.5 years. Among the predisposing factors that played a role in the formation of SPM, the most common symptom was dyspnea, while the second most common symptom was coughing seizures. The median duration of hospitalization was 3.8 days, and no mortality was observed.

Conclusion: Spontaneous pneumomediastinum is a rare clinical condition, especially in young men. SPM treatment can be conservative or surgical.

Keywords: Dyspnea; pneumomediastinum; spontaneous.

Please cite this article as "Haberal MA, Sengören Dikis O, Akar E. Spontaneous Pneumomediastinum: Analysis of 11 Cases. Med Bull Sisli Etfal Hosp 2021;55(1):49–52".

Free air accumulation in the mediastinum is defined as pneumomediastinum (PM). It mostly occurs as a result of the rupture of organs in the respiratory system or digestive system. It was first identified by Laennec in a trauma patient in 1819, and it was defined by Hamman in 1939.^[1] Spontaneous pneumomediastinum (SPM) is rare and mostly occurs as a result of rupture of the pulmonary alveoli in healthy young men. Causes, such as coughing, vomiting and straining, play a role in the formation of spontaneous alveolar rupture, which causes increased intra-abdominal and intra-thoracic pressure. The most common symptoms seen in the clinic are dyspnea, chest pain,

neck pain, and subcutaneous emphysema.^[2] The crunching sound heard on auscultation that occurs with heart beats on the front chest wall is known as the Hamman sign. The incidence of PM has been reported between 1/7000-1/32000.^[3] Our aim in this study is to discuss our SPM cases in the light of literature.

Methods

The files of 11 patients who were diagnosed with SPM in the pulmonary diseases and thoracic surgery clinics between 2012 and 2018 and were treated in the Department of Thoracic Surgery were retrospectively analyzed. The pa-

Address for correspondence: Ozlem Sengoren Dikis, MD. Saglik Bilimleri Universitesi Bursa Yuksek Ihtisas Egitim ve Arastirma Hastanesi, Gogus Cerrahisi Klinigi, Bursa, Turkey

Phone: +90 507 234 08 10 **E-mail:** ozlemsengoren@hotmail.com

Submitted Date: April 27, 2019 **Accepted Date:** October 14, 2019 **Available Online Date:** March 17, 2021

©Copyright 2021 by The Medical Bulletin of Sisli Etfal Hospital - Available online at www.sislietfaltip.org

OPEN ACCESS This is an open access article under the CC BY-NC license (<http://creativecommons.org/licenses/by-nc/4.0/>).



tients were evaluated concerning age, gender, etiological factors, diagnosis and treatment methods, and length of hospital stay.

Pneumomediastinum cases resulting from thoracic trauma, surgical and invasive diagnostic procedures (e.g., esophagoscopy and bronchoscopy), which are secondary causes of pneumomediastinum, were not included in this study. All patients were hospitalized and followed up. Before the hospitalization, whole blood, biochemistry, sedimentation and CRP values were measured. Each patient had a posteroanterior (PA) chest x-ray as a radiological examination. Computed tomography (CT) of the thorax was requested in cases that were deemed necessary to better examine mediastinal structures. ECG was performed in patients with cardiac complaints, and an echocardiogram was requested in patients who were deemed necessary. Oral intake of the patients was discontinued after admission to the service, and parenteral treatment was started. Nutritional regimens were initiated in patients with clinical improvement and no progression of PM after 24 hours. Inhaled bronchodilators, oxygen (6-7 lt/min) and analgesic treatment were used in medical treatment.

Ethics committee approval of the study was obtained from the ethics committee of Health Sciences University Bursa Yuksek Ihtisas Education and Research Hospital with the date and number of 2011-KAEK-25 2019/03-11.

Results

In the seven-year period, we included in our study, we detected 11 cases with SPM that were not related to trauma or invasive diagnostic intervention. Nine (81.8%) of the patients were male, two (18.2%) were female, and the age distribution was between 29-46 (median 38.5). Among the predisposing factors that play a role in the formation of SPM, coughing attacks secondary to respiratory tract infection were the first, and the most common symptom was dyspnea (Table 1, Table 2). PA chest x-ray was performed initially as an imaging method in all cases to reach the diagnosis (Fig. 1). In cases of doubt, the diagnosis was confirmed by thoracic CT (Figs. 2, 3). The median length of hospital stay of the cases was 3.8 days (2-5 days). No mortality was observed.

Discussion

The pathophysiology of spontaneous pneumomediastinum was first described by Macklin in 1944. Macklin reported that PM was formed with the rupture of the distal alveoli as a result of increased intraalveolar pressure and that due to the pressure difference of the air from this tear, it spread from the lung parenchyma tissue to the mediastinum via

Table 1. Factors involved in the formation of spontaneous pneumomediastinum

Predisposing factor	n	%
Cough	6	54.5
Extreme exercise	3	27.3
Inhaler drug use	1	9.1
Unknown	1	9.1
Total	11	100

Table 2. Distribution of spontaneous pneumomediastinum cases according to symptoms

Symptoms	n	%
Dyspnea	10	90.9
Chest pain	8	72.7
Cough	8	72.7
Subcutaneous emphysema	5	45.4
Neck pain	3	27.2

the peribronchovascular pathway.^[4] Spontaneous pneumomediastinum is a pathology usually seen in young men, of which symptoms disappear spontaneously.^[5] Spontaneous alveolar rupture occurs in conditions that cause an increase in alveolar pressure, such as coughing, vomiting, straining, and Valsalva maneuver.^[5,6] Chronic obstructive pulmonary disease (COPD), asthma, use of narcotic agents, such as cannabis and cocaine, widespread interstitial fibrosis are among the diseases that lead to SPM.^[7] In addition, mediastinal emphysema can be seen in children with a severe cough caused by diseases, such as diphtheria, acute bronchitis, whooping cough and influenza. In addition, it may also appear as a complication of vaginal delivery.^[8] In a study, a case of SPM developing as a result of the use of narcotic cocaine was identified and published.^[9] Although none of our patients used narcotic agents, seven (63.6%) were smokers. It has been stated that SPM may occur after tonsillectomy, tooth extraction, tracheostomy, head and neck surgery and after head and facial trauma.^[10] Symptoms, such as sudden onset chest pain, dyspnea, fullness in the neck veins, cyanosis, dysphagia, hoarseness and subcutaneous emphysema, can be seen as clinical signs in patients with SPM.^[11] The most common symptoms in our study were determined as dyspnea, chest pain and cough. Mediastinal air can pass under the skin and move towards the neck and facial area, causing subcutaneous emphysema. We detected subcutaneous emphysema in the neck region in five of our patients. Fever, hypotension, dysphagia, leukocytosis and elevated CRP may accompany mediastinal emphysema.^[5] It is important to be diagnosed quickly because of its potential of being lethal. It should be kept

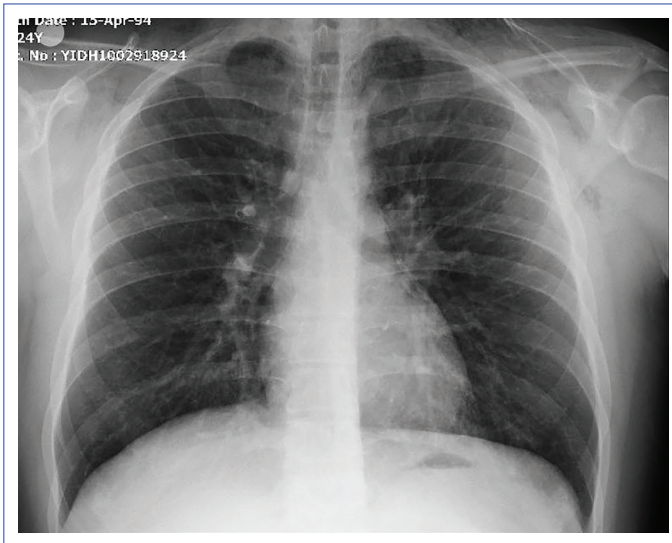


Figure 1. PA chest radiography of a patient diagnosed with spontaneous pneumomediastinum.

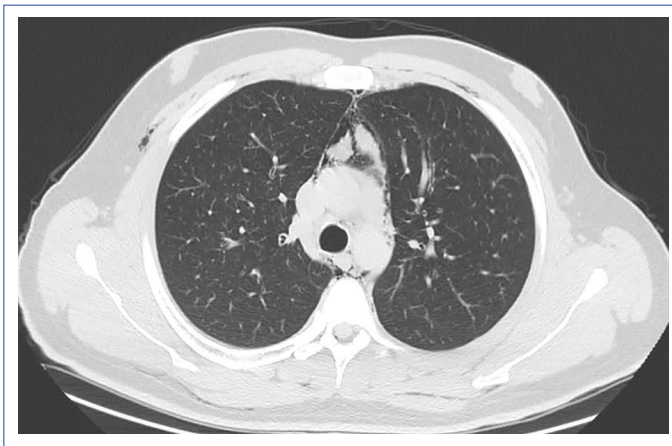


Figure 2. Thoracic CT section of a patient diagnosed with spontaneous pneumomediastinum.

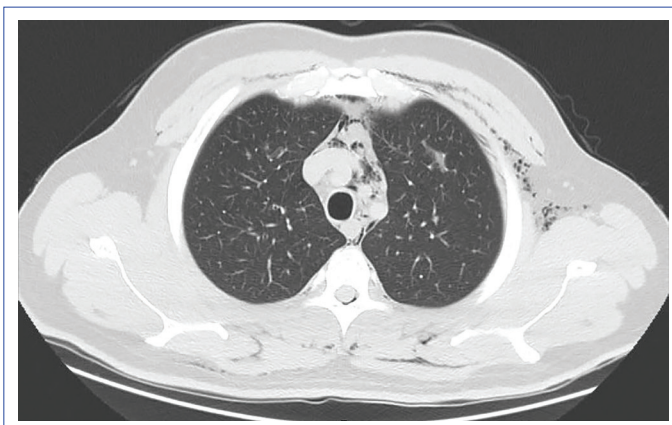


Figure 3. Thoracic CT section of a patient diagnosed with spontaneous pneumomediastinum.

in mind that SPM may also be in the etiology of acute on-set chest pain in healthy adolescents and young adults. PA

chest x-ray and thoracic CT are sufficient imaging methods in the diagnosis of patients.^[12] In addition, bronchoscopy, esophageal passage X-ray in suspicion of esophageal perforation, and bilateral cervical radiographs are used to detect subcutaneous emphysema in the cervical region. Thoracic CT is the most sensitive diagnostic method for spontaneous pneumomediastinum. The appearance of air bubbles together with the enlargement of the mediastinum confirms the diagnosis. In our study, we used PA chest x-ray and thoracic CT as radiological diagnostic methods. Treatment should be directed to the cause and the diagnosis should be made quickly. If necessary, surgical treatment should not be avoided. When patients with spontaneous pneumomediastinum are admitted to the hospital, oral food intake should be discontinued, and follow-up should be performed using daily chest x-rays. The observation periods of the patients are at least 24 or 36 hours, but this period can be extended according to the clinical situation.^[11]

Conclusion

Spontaneous pneumomediastinum is a rare clinical condition that is detected especially in young men and whose complaints spontaneously regress or disappear. In the differential diagnosis, musculoskeletal pain, pleural, pulmonary, cardiac and esophageal causes should be considered first. Spontaneous pneumomediastinum treatment can be conservative or surgical. In the event of an indication, surgery should not be avoided. We think that conservative treatment has an important place in the treatment of the disease.

Disclosures

Ethics Committee Approval: Ethics committee approval of the study was obtained from the ethics committee of Health Sciences University Bursa Yuksek Ihtisas Education and Research Hospital with the date and number of 2011-KAEK-25 2019/03-11.

Peer-review: Externally peer-reviewed.

Conflict of Interest: None declared.

Authorship Contributions: Concept – M.A.H.; Design – M.A.H.; Supervision – E.A.; Materials – O.S.D., M.A.H.; Data collection &/or processing – O.S.D., E.A.; Analysis and/or interpretation – M.A.H.; Literature search – O.S.D., E.A.; Writing – M.A.H.; Critical review – O.S.D., E.A.

References

1. Macia I, Moya J, Ramos R, Morera R, Escobar I, Saumench J, et al. Spontaneous pneumomediastinum: 41 cases. *Eur J Cardiothorac Surg* 2007;31:1110–4.
2. Ryoo JY. Clinical analysis of spontaneous pneumomediastinum. *Tuberc Respir Dis (Seoul)* 2012;73:169–73.
3. Jougon JB, Ballester M, Delcambre F, Mac Bride T, Dromer CE, Velly JF. Assessment of spontaneous pneumomediastinum: experi-

- ence with 12 patients. *Ann Thorac Surg* 2003;75(6):1711-4.
4. Koullias GJ, Korkolis DP, Wang XJ, Hammond GL. Current assessment and management of spontaneous pneumomediastinum: experience in 24 adult patients. *Eur J Cardiothorac Surg* 2004;25:852-5.
 5. Chujo M, Yoshimatsu T, Kimura T, Uchida Y, Kawahara K. Spontaneous pneumomediastinum. [Article in Japanese]. *Kyobu Geka* 2006;59:464-8.
 6. Dionísio P, Martins L, Moreira S, Manique A, Macedo R, Caeiro F, et al. Spontaneous pneumomediastinum: experience in 18 patients during the last 12 years. *J Bras Pneumol* 2017;43:101-5.
 7. Singhal S, Ferraris VA, Bridges CR, Clough ER, Mitchell JD, Fernando HC, et al. Management of alveolar air leaks after pulmonary resection. *Ann Thorac Surg* 2010;89:1327-35.
 8. Chow JL, Green-Hopkins I, Peabody CR. A Toddler with spontaneous pneumomediastinum. *Clin Pract Cases Emerg Med* 2017;1:411-2.
 9. Schönnagel BP, Adam G, Ittrich H. Spontaneous pneumomediastinum after cocaine abuse. *Rofo* 2013;185:371-3.
 10. Altınok T, Ceran S. Pneumomediastinum. *Turkiye Klin J Surg Med* 2007;3:39-42.
 11. Langwieler TE, Steffani KD, Bogoevski DP, Mann O, Izbicki JR. Spontaneous pneumomediastinum. *Ann Thorac Surg* 2004;78:711-3.
 12. Chan V, Raza A, Lashari BH, Patel R. Silent Breathlessness: A case and brief review of spontaneous pneumomediastinum. *Cureus* 2019;11:e4487.