

# Surgical management of middle ear cholesteatoma in children with Turner syndrome: a multicenter experience

Diego Zanetti<sup>1</sup>, Filippo Di Lella<sup>2</sup>, Maurizio Negri<sup>3</sup>, Vincenzo Vincenti<sup>2</sup>

<sup>1</sup>Department of Audiology, University of Milano, IRCSS Policlinico “Ca’ Granda”, Milano, Italy; <sup>2</sup>Department of Clinical and Experimental Medicine, Unit of Audiology and Pediatric Otorhinolaryngology, University of Parma, Italy; <sup>3</sup>Department of Otorhinolaryngology, Ospedale Ramazzini, Carpi, Italy

**Summary.** *Background and aim:* As in other syndromes characterized by craniofacial anomalies, middle ear cholesteatoma is known to have a high prevalence in Turner syndrome. The aim of this study was to review a multicenter experience with the surgical management of middle ear cholesteatoma in children with Turner syndrome. *Methods:* We retrospectively analyzed sixteen girls with Turner syndrome who underwent otologic surgery for middle ear cholesteatoma between January 2000 and December 2012. Surgery was performed in 3 tertiary care otologic centers. Four patients had bilateral disease, resulting in a total of 20 ears treated. The following data were recorded: age, history of ventilation tube insertion, status of the contralateral ear, cholesteatoma location and extension, and surgical technique involved. Cholesteatoma recidivism, stable mastoid cavity and hearing levels were the main outcomes measured. *Results:* Follow-up ranged from 3 to 15 years (mean 7 years). Fourteen ears underwent canal wall down mastoidectomy: no cases of recurrent cholesteatoma were observed in these cases; revision mastoidectomy with cavity obliteration was needed in 2 ears (14.3%) for recurrent otorrhea. In the remaining 6 ears a staged canal wall up mastoidectomy was performed: 1 child showed a recurrent cholesteatoma and required conversion to canal wall down mastoidectomy. A postoperative air-bone gap result of 0 to 20 dB was achieved in 6 ears (30%); in 9 ears (45%) postoperative air-bone gap was between 21 and 30 dB, while in 5 (25%) was >30 dB. Bone conduction thresholds remained unaffected in all cases. *Conclusions:* Cholesteatoma in children with Turner syndrome is a challenging entity for the otologic surgeon. Although not mandatory, canal wall down mastoidectomy should be regarded as the technique of choice to achieve a safe and dry ear in TS children with middle ear cholesteatoma. Intact canal wall mastoidectomy should be adopted only in appropriately selected patients such as those with limited attic cholesteatoma that can be regularly followed-up. ([www.actabiomedica.it](http://www.actabiomedica.it))

**Key words:** cholesteatoma, Turner syndrome, middle ear surgery, mastoidectomy, hearing

## 1. Introduction

Turner syndrome (TS), a relatively common chromosomal disorder occurring in one out of 2,000 live-born girls, is caused by complete or partial absence of one X chromosome (1). Monosomy 45,X, having only one X-chromosome in all cells, is the most frequently

occurring karyotype (50%), while 30-40% of the patients have a mosaicism, with two or more chromosomally different cell lines (2). The prominent features of TS are gonadal dysgenesis, short stature, and dysmorphic abnormalities, including webbing of the neck, cubitus valgus, micrognathia, high arched palate, low posterior hairline. Several studies (3-5) reported an

increased prevalence of otologic and audiological problems in TS. The external ear anomalies include low set ears, cupped auricles, external auditory canal stenosis, and abnormally protruding ears. Women with TS often develop a mid-frequency SNHL in their teens or adolescence; as long as the higher frequencies are still heard, this usually does not cause hearing problems (5). Literature data (6-7) show great variability in the prevalence of SNHL varying from 9 to 66%. Girls with TS are known to have a high prevalence of middle ear disease with a predisposition for the development of chronic and recalcitrant otologic disease. The predisposition to middle ear disease is most likely due to craniofacial anomalies frequently observed in TS patients, such as growth disturbances of the cranial base, downward sloping of the external auditory canal, abnormal orientation of the Eustachian tube, palatal anomalies. An interesting theory, the cell cycle hypothesis, was proposed by Barrenas et al. (4) to explain the predisposition of TS patients for acute and chronic otitis media. Because of a prolonged cell cycle and a lack of transacting growth-regulating genes such as the SHOX/PHOG gene, the up-regulation of the cell cycle in the branchial arches and in the neck region is insufficient, leading to growth disturbance of the cranial base, influencing the anatomy and the function of the Eustachian tube.

As in other syndromes characterized by craniofacial anomalies (7-10), middle ear cholesteatoma is known to have a high prevalence in TS. Verver et al. (2), in a case series of 60 girls founded cholesteatoma in 3 patients, affecting four ears. In a study on 179 patients with TS, Lim et al. (11) reported a cholesteatoma incidence of 3.9% and highlighted the need for early diagnosis and careful follow-up in order to minimize the risk of cholesteatoma progression. Although transfer technologies have been proposed to treat or prevent middle ear disease (12), surgical treatment is our only tool to avoid cholesteatoma-related complications. In the literature, there are little and sparse data regarding the surgical treatment of cholesteatoma in children with TS. In the present study, we describe the results obtained in 3 tertiary otologic care centers, sharing the same criteria in choosing the surgical technique in the management of acquired middle ear cholesteatoma in children.

## 2. Material and methods

Charts of children (0-18 years) with TS and middle ear cholesteatoma who had been surgically treated at three tertiary otologic care centers (Carpi, Milano, and Parma) during the period between January 2000 and December 2012 were retrospectively reviewed. The study protocol was approved by the institutional review boards and an informed written consent was obtained from all parents of the patients. Cholesteatoma was diagnosed otoscopically and confirmed by high resolution computed tomography (HRCT) in all children. Medical reports were analyzed by age, history of ventilation tube insertion, cholesteatoma location and extension, status of contralateral ear, neuroradiological findings, surgical procedure adopted, preoperative and postoperative audiograms. Cholesteatoma recidivism, ears with canal wall up mastoidectomy (CWUM) later requiring conversion to canal wall down mastoidectomy (CWDM), postoperative complications, and hearing levels were the main outcomes measured. Hearing results were evaluated according to guidelines set forth by the Committee on Hearing and Equilibrium of the American Academy of Otolaryngology and Neck Surgery for the evaluation of results of treatment of conductive hearing loss (13). Pure-tone average (PTA) was calculated as the mean of 500, 1000, 2000, and 3000 Hz thresholds. The air-bone gap was reported as the four-tone PTA for air-conduction and bone-conduction values determined at the same time. Hearing results were determined at the last follow-up.

## 3. Results

A total of 16 children were identified and included in this study. Four girls had bilateral disease, resulting in a total of 20 ears surgically treated. Relevant patient demographic data were reported in Table 1. All patients had fresh primary acquired middle ear cholesteatoma. The median age at the time of first surgery was 10.9 years (range, 7-18 years). A positive history for ventilation tube insertion was found in 15 (62.5%) out of the 24 ears. On presentation, all patients reported hearing loss in the affected ear, while recurrent otorrhea was present in 15 (75%) ears. Five

**Table 1.** Patient demographic data, cholesteatoma type and extension, surgical technique, and postoperative complications

Patient/Ear	Age	Cholesteatoma type	Cholesteatoma extension	Surgical technique	Intraoperative findings	complication Postoperatives
1/Left	11	Attic cholesteatoma	E	Staged CWUM	Residual cholesteatoma	
2/Left	15	Attic cholesteatoma	E	Staged CWUM		
2/Right	18	Attic cholesteatoma	E	Staged CWUM	Residual cholesteatoma	
3/Right	7	Attic cholesteatoma	E	Staged CWUM		
4/Left	13	Attic cholesteatoma	E	Staged CWUM		
5/Right	12	Attic cholesteatoma	EAM	Staged CWUM		Recurrent cholesteatoma requiring CWDM
6/Left	10	Attic cholesteatoma	EAM	CWDM		
7/Right	15	Attic cholesteatoma	ERAM	CWDM	LSCC fistula	
8/Right	9	Attic cholesteatoma	EAM	CWDM	Contracted mastoid	
8/Left	10	Attic cholesteatoma	EAM	CWDM		Otorrhea treated by medical therapy
9/Left	10	Sinus cholesteatoma	R	CWDM		
10/Left	11	Sinus cholesteatoma	R	CWDM	Contracted mastoid	
11/Right	8	Sinus cholesteatoma	R	CWDM		
12/Left	13	Sinus cholesteatoma	R	CWDM	Contracted mastoid	Otorrhea requiring cavity obliteration
13/Left	12	Sinus cholesteatoma	ERAM	CWDM		
13/Right	13	Sinus cholesteatoma	ERAM	CWDM		
14/Right	10	Sinus cholesteatoma	ERAM	CWDM		Otorrhea requiring cavity obliteration
14/Left	9	Tensa retraction cholesteatoma	ERAM	CWDM		
15/Left	14	Tensa retraction cholesteatoma	ERAM	CWDM		
16/Right	10	Tensa retraction cholesteatoma	ERAM	CWDM		

E: epytympanum; A: antrum; R:retrotympanum; M: mastoid; CWUM: canal wall up mastoidectomy; CWDM: canal wall down mastoidectomy; LSCC: lateral semicircular canal.

patients (31.2%) had evidence of sensorineural deficits including 4 with mixed and 1 with isolated sensorineural hearing loss. Preoperative otoscopic examination showed an attic cholesteatoma in 10 ears, a sinus cholesteatoma in 7 ears, and a tensa retraction cholesteatoma in 3 ears. A stenosis of the external auditory

canal was observed in 13 (65%) out of the 20 ears. The contralateral ear was normal in 13 ears; 4 ears presented a cholesteatoma, 2 a retraction pocket and one a tympanic membrane perforation. The average follow-up time was 5 years (range 3 to 10 years). At surgery, the location of the cholesteatoma was as follows: lim-

ited to the attic in 5 ears; attic, antrum and mastoid involvement was evident in 5 ears; limited to the retrotympanum in 4 ears; retrotympanum, attic and mastoid involvement was present in 6 ears. In the majority of patients, HRCT findings included: stenotic external auditory canal, directed posteriorly and superiorly, and more oblique than usual; prominence of conchal cartilage obstructing the meatus; para-transverse direction and increased angle of major axis of the petrous bone ( $45^\circ$  instead of  $30^\circ$ ); contracted mastoid with low cellularity (Fig. 1).

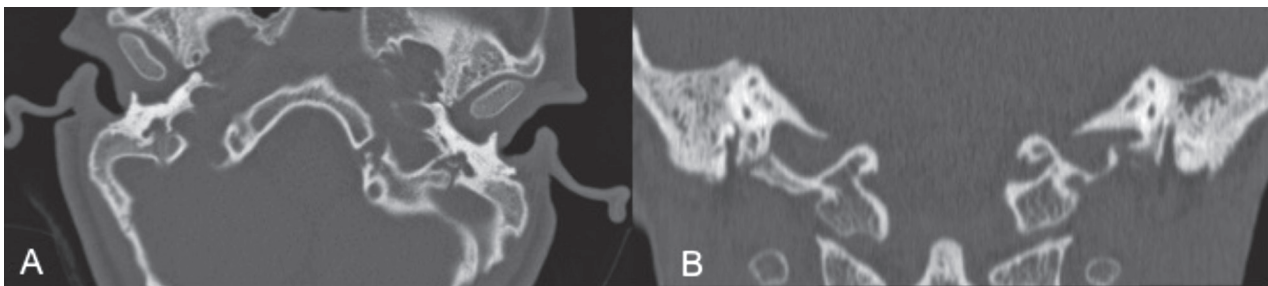
In fourteen ears a one-stage CWDM was performed: no cases of recurrent cholesteatoma were observed in these cases at last follow-up examination. Three patients had recurrent otorrhea due to cavity granulation: in one case, granulation tissue formation was treated by suctioning and debriding in the office followed by short period local application of otological drops, while in 2 patients a revision surgery was performed with blind sac closure of the external auditory canal, removal of skin and tympanic membrane remnants, Eustachian tube closure with periosteum and bone wax, and cavity obliteration with abdominal fat. A planned staged CWUM with facial recess opening was used in 6 ears, in which preoperative imaging and intraoperative findings evidenced a small cholesteatoma strictly confined to the attic with minor erosion of the posterior canal wall. Among the 6 ears that underwent staged CWUM, one developed a recurrent cholesteatoma, and required conversion to CWDM. During the second-look procedure, one ear (16.6%) was found to have a residual cholesteatoma. A postoperative air-bone gap  $\leq 20$  dB was achieved in 6

ears (30%); in four of these 6 ears a planned CWUM was performed. Results comparing preoperative and postoperative hearing are shown in Table 2. No cases of bone conduction deterioration were observed. Four patients with bilateral hearing loss were rehabilitated by means of a bone-anchored hearing aid.

#### 4. Discussion

The incidence of middle ear cholesteatoma in childhood has been reported at 3-6 per 100.000 (14) while in children with TS has been reported to be approximately 1000 times higher than in the general population (11,15). Hall et al. (16) described a population of 178 TS patients of whom 6 (3.4%) had cholesteatoma; similarly, Dhooge et al. (3) found cholesteatoma in 2 (2.3%) out of 87 ears. In the only study reporting specifically on cholesteatoma management in TS patients, Lim et al. (11) observed a cholesteatoma in 7 (3.9%) of the 179 girls reviewed; a bilateral disease was present in 2 cases resulting in a total of 9 ears treated. A CWDM was performed in 5 ears and a CWUM in the remaining 4 ears. A recurrent cholesteatoma was observed in 2 cases (22.2%), one after a CWDM, and the other one following a CWUM and requiring conversion to modified radical mastoidectomy.

Hall et al. (16) reported on result of surgery for otologic disease in TS and included patients operated on for a variety of diagnoses. Six children were found to have cholesteatoma; one patient had bilateral disease, resulting in a total of 7 ears surgically treated. Multiple interventions were required to obtain a dry and safe ear



**Figure 1.** High resolution computed tomography (A: axial view; B: coronal view) showing typical findings in Turner Syndrome: stenotic external auditory canal, directed posteriorly and superiorly, and more oblique than usual; prominence of conchal cartilage obstructing the meatus; para-transverse direction and increased angle of major axis of the petrous bone ( $45^\circ$  instead of  $30^\circ$ ); contracted mastoid with low cellularity

**Table 2.** Pure tone averages and air-bone gap preoperatively, and at last follow-up

Patient/Ear	Preoperative BC PTA (dB)	Postoperative BC PTA (dB)	Preoperative AC PTA (dB)	Postoperative AC PTA (dB)	Preoperative ABG (dB)	Postoperative ABG (dB)	Notes
1/Left	10	10	30	10	20	0	
2/Left	10	10	20	20	10	10	
2/Right	15	15	35	30	20	15	
3/Right	10	10	40	35	30	25	
4/Left	20	20	40	20	20	0	
5/Right	10	10	35	35	25	25	
6/Left	30	30	65	60	35	30	
7/Right	10	10	45	20	35	10	
8/Right	30	30	55	55	25	25	
8/Left	30	30	50	70	20	35	BAHA
9/Left	10	10	50	40	40	30	
10/Left	10	10	40	40	30	30	
11/Right	45	45	45	45	0	0	
12/Left	10	10	30	55	20	45	
13/Left	40	40	80	80	40	40	BAHA
13/Right	30	30	75	60	45	30	
14/Right	10	10	60	60	50	50	BAHA
14/Left	10	10	40	40	30	30	
15/Left	40	40	70	65	30	25	
16/Right	20	20	60	60	40	40	BAHA

BC: bone conduction; AC: air conduction; PTA: pure tone average; ABG: air-bone gap; BAHA: bone-anchored hearing aid.

as reflected by two or more procedures required in 5 of the 7 ears. In the child with bilateral cholesteatoma, the left ear underwent 4 operations, the last of which was a modified radical mastoidectomy, while the right ear underwent 2 interventions (tympanomastoidectomy and subsequent CWDM). The authors (16) concluded that revision procedures are common and reflect the recalcitrant nature of middle ear disease in TS patients. Similarly, O'Malley et al. (10), in a study on chronic ear surgery in syndromic subjects, reported on five patients with TS who underwent 11 surgical procedures on 6 ears. Three patients were successfully managed with one surgery, one patient required three surgeries, and another patient required five surgeries. Four of the 6 ears were found to have cholesteatoma. Three of the 4 ears required a CWDM, while the remaining patient underwent a cavity obliteration procedure. Verver et al. (2), reporting on ear and hearing problems in TS, affirmed that, although they prefer to perform a CWUM in children with middle ear cho-

lesteatoma, a canal wall down procedure was necessary in 5 of the 7 ears treated due to the recurrence of the disease. Our experience in the surgical treatment of middle ear cholesteatoma in TS, is quite similar. Although CWUM represents our preferred approach to pediatric cholesteatoma, location and extension of cholesteatoma evaluated by preoperative imaging and intraoperative findings represent the major decisional factor in the choice of the surgical technique. We do not hesitate to perform an open technique in presence of irreparable erosions of the postero-superior canal wall, dead ear, labyrinthine fistula, contracted mastoid, recurrent cholesteatoma or, if the child is judged either unable or unwilling to collaborate with adequate follow-up. In the present case series, a CWDM was performed as technique of choice in 14 ears because of extensive cholesteatoma with posterior canal wall considered unreconstructable (10 cases), contracted mastoid (3 cases), and large labyrinthine fistulae (1 case). In accordance with O'Malley et al. (10), we think that

the presence of a syndrome characterized by craniofacial anomalies, should not be considered a criterion, in itself, to perform an open technique. Certainly, in patients with craniofacial anomalies, chronic Eustachian tube dysfunction must be taken into account, since it represent the main risk factor for the development of recurrent cholesteatoma in CWUM. For this reason, we consider fundamental the reconstruction of even minimal loss of substance of the postero-superior canal wall using autogenous bone pate graft (17). Another source of recidivism is represented by epidermal debris left behind from surgery. Staging the procedure, use of otoendoscopes as an adjunct to operating microscope to better visualize and clean the blind areas in the middle ear, and chemically assisted dissection by means of mesna permit to reduce the likelihood of residual disease (18-21).

As for hearing results, Lim et al. (11) reported an improvement of air-bone gap between 7 and 40 dB in four cases, while the remaining eight had deterioration of air-bone gap between 8 and 23 dB; after surgery, no change in bone conduction occurred in any patient. Two girls required hearing aid post-cholesteatoma surgery. Also in our series, bone conduction thresholds remained unaffected in all cases; a postoperative air-bone gap between 0 and 20 dB was obtained only in 30% of the ears. As one could expect, better hearing results were obtained in patients who underwent CWUM. Five patients required hearing aids after surgery; 2 cases treated by means of CWUM benefitted from a traditional hearing aid, while the remaining 3 patients had a CWDM and received a bone-anchored hearing aid.

Surgery performed by different surgeons, next to the small number of patients, represent the main limitations of this study. That said, the results brought us to some considerations. Although the presence of a syndrome characterized by craniofacial anomalies, should not be considered a criterion, in itself, to perform an open technique, CWDM should be regarded as the technique of choice to achieve a safe and dry ear in TS children with middle ear cholesteatoma. CWUM may give excellent durable anatomical and functional results even in syndromic patients, but it should be adopted only in appropriately selected patients such as those with limited attic cholesteatoma that can be regularly followed-up.

## References

1. Ranke MB, Saenger P. Turner's syndrome. *Lancet* 2001; 358: 309-14.
2. Verver EJ, Freriks K, Thomeer HG, et al. Ear and hearing problems in relation to karyotype in children with Turner syndrome. *Hear Res* 2011; 275: 81-8.
3. Dhooge IJ, De Vel E, Verhoye C, Lemmerling M, Vinck B. Otologic disease in Turner syndrome. *Otol Neurotol* 26; 2005: 145-50.
4. Barrenas ML, Landin-Wilhelmsen K, Hanson C. Ear and hearing in relation to genotype and growth in Turner syndrome. *Hear Res* 2000; 144: 21-8.
5. Verver EJ, Freriks K, Sas TCJ, et al. Karyotype-specific ear and hearing problems in young adults with Turner syndrome and the effect of oxandrolone treatment. *Otol Neurotol* 2014; 35: 1577-84.
6. Sculerati N, Oddoux C, Clayton CM, Lim JW, Oster H. Hearing loss in Turner syndrome. *Laryngoscope* 1996; 106: 992-7.
7. Gawron W, Wikiera B, Rostkowska-Nadolska B, Orendorz-Fraczkowska K, Noczynska A. Evaluation of hearing organ in patients with Turner syndrome. *Int J Pediatr Otorhinolaryngol* 2008; 72: 575-579.
8. Vincenti V, Marra F, Bertoldi B, et al. Acquired middle ear cholesteatoma in children with cleft palate: experience from 18 surgical cases. *Int J Pediatr Otorhinolaryngol* 2014; 78: 918-22.
9. Bacciu A, Pasanisi E, Vincenti V, et al. Surgical treatment of middle ear cholesteatoma in children with Down syndrome. *Otol Neurotol* 2005; 26: 1007-10.
10. O'Malley MR, Kaylie DM, Van Himbergen DJ, Bennett ML. Chronic ear surgery in patients with syndromes and multiple congenital malformations. *Laryngoscope* 2007; 117: 1993-8.
11. Lim DB, Gault EG, Kubba H, Morrissey MS, Wynne DM, Donaldson MD. Cholesteatoma has a high prevalence in Turner syndrome, highlighting the need for earlier diagnosis and the potential benefits of otoscopy training for pediatricians. *Acta Pediatr* 2014; 103: e282-287.
12. Mondain M, Restituito S, Vincenti V, et al. Adenovirus-mediated in vivo transfer in guinea pig middle ear mucosa. *Human Gene Therapy* 1998; 1217-21.
13. Committee on hearing and equilibrium guidelines for the evaluation of results of treatment of conductive hearing loss. *Otolaryngol Head Neck Surg* 1995; 113: 186-7.
14. Harker L.A. Cholesteatoma: an incidence study, in: Cholesteatoma: First International Conference, Aesculapius Publishing Company, Birmingham, AL, 1977; 308-309.
15. Bergamaschi R, Bergonzoni C, Mazzanti L, et al. Hearing loss in Turner syndrome: results of a multicentric study. *J Endocrinol Invest* 2008; 31: 779-83.
16. Hall JE, Richter GT, Choo DI. Surgical management of otologic disease in pediatric patients with Turner syndrome. *Int J Pediatr Otorhinolaryngol* 2009; 73: 57-65.
17. Bacciu A, Pasanisi E, Vincenti V, Di Lella F, Bacciu S.

- Reconstruction of outer attic wall defects using bone patè: long-term clinical and histological evaluation. *Eur Arch Otorhinolaryngol* 2006; 263: 983-7.
18. Vincenti V, Magnan J, Saccardi MS, Zini C. Chemically assisted dissection by means of Mesna in cholesteatoma surgery. *Otol Neurotol* 2014; 35: 1819-24.
  19. Vincenti V, Magnan J, Zini C. Cochlear effects of intraoperative use of Mesna in cholesteatoma surgery. *Acta Biomed* 2014; 85: 30-4.
  20. Prasad SC, La Melia C, Medina M, et al. Long-term surgical and functional outcomes of intact canal wall technique for middle ear cholesteatoma in the pediatric population. *Acta Otorhinolaryngol Ital* 2014; 34: 354-61.
  21. Bacciu A, Di Lella F, Pasanisi E, et al. Open vs closed type congenital cholesteatoma of the middle ear: two distinct entities or two aspects of the same phenomenon? *Int J Pediatr Otorhinolaryngol* 2014; 78: 2205-9.
- 
- Received: 30 April 2016  
Accepted: 3 May 2016  
Correspondence:  
Prof. Vincenzo Vincenti  
Department of Clinical and Experimental Medicine,  
Unit of Audiology and Pediatric Otorhinolaryngology,  
University of Parma, Italy  
Via Gramsci, 14 - 43126 Parma (Italy)  
Tel. +39 0521 703204  
Fax +39 0521 703788,  
E-mail: vincenzo.vincenti@unipr.it