

Transesophageal echocardiography and fluoroscopy for percutaneous closure of atrial septal defects

A comparative study

Weize Xu, MS*, Jianhua Li, MS, Jingjing Ye, MD, Jin Yu, MS, Jiange Yu, MD, Zewei Zhang, MS

Abstract

The aim of the study was to compare transesophageal echocardiography (TEE) and fluoroscopy for percutaneous atrial septal defect (ASD) closure.

This was a retrospective analysis of children who underwent percutaneous ASD closure. The procedure was guided by TEE without fluoroscopy in 130 patients (TEE group) and by fluoroscopy in 163 patients (fluoroscopy group). Baseline demographic/clinical characteristics were recorded. Patients were followed until hospital discharge. Outcomes were procedure duration, peri/postoperative complications, hospital stay, and costs.

The TEE and fluoroscopy groups showed no significant differences in age (71.7 ± 40.7 vs 62.5 ± 38.8 months), male/female ratio (54/76 vs 66/97), weight (22.0 ± 12.0 vs 20.1 ± 9.0 kg), ASD diameter (9.9 ± 4.2 vs 9.3 ± 3.9 cm), distances to the superior vena cava (13.4 ± 4.6 vs 13.3 ± 4.2 cm), inferior vena cava (13.4 ± 4.3 vs 13.9 ± 4.1 cm) and atrial septal roof (12.1 ± 4.0 vs 12.3 ± 3.2 cm), or atrial septal size (38.2 ± 6.2 vs 39.4 ± 26.6 cm); distance to the mitral valve was greater in the TEE group (13.2 ± 4.4 vs 11.3 ± 3.9 cm; $P < .001$). The TEE and fluoroscopy groups showed no significant differences in occlusion device size (14.3 ± 4.6 vs 13.8 ± 4.0 cm) or sheath size (8.7 ± 1.8 vs 8.7 ± 0.9 cm), but procedure duration was shorter in the TEE group (21.5 ± 14.6 vs 28.6 ± 10.9 minutes; $P < .001$). Postoperative fever ($>38^\circ\text{C}$) occurred less frequently in the TEE group than in the fluoroscopy group (0.8% vs 9.2%; $P < .001$); there were no significant differences for the other complications. No patient had postoperative residual shunt, occlusion device shedding/displacement, or pericardial effusion. The TEE group had longer hospital stay (3.2 ± 0.6 vs 2.9 ± 0.6 days; $P < .001$) and higher procedure cost ($29,687 \pm 4218$ vs $28,530 \pm 1668$ CNY (China Yuan); $P = .002$) than the fluoroscopy group.

TEE-guided percutaneous ASD closure can be used as an alternative to fluoroscopy-guided procedures and avoids the use of radiation or contrast agents.

Abbreviations: ASD = atrial septal defect, IVC = inferior vena cava, SVC = superior vena cava, TEE = transesophageal echocardiography, TTE = transthoracic echocardiography.

Keywords: atrial septal defect, children, fluoroscopy, septal occluder device, transesophageal echocardiography

1. Introduction

Congenital heart diseases are the most common congenital anomalies, with an incidence of 4 to 10 per 1000 live births.^[1,2] Atrial septal defect (ASD) is one of the most frequently encountered congenital heart diseases, with an estimated

prevalence of 3.89 per 1000 children and 0.88 per 1000 adults.^[1] The clinical course of ASD is variable and depends on the lesion characteristics, with presenting symptoms including dyspnea, fatigue, exercise intolerance, palpitations, syncope, peripheral edema secondary to right heart failure, and recurrent chest infections.^[3] Early diagnosis and treatment of ASD can avoid serious complications.

Management of ASD involves percutaneous device closure or open-heart surgery. Percutaneous closure is a minimally invasive technique with good efficacy and safety that is generally preferred to open-heart surgery, which is highly invasive that necessitates cardiopulmonary bypass, cardioplegia, thoracotomy, sternotomy, and longer surgical time, leading to a higher rate of complications.^[4-7] Percutaneous closure of ASD under fluoroscopic guidance is now considered a routine procedure and studies using a variety of devices have reported good success and low complication rates in children and adults.^[8-17]

Nevertheless, radiation exposure during fluoroscopy represents a risk to the patient and medical staff.^[18-20] Because percutaneous ASD closure under fluoroscopic guidance is usually carried out with the assistance of transesophageal echocardiography (TEE) or transthoracic echocardiography (TTE),^[9,11,12,14,17,21-34] it has been suggested that echocardiography alone could be used to guide device placement. TEE or TTE

Editor: Phil Phan.

This work was supported by the Education Department of Zhejiang Province, China (No. Y201636526).

Conflicts of Interest: The authors declare that they have no conflict of interest.

Heart Center, Children's Hospital, Zhejiang University School of Medicine, Hangzhou, China.

* Correspondence: Weize Xu, Heart Center, Children's Hospital, Zhejiang University School of Medicine, Hangzhou 310052, China (e-mail: 120heart@zju.edu.cn).

Copyright © 2018 the Author(s). Published by Wolters Kluwer Health, Inc. This is an open access article distributed under the terms of the Creative Commons Attribution-Non Commercial-No Derivatives License 4.0 (CCBY-NC-ND), where it is permissible to download and share the work provided it is properly cited. The work cannot be changed in any way or used commercially without permission from the journal.

Medicine (2018) 97:43(e12891)

Received: 4 July 2018 / Accepted: 25 September 2018

<http://dx.doi.org/10.1097/MD.00000000000012891>

without fluoroscopy have been used successfully to guide peratrial or perventricular repair of ventricular septal defects.^[4,7–9,21,22,26,30,31,35–40] Some studies have reported the use of TEE or TTE to guide percutaneous ASD closure without fluoroscopy.^[37–42] Nevertheless, data about the direct comparison of the efficacy and safety between TEE-guided and fluoroscopy-guided procedures are limited.

Over the past 2 years, our hospital has carried out TEE-guided percutaneous ASD closure without fluoroscopy. Therefore, the aim of this retrospective study was to comparatively assess TEE-guided and fluoroscopy-guided percutaneous ASD closure in our hospital.

2. Patients and methods

2.1. Patients

This was a retrospective analysis of children who underwent percutaneous ASD closure at our hospital (China) between November 2014 and January 2017. The procedure was guided by TEE without fluoroscopy in 130 patients (TEE group) and by fluoroscopy in 163 patients (fluoroscopy group). The indications for surgery were the same in all patients. The inclusion criteria were preoperative diagnosis of isolated type II ASD based on medical history, clinical signs, chest x-ray, electrocardiogram, and TTE and determined as being suitable for percutaneous closure following an outpatient TTE study from the standard subcostal, apical 4-chamber and parasternal short-axis views: ostium secundum ASD with a diameter ≥ 5 and ≤ 36 mm that increased right ventricular volume load; ≥ 5 mm from the edge of the defect to the superior vena cava (SVC), inferior vena cava (IVC), coronary sinus, and pulmonary vein and ≥ 7 mm from the edge of the defect to the atrioventricular valve; diameter of the atrial septum larger than the diameter of the left atrial side of the selected occluder; and no other heart disease requiring surgery. The exclusion criteria were severe pulmonary hypertension or evidence of an infectious disease or any other condition that would be a contraindication for surgery. The study was approved by the institutional ethics committee of the Children's Hospital, Zhejiang University School of Medicine. Informed written consent was obtained from the legal guardians to perform the procedure. The need for individual consent for this particular study was waived by the committee because of the retrospective nature of the study.

2.2. Preoperative evaluation

Careful examination was carried out of the location, number, size, and morphology of the ASD, the distance of the ASD to the SVC, IVC, atrioventricular (mitral) valve and roof of the atrial septum, and the dimensions of the atrial septum.

2.3. Baseline demographic and clinical characteristics

Age, sex, weight, ASD diameter, distance to the SVC, distance to the IVC, distance to the mitral valve, distance to the roof of the atrial septum, and dimensions of the atrial septum were extracted from the medical charts.

2.4. Procedures

Because some surgeons and cardiologist in our center were not trained for TEE-guided procedure without fluoroscopy, 2 different teams performed the TEE-guided and fluoroscopy-guided

procedures. All devices were made by Shanghai Shape Memory Alloy Material Co. Ltd (Shanghai, China) and LifeTech Technology Co. Ltd (Shenzhen, China). The equipment is shown in Figure 1.

2.4.1. TEE-guided percutaneous ASD closure. All surgeons were qualified in cardiac surgery and congenital heart disease intervention by the National Health and Family Planning Commission for Cardiovascular Disease Interventional Therapy, and had received cardiothoracic surgery and interventional cardiology fellowship training and performed the procedures (Fig. 2). After total intravenous and endotracheal anesthesia (midazolam 0.1–0.2 mg/kg, propofol 2 mg/kg, rocuronium bromide 0.9 mg/kg, and fentanyl 5–10 μ g/kg), we reevaluated the ASD by TEE from various views. Generally, the right femoral vein was used as the catheter path and a 5F arterial sheath was inserted after puncture. Heparin (100 units/kg) was administered intravenously before the procedure. Under the guidance of TEE, the 5F MP catheter was placed into the left pulmonary vein through the ASD. The guide was inserted into the delivery sheath, and the occlusion device was fed along the delivery sheath into the left atrium. The left atrial plate was released after withdrawal of the delivery system to close the atrial septum and the outer sheath was retracted to release the occlusion device waist and right atrial plate, so that the atrial septum was between the left and right umbrella folder. Multiple TEE views and final pull-push tests were used to evaluate the position of the occlusion device, the presence of residual shunt, the condition of the valve, the relationship between the occlusion device and the coronary sinus, SVC, IVC, and pulmonary vein, and the presence or absence of pericardial effusion. The occlusion device was released under TEE guidance. Additional verifications were made for correct the positioning of the device, residual leak, and any other defects, and to ensure that the atrioventricular valves, pulmonary veins, SVC, and IVC were not altered or obstructed. After determining that the occlusion device had been released successfully (correct location and shape of the umbrella folders, with absence of shunt around the occlusion in the ultrasound examination), the delivery system was removed, with appropriate routine care.

2.4.2. Fluoroscopy-guided percutaneous ASD closure. The patients were received intravenous anesthesia (midazolam 0.1–0.2 mg/kg, propofol 2 mg/kg, and pentazocine 0.3 mg/kg) and caudal block (lidocaine; 0.67% for patients weighing 10–15 kg, 0.8% for patients weighing 15–25 kg; total dose ≤ 10 mg/kg). In addition, children ≥ 12 years of age were given local anesthesia. The ASD was then reevaluated with TTE from various views. The same surgical technique was used as described above, but under the guidance of fluoroscopy. After the device was released, we evaluated the occlusion device position, residual shunt if any, the valve condition, the relationship between the occlusion device and the coronary sinus, SVC, IVC, and pulmonary vein, and the presence or absence of a pericardial effusion using multiple views of TTE and fluoroscopy and final push-pull tests. After determining that the occlusion device was successfully released, the delivery system was removed from the femoral vein puncture site, with routine care.

2.4.3. Intraoperative monitoring. During the procedure, we closely monitored the electrocardiogram, blood pressure, and other vital signs. If any abnormalities were noted, surgery was suspended and resumed after recovery. The size of the occlusion device, size of the sheath, and duration of surgery (measured from heparinization to exit of the delivery system) were recorded.

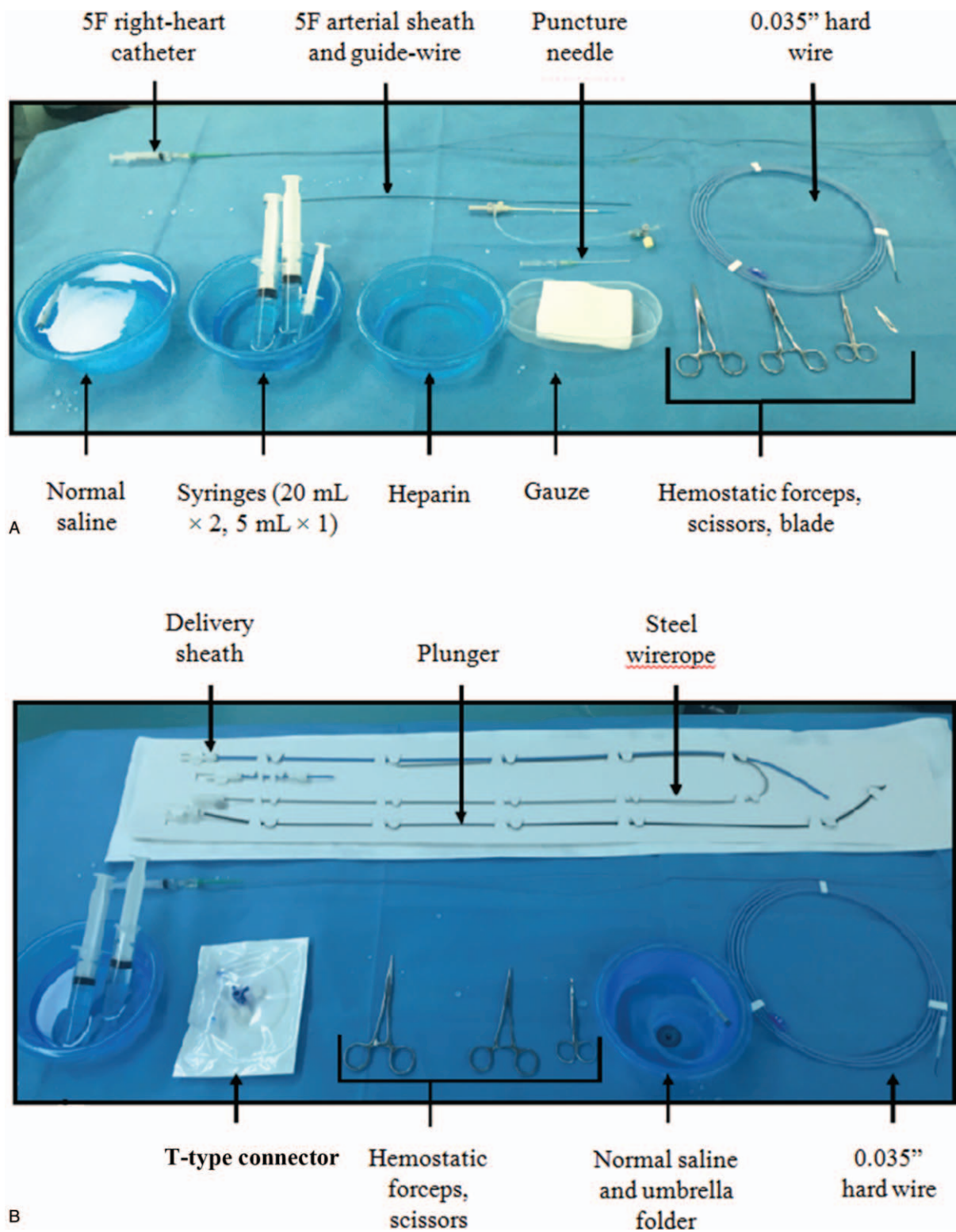


Figure 1. Equipment used for percutaneous device closure of atrial septal defect.

2.5. Follow-up and outcome measures

Patients were followed-up until discharge from hospital. The outcome measures were procedure duration, peri/postoperative complications, hospital stay, and costs.

2.6. Statistical analysis

Statistical analyses were performed using SPSS 20.0 (IBM Corp, Armonk, NY). Values are presented as mean ± standard deviation or n (%). Comparisons between the TEE and fluoroscopy

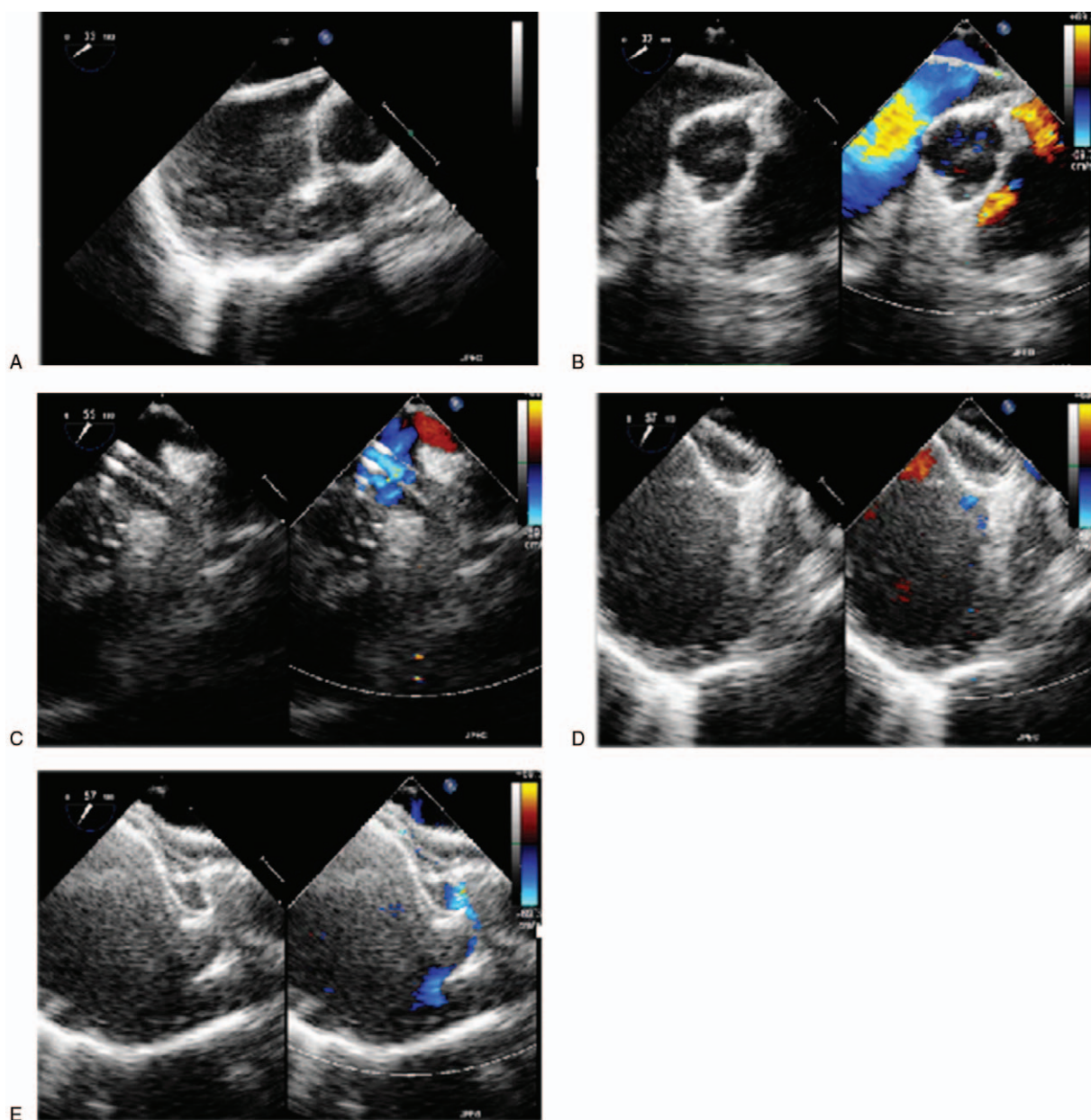


Figure 2. Percutaneous device closure of atrial septal defect (ASD) under the guidance of transesophageal echocardiography (TEE). A, The catheter was inserted into the right atrium via the inferior vena cava and passed into the left atrium via the atrial septal defect, under the guidance of TEE. B, The guidewire was inserted into the catheter and the catheter was inserted into the left pulmonary vein or left atrium under the guidance of TEE. C, The sheath was delivered to the left atrium under the guidance of TEE. D, The left atrial umbrella folder was expanded under the guidance of TEE. E, The right atrial umbrella folder was expanded under the guidance of TEE.

groups were made using Student *t* test, the chi-square test, or the Fisher exact test, as appropriate. Statistical significance was defined as $P < .05$.

3. Results

3.1. Baseline demographic and clinical characteristics

The TEE group ($n=130$) consisted of 54 men and 76 women; mean age was 71.7 ± 40.7 months (14–188 months) and mean body weight was 22.0 ± 12.0 kg (9.6–77.0 kg). The fluoroscopy group ($n=163$) consisted of 66 men and 97 women; mean age

was 62.5 ± 38.8 months (12–192 months) and mean body weight was 20.1 ± 9.0 kg (9.4–53.5 kg). There were no significant differences between the 2 groups in male/female ratio ($P=.86$), age ($P=.051$), or weight ($P=.134$). No patient had pulmonary hypertension.

3.2. ASD characteristics

As presented in Table 1, the 2 groups showed no significant differences in ASD diameter (9.9 ± 4.2 vs 9.3 ± 3.9 cm), distance to SVC (13.4 ± 4.6 vs 13.3 ± 4.2 cm), distance to IVC (13.4 ± 4.3 vs 13.9 ± 4.1 cm), distance to the roof of the atrial septum (12.1 ± 4.0

Table 1

Comparison of atrial septal defect characteristics between the transesophageal echocardiography and fluoroscopy groups.

	TEE group (n=130)	Fluoroscopy group (n=163)	P
ASD diameter, cm	9.9±4.2	9.3±3.9	.270
Distance to SVC, cm	13.4±4.6	13.3±4.2	.869
Distance to IVC, cm	13.4±4.3	13.9±4.1	.412
Distance to mitral valve, cm	13.2±4.4	11.3±3.9	<.001
Distance to atrial septal roof, cm	12.1±4.0	12.3±3.2	.701
Size of atrial septum, cm	38.2±6.2	39.5±26.6	.794

Data are presented as means ± standard deviation.
ASD = atrial septal defect, IVC = inferior vena cava, SVC = superior vena cava, TEE = transesophageal echocardiography.

vs 12.3 ± 3.2 cm), or atrial septal size (38.2 ± 6.2 vs 39.5 ± 26.6 cm). The distance to the mitral valve was significantly greater in the TEE group than in the fluoroscopy group (13.2 ± 4.4 vs 11.3 ± 3.9 cm; *P* < .001).

3.3. Procedure characteristics

Table 2 shows that there were no differences between the TEE and fluoroscopy groups showed regarding the size of the occlusion device (14.3 ± 4.6 vs 13.8 ± 4.0 cm) or the size of the sheath (8.7 ± 1.8 vs 8.7 ± 0.9 cm). The procedure duration was significantly shorter in the TEE group compared with the fluoroscopy group (21.5 ± 14.6 vs 28.6 ± 10.9 minutes; *P* < .001).

3.4. Complications

Postoperative fever (>38°C) occurred less frequently in the TEE group than in the fluoroscopy group (1/130, 0.8% vs 15/163, 9.2%; *P* < .001). There were no significant differences between groups for the occurrence of other complications (Table 3). No patient had postoperative residual shunt, occlusion device shedding or displacement, or pericardial effusion.

3.5. Postoperative hospital stay and procedure cost

Postoperative hospital stay was longer in the TEE group than in the fluoroscopy group (3.2 ± 0.6 vs 2.9 ± 0.6 days; *P* < .001). Total procedure costs were higher in the TEE group than in the fluoroscopy group (29,687 ± 4218 vs 28,530 ± 1668 RMB, where 1 RMB = 0.15 US dollar; *P* = .002).

4. Discussion

An important finding of the present study was that percutaneous ASD closure was achieved successfully in all patients. The

Table 2

Comparison of the procedure characteristics between the transesophageal echocardiography and fluoroscopy groups.

	TEE group (n=130)	Fluoroscopy group (n=163)	P
Atrial septal defect diameter, cm	9.9±4.2	9.3±3.9	.270
Size of occlusion device, cm	14.3±4.6	13.8±4.0	.306
Size of sheath, cm	8.7±1.8	8.7±0.9	.771
Procedure duration, min*	21.5±14.6	28.6±10.9	<.001

Data are presented as means ± standard deviation. TEE = transesophageal echocardiography.
* From heparin injection to removal of the sheath.

Table 3

Comparison of postoperative complications between the transesophageal echocardiography and fluoroscopy groups.

	TEE group (n=130)	Fluoroscopy group (n=163)	P
Atrioventricular block	0	1 (0.6%)	NA
Fever (>38°C)	1 (0.8%)	15 (9.2%)	.002
Cough	0	4 (2.5%)	.300
Diarrhea	0	1 (0.6%)	NA
All complications	1 (0.8%)	21 (12.9%)	

Data are presented as n (%).
NA = not applicable, TEE = transesophageal echocardiography.

procedure duration was about 7 minutes shorter (~25%) in the TEE group than in the fluoroscopy group. Furthermore, postoperative fever occurred less frequently in the TEE group than in the fluoroscopy group, with no significant differences for the other complications. No patients had postoperative residual shunt, occlusion device shedding/displacement, or pericardial effusion. Compared with fluoroscopy-guided closure, minor disadvantages of TEE-guided percutaneous ASD closure were a slightly longer hospital stay (~6 hours) and higher costs (by ~1157 RMB, equivalent to ~175 USD). The main innovation of this method is the completion of ASD closure completely guided by ultrasound, which is not routine practice. In most centers, closure of ASD is completed under digital subtraction angiography and ultrasound. Avoiding radiations should have a certain significance on the long-term health of the children and medical staff. Therefore, we suggest that TEE-guided percutaneous ASD closure is a good alternative to fluoroscopy-guided procedures in children.

Numerous studies have reported the use of fluoroscopy-guided procedures for the percutaneous closure of ASD and most of these studies used fluoroscopy in combination with TEE or TTE.^[9,11,12,14,17,21,22] Previous studies in pediatric patients using procedures guided by both fluoroscopy and TEE or TTE have reported successful implantation rates of 93% to 100%, low complication rates of 0% to 20% (predominantly minor complications), and good long-term outcomes.^[8,10,14,15,17] In the present study, the fluoroscopy group showed a successful implantation rate of 100% and the complication rate was 13%, which are in agreement with the previous studies.^[8,10,14,15,17] Importantly, successful implantation was also achieved for all patients of the TEE group, and the complication rate was lower. There were no postoperative residual shunt or occlusion device shift, and postoperative cardiac function was normal in all patients. There was 1 case of atrioventricular block in the fluoroscopy group and the incidence of postoperative fever was lower in the TEE group than in the fluoroscopy group. Although the 2 groups received different anesthesia regimens, there were no differences in anesthesia-related complications.

Only a few previous studies reported the use of TEE-guided percutaneous ASD closure without fluoroscopy. Consistent with our series, these studies achieved successful ASD closure under TEE guidance alone in a high proportion of patients (86%–100%) with low complication rates.^[38–42] Therefore, we consider that percutaneous ASD closure under TEE guidance alone is an effective and safe procedure. Nevertheless, the distance to the mitral valve must be considered carefully because it can complicate the procedure if the distance is too short.^[43,44]

Mean procedure duration for fluoroscopy-guided percutaneous ASD closure has been reported to range from 40 to 110 minutes, although it should be noted that the definition of total the procedure time varied among studies.^[9,14,15,17] In the present study, procedure time (measured from heparinization to removal of the delivery system) was significantly shorter in the TEE group (21.5 ± 14.6 minutes) than in the fluoroscopy group (28.6 ± 10.9 minutes). Ewert et al^[41] also reported numerically shorter duration for TEE-guided ASD closure (88 minutes) than for conventional fluoroscopy-guided ASD closure (100 minutes), but the difference was not statistically significant ($P=.09$). A number of reasons may be responsible for the difference between the 2 procedures. First, the image obtained with TEE is clear, allowing an accurate assessment of ASD location, size, and shape. This facilitates the selection of the appropriate occlusion device for first-time closure success. Secondly, TEE can display the shape of the steel wire, sheath, and occlusion device in real time, thereby facilitating the assessment of residual shunt and the effect of the occlusion device on the atrioventricular valve, pulmonary vein, vena cava, and coronary sinus opening. This greatly reduces the operative time. Indeed, among all patients in the present series, the fastest procedure took only 6 minutes. Thirdly, x-ray digital equipment is unable to display the anatomic structure of the heart accurately. During the closure process, the requirement to rotate the equipment and the need for repeated TEE increase the procedure time.

A potentially important advantage of TEE-guided percutaneous closure over fluoroscopy-guided closure is that it avoids exposure to radiation and contrast agents. In addition to reducing the risks for the patient, TEE-guided percutaneous closure without fluoroscopy also prevents radiation to the medical staff and avoids the need for heavy lead clothing. In our hospital if the ASD is found unsuitable for percutaneous closure or if the procedure fails, the procedure can be converted immediately to a TEE-guided thoracotomy or cardiopulmonary bypass surgery. This insures patient safety.

This study has some limitations. First, this was a retrospective analysis and may be prone to selection bias or information bias. In addition, the strength of the evidence is not as high as that of a prospective study. Secondly, this was a single-center study and the generalizability of the findings is unknown. Thirdly, although the sample size was not particularly small, the study may have been underpowered to detect certain differences between groups. Fourthly, the follow-up was short, so longer-term outcomes could not be assessed. Finally, the 2 procedures were performed by 2 different teams of surgeons, but the 2 teams has similar work experience and all surgeons were qualified in cardiac surgery and congenital heart disease intervention by the National Health and Family Planning Commission for Cardiovascular Disease Interventional Therapy, and had received cardiothoracic surgery and interventional cardiology fellowship training. In addition, prospective, randomized trials are needed to confirm and extend our observations.

In conclusion, TEE-guided percutaneous ASD closure has similar short-term outcomes to fluoroscopy-guided closure, but shortens the procedure and avoids the use of radiation or contrast agents. The main innovation of this method is the completion of ASD closure completely guided by ultrasound, which is not routine practice. Avoiding radiations should have a certain significance on the long-term health of the children and medical staff.

Acknowledgments

The authors thank Dr. Xia Chengsen for providing technical support. The authors are grateful to our colleagues in the cardiac

surgery, cardiology, and ultrasound departments for supporting our work.

Author contributions

Conceptualization: Weize Xu.

Data curation: Weize Xu, Jianhua Li, Jingjing Ye, Jin Yu, Jianguen Yu, Zewei Zhang.

Formal analysis: Weize Xu, Jianhua Li, Jingjing Ye, Jin Yu, Jianguen Yu, Zewei Zhang.

Funding acquisition: Weize Xu.

Project administration: Weize Xu.

Writing – original draft: Weize Xu.

Writing – review and editing: Jianhua Li, Jingjing Ye, Jin Yu, Jianguen Yu, Zewei Zhang.

References

- Marelli AJ, Mackie AS, Ionescu-Ittu R, et al. Congenital heart disease in the general population: changing prevalence and age distribution. *Circulation* 2007;115:163–72.
- Miranovic V. The incidence of congenital heart disease: previous findings and perspectives. *Srp Arh Celok Lek* 2014;142:243–8.
- Martin SS, Shapiro EP, Mukherjee M. Atrial septal defects—clinical manifestations, echo assessment, and intervention. *Clin Med Insights Cardiol* 2014;8:93–8.
- Butera G, Biondi-Zoccai G, Sangiorgi G, et al. Percutaneous versus surgical closure of secundum atrial septal defects: a systematic review and meta-analysis of currently available clinical evidence. *EuroIntervention* 2011;7:377–85.
- Butera G, Carminati M, Chessa M, et al. Percutaneous versus surgical closure of secundum atrial septal defect: comparison of early results and complications. *Am Heart J* 2006;151:228–34.
- Du ZD, Hijazi ZM, Kleinman CS, et al. Comparison between transcatheter and surgical closure of secundum atrial septal defect in children and adults: results of a multicenter nonrandomized trial. *J Am Coll Cardiol* 2002;39:1836–44.
- Moore J, Hegde S, El-Said H, et al. Transcatheter device closure of atrial septal defects: a safety review. *JACC Cardiovasc Interv* 2013;6:433–42.
- Praz F, Wahl A, Schmutz M, et al. Safety, feasibility, and long-term results of percutaneous closure of atrial septal defects using the Amplatzer septal occluder without periprocedural echocardiography. *J Invasive Cardiol* 2015;27:157–62.
- Kaya Y, Yurtdas M, Ceylan Y, et al. Percutaneous closure of secundum atrial septal defects in pediatric and adult patients: short- and mid-term follow-up results. *Turk Kardiyol Dern Ars [in Turkish]* 2013;41:705–13.
- Knop M, Szkutnik M, Fiszler R, et al. Transcatheter closure of atrial septal defect in children up to 10 kg of body weight with Amplatzer device. *Cardiol J* 2014;21:279–83.
- Saritas T, Kaya MG, Lam YY, et al. A comparative study of Cardi-O-Fix septal occluder versus Amplatzer septal occluder in percutaneous closure of secundum atrial septal defects. *Catheter Cardiovasc Interv* 2013;82:116–21.
- Tomar M, Khatri S, Radhakrishnan S, et al. Intermediate and long-term followup of percutaneous device closure of fossa ovalis atrial septal defect by the Amplatzer septal occluder in a cohort of 529 patients. *Ann Pediatr Cardiol* 2011;4:22–7.
- Pac A, Polat TB, Cetin I, et al. Figulla ASD occluder versus Amplatzer Septal Occluder: a comparative study on validation of a novel device for percutaneous closure of atrial septal defects. *J Interv Cardiol* 2009;22:489–95.
- Rossi RI, Cardoso Cde O, Machado PR, et al. Transcatheter closure of atrial septal defect with Amplatzer device in children aged less than 10 years old: immediate and late follow-up. *Catheter Cardiovasc Interv* 2008;71:231–6.
- Diab KA, Cao QL, Bacha EA, et al. Device closure of atrial septal defects with the Amplatzer septal occluder: safety and outcome in infants. *J Thorac Cardiovasc Surg* 2007;134:960–6.
- Pedra CA, Pedra SF, Esteves CA, et al. Initial experience in Brazil with the Helix septal occluder for percutaneous occlusion of atrial septal defects. *Arq Bras Cardiol* 2003;81:435–52.
- Butera G, De Rosa G, Chessa M, et al. Transcatheter closure of atrial septal defect in young children: results and follow-up. *J Am Coll Cardiol* 2003;42:241–5.

- [18] Kleinerman RA. Cancer risks following diagnostic and therapeutic radiation exposure in children. *Pediatr Radiol* 2006;36(suppl 2):121–5.
- [19] Wagdi P, Ritter M. Patient radiation dose during percutaneous interventional closure of interatrial communications. *J Cardiol* 2009;53:368–73.
- [20] Yakoumakis EN, Gialousis GI, Papadopoulou D, et al. Estimation of children's radiation dose from cardiac catheterisations, performed for the diagnosis or the treatment of a congenital heart disease using TLD dosimetry and Monte Carlo simulation. *J Radiol Prot* 2009;29:251–61.
- [21] Baykan A, Pamukcu O, Ozyurt A, et al. Is it safe to close ASD with the guidance of transthoracic echocardiography in pediatric population “ten years' experience of a single center”. *J Interv Cardiol* 2015;28:172–9.
- [22] Lodato JA, Cao QL, Weinert L, et al. Feasibility of real-time three-dimensional transoesophageal echocardiography for guidance of percutaneous atrial septal defect closure. *Eur J Echocardiogr* 2009;10:543–8.
- [23] Choudhari MS, Charan N, Sonkusale MI, et al. Inadvertent diversion of inferior vena cava to left atrium after repair of atrial septal defect—early diagnosis and correction of error: role of intraoperative transesophageal echocardiography. *Ann Card Anaesth* 2017;20:481–2.
- [24] Sung Y, Cho JS, Youn HJ. Real time three-dimensional transesophageal echocardiography imaging of crescent-shaped superior sinus venosus atrial septal defect. *Echocardiography* 2017;34:147–8.
- [25] Jain PK, Malik V, Kapoor PM. Transesophageal echocardiography for minimally invasive cardiac surgery-atrial septal defect closure. *Ann Card Anaesth* 2016;19:527–9.
- [26] Aggarwal N, Gadhinglajkar S, Sreedhar R, et al. Warden repair for superior sinus venosus atrial septal defect and anomalous pulmonary venous drainage in children: Anesthesia and transesophageal echocardiography perspectives. *Ann Card Anaesth* 2016;19:293–9.
- [27] Kuroda M, Kumakura M, Sato T, et al. The usefulness of three-dimensional transesophageal echocardiography for a primum atrial septal defect. *Anesth Analg* 2015;121:1151–4.
- [28] Zhang Y, Song H, Qiao X, et al. Detection and diagnosis of iatrogenic inadvertent diversion of partial inferior vena cava into the left atrium by transesophageal echocardiography during large posteroinferior surgical atrial septal defect closure. *J Anesth* 2015;29:442–5.
- [29] Kobayashi T. Monitoring tool of transcatheter atrial septal defect: transesophageal echocardiography or transthoracic echocardiography? *J Cardiol* 2015;65:1.
- [30] Nyrcnes SA, Lovstakken L, Dohlen G, et al. Blood flow imaging in transesophageal echocardiography during atrial septal defect closure: a comparison with the current references. *Echocardiography* 2015;32:34–41.
- [31] Roberson DA, Cui VW. Three-dimensional transesophageal echocardiography of atrial septal defect device closure. *Curr Cardiol Rep* 2014;16:453.
- [32] Cakal B, Cakal S, Arslan K, et al. Dehiscence of an atrial septal defect patch: evaluation using three-dimensional transesophageal echocardiography. *Herz* 2015;40:455–6.
- [33] Demirkol S, Barcin C, Balta S, et al. Percutaneous closure of second secundum atrial septal defect under guidance of three-dimensional transesophageal echocardiography guidance. *Anadolu Kardiyol Derg* 2013;13:E22–3.
- [34] Seo JS, Song JM, Kim YH, et al. Effect of atrial septal defect shape evaluated using three-dimensional transesophageal echocardiography on size measurements for percutaneous closure. *J Am Soc Echocardiogr* 2012;25:1031–40.
- [35] Hongxin L, Zhang N, Wenbin G, et al. Peratrial device closure of perimembranous ventricular septal defects through a right parasternal approach. *Ann Thorac Surg* 2014;98:668–74.
- [36] Zhang GC, Chen Q, Cao H, et al. Minimally invasive periventricular device closure of ventricular septal defect in infants under transthoracic echocardiographic guidance: feasibility and comparison with transesophageal echocardiography. *Cardiovasc Ultrasound* 2013;11:8.
- [37] Kardon RE, Sokoloski MC, Levi DS, et al. Transthoracic echocardiographic guidance of transcatheter atrial septal defect closure. *Am J Cardiol* 2004;94:256–60.
- [38] Lu H, Chen L, Zhang G, et al. Clinical evaluation of percutaneous atrial septal defect closer guided by transthoracic echocardiography and/or transesophageal echocardiography [in Chinese]. *Zhong Nan Da Xue Xue Bao Yi Xue Ban* 2015;40:646–50.
- [39] Pan XB, Ou-Yang WB, Pang KJ, et al. Percutaneous closure of atrial septal defects under transthoracic echocardiography guidance without fluoroscopy or intubation in children. *J Interv Cardiol* 2015;28:390–5.
- [40] Pan XB, Pang KJ, Hu SS, et al. Safety and efficacy of percutaneous transcatheter closure of atrial septal defect under transesophageal echocardiography guidance in children [in Chinese]. *Zhonghua Xin Xue Guan Bing Za Zhi* 2013;41:744–6.
- [41] Ewert P, Berger F, Daehnert I, et al. Transcatheter closure of atrial septal defects without fluoroscopy: feasibility of a new method. *Circulation* 2000;101:847–9.
- [42] Ewert P, Daehnert I, Berger F, et al. Transcatheter closure of atrial septal defects under echocardiographic guidance without X-ray: initial experiences. *Cardiol Young* 1999;9:136–40.
- [43] Park JJ, Lee SC, Kim JB, et al. Deterioration of mitral valve competence after the repair of atrial septal defect in adults. *Ann Thorac Surg* 2011;92:1629–33.
- [44] English RF, Ettedgui JA. The distance from the Amplatzer septal occluder to the mitral valve in patients undergoing interventional closure of defects in the oval fossa increases with growth of the patient. *Cardiol Young* 2004;14:494–7.