



# Fluoroscopy-guided balloon dilation of a proximal urethral stricture caused by a urethral membrane in a female cat

Javier Rincon Alvarez<sup>1</sup>, Victoria Smith<sup>2</sup> and Cameron Broome<sup>3</sup>

*Journal of Feline Medicine and Surgery Open Reports*  
1–5

© The Author(s) 2019

Article reuse guidelines:

sagepub.com/journals-permissions

DOI: 10.1177/2055116919867177

journals.sagepub.com/home/jfmsopenreports

This paper was handled and processed by the European Editorial Office (ISFM) for publication in *JFMS Open Reports*



## Abstract

**Case summary** A proximal urethral stricture was diagnosed by retrograde urethrogram in a 2-year-old female neutered cat, which was referred following a 2-month history of stranguria, pollakiuria and urinary incontinence. Cystoscopic examination confirmed the presence of a severe narrowing of the proximal urethra near to the bladder neck, consisting of a membrane arising from the urethral mucosa. Fluoroscopy-guided balloon dilation was performed. Twelve months after the procedure, the cat did not show any recurrence of clinical signs.

**Relevance and novel information** To our knowledge, this is the first report of a proximal urethral stricture in a cat. Management by fluoroscopy-guided balloon dilation proved to be a successful and minimally invasive option with an excellent outcome.

**Keywords:** Urethra; urethral stricture; balloon dilation; fluoroscopy

**Accepted:** 11 July 2019

## Introduction

Feline urethral strictures are uncommon, usually occurring secondary to catheter-induced or pelvic trauma and most commonly within the mid–distal or distal urethra. Although rare, urethral strictures of presumed congenital origin have also been described in young cats.<sup>1</sup> Diagnosis, management and confirmation of the aetiology of non-trauma-induced urethral strictures can be challenging owing to the sparseness of the current literature describing affected cases and a lack of histopathology due to tissue size and difficulty in sampling.<sup>2–7</sup> Several surgical options have been described for the treatment of urethral strictures. These are invasive procedures with significant complications and variable outcomes.<sup>3,8–11</sup> This report describes the successful management of a suspected congenital proximal urethral stricture in a female cat using minimally invasive fluoroscopy-guided balloon dilation. To our knowledge, this treatment modality has not been previously reported in cats.

## Case description

A 2-year-old female neutered domestic shorthair cat was presented with a 5-week history of stranguria, pollakiuria and urinary incontinence. On initial presentation to the primary veterinarian the cat was reported to be excessively licking her vulva. This progressed to urinary incontinence when laying down and stranguria when urinating. Symptomatic treatment with cefovecin (8 mg/kg SC [Convenia; Zoetis]), meloxicam (0.05 mg/kg PO q24h [Metacam; Boehringer Ingelheim]),

<sup>1</sup>School of Veterinary Medicine, University of Glasgow, Glasgow, UK

<sup>2</sup>North Downs Specialist Referrals, Bletchingley, UK

<sup>3</sup>Veterinary Referral Hospital, Victoria, Australia

### Corresponding author:

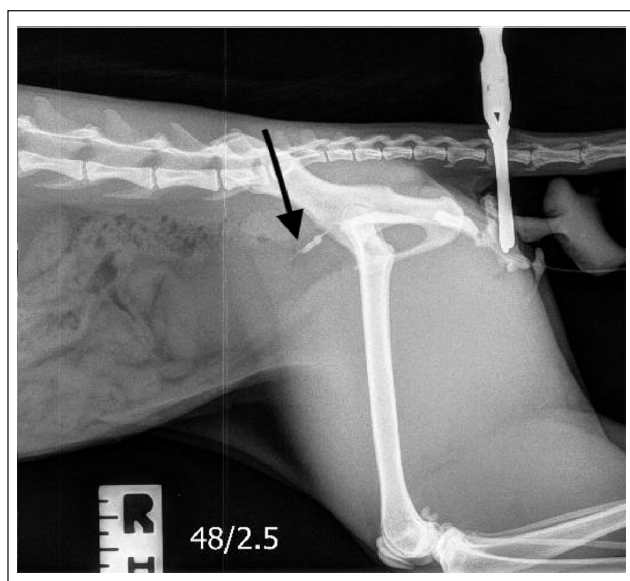
Javier Rincon Alvarez, LdoVet MRCVS, School of Veterinary Medicine, University of Glasgow, 464 Bearsden Road, Glasgow, Bearsden, G61 1QH, UK

Email: j.rincon.1@research.gla.ac.uk

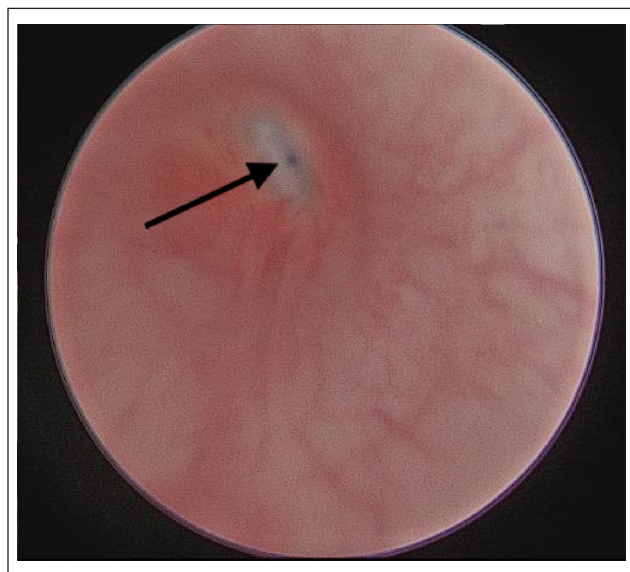


Creative Commons Non Commercial CC BY-NC: This article is distributed under the terms of the Creative Commons

Attribution-NonCommercial 4.0 License (<http://www.creativecommons.org/licenses/by-nc/4.0/>) which permits non-commercial use, reproduction and distribution of the work without further permission provided the original work is attributed as specified on the SAGE and Open Access pages (<https://us.sagepub.com/en-us/nam/open-access-at-sage>).



**Figure 1** Retrograde urethrograph showing a sharp reduction in the proximal urethral diameter (black arrow) near the bladder neck, allowing only a thin trace of contrast into the bladder



**Figure 2** Endoscopic image from the urethra at the level of the bladder neck. Membranous structure causing urethral stricture, with a small opening to the urinary bladder (black arrow), can be appreciated, preventing the cystoscope from reaching the bladder

clomipramine (5 mg PO q24h [Clomicalm; Elanco]) and urinary diet did not lead to improvement; therefore, phenylpropanolamine (1.2 mg/kg PO q24h [Propalin; Vetoquinol]) was subsequently trialled. Owing to ongoing clinical signs, an exploratory coeliotomy was performed 3 weeks later. The primary veterinarian

identified a thickened but grossly normal bladder. Ovariohysterectomy and bladder wall biopsy were performed. Histopathology revealed no abnormalities.

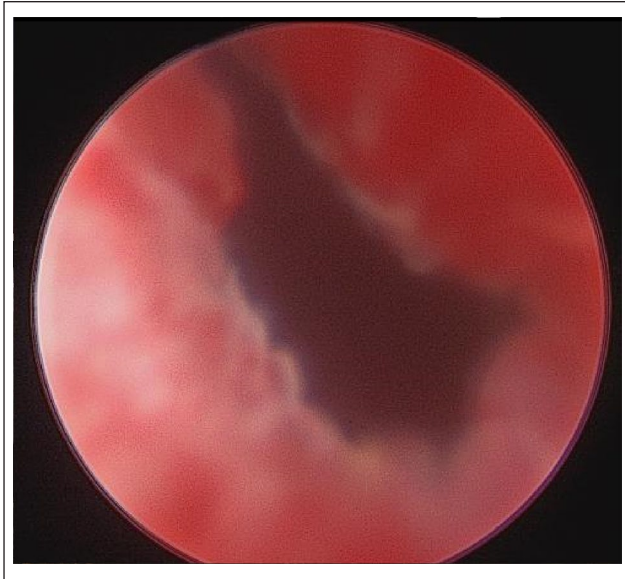
Physical examination at the referral institution was unremarkable aside from the bladder being medium sized but firm on abdominal palpation. The cat demonstrated urinary incontinence in the consultation.

Biochemistry and haematology, urinalysis and culture were performed. These were unremarkable apart from a mild elevation of urea (12.1 mmol/l [reference interval 2.7–9.2 mmol/l]). Feline leukaemia virus, feline immunodeficiency virus and coronavirus testing were negative.

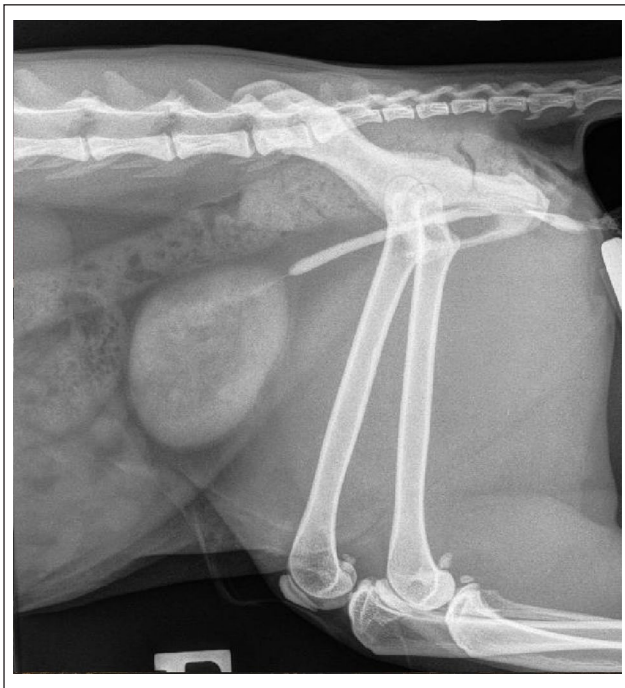
Abdominal radiographs performed under sedation (ketamine 2.5 mg/kg [Ketavet; Zoetis] and midazolam 0.2 mg/kg [Hypnovel; Roche], IM) showed a markedly distended bladder causing dorsal displacement of the descending colon. Abdominal ultrasonography showed a focal thickening of the mid dorsal bladder wall. Mild right renal pelvic dilation and diverticuli were noted without ureteral dilation. Based on the clinical history, these findings were suspected to be due to a partial urethral obstruction causing chronic bladder distension. Urethral catheterisation using a 3.5 Fr urinary catheter (KatKath; Vigon Vet) was attempted but not possible. Therefore, cystoscopy was performed under general anaesthesia. This revealed a markedly dilated urethra with an abrupt narrowing near the bladder neck. The cystoscope was unable to traverse this narrowing, precluding visual assessment of the bladder lumen. A retrograde urethrograph was performed, which confirmed the presence of caudal urethral dilation with a sharp reduction in the proximal urethral diameter near the bladder neck (Figure 1). The urethral wall appeared smooth and regular. Based on the urethroscopic and urethrography findings, a diagnosis of urethral stricture was made.

The cat was discharged with meloxicam (0.05 mg/kg PO q24h) while interventional treatment options were being considered. The owner reported improvement of clinical signs and initially elected to continue monitoring. The cat re-presented 8 weeks later with ongoing dysuria and a distended, firm bladder. Repeat biochemistry was unremarkable. Repeated abdominal ultrasonography showed the development of bilateral renal pelvic and ureteral dilation. Owing to worsened clinical signs and progression of urinary tract obstruction on ultrasonography, the cat was admitted for fluoroscopy-guided balloon dilation of the urethral stricture.

The cat was anaesthetised. While in dorsal recumbency, a 9.5 Fr cystoscope (67030 BA; Karl Storz-Endoskope) was introduced into the distal urethra. The stricture was identified as a membranous structure arising from the urethral mucosa, with a very narrow lumen leading to the bladder neck (Figure 2). A 0.014-inch guidewire was introduced into the bladder across the urethral



**Figure 3** Urethral opening post-fluoroscopic-guided balloon dilation. Note the moderate inflammation of the urethral mucosa at the level of the stricture



**Figure 4** Six-week post-balloon dilation retrograde urethrogram. Marked improvement of the previously reported urethral stricture. Although some degree of reduction of the urethral diameter can be appreciated, good contrast flow into the bladder is noted

stricture, followed by placement of a 4 Fr micro-introducer to minimally dilate the stricture. This allowed passage of a 5mm percutaneous transluminal angioplasty balloon

dilation catheter (Sterling PTA Balloon; Boston Scientific). The positioning of the balloon was confirmed and monitored by fluoroscopy. The stricture was dilated with 5ml of sterile saline introduced for 15 s into the balloon dilation catheter. Cystoscopic evaluation post-dilation revealed successful dilation of the stricture (Figure 3). The bladder lumen was evaluated with no abnormalities identified.

The cat recovered uneventfully and was hospitalised for 48 h to monitor urination. Mild pollakiuria and dysuria were noted but resolved within 48h. No urinary incontinence was noted. The cat was discharged with meloxicam (0.05 mg/kg PO q24h).

On re-evaluation 6 weeks post-stricture dilation, complete resolution of all clinical signs was reported. Serum biochemistry results were unremarkable. Abdominal ultrasonography showed resolution of the bilateral ureteral dilation with mild persistence of bilateral renal pelvic dilation. A retrograde urethrogram showed a marked improvement in the diameter of the proximal urethra at the site of the previous stricture (Figure 4). Subsequent follow-up was performed by telephone communication with both the referring veterinarian and owner. Twelve months after the procedure, the cat remained without clinical signs or complications.

## Discussion

Urethral obstruction is a common condition in cats.<sup>12</sup> It can occur as a result of the presence of urethral plugs, urolithiasis, neoplasia, granuloma formation, bladder displacement or herniation, urethral stricture or idiopathic causes.<sup>1,13,14</sup> Strictures are defined as a reduction in the diameter of the lumen of a hollow structure. This occurs owing to the presence of cicatricial tissue as a result of inflammation and has been reported in hollow organs, such as the oesophagus, the rectum, the trachea, ureters and the urethra.<sup>15,16</sup> In the present case, the lesion was considered a stricture, as its location did not correlate with a natural narrowing point of the urethra. Furthermore, it was located proximally at its widest point. To our knowledge, the proximal nature of the stricture is thought to be a novel clinical finding, as previous literature only describes the presence of distal or mid urethral strictures in cats.<sup>1</sup>

Urethral strictures are usually sequelae of malignancy, pelvic trauma, severe inflammation or surgical intervention.<sup>9,11,14</sup> From the case history, stricture formation was considered congenital in origin based on signalment and the lack of trauma, urethral catheterisation or surgical intervention prior to presentation. In addition, the presence of the membranous structure separating both cavities suggests a congenital origin. Despite the lack of histopathology, it was considered to be a membrane based on the correlation of its clinical appearance and the definition of a membrane as a 'thin layer of



tissue separating two cavities'.<sup>15</sup> It was hypothesised that the membrane originated from the urethral mucosa. A similar finding has been reported in a dog with partial urethral obstruction, which was also suspected to be congenital in origin.<sup>7</sup>

Urethral strictures typically present with clinical signs of dysuria and pollakiuria owing to partial or complete lower urinary tract obstruction.<sup>17–19</sup> In this case, the cat presented with similar dysuria, stranguria and incontinence. The mild uraemia noted on biochemistry analysis was considered either postprandial in nature or subclinical dehydration. The cat's hydration status appeared clinically correct; however, subclinical dehydration can present with a marginal elevation of urea.<sup>20</sup>

Abdominal ultrasound and contrast radiography are common diagnostic tools when investigating urinary tract disorders.<sup>21,22</sup> In the present case, the abdominal ultrasound showed focal thickening of the dorsal bladder wall. This was suspected to represent the area previously biopsied by the referring veterinarian. The presence and location of the stricture was confirmed via retrograde positive contrast radiography, an imaging modality commonly used to diagnose urethral strictures.<sup>2,9,12,18,19</sup> Cystourethroscopy can also be used when investigating persistent lower urinary tract signs, providing a magnified internal image of the urinary tract. In this case, it identified the nature of the urethral obstruction, precluding placement of a urinary catheter. Cystourethroscopy also aids in performing interventional treatments.<sup>23,24</sup> Although considered a minimally invasive procedure, complications associated with cystoscopy include trauma to the urethral wall, urethritis, urethral and/or bladder rupture.<sup>23</sup>

Various surgical procedures (perineal, prepubic and subpubic urethrostomy) have been described for the treatment of proximal and distal urethral obstructions, mostly in male cats. Such procedures are rarely performed as they are associated with a high complication rate, including stricture formation, urinary leakage, recurrent urinary tract infections, dehiscence, skin necrosis and urinary incontinence.<sup>8,25,26</sup> In the present case, surgical treatment was not considered a valid option due to the proximal location of the stricture near to the bladder neck.

Bougienage, either digital or with specific instrumentation, has been described as a management method for oesophageal and rectal strictures in dogs.<sup>27,28</sup> A single case report of a urethral stricture as a consequence of perineal urethrostomy surgery in a cat was managed via bougienage with a successful outcome.<sup>5</sup> Although bougienage could be considered a management option for urethral stricture in cats, in the present case report the very narrow lumen of the membranous stricture was considered too small to be amenable for this technique.

Urethral balloon dilation is a common treatment modality for urethral strictures in humans, with similar outcomes to transurethral urethrotomy. The main

complication is recurrence of the stricture in up to 25% of patients within the first 3 years.<sup>29</sup> Urethroplasty offers the greatest chance for cure in humans and remains the gold standard in management of urethral strictures.<sup>6,30</sup> In veterinary medicine, limited cases of non-malignant urethral strictures have been reported in dogs<sup>2,7,31,32</sup> and cats.<sup>5,17–19</sup> To our knowledge, no other feline cases managed by balloon dilation have been reported. Only two of the canine cases reported were managed by fluoroscopy- and cystoscopy-guided balloon dilation,<sup>2,31</sup> with no associated complications or signs of re-obstruction noted 22 months post treatment. In the current case, follow-up retrograde urethrography showed persistent mild narrowing of the previous stricture site; however, there was normal flow of contrast into the bladder and resolution of clinical signs. This was considered a good outcome and repeat dilation was not necessary.

The placement of stents, self-expanding metallic stents (SEMS) and balloon-expandable metallic stents have been reported as treatment for urethral strictures and malignant urethral obstructions in both dogs and cats. Ureteral obstruction is the main concern with placement of SEMS for proximal urethral obstructions in cats, owing to a more caudal entrance of the ureters in the area of the trigone;<sup>17,18</sup> therefore, balloon dilation was the preferred treatment choice in this case.

## Conclusions

To our knowledge, this is the first report of a young cat with a suspected congenital proximal urethral obstruction that was successfully managed by fluoroscopy-guided balloon dilation. Based on the promising results of this case report, fluoroscopy-guided balloon dilation should be considered a technique for management of urethral stricture in cats; although further studies with a larger caseload are required to fully endorse this technique in cats.

**Acknowledgements** The authors would like to thank all of the hospital staff involved in the care of this cat.

**Conflict of interest** The authors declared no potential conflicts of interest with respect to the research, authorship, and/or publication of this article.

**Funding** The authors received no financial support for the research, authorship, and/or publication of this article.

**Ethical approval** The authors declare that this work involved the use of client-owned animals only, and followed established internationally recognised high standards ('best practice') of individual veterinary clinical patient care. Ethical approval from a committee was not therefore needed.

**Informed consent** Informed written consent was obtained from the owner of the animal described in this work for the procedures undertaken. For any animals or humans individually

identifiable within this publication, informed verbal consent for their use in the publication was obtained from the people involved.

## References

- Osborne CA, Kruger JM, Lulich JP, et al. **Disorders of the feline lower urinary tract.** In: Canine and feline nephrology and urology. Williams & Wilkins, 1995, pp 625–679.
- Bennett SL, Edwards GE and Tyrrell D. **Balloon dilation of a urethral stricture in a dog.** *Aust Vet J* 2005; 83: 552–554.
- Hill TL, Berent AC and Weisse CW. **Evaluation of urethral stent placement for benign urethral obstructions in dogs.** *J Vet Intern Med* 2014; 28: 1384–1390.
- Djordjevic ML. **Treatment of urethral stricture disease by internal urethrotomy, dilation, or stenting.** *Eur Urol Suppl* 2016; 15: 7–12.
- Shin Y, Chung D, Myung H, et al. **Balloon dilation and bougienage of a urethral stricture in a cat.** *Pak Vet J* 2015; 35: 540–542.
- Santucci R and Eisenberg L. **Urethrotomy has a much lower success rate than previously reported.** *J Urol* 2010; 183: 1859–1862.
- Lechner ES and Cooke KL. **Dysuria caused by a partially obstructing urethral membrane in a female dog.** *J Am Vet Med Assoc* 2011; 239: 818–22.
- Baines SJ, Rennie S and White RAS. **Prepubic urethrostomy: a long-term study in 16 cats.** *Vet Surg* 2001; 30: 107–113.
- McLoughlin MA. **Complications of lower urinary tract surgery in small animals.** *Vet Clin North Am Small Anim Pract* 2011; 41: 889–913.
- Kanakubo K, Palm CA, Korner AL, et al. **Treatment of urethral obstruction secondary to caudal bladder displacement, trigonal invagination, and urethral kinking in a dog.** *J Am Vet Med Assoc* 2017; 251: 818–823.
- Corgozinho KB, de Souza HJM, Pereira AN, et al. **Catheter-induced urethral trauma in cats with urethral obstruction.** *J Feline Med Surg* 2007; 9: 481–486.
- Osborne CA, Kruger JM and Lulich JP. **Feline lower urinary tract disorders. Definition of terms and concepts.** *Vet Clin North Am Small Anim Pract* 1996; 26: 169–179.
- Westropp JL and Buffington CAT. **Lower urinary tract disorders in cats.** In: Ettinger SJ and Feldman EC (eds). *Veterinary internal medicine.* St Louis, MO: Elsevier Saunders, 2010, pp 2069–2086.
- Bleedorn JA and Bjorling DE. **Urethra.** In: Tobias KM and Johnston SA (eds). *Veterinary surgery: small animal.* St Louis, MO: Elsevier Saunders, 2012, pp 1993–2010.
- Martin E. *Concise medical dictionary.* 9th ed. Oxford: Oxford University Press.
- Zaid MS, Berent AC, Weisse C, et al. **Feline ureteral strictures: 10 cases (2007–2009).** *J Vet Intern Med* 2011; 25: 222–229.
- Brace MA, Weisse C and Berent A. **Preliminary experience with stenting for management of non-urolith urethral obstruction in eight cats.** *Vet Surg* 2014; 43: 199–208.
- Hadar EN, Morgan MJ and Morgan ODE. **Use of a self-expanding metallic stent for the treatment of a urethral stricture in a young cat.** *J Feline Med Surg* 2011; 13: 597–601.
- Shipov A, Zafrany A, Kahana N, et al. **Successful balloon expandable stent placement in the management of severe proximal urethral stricture in a cat.** *Isr J Vet Med* 2014; 69: 88–91.
- Palm CA. **Blood urea nitrogen and creatinine.** In: Ettinger SJ, Feldman EC and Cote E (eds). *Veterinary internal medicine.* St Louis, MO: Elsevier, 2017, pp 250–251.
- Gunn-Moore D. **Feline lower urinary tract disease: an update.** *In Pract* 2000; 22: 534–542.
- Hostutler RA, Chew DJ and DiBartola SP. **Recent concepts in feline lower urinary tract disease.** *Vet Clin North Am Small Anim Pract* 2005; 35: 147–170.
- Morgan M and Forman M. **Cystoscopy in dogs and cats.** *Vet Clin North Am Small Anim Pract* 2015; 45: 665–701.
- Rawlings CA. **Diagnostic rigid endoscopy: otoscopy, rhinoscopy, and cystoscopy.** *Vet Clin North Am Small Anim Pract* 2009; 39: 849–868.
- Bernarde A and Viguier E. **Transpelvic urethrostomy in 11 cats using an ischial osteotomy.** *Vet Surg* 2004; 33: 246–252.
- Ruda L and Heiene R. **Short- and long-term outcome after perineal urethrostomy in 86 cats with feline lower urinary tract disease.** *J Small Anim Pract* 2012; 53: 693–698.
- Bissett SA, Davis J, Subler K, et al. **Risk factors and outcome of bougienage for treatment of benign esophageal strictures in dogs and cats: 28 cases (1995–2004).** *J Am Vet Med Assoc* 2009; 235: 844–850.
- Lamoureux A, Maurey C and Freiche V. **Treatment of inflammatory rectal strictures by digital bougienage: a retrospective study of nine cases.** *J Small Anim Pract* 2017; 58: 293–297.
- Djordjevic ML. **Treatment of urethral stricture disease by internal urethrotomy, dilation, or stenting.** *Eur Urol Suppl* 2016; 15: 7–12.
- Chhabra JS, Balaji SS, Singh A, et al. **Urethral balloon dilatation: factors affecting outcomes.** *Urol Int* 2016; 96: 427–431.
- Wood MW, Vaden S, Cerda-Gonzalez S, et al. **Cystoscopic-guided balloon dilation of a urethral stricture in a female dog.** *Can Vet J* 2007; 48: 731–733.
- Bae JH, Kwon YH, Jung YC, et al. **Use of an aortic stent graft extension for the treatment of urethral stricture in a dog.** *J Vet Med Sci* 2013; 75: 1363–1365.