



Early experience with use of an endoscopic “hot” scissor-type knife for myotomy during per-oral endoscopic myotomy procedure

Toshitaka Shimizu, MD, Kyle J. Fortinsky, MD, Kenneth J. Chang, MD

Background and Aims: Current devices used for per-oral endoscopic myotomy (POEM) function predominantly to either cut tissue or coagulate vessels. When bleeding vessels are encountered within the submucosa or muscle, dedicated coagulation grasping devices are often necessary. An endoscopic “hot” scissor-type knife is available that combines coagulation and cutting functions. Scissor-type knives may therefore be helpful during the POEM procedure.

Methods: We report 4 cases of achalasia that were treated by the POEM procedure using the Stag Beetle scissor-type knife for myotomy. Patients were identified from a prospectively maintained database of patients undergoing POEM at our center between September and October 2017. A single operator (K.J.C.) performed all of the procedures using both a hybrid knife and an SB knife. Demographic and clinical data were collected for all patients.

Results: All 4 POEM procedures were performed successfully without any adverse events. Only 3 spontaneous bleeding episodes occurred among the 4 procedures, and no perforation occurred. The patients were all doing very well at clinic follow-up at 4 weeks.

Conclusions: The technique of using the SB knife during myotomy during the POEM procedure is feasible and appears safe. Muscle tissue and blood vessels can be coagulated and cut simultaneously, reducing bleeding and improving control. Further comparative studies are warranted to evaluate the efficacy, safety, and cost effectiveness against existing techniques. (VideoGIE 2019;4:182-4.)

Dr Inoue performed the first per-oral endoscopic myotomy (POEM) procedure in Japan in 2008.¹ The most frequently reported adverse events of the POEM procedure include mucosal perforation, pneumothorax, pneumoperitoneum, subcutaneous emphysema, pleural effusion, and pneumonia.²⁻⁴ The incidence of perforation during the POEM procedure has been reported to be 6% to 10%.^{5,6} Although minor bleeding is common, major bleeding is an uncommon adverse event of the POEM procedure, likely resulting from devices such as the triangular tip (TT) knife and the coagrasper, which help achieve immediate hemostasis during both the submucosal dissection and the myotomy.

There is variability among different centers as to the ideal devices used to perform POEM.⁷ One previous study highlighted use of the scissor-type knife to separate the circular and longitudinal muscles during the POEM procedure.⁸ Most centers prefer a TT knife, and a few centers use the HybridKnife, I-Type (Erbe Elektromedizin GmbH,

Tuebingen, Germany) (HK).⁷ The SB knife (Olympus Corp, Tokyo, Japan) was originally developed for endoscopic submucosal dissection (ESD). The opening widths of the SB knife (junior and senior) are 3.5 mm and 7 mm, respectively. The tip of the device can be rotated 360°. ⁹ The device works by using a scissor-like mechanism whereby tissue is grasped into the device, and only tissue between the 2 scissors is coagulated and cut. Other devices with similar scissor-knife designs have been used during the POEM procedure.⁸

In this case series, we highlight how the SB knife not only can help with dissection of muscle layers but can be useful for coagulating vessels, thus reducing the risk of unexpected bleeding during the POEM procedure. Additionally, during performance of a full-thickness myotomy, the SB can provide excellent control and safety by reducing the risk of unintentional mediastinal injury. Our video series depicts the 4 cases in which the SB knife was used for full-thickness myotomy during the POEM procedure (Video 1, available online at www.VideoGIE.org).

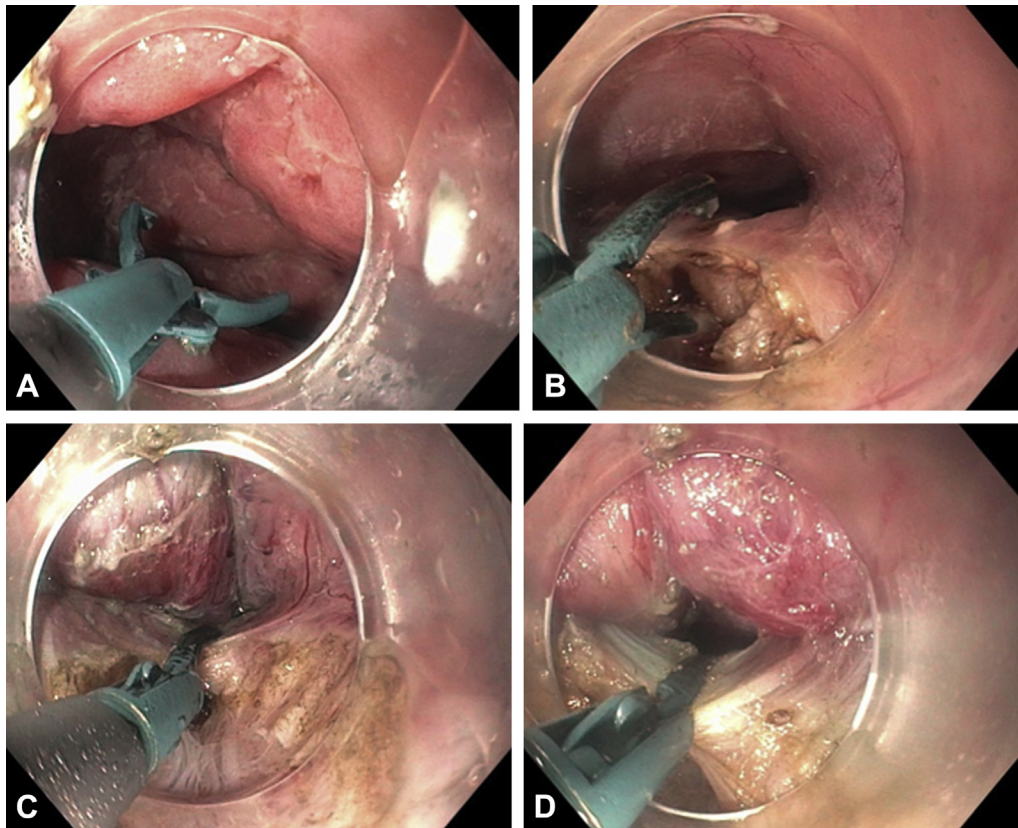


Figure 1. The SB knife opening (A) grasping muscle tissue (B), closing on muscle tissue (C), and retracting and cauterizing muscle tissue (D) during a per-oral endoscopic myotomy procedure.

POEM PROCEDURE

All 4 patients underwent similar POEM procedures with use of the HK and SB knife by a single endoscopist (K.J.C.). Procedures were performed with the patient under general anesthesia with intubation. A forward-viewing endoscope (GIF-H190; Olympus, Tokyo, Japan) was used with a transparent distal cap attachment (MH-588; Olympus). Carbon dioxide was used for insufflation. The esophagus was then lavaged with a gentamicin (100 mg/1 L) solution. A functional lumen imaging probe (EndoFLIP; Medtronic, Dublin, Ireland) was used to measure the distensibility index before and after myotomy. After submucosal injection, the HK (ERBE, Tübingen, Germany) was used to perform submucosal tunneling down the esophagus toward the lower-esophageal sphincter. Any submucosal blood vessel that was encountered during tunneling was cauterized with the SB knife (soft coagulation: effect 4, 80 W). The distal extent of the tunnel was confirmed by observation of a submucosal cushion in the cardia at retroflexion. Once the lower esophageal sphincter was reached, the SB knife was used to perform the myotomy (effect 1, cut duration 1, cut interval 1). The SB knife was used to selectively grasp muscle within the scissor mechanism so as to cauterize and cut through the muscle (Fig. 1). The mucosal entry site was closed with an Apollo suturing

device (Overstitch; Apollo Endosurgery, Austin, Tex, USA). All patients were admitted to the hospital overnight and underwent a barium swallow the next day, which revealed no leak or perforation. All patients received nothing by mouth for 24 hours after the procedure, followed by clear fluids for 3 days, then a soft diet for 3 weeks. There were no adverse events, and all patients were doing well at clinic follow-up at 4 weeks. A summary of the 4 cases can be seen in Table 1.

DISCUSSION

To our knowledge, these 4 cases of achalasia represent only the second literature report describing performance of POEM procedures with the SB knife and the first report of this procedure for full-thickness myotomy. The POEM procedure has become an established treatment for achalasia. The most common devices used to perform a POEM procedure include a TT and an HK, both of which are effective tools for endoscopic dissection and myotomy as part of the POEM procedure.¹⁰

Over the past several years, most of the POEM procedures have been performed by specialized centers with expert endoscopists. As the procedure becomes more readily available, it is likely that more endoscopists will

TABLE 1. Summary of 4 POEM cases using SB knife for myotomy

Patient	Type of achalasia	Myotomy length, cm	Pre-POEM distensibility	Post-POEM distensibility	Spontaneous bleeding
1	II	10	0.9	3.5	2
2	III	15	0.9	3.5	1
3	I	8	1.6	5.3	0
4	II	10	0.9	4.5	1

POEM, Per-oral endoscopic myotomy; SB, Stag Beetle.

venture into performing the POEM procedure, and with less-experienced endoscopists there may be a higher propensity for adverse events. Therefore, using a potentially safer device for the myotomy may become important.

The SB knife may be safer than the TT knife or the HK because it cuts only the muscle between the scissors, thus reducing the possibility of perforation into the mediastinum (Fig. 1). Additionally, the SB knife provides excellent cautery during myotomy, which may reduce bleeding, and it can be used to cauterize submucosal vessels during tunneling instead of the often-used coaggraspers.

Overall, the SB knife may improve the safety of the POEM procedure, especially as more endoscopists begin performing the procedure. Future larger studies may compare the perforation and bleeding rates between SB knives and classic instruments used for POEM such as the TT knife and the HK.

DISCLOSURE

Dr Chang has received educational grants and served as consultant with Olympus and Erbe. All authors disclosed no financial relationships relevant to this publication.

Abbreviations: HK, HybridKnife; POEM, per-oral endoscopic myotomy; SB, Stag Beetle; TT, triangular tip.

REFERENCES

- Hungness ES, Jorge JM. Per-oral esophageal myotomy: is it a safe and durable procedure for achalasia? *Adv Surg* 2017;51:193-205.
- Crespin OM, Liu LWC, Parmar A, et al. Safety and efficacy of POEM for treatment of achalasia: a systematic review of the literature. *Surg Endosc* 2017;31:2187-201.
- Ujiki MB, Yetasook AK, Zapf M, et al. Peroral endoscopic myotomy: a short-term comparison with the standard laparoscopic approach. *Surgery* 2013;154:893-7; discussion 7-900.
- Onimaru M, Inoue H, Ikeda H, et al. Peroral endoscopic myotomy is a viable option for failed surgical esophagocardiomyotomy instead of redo surgical Heller myotomy: a single center prospective study. *J Am Coll Surg* 2013;217:598-605.
- Tang X, Ren Y, Wei Z, et al. Factors predicting the technical difficulty of peroral endoscopic myotomy for achalasia. *Surg Endosc* 2016;30:3774-82.
- Stavropoulos SN, Desilets DJ, Fuchs KH, et al. Per-oral endoscopic myotomy white paper summary. *Surg Endosc* 2014;28:2005-19.
- Stavropoulos SN, Modayil RJ, Friedel D, et al. The International Per Oral Endoscopic Myotomy Survey (IPOEMS): a snapshot of the global POEM experience. *Surg Endosc* 2013;27:3322-38.
- Bittinger M, Messmann H. Use of the stag-beetle knife for peroral endoscopic myotomy for achalasia: a novel method for myotomy. *Gastrointest Endosc* 2015;82:401-2.
- Goelder SK, Brueckner J, Messmann H. Endoscopic treatment of Zenker's diverticulum with the stag beetle knife (SB knife): feasibility and follow-up. *Scand J Gastroenterol* 2016;51:1155-8.
- Khashab MA, Messallam AA, El Zein M, et al. Submucosal endoscopy: the new frontier of therapeutic endoscopy. *Curr Opin Gastroenterol* 2014;30:444-52.

Division of Gastroenterology and Hepatology, Department of Medicine, University of California, Irvine, Orange, California, USA.

Copyright © 2019 American Society for Gastrointestinal Endoscopy. Published by Elsevier Inc. This is an open access article under the CC BY-NC-ND license (<http://creativecommons.org/licenses/by-nc-nd/4.0/>).

<https://doi.org/10.1016/j.vgie.2018.12.014>