

Available online at www.sciencedirect.com

ScienceDirect

journal homepage: www.elsevier.com/locate/radcr

Case Report

Non-traumatic bilateral rectus sheath hematoma during septic disseminated intravascular coagulation ☆☆☆

Kana Taguchi, PhD^a, Yoshiaki Kamei, PhD^{a,*}, Erina Kusakabe, MD^a, Michiko Yamashita, PhD^a, Haruna Noda, MD^a, Reina Aoki, MD^a, Kanako Nishiyama, MD^a, Akari Murakami, PhD^a, Hiroaki Tanaka, PhD^b, Megumi Matsuda, PhD^b, Teruhito Kido, PhD^b, Norio Sato, PhD^c, Yasutsugu Takada, PhD^d

^aDepartment of Breast Center, Ehime University Hospital, Japan

^bDepartment of Radiology, Ehime University Graduate School of Medicine, Ehime, Japan

^cDepartment of Emergency and Critical Care Medicine, Ehime University Graduate School of Medicine, Ehime, Japan

^dDepartment of Hepato-Biliary-Pancreatic Surgery and Breast Surgery, Ehime University Graduate School of Medicine, Ehime, Japan

ARTICLE INFO

Article history:

Received 16 December 2021

Revised 20 February 2022

Accepted 22 February 2022

Keywords:

Rectus sheath hematoma

Angioembolization

Disseminated intravascular coagulation

ABSTRACT

A non-traumatic abdominal wall hematoma is rare, and occurs occasionally due to coughing, physical activity, or antithrombotic/anticoagulant therapy. The condition is usually unilateral; however, rare bilateral cases have been reported. Here, we report a rare case of a non-traumatic bilateral rectus sheath hematoma. The patient was a 60-year-old woman who was urgently admitted to our hospital due to the occurrence of pneumonia during post-operative chemotherapy for breast cancer. Because she exhibited disseminated intravascular coagulation, a therapy with antibacterial agents, thrombomodulin alpha, and catecholamines was initiated. During hospitalization, hemorrhagic shock due to hematomas in both rectus abdominis muscles was observed without any discernible cause. Subsequent emergency angioembolization was successful, and abdominal computed tomography performed 3 months after the onset of the rectus sheath hematoma confirmed a reduction in the hematoma size.

© 2022 The Authors. Published by Elsevier Inc. on behalf of University of Washington.

This is an open access article under the CC BY-NC-ND license

(<http://creativecommons.org/licenses/by-nc-nd/4.0/>)

☆ Competing Interest: The authors declare that they have no known competing financial interests or personal relationships that could have appeared to influence the work reported in this paper.

☆☆ Patient consent: Informed consent was obtained from the patient.

* Corresponding author.

E-mail address: yoshkam@m.ehime-u.ac.jp (Y. Kamei).

<https://doi.org/10.1016/j.radcr.2022.02.074>

1930-0433/© 2022 The Authors. Published by Elsevier Inc. on behalf of University of Washington. This is an open access article under the CC BY-NC-ND license (<http://creativecommons.org/licenses/by-nc-nd/4.0/>)

Introduction

Rectus sheath hematoma (RSH) is a rare disorder that accounts for 1%-2% of all causes of abdominal pain [1]. The disease is usually unilateral, although rare bilateral cases may occur. Coughing, physical activity, and anticoagulant use have been reported as causes of non-traumatic RSH [2]. In most cases, RSH is relieved by conservative treatment, such as rest, ice, and compression; [3] however, angioembolization is sometimes considered for RSH cases presenting with rapidly progressive anemia and decreased blood pressure. Herein, we present a case of bilateral RSH associated with anti-disseminated intravascular coagulation (anti-DIC) therapy; subsequent angioembolization saved the patient's life. Informed consent was obtained from the patient.

Case report

A 60-year-old woman with a medical history of left breast cancer underwent postoperative adjuvant chemotherapy with doxorubicin and cyclophosphamide (AC therapy). She had a history of hypertension and total thyroidectomy for thyroid cancer, and was taking amlodipine besilate. She visited our hospital with nausea and fever during the nadir phase of the first course of the AC therapy. Upon close examination, she was diagnosed with febrile neutropenia and septic DIC due to severe pneumonia, and was admitted to the hospital immediately. Administration of meropenem, granulocyte colony-stimulating factor, thrombomodulin alpha, noradrenaline, and methylprednisolone sodium succinate was initiated. Atrial fibrillation (AF) developed 3 days after admission; therefore, diuretics and antiarrhythmic drugs were administered, resulting in an improvement in her general condition. Administration of edoxaban tosylate hydrate was initiated on the fourth day of hospitalization for the treatment of AF. On the fifth day of hospitalization, she

experienced lower right abdominal pain, decreased blood pressure, and transient lowering of consciousness with convulsions. A blood test revealed progression of anemia (hemoglobin level decreased from 10.8 mg/dL to 8.8 mg/dL). Abdominal computed tomography (CT) revealed a hematoma in the right rectus abdominis muscle (Fig 1-A), although there was no apparent extravasation. We decided to administer conservative treatment (eg blood transfusion). However, at night, her blood pressure decreased, and her anemia continued to progress (hemoglobin: 6.6 mg/dL). Therefore, we performed emergency angiography and inserted a 4-Fr sheath into the left femoral artery; selective angiography of the right inferior epigastric artery revealed several hemorrhages in the abdominal cavity (Fig 1-B). The distal side of the artery was embolized with 2 interlocking detachable coils, and embolization was performed using 10% histoacryl from the proximal part to the bifurcation.

On the sixth day of hospitalization, despite the discontinuation of edoxaban tosylate hydrate and thrombomodulin alpha, she exhibited breathing difficulty, lowering of consciousness, and progression of anemia at night. As contrast-enhanced CT examination revealed a hematoma in the left rectus abdominis muscle (Fig. 2-A), emergency angiography was performed again, and bleeding from the left inferior epigastric artery was observed (Fig. 2-B). Therefore, embolization was performed using 2 microcoils (orbit: 2 mm × 4 cm) and an embolic agent (10% histoacryl). On the seventh day of hospitalization, progressive anemia was observed again (hemoglobin level decreased from 9.0 mg/dL to 6.6 mg/dL), and emergency angiography was performed. However, no evident bleeding point could be identified, and a conservative treatment was planned. Thereafter, there was no rebleeding, and contrast-enhanced CT examination revealed no increase in the size of the hematoma. The patient's condition recovered satisfactorily, and she was transferred to another hospital 50 days after hospitalization. An abdominal CT scan 3 months after the onset of RSH confirmed a reduction in the size of the hematoma (Fig. 3). Subsequently, postoperative adjuvant therapy was administered as planned.

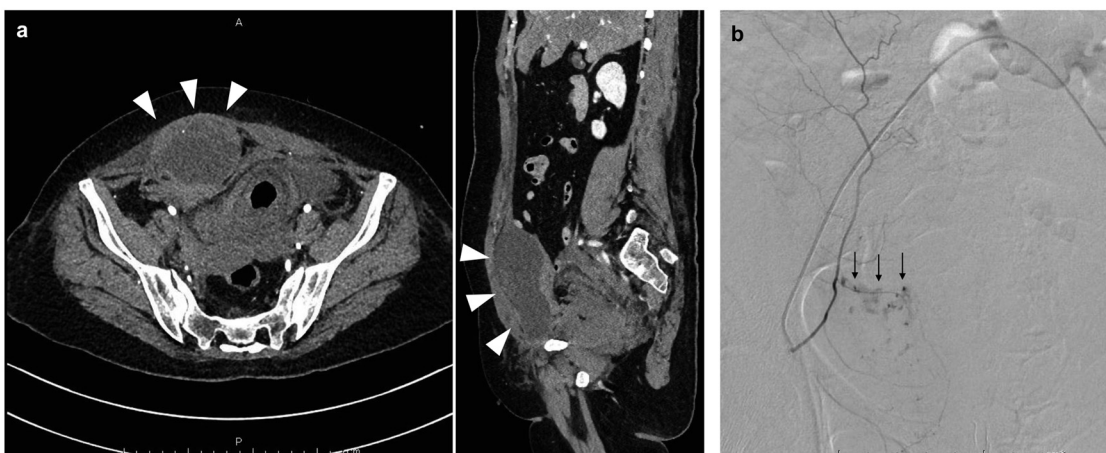


Fig. 1 – A: Enhanced abdominal computed tomography reveals a mass in the right abdominal wall (white arrowhead). **(B)** Selective angiography before embolization reveals bleeding (black arrow) from the right inferior epigastric artery.

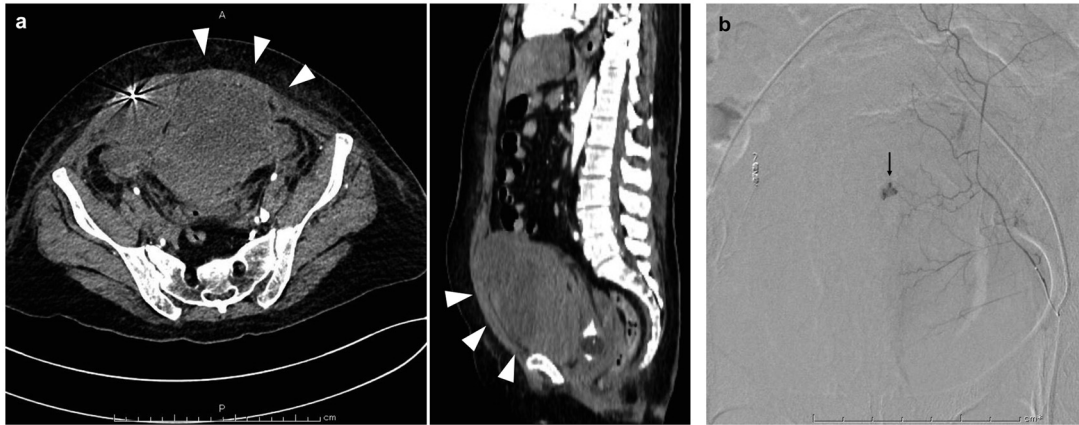


Fig. 2 – A: Enhanced abdominal computed tomography reveals a mass in the left abdominal wall (white arrowhead). **(B)** Selective angiogram shows bleeding (black arrow) from the left inferior epigastric artery.

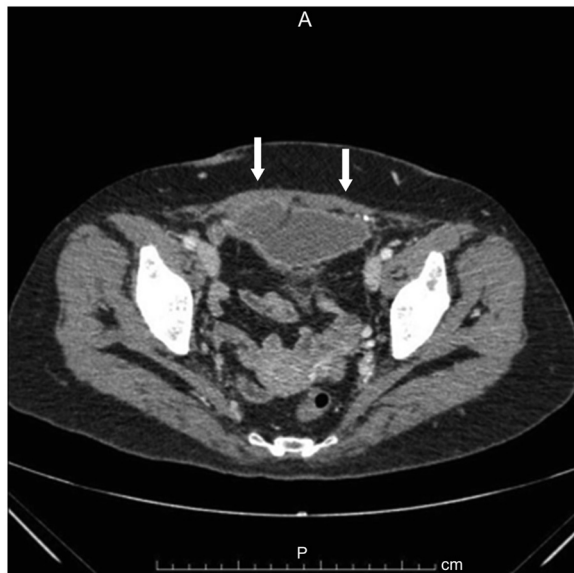

Fig. 3 – A: Follow-up enhanced abdominal computed tomography performed 3 months later reveals that both hematomas have decreased in size/.

Discussion

RSH is a rare disorder. Non-traumatic RSH is typically caused by abdominal surgery, anticoagulant therapy, coughing, or physical activity. The most common symptoms are persistent abdominal pain, abdominal masses, abdominal tenderness, and muscular defensiveness [2]. Usually, RSH is relieved by conservative treatment; however, as the size of the hematoma increases, and the hemodynamics become unstable, treatments such as vascular embolization via angiography or ligation of the bleeding vessels via surgery are required [2].

CT is the most useful modality for the diagnosis of RSH, and Pierro et al. have reported the utility of CT angiography for identifying the causative blood vessels [4]. In this case, although contrast-enhanced CT was used to diagnose the RSH,

no conspicuous bleeding source was confirmed; therefore, conservative treatment was selected. However, the hematoma increased in size, leading to a hemorrhagic shock. Thus, we performed emergency angiography to identify the causative vessel, following which vascular embolization was performed to achieve hemostasis and save the patient's life. Hematoma removal and ligation of blood vessels via surgery are more invasive to patients than is angiography, which is therefore very useful because it can simultaneously identify the source of bleeding and ensure vascular embolization.

Only 10 reports of bilateral RSH, including the present one, are available (Supplementary Table S1). The cause of non-traumatic RSH was antiplatelet/coagulation therapy in 5 cases [5–8]. In most cases, conservative treatment was performed [6–11]. In our case, the right RSH developed first; thereafter, the left RSH developed after angiography that was performed to identify bleeding from the right lower abdominal wall and embolization of the same. Although thrombomodulin alpha and edoxaban tosilate hydrate were orally administered at the onset of the right RSH, they had been discontinued by the onset of the left RSH. Anticoagulation therapy using the combination of both drugs was speculated as the cause of RSH onset.

To conclude, in this report, we discussed a case of bilateral RSH with hemorrhagic shock during anticoagulation therapy for septic DIC. The present case highlights the usefulness of angiography for the diagnosis and treatment of RSH. We were able to save our patient's life by performing angiography immediately. Physicians should be aware that RSH may cause hemorrhagic shock, especially in patients undergoing anticoagulant therapy.

Author contributions

K.T., Y.K., E.K., M.Y., H.N., R.A., K.Na and A.M. contributed to the design and implementation of the research. K.T., Y.K., M.M., H.T., T.K., N.S and Y.T. were involved in the analysis of the results and to the writing of the manuscript. All authors critically revised the report, commented on drafts of the manuscript, and approved the final report.

Data availability

The data that support the findings of this study are openly available.

Acknowledgments

We would like to thank Editage (www.editage.jp) for English language editing.

Supplementary materials

Supplementary material associated with this article can be found, in the online version, at doi:[10.1016/j.radcr.2022.02.074](https://doi.org/10.1016/j.radcr.2022.02.074).

REFERENCES

- [1] Klingler PJ, Wetscher G, Glaser K, Tschmelitsch J, Schmid T, Hinder RA. The use of ultrasound to differentiate rectus sheath hematoma from other acute abdominal disorders. *Surg Endosc* 1999;13:1129–34. doi:[10.1007/s004649901188](https://doi.org/10.1007/s004649901188).
- [2] Hatjipetrou A, Anyfantakis D, Kastanakis M. Rectus sheath hematoma: a review of the literature. *Int J Surg* 2015;13:267–71. doi:[10.1016/j.ijsu.2014.12.015](https://doi.org/10.1016/j.ijsu.2014.12.015).
- [3] Cherry WB, Mueller PS. Rectus sheath hematoma: review of 126 cases at a single institution. *Med (Baltim)* 2006;85:105–10. doi:[10.1097/01.md.0000216818.13067.5a](https://doi.org/10.1097/01.md.0000216818.13067.5a).
- [4] MD Antonio Pierro, PhD Cilla S, Modugno P, et al. Spontaneous rectus sheath hematoma: the utility of CT angiography. *Radiol Case Rep* 2018;13:328–32.
- [5] Yamada Y, Ogawa K, Shiomi E, Hayashi T. Images in cardiovascular medicine. Bilateral rectus sheath hematoma developing during anticoagulant therapy. *Circulation* 2010;121:1778–9 Apr 20. doi:[10.1161/CIR.0b013e3181db2135](https://doi.org/10.1161/CIR.0b013e3181db2135).
- [6] Jensen L, Luk A, Skarpathiotakis M, Madan M. Bilateral rectus sheath hematomas in a coughing patient. *Am J Med* 2013;126:e5–6. doi:[10.1016/j.amjmed.2013.01.021](https://doi.org/10.1016/j.amjmed.2013.01.021).
- [7] Xu L, Liu L, Li X. Bilateral rectal sheath hematomas after low-molecular weight heparin treatment in uremia. *Ren Fail* 2017;39:414–16. doi:[10.1080/0886022X.2017.1305406](https://doi.org/10.1080/0886022X.2017.1305406).
- [8] Rosa CT, Navinan MR, Samarawickrama S, Hamza H, Gunarathne M, Arulanantham A, et al. Bilateral rectus sheath haematoma complicating dengue virus infection in a patient on warfarin for mechanical aortic valve replacement: a case report. *BMC Res Notes* 2017;10:26. doi:[10.1186/s13104-016-2330-x](https://doi.org/10.1186/s13104-016-2330-x).
- [9] Trias A, Boctor M, Echave V. Ultrasonography in the diagnosis of rectus abdominis hematoma. *Can J Surg* 1981;24:524–5.
- [10] Docherty JG, Herrick AL. Bilateral rectus sheath haematoma complicating alcoholic liver disease. *Br J Clin Pract* 1991;45:289.
- [11] Bhat KJ, Shovkat R, Samoon HJ. Abdominal haematomas and dengue fever: two different cases of spontaneous psoas muscle haematoma and bilateral rectus sheath haematoma complicating dengue haemorrhagic fever. *J Vector Borne Dis* 2015;52:339–41.