


# Accuracy of half-way mucosa-supported implant guides for edentulous jaws: a retrospective study with a median follow-up of 2 years

Weiwei Tang<sup>1,\*</sup>, Qilong Liu<sup>2,\*</sup>,  
Xianshang Zeng<sup>3</sup>, Jiali Yu<sup>4</sup>, Dalong Shu<sup>4</sup>,  
Guorong Shen<sup>5</sup>, Weiguang Yu<sup>3</sup> ,  
Xiangzhen Liu<sup>4</sup> and Guixing Xu<sup>6</sup>

## Abstract

**Objective:** To assess the accuracy of half-way digital mucosa-supported implant guides (HDMIGs) for edentulous jaws.

**Methods:** Ninety-five consecutive patients (859 implants) with edentulous jaws who underwent implant placement using an HDMIG from July 2012 to June 2018 were retrospectively identified. The primary endpoint was implant-related complications (nerve injury and unexpected perforation), and the secondary endpoints were the faciolingual distance, mesiodistal distance, buccolingual angle, and mesiodistal angle. Follow-ups occurred at 1 month, 2 months, and then every 2 months following implant placement.

**Results:** Twenty-seven (28.4%) patients met the exclusion criteria, leaving 68 eligible patients (636 implants) for the final analysis. The median follow-up was 24 months (range, 18–27 months). No patients developed nerve injury, revision, or unexpected perforation. At the final follow-up,

<sup>1</sup>Department of Ultrasound Medicine, Affiliated Hospital of Xiangnan University, Chenzhou, China

<sup>2</sup>Department of Gastrointestinal Surgery, The First Affiliated Hospital, Sun Yat-sen University, Guangzhou, China

<sup>3</sup>Department of Orthopaedics, The First Affiliated Hospital, Sun Yat-sen University, Guangzhou, China

<sup>4</sup>Department of Oral and Maxillofacial Surgery, The First Affiliated Hospital, Sun Yat-sen University, Guangzhou, China

<sup>5</sup>Department of Oral and Maxillofacial Surgery, Jinshan Hospital, Fudan University, Shanghai, China

<sup>6</sup>Department of Neurosurgery, The First Affiliated Hospital, Sun Yat-sen University, Guangzhou, China

\*These authors contributed equally to this work.

## Corresponding authors:

Guorong Shen and Guixing Xu, Department of Oral and Maxillofacial Surgery, Jinshan Hospital, Fudan University, No. 1508 Longhang Road, Jinshan District, Shanghai 201508, China; Department of Neurosurgery, The First Affiliated Hospital, Sun Yat-sen University, No. 58 Zhongshan 2nd Road, Yuexiu District, Guangzhou 510080, China.

Emails: 18930819940@189.cn; xuguix@mail.sysu.edu.cn



the mean faciolingual distance was  $0.65 \pm 0.16$  mm, the mean mesiodistal distance was  $1.16 \pm 0.61$  mm, the mean buccolingual angle was  $4.04^\circ \pm 2.26^\circ$ , and the mean mesiodistal angle was  $3.75^\circ \pm 2.56^\circ$ . In the comparison of the first month after surgery and the last follow-up, no significant differences were detected in any of the four measured variables.

**Conclusion:** Use of an HDMIG may be a convenient and safe method to ensure correct implantation.

## Keywords

Implant, edentulous jaws, nerve injury, outcome, complication, Asian patients

Date received: 28 January 2021; accepted: 8 February 2021

## Introduction

Digital implant guides have been used for placement of dental implants for many years. The main objectives of using such guides are to improve diagnosis, improve the accuracy of prosthesis placement, and simplify the procedure.<sup>1,2</sup> The design and production of implant guides have gradually become more professional and commercialized with the aid of computed tomography (CT), dental three-dimensional (3D) scanners, implant planning software, and 3D printers.<sup>3-5</sup> Thus, most implant guides are manufactured by commercial companies. Guides can be divided into two types according to whether they help surgeons to complete the entire implant process: full-way digital mucosa-supported implant guides and half-way digital mucosa-supported implant guides (HDMIGs). Full-way digital mucosa-supported implant guides can help surgeons perform all implant procedures, including punching the gingiva, drilling bone, and placing implants.<sup>3-6</sup> In contrast, an HDMIG is known as a pilot drill,<sup>4</sup> and its primary role is to punch the gingiva.<sup>4-7</sup> Surgeons must manually perform all subsequent procedures. HDMIGs can give the surgeon more opportunities to correct the deviation if guides fail. Recent studies<sup>1,6,7</sup>

have shown that the HDMIG for stereolithographic implants shows accuracy similar to that of the guide technologies prepared by laboratories or manufacturers. Although HDMIGs are based on tooth-supported guides,<sup>8</sup> we were inspired to design implant plans and fabricate mucosa-supported implant guides for edentulous jaws. In clinical practice, we have encountered a difference in accuracy between mucosal-supported guides and tooth-supported guides.

The reported HDMIG-related clinical outcomes, including the implant-related complications, faciolingual distance, mesiodistal distance, buccolingual angle, and mesiodistal angle, are inconsistent,<sup>7</sup> and 2-year follow-up studies are lacking. Therefore, we retrospectively evaluated the 2-year clinical outcomes of Asian patients with edentulous jaws who were treated with an HDMIG.

## Materials and methods

### Study population

This study was approved by the Institutional Review Board of The First Affiliated Hospital, Sun Yat-sen University (IRB21-3421). The requirement for informed consent was waived by the

board because of the retrospective nature of the study. We retrospectively identified 95 consecutive patients (859 implants) with edentulous jaws who were treated using an HDMIG from July 2012 to June 2018 at our medical center. The inclusion criteria were an age of  $\geq 18$  years; edentulous jaws or a plan to extract the rest of the teeth from the upper, lower, or both jaws; implant plans that could be made using a normal implant or osteotome sinus floor elevation without bone grafting; and at least one planned implant site (alveolar thickness of  $< 6$  mm, alveolar height of  $< 8$  mm).<sup>9</sup> The exclusion criteria were a lack of follow-up data, oral dysplasia prior to implant placement, inability to abide by the follow-up plans, severe maxillary or mandibular disorders (e.g., osteoporosis), severe oral soft tissue disease, medical diseases (e.g., uremia or active infectious disease), a long-term bedridden status, advanced cancer, inability to perform self-care, long-term fasting, and mental diseases.

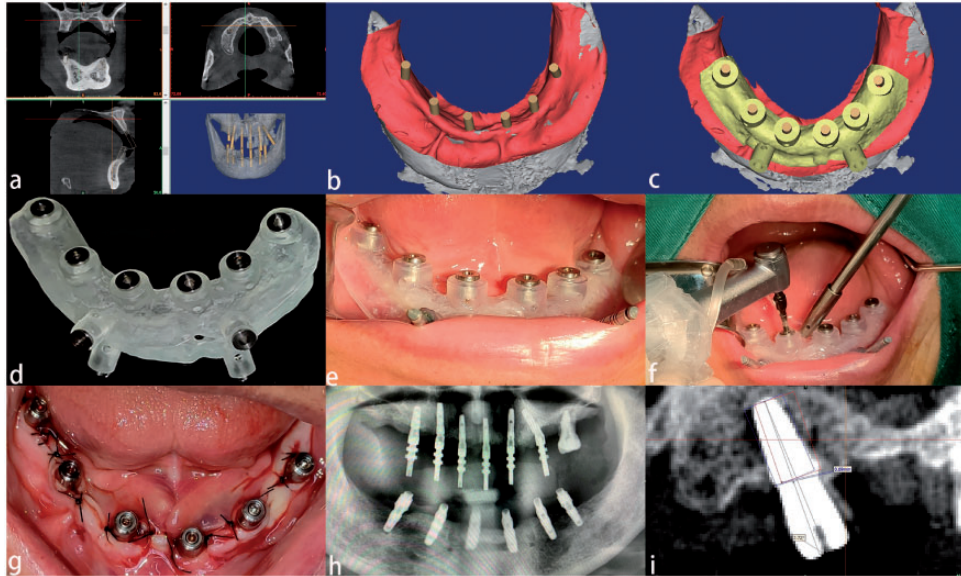
### *HDMIG techniques and details*

Each patient underwent a preoperative CT scan with a slice thickness of 0.5 mm (Aquilion 64 CT; Toshiba, Tokyo, Japan). The CT scan data were imported as Digital Imaging and Communications in Medicine standard files to create a project with Mimics software (Materialise, Leuven, Belgium). A plaster model was used to duplicate the oral mucosa contour for each patient. The plaster model was scanned using a 3D denture scanner (3D EX Pro; Shining 3D, Hangzhou, China) in stereolithography (STL) file format. The STL file of the plaster model was imported in the Mimics project of the corresponding patient. The 3D image of the edentulous jaw was reconstructed by setting CT soft tissue and bone threshold values to obtain a virtual implant plan, including the

implant distribution, direction, and depth and whether the sinus floor was elevated (Figure 1(a)). A mucosa contour image was reconstructed by setting the CT threshold values. We manually located three or more registration points so that the CT soft tissue model and the plaster model could be located simultaneously (Figure 1(b)). A 2-mm-thick, 20- to 40-mm-wide shell on the alveolar ridge mucosa of the registered plaster model was designed as the base template. Based on this template, we designed implant guide holes, cooling water holes for the implant points, and two to four template-fixing holes (Figure 1(c)). The guide design was sent to a desktop 3D printer (Form 2; Formlabs, Somerville, MA, USA) as an STL file. The guides were printed using Dental LT Resin (Formlabs) (Figure 1(d)). With the patient under local anesthesia, the guide was mounted on the alveolar ridge mucosa by an occlusal record of silicon impressions. Two to four guide-fixing holes were drilled through the mucosa and cortical bones with no damage to the contralateral cortical bone. Pins were inserted to fix the guide, and the occlusal markers were removed. The pilot drill following the pilot hole was used to drill the pilot implant hole, and its position, direction, and depth had been planned prior to surgery. After removing the guide, the segmentation incision, exposure, shaping, and implant placement were performed in a free-hand manner. All drilling and shaping proceeds were cooled using sodium chloride solution. Each implant was placed stably and protected using a healing abutment, and some leaning implants were corrected using angle abutments during the surgery to situate them preliminarily parallel with the other implants (Figure 1(e-h)).

### *Outcome evaluation*

The primary endpoint was implant-related complications (nerve injury, revision, and



**Figure 1.** (a) By setting the threshold values, a three-dimensional maxillary and mandibular image (gray) was reconstructed to plan an implant (brown). (b) By setting three or more pairs of points, a plaster model (red) was registered to the computed tomography images. (c) An implant guide (yellow) was designed to attach the plaster model (red) based on the implant plan (brown). (d) Printed implant guide with titanium circles. (e) A guide was fixed by pins. (f) Pilot drilling followed by the fixed guide. (g) The implants were protected by healing abutment. (h) Postoperative X-ray image of a patient who underwent correction by angle abutments to ensure that the implants were preliminarily parallel with the other implants. (i) The placed implant images were registered to measure the distance and angulation deviations: the red rectangle represents the planned implant, and the blue rectangle represents the placed implant. The two gray lines are the axis of two rectangles, the angles of which represent the angulation deviations of the planned implant and placed implant. For this implant (4.5-mm width and 8-mm height), the mesiodistal distance was measured as 0.62 mm and the mesiodistal angle was measured as  $2.72^\circ$ .

unexpected perforation), and the secondary endpoints were the faciolingual distance, mesiodistal distance, buccolingual angle, and mesiodistal angle. Each patient underwent a CT scan after the surgery. A postoperative image of the jaw with implants was reconstructed using Mimics software and was exported to the preoperative planning project as an STL file. The placed implants and the preoperatively planned implants were compared (Figure 1(i)). Standardized postoperative procedures were conducted for each patient.<sup>10</sup> Follow-ups occurred at 1 month, 2 months, and then every 2 months following implant placement. Follow-up data were gathered

by two authors (J.Y. and X.L.). The follow-up time was defined as the date of primary surgery to the date of either death of any cause or the final follow-up, whichever came first. Revision was defined as the exchange of any component.<sup>12</sup>

### Statistical analysis

The descriptive statistics include continuous variables (i.e., age, body mass index, and bone mineral density), which are expressed as mean  $\pm$  standard deviation, and categorical variables (i.e., sex, comorbidities, and implant distributions), which are expressed as percentage. Differences in continuous

variables were compared using Student's t-test. All analyses were performed using IBM SPSS Statistics for Windows, Version  $\geq 26.0$  (IBM Corp., Armonk, NY, USA). A two-sided p value of 0.05 was deemed statistically significant.

## Results

Twenty-seven (28.4%) patients met the exclusion criteria, leaving 68 eligible patients (636 implants) for the final analysis. The median age at the time of surgery was  $64.25 \pm 6.31$  years. The median follow-up was 24 months (range, 18–27 months). The mean body mass index and bone mineral density were  $28.04 \pm 5.19$  kg/m<sup>2</sup> and  $-3.76 \pm 0.43$ , respectively. The patients' characteristics are presented in Table 1.

None of the patients developed nerve injury, required revision, or developed unexpected perforation throughout the follow-up period. Of the 636 implants, 612 underwent successful loading of fixed prostheses; however, 24 implants in 2 patients were removed 1 month after surgery because of infection.

**Table 1.** Patient demographics.

Variable	N = 68 patients (636 implants)
Sex, male/female	23/45
Age, years	$64.25 \pm 6.31$
Body mass index, kg/m <sup>2</sup>	$28.04 \pm 5.19$
Bone mineral density	$-3.76 \pm 0.43$
Comorbidities	
Hypertension	9 (13.2)
Diabetes mellitus	13 (19.1)
Hypertension and diabetes mellitus	5 (7.4)
Implant distributions*	
Upper jaw $\geq 6$	8 (11.8)
Lower jaw $\geq 6$	14 (20.6)
Upper and lower jaws $\geq 8$	46 (67.6)

Data are presented as mean  $\pm$  standard deviation or n (%).

\*Using the Fédération Dentaire Internationale (FDI) Tooth Numbering System.

Follow-up data regarding the secondary endpoints are shown in Table 2. At the final follow-up, the mean faciolingual distance between the placed implants and planned implants was  $0.65 \pm 0.16$  mm, the mean mesiodistal distance was  $1.16 \pm 0.61$  mm, the mean buccolingual angle was  $4.04^\circ \pm 2.26^\circ$ , and the mean mesiodistal angle was  $3.75^\circ \pm 2.56^\circ$ . In the comparison of the first month after surgery and the last follow-up, no significant differences were detected in any of the four measured variables.

## Discussion

Our results may provide evidence that the HDMIG performed initially for edentulous jaws in the Chinese population tends to lead to favorable clinical outcomes and acceptable accuracy without nerve injury, revision, or unexpected perforation.

The implant guides used in the present study were designed by implant surgeons and printed using a desktop 3D printer. The print accuracy and resin biocompatibility had already been thoroughly tested by the 3D printer manufacturer.<sup>6</sup> Similar techniques using the same software and similar operative processes have been applied to guide mid-face fracture reduction, mandibular reconstruction, and removal of foreign bodies from the skull base.<sup>3,6</sup> The guides were mounted either on teeth or on bones, ensuring their stability. Turbush and Turkyilmaz<sup>13</sup> reported that mucosa-supported guides were less accurate than both tooth- and bone-supported guides in terms of linear deviation.

In the current study, we mounted most of the guides on the alveolar ridge mucosa<sup>14</sup>; some additional steps were used to stabilize the mucosa-supported guides. The first step was to use the occlusal impression marks between the upper and lower jaws to encourage the patient to bite. In this way, the guide rail can remain stable when drilling the fixing pin holes.<sup>15</sup>

**Table 2.** Implant position deviation.

Month(s) after surgery	Faciolingual distance, mm	Mesiodistal distance, mm	Buccolingual angle	Mesiodistal angle
1	0.64 ± 0.13*	1.16 ± 0.72*	4.05° ± 2.11°*	3.74° ± 2.61°*
2	0.65 ± 0.17	1.16 ± 0.81	4.07° ± 3.17°	3.76° ± 2.22°
4	0.64 ± 0.21	1.17 ± 0.64	4.01° ± 2.16°	3.74° ± 2.42°
6	0.64 ± 0.14	1.17 ± 0.42	4.05° ± 1.24°	3.76° ± 2.55°
8	0.64 ± 0.22	1.16 ± 0.55	4.04° ± 2.16°	3.75° ± 2.33°
10	0.66 ± 0.12	1.17 ± 0.73	4.03° ± 3.23°	3.74° ± 2.66°
12	0.64 ± 0.23	1.17 ± 0.45	4.04° ± 2.15°	3.73° ± 2.57°
14	0.65 ± 0.21	1.16 ± 0.53	4.02° ± 2.25°	3.74° ± 2.69°
16	0.63 ± 0.24	1.17 ± 0.56	4.07° ± 2.36°	3.75° ± 2.41°
18	0.63 ± 0.19	1.15 ± 0.67	4.06° ± 1.44°	3.77° ± 2.28°
20	0.64 ± 0.18	1.17 ± 0.62	4.03° ± 2.22°	3.74° ± 2.32°
22	0.65 ± 0.25	1.16 ± 0.73	4.05° ± 2.41°	3.76° ± 2.44°
24	0.65 ± 0.26	1.16 ± 0.64	4.04° ± 2.37°	3.75° ± 2.53°
Final follow-up	0.65 ± 0.16 <sup>#</sup>	1.16 ± 0.61 <sup>#</sup>	4.04° ± 2.26° <sup>#</sup>	3.75° ± 2.56° <sup>#</sup>

\*#No statistical significance (all  $p > 0.05$ ).

The second step was to use bicortical fixing pins. In practice, we have found that even if four fixing pins are designed (the conventional number of fixing pins is three), the fixing pins passing through the buccal cortex alone do not provide sufficient stability for the guide plate.<sup>16</sup> One possible explanation for this phenomenon is that the fixing pin is smooth rather than having a high holding force like a screw, and the pin hole in patients with osteoporosis tends to be 0.2 mm larger than the hole actually required.<sup>17,18</sup> However, the fixing pin is inserted in the absorbed jaw. When the orbicularis oris contracts, the lips push the fixing pin, which weakens the stability of the fixing pin. After designing the bicortical fixing pins, based on our practical process, we deem that the stability of the guide plate is acceptable. The third step is to use a sharp pilot drill and a high drilling speed of approximately 1000 rpm to avoid slipping on the inclined alveolar surface. A sharp drill and rapid drilling can also reduce steering swing, and the cooling of the sodium chloride solution should be adequate. Common adverse events during drilling

include accidental perforation of the maxillary sinus, inferior alveolar neural tube, and lateral alveolar bone. These events are mainly associated with the depth control of the guide and are rare if there are no errors in the depth design and the guide is properly installed.<sup>18-20</sup>

In practice, we strive to avoid the occurrence of lateral alveolar perforation. Because this study was based on clinical needs, the guidance process was only performed when the edentulous jaw appeared thin and low-density on the CT image; this is mainly attributable to the fact that fully free-hand operations might be insecure.<sup>3</sup> A thin jaw is associated with an increased risk of lateral alveolar perforation, which can be extremely challenging to salvage once it occurs. Van de Velde et al.<sup>16</sup> reported that the 3D location of implants installed using a flapless approach differs significantly from the ideal. In terms of details, we only conduct pilot drilling and then cut and expose to observe whether the pilot drilling is safe. Guided drilling has a positioning effect for experienced implant dental surgeons, and the risk of lateral alveolar

perforation can be avoided in the absence of flap implant preparation.<sup>3,21</sup> The subsequent free-hand implant hole shaping can simply enlarge the pilot hole, but adjustments can also be made based on the surgeon's experience to avoid lateral alveolar perforation or breakage.<sup>22</sup>

Several limitations of this study should be acknowledged. First, this was a retrospective study with inherent limitations. Second, in the absence of a control group, the study contains a certain amount of bias that may have been triggered by guide swing, free-hand drilling, or self-tapping implant placement. Third, the median follow-up was 24 months (range, 18–27 months), which may have led to potential complications that were not exposed. Furthermore, the evaluation of the follow-up results was relatively simple.

In conclusion, the short-term results reported in this review may support the increasing body of evidence showing that HDMIGs tend to yield favorable clinical outcomes and acceptable accuracy without nerve injury, revision, or unexpected perforation. Based on our previous successful experience, we now use HDMIGs to manage edentulous jaws. The problem of edentulous jaws induced by the HDMIG requires further exploration.

### Declaration of conflicting interest

The authors declare that there is no conflict of interest.

### Funding

The authors received the following financial support for the research, authorship, and/or publication of this article: This study was supported by the Natural Science Foundation of Guangdong Province (Grant No. 2016A030310176) and the National Natural Science Foundation of China (Grant No. 81801454).

### ORCID iD

Weiguang Yu  <https://orcid.org/0000-0001-6190-8336>

### References

1. Cassetta M and Bellardini M. How much does experience in guided implant surgery play a role in accuracy? A randomized controlled pilot study. *Int J Oral Maxillofac Surg* 2017; 46: 922–930.
2. Hack G, Liberman L, Vach K, et al. Computerized optical impression making of edentulous jaws - an in vivo feasibility study. *J Prosthodont Res* 2020; 64: 444–453.
3. Jones A. Accuracy of mucosa supported guided dental implant surgery. *Clin Case Rep* 2018; 6: 2131–2139.
4. Cheng AW, Berridge JP, McGary RT, et al. The extraction socket management continuum: a hierarchical approach to dental implant site development. *Clin Adv Periodontics* 2019; 9: 91–104.
5. Shu DL, Liu XZ, Guo B, et al. Accuracy of using computer-aided rapid prototyping templates for mandible reconstruction with an iliac crest graft. *World J Surg Oncol* 2014; 12: 190.
6. Deeb GR, Allen RK, Hall VP, et al. How accurate are implant surgical guides produced with desktop stereolithographic 3-dimensional printers? *J Oral Maxillofac Surg* 2017; 75: 2559.e1–e8.
7. Raico Gallardo YN, Teixeira Da Silva-Olivio IR, Mukai E, et al. Accuracy comparison of guided surgery for dental implants according to the tissue of support: a systematic review and meta-analysis. *Clin Oral Implants Res* 2017; 28: 602–612.
8. Li WW, Xie QF, Wang Y, et al. A pilot study of digital recording of edentulous jaw relations using a handheld scanner and specially designed headgear. *Sci Rep* 2018; 8: 8975.
9. Ohiomoba H, Sonis A, Yansane A, et al. Quantitative evaluation of maxillary alveolar cortical bone thickness and density using computed tomography imaging. *Am J Orthod Dentofacial Orthop* 2017; 151: 82–91.
10. Benic GI, Elmasry M and Hammerle CHF. Novel digital imaging techniques to assess the outcome in oral rehabilitation with dental implants: a narrative review. *Clin Oral Implants Res* 2015; 26: 86–96.

11. Liu YF, Shao XH, Dong XT, et al. Study on realization of minimally invasive dental implant based on techniques of digital design and manufacturing. In: Guo DM, Wang J, Jia ZY, et al. (eds) *Advances in materials manufacturing science and technology XIII, Vol 1: Advanced manufacturing technology and equipment, and manufacturing systems and automation*. Stafa-Zurich: Trans Tech Publications, 2009, p.559.
12. Jemt T. Implant failures and age at the time of surgery: a retrospective study on implant treatment in 2915 partially edentulous jaws. *Clin Implant Dent Relat Res* 2019; 21: 686–692.
13. Turbush SK and Turkyilmaz I. Accuracy of three different types of stereolithographic surgical guide in implant placement: an in vitro study. *J Prosthet Dent* 2012; 108: 181–188.
14. Zitzmann NU, Berglundh T, Marinello CP, et al. Expression of endothelial adhesion molecules in the alveolar ridge mucosa, gingiva and periimplant mucosa. *J Clin Periodontol* 2002; 29: 490–495.
15. Wei R, Xiang-Zhen L, Bing G, et al. Removal of a foreign body from the skull base using a customized computer-designed guide bar. *J Craniomaxillofac Surg* 2010; 38: 279–283.
16. Van de Velde T, Glor F and De Bruyn H. A model study on flapless implant placement by clinicians with a different experience level in implant surgery. *Clin Oral Implants Res* 2008; 19: 66–72.
17. Yuan FS, Sun YC, Wang Y, et al. Accuracy evaluation of a new three-dimensional reproduction method of edentulous dental casts and wax occlusion rims with jaw relation. *Int J Oral Sci* 2013; 5: 155–161.
18. Matsuda T, Goto T, Kurahashi K, et al. Digital assessment of preliminary impression accuracy for edentulous jaws: comparisons of 3-dimensional surfaces between study and working casts. *J Prosthodont Res* 2016; 60: 206–212.
19. Li WW, Yuan FS, Lv PJ, et al. Evaluation of the quantitative accuracy of 3D reconstruction of edentulous jaw models with jaw relation based on reference point system alignment. *PLoS One* 2015; 10: e0117320.
20. Seo C and Juodzbalys G. Accuracy of guided surgery via stereolithographic mucosa-supported surgical guide in implant surgery for edentulous patient: a systematic review. *J Oral Maxillofac Res* 2018; 9: e1.
21. Werbelow L, Weiss M and Schramm A. Long-term follow-up of full-arch immediate implant-supported restorations in edentulous jaws: a clinical study. *Int J Implant Dent* 2020; 6: 34.
22. Torsten J. Data on implant failures will show different results depending on how patients are compiled and analyzed: a retrospective study on 3902 individual patients treated either with one single implant or implants in the edentulous upper jaw. *Clin Implant Dent Relat Res* 2020; 22: 226–236.