

Cone-beam computed tomographic imaging of central giant cell granuloma: A comprehensive review

Mehrnaz Tahmasbi-Arashlow^{1,*}, Paras B. Patel¹, Madhu K. Nair¹, Hui Liang¹, Yi-Shing Lisa Cheng¹

¹Department of Diagnostic Sciences, Texas A&M University College of Dentistry, United States

ABSTRACT

Purpose: The aim of this study was to characterize the cone-beam computed tomographic (CBCT) imaging features of central giant cell granuloma (CGCG) of the jawbone.

Materials and Methods: This study retrospectively reviewed 26 CBCT studies of histologically proven cases of CGCG during a period of 20 years, from 1999 to 2019. Patients' demographic data were recorded, and radiographic features were assessed (location, border, cortication, appearance of the internal structure, locularity, septation, expansion, cortical perforation, effects on surrounding tissue, whether the lesion crossed the midline, and lesion volume).

Results: In this study, CGCGs were seen almost twice as often in the mandible than in the maxilla, and 64.7% of mandibular lesions involved the anterior region. Only 26.9% of lesions crossed the midline, a feature that was considered characteristic of CGCG. Furthermore, 65.4% of lesions were unilocular and 34.6% were multilocular. The correlation between a lesion's size and its locularity was statistically significant, and larger lesions showed a multilocular appearance. The mean volume of multilocular lesions was greater than that of unilocular lesions.

Conclusion: CGCGs showed variable radiographic features on CBCT, and this imaging modality is highly effective at demonstrating the radiographic spectrum and lesional extent of CGCGs in the jawbone. (*Imaging Sci Dent* 2022; 52: 123-31)

KEY WORDS: Cone-Beam Computed Tomography; Granuloma, Giant Cell; Treatment; Jaw

Introduction

Central giant cell granuloma (CGCG) was first described by Jaffe in 1953.¹ Its exact etiology is unknown, and there is debate over whether CGCGs represent benign neoplasms or are non-neoplastic and reactive in nature. CGCG is characterized by varied biological behavior, ranging from lesions that are relatively indolent to those that are locally aggressive. Clinically, CGCG usually occurs in the second and third decades of life, often showing a predilection for women and affecting the mandible rather than the maxilla.²

In general, the diagnosis of gnathic bone pathoses is made by a radiographic evaluation followed by a histo-

pathological examination to obtain a definitive diagnosis.³ Conventional radiography, such as panoramic imaging, is usually the first-line choice for the evaluation of jaw lesions. However, the well-known limitations of this imaging modality, such as distortion, magnification, and superimposition of structures, increase the degree of inaccuracy in the diagnosis and make treatment planning for certain pathologies more challenging. Cone-beam computed tomography (CBCT) overcomes these limitations of 2D radiography. CBCT visualizes structures in multiplanar views and reveals detailed radiographic features of lesions.³⁻⁵

CGCG has a wide range of radiographic features, varying from well-defined expansile lesions to lesions that are ill-defined and destructive, with or without expansion. Studies have reported the radiographic features of CGCGs utilizing conventional radiographs.^{1,6} However, to the authors' knowledge, no prior studies larger than individual case reports have examined the imaging appearance

Received January 30, 2022; Revised March 8, 2022; Accepted March 18, 2022
Published online April 28, 2022

*Correspondence to : Prof. Mehrnaz Tahmasbi-Arashlow
Department of Diagnostic Sciences, Texas A&M University College of Dentistry,
3302 Gaston Ave, Dallas, TX 75246, USA
Tel) 1-214-828-8197, E-mail) tahmasbi@tamuedu

Copyright © 2022 by Korean Academy of Oral and Maxillofacial Radiology

This is an Open Access article distributed under the terms of the Creative Commons Attribution Non-Commercial License (<http://creativecommons.org/licenses/by-nc/3.0>) which permits unrestricted non-commercial use, distribution, and reproduction in any medium, provided the original work is properly cited.

Imaging Science in Dentistry · pISSN 2233-7822 eISSN 2233-7830

Table 1. Description of radiographic features

Criteria	Description of radiographic appearance
Location	Establishing the epicenter of the lesion Anterior: canine to canine Posterior: junction between the first premolar and canine to maxillary tuberosity/retromolar pad region Anterior and posterior: lesion involving both regions Ramus and condyle
Border	Lesion borders are considered well-defined or partially well-defined, depending on whether the whole boundary is clearly distinguishable or only partially. The lesion is considered ill-defined when no clear distinction between the lesion and surrounding bone can be made.
Cortication	Well-corticated: all borders present with a radiopaque line Moderately corticated: some parts of the lesion border present with a radiopaque line Non-corticated: borders are identified with no radiopaque line
Appearance of internal structures	The content of the lesion is compared with the surrounding tissue and accordingly the lesion is categorized as: Hypodense/low attenuation with no internal trabeculation Mixed density with internal granular bone deposits/internal trabecula Hyperdense/high attenuation
Locularity	Unilocular: lesion with single compartment Multilocular: lesion with multiple compartments separated by septations
Septations	Wispy septa, regardless of whether they emanate at right angles to the edge of the lesion Coarse curved septa Sharp straight septa at right angles with each other/make geometric shapes Combination of any two or more of the above No septa
Lesion border	Smooth border Scalloping border: a series of contiguous arcs that may develop around the roots of teeth or within adjacent bone.
Effects on surrounding tissues	Teeth displacement, root resorption, extension into the mandibular canal, maxillary sinus, and nasal cavity

of CGCGs with the use of advanced imaging like CBCT; accordingly, knowledge of the imaging features of this lesion in the literature is limited. The main objective of this study was to demonstrate and present the CBCT findings of CGCG in the maxillofacial region. In addition, various treatment modalities of the lesion were reviewed.

Materials and Methods

CBCT imaging data of patients with histopathologically proven CGCG from January 1999 through January 2019 were retrospectively evaluated. The study protocol was approved by the institutional review board of the authors' affiliated institution. All procedures conformed to the tenets of the Declaration of Helsinki.

The inclusion criteria were the availability of CBCT scans of patients who had a histopathological diagnosis of CGCG. The exclusion criteria were poor-quality images and postoperative CBCT images without initial radiographs.

Patients' demographic data, including age and sex, were

recorded. The CBCT studies were reviewed in consensus by 3 board-certified oral and maxillofacial radiologists. All CBCT images were analyzed using the InVivo6 Dental software (Anatomage, Inc., San Jose, CA, USA). The medical imaging software Mimics Research (20.0 version; Leuven, Belgium) was used to calculate the lesion volume.

The following radiographic features were assessed: location, borders, cortication, appearance of internal structures, locularity, septation, expansion, cortical perforation, effects on surrounding structures, and involvement past the midline. The radiographic features are described in Table 1. Descriptive statistics were calculated using Microsoft Excel version 2102 (Microsoft, Redmond, WA, USA), including the total number of cases based on the above factors. Point-biserial correlations and the chi-square test were used for statistical analysis, with a *P*-value of <0.05 considered significant. The normality of the data for lesion volume was tested using the Kolmogorov-Smirnov test, which yielded a test statistic (D) of 0.25097. The data were analyzed using Stata/SE 16.1 (StataCorp, College Station, TX, USA).

Results

The CBCT studies of 57 cases were reviewed, but 31 patients who did not meet the inclusion criteria were excluded. Data regarding age and sex are shown in Table 2. At the time of diagnosis, the age range was from 8 to 86 years (mean age: 31 years, median age: 24.5 years), with the largest proportion of patients (34.6%) being diagnosed in the second decade of life. Among the 26 CBCT scans included, 35% were from male patients and 65% were from female patients.

Data regarding radiographic features are shown in Table 3. Out of 26 cases, the mandible was more frequently affected (65.4%; n = 17) than the maxilla (34.6%; n = 9). In

Table 2. Distribution of central giant cell granuloma according to age and sex

Age (years)	Female	Male	Total
0-10	1	1	2
11-20	6	3	9
21-30	3	2	5
31-40	4	0	4
41-50	1	1	2
51-60	0	0	0
61-70	0	1	1
71-80	2	0	2
81-90	0	1	1
Total	17	9	26

Table 3. Radiographic features of central giant cell granuloma

Features	Mandible, n (%) (Total: 17)	Maxilla, n (%) (Total: 9)	Total, n (%) (Total: 26)
Border definition with marginal morphology:			
Well-defined with a smooth margin	4 (23.5)	3 (33.3)	7 (26.9)
Well-defined with a scalloped margin	9 (52.9)	4 (44.4)	13 (50)
Partly well-defined with a smooth margin	1 (5.9)	0	1 (3.8)
Partly well-defined with a scalloped margin	2 (11.8)	2 (22.2)	4 (15.4)
Ill-defined	1 (5.9)	0	1 (3.8)
Cortication			
Well-corticated	6 (35.3)	3 (33.3)	9 (34.6)
Moderately corticated	9 (52.9)	6 (66.7)	15 (57.7)
Non-corticated	2 (11.8)	0	2 (7.7)
Appearance of the internal structures (density)			
Hypodense	11 (64.7)	6 (66.7)	17 (65.4)
Mixed with internal granular bone deposits/internal trabecula	6 (35.3)	3 (33.3)	9 (34.6)
Hyperdense	0	0	0
Locularity			
Unilocular	11 (64.7)	6 (66.7)	17 (65.4)
Multilocular	6 (35.3)	3 (33.3)	9 (34.6)
Septations			
Wispy septa, regardless of whether they emanate at right angles to the edge of the lesion	6 (35.3)	6 (66.7)	12 (46.2)
Coarse curved septa	1 (5.9)	0	1 (3.8)
Sharp straight septa at right angles with each other	1 (5.9)	0	1 (3.8)
Combination of any two or more of the above	1 (5.9)	1 (11.1)	2 (7.7)
No septa	8 (47.1)	2 (22.2)	10 (38.5)
Effect on adjacent teeth			
Displacement/root divergence	3 (17.6)	2 (22.2)	5 (19.2)
Root resorption	0	0	0
Both displacement and resorption	7 (41.2)	6 (66.7)	13 (50)
No displacement, no resorption/edentulous area	7 (41.2)	1 (11.1)	8 (30.8)
Cortical bone expansion with or without perforation	13 (76.5)	8 (88.9)	21 (80.8)
Cortical bone perforation with or without expansion	11 (64.7)	8 (88.9)	19 (73.1)
Crossing the midline	5 (29.4)	2 (22.2)	7 (26.9)

Table 4. Distribution of central giant cell granuloma according to location

Location	Mandible, n (%)	Maxilla, n (%)	Total, n (%)
Only anterior	2 (11.8)	1 (11.1)	3 (11.5)
Only posterior	6 (35.3)	2 (22.2)	8 (30.8)
Both anterior and posterior	9 (52.9)	6 (66.7)	15 (57.7)
Ramus and condyle	0	0	0
Total	17 (65.4)	9 (34.6)	26 (100)

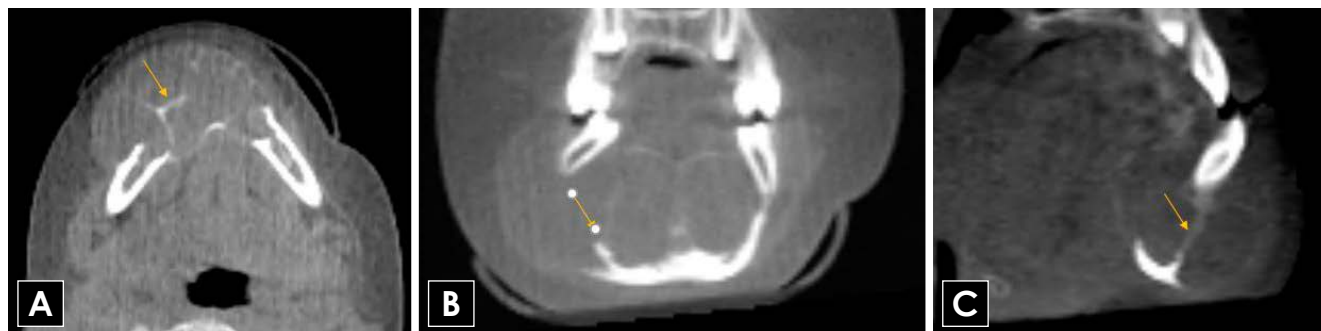


Fig. 1. Axial (A), coronal (B), and sagittal (C) CBCT images indicate an example of an expansile multilocular low-density lesion involving the anterior region of the mandible. Considerable bone expansion is evident buccally. Note the wispy/granular septations within the lesion (arrows). CBCT: cone-beam computed tomography.

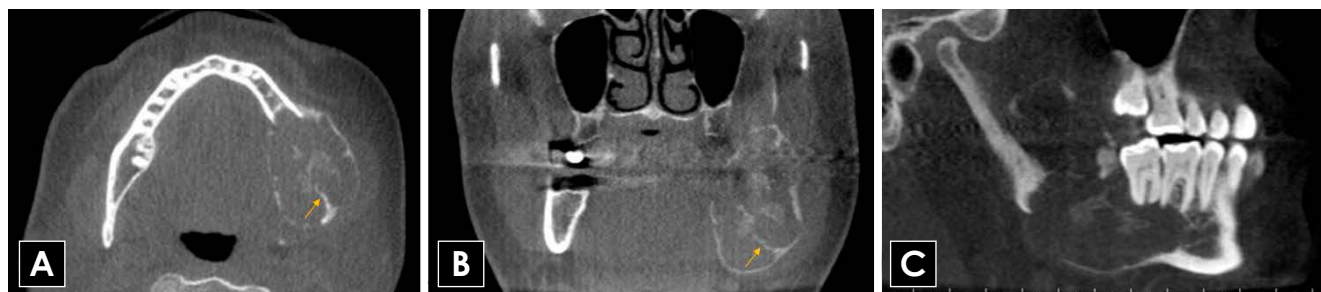

Fig. 2. Axial (A), coronal (B), and sagittal (C) CBCT images indicate an example of an expansile multilocular low-density lesion involving the posterior region of the mandible. Wispy/granular septations that emanate at right angles from the periphery of the lesion are evident (arrows). CBCT: cone-beam computed tomography.

69.2% of cases, the lesions involved the anterior region of the jaws (with or without posterior extension). Localized posterior involvement was more common in the mandible (35.3%) than in the maxilla (22.2%), whereas localized anterior jaw involvement showed a more equal distribution (Table 4). Out of 26 cases, 29.4% of mandibular lesions and 22.2% of maxillary lesions crossed the midline.

Of the 26 cases, 65.4% of lesions were unilocular and 34.6% were multilocular ($P > 0.05$). In the mandible, 35.3% of lesions were multilocular, while this was the case for 33.3% of lesions in the maxilla. In 26 cases (65.4%), the

lesions were hypodense with no evidence of internal structures, whereas 34.6% of cases showed internal granular trabeculae. Out of 26 cases, 61.5% of lesions showed cortical bone expansion with perforation and 11.5% of cases showed cortical bone perforation without expansion. The lesions caused root displacement in 19.2% of cases and root displacement with resorption in 50%. The borders of the lesions were well-defined in 76.9% of cases, partly well-defined in 19.2%, and ill-defined in 3.8% of cases (Figs. 1-4). Lesion volume varied considerably (Fig. 5). The mean lesion volume was 7,651.8 mm³, whereas the

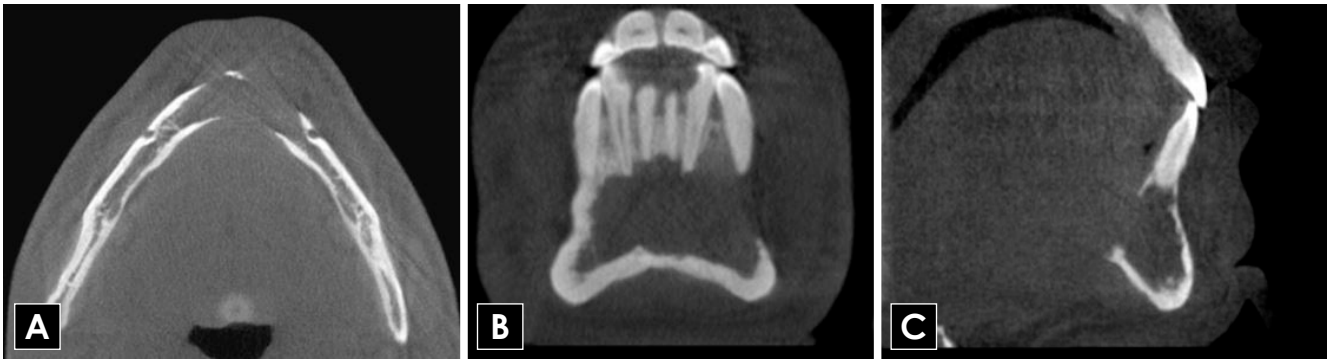


Fig. 3. Axial (A), coronal (B), and sagittal (C) CBCT images indicate a unilocular low-density lesion without apparent expansion involving the anterior region of the mandible. CBCT: cone-beam computed tomography.

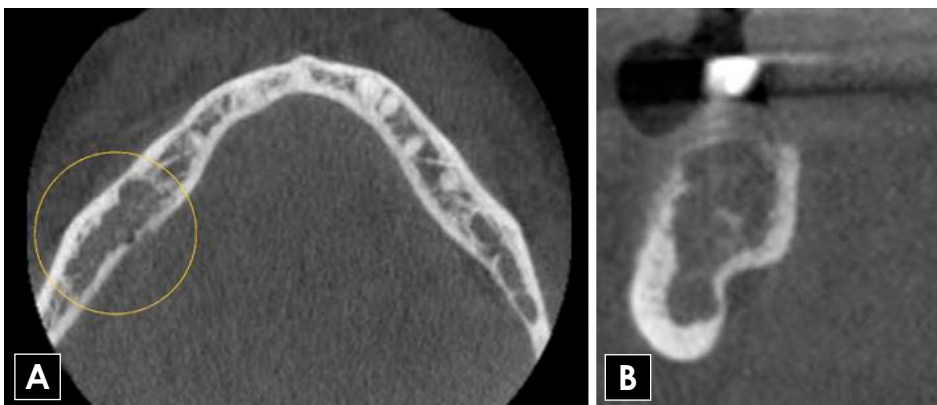


Fig. 4. Axial (A), and coronal (B) CBCT images indicate an ill-defined low-density lesion without expansion involving the posterior right side of the mandible. CBCT: cone-beam computed tomography.

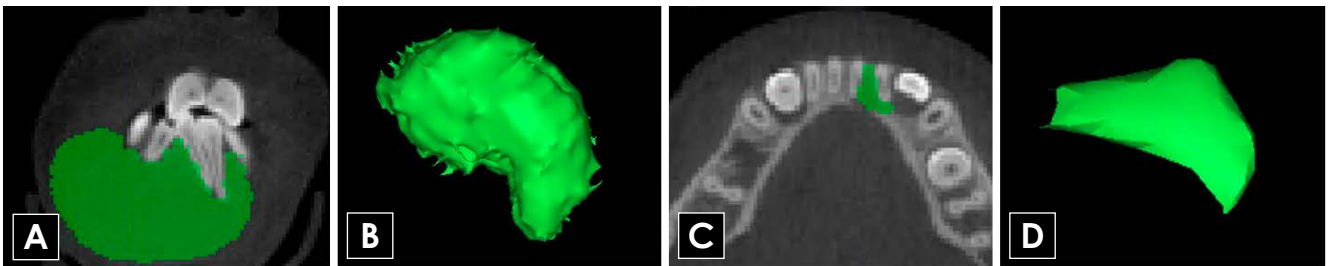


Fig. 5. Volumetric analysis of the largest (A, B) and smallest (C, D) CGCG lesions in this study. Coronal (A) and axial (C) CBCT images of CGCG demarcated and filled to reconstruct the 3-dimensional structure (B: 31,347.0 mm³, D: 33.5 mm³). CGCG: central giant cell granuloma, CBCT: cone-beam computed tomography.

median was 2,821.7 mm³ (Range: 33.5 mm³-31,347 mm³, interquartile range (IQR): 12,316 mm³).

Two hybrid lesions comprising CGCG and central ossifying fibroma (COF) and one hybrid lesion comprising CGCG, and central odontogenic fibroma (CODF) were identified (Figs. 6 and 7).

Discussion

Central giant cell granuloma is a locally aggressive lesion

of unknown etiology. Initially, it was thought to be a reparative reaction of bone to trauma, inflammation, or intra-medullary hemorrhage. However, because the lesion does occasionally present with aggressive behavior and it consists of osteoclast-like cells similar to giant cell tumors of long bone, CGCG is best considered a benign neoplasm.^{2,7}

Demographics and clinical features

The clinical and biological behavior of CGCG can range from a slowly growing asymptomatic lesion with a rela-

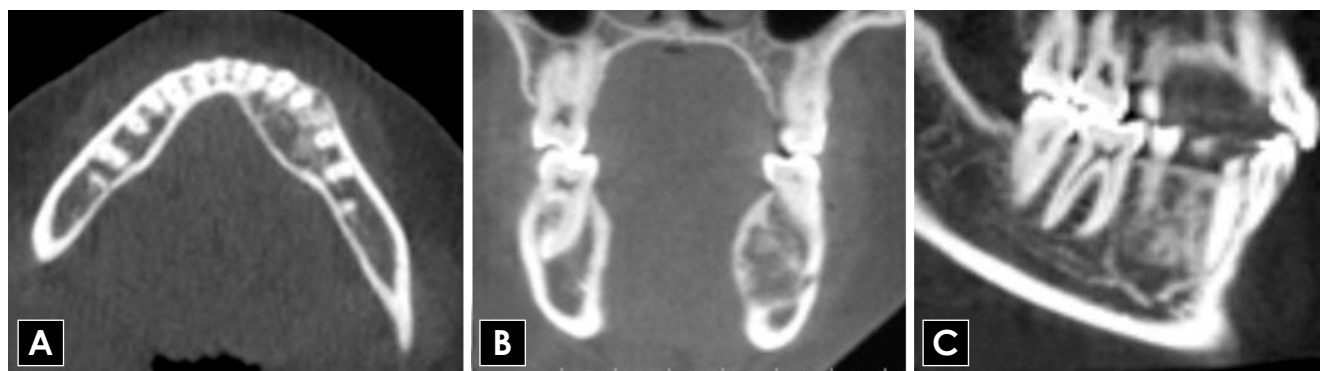

Fig. 6. Axial (A), coronal (B), and sagittal (C) CBCT images of a hybrid CGCG with COF lesion in the left premolar region of the mandible with a well-defined, mixed-density appearance. CBCT: cone-beam computed tomography, CGCG: central giant cell granuloma, COF: central ossifying fibroma.

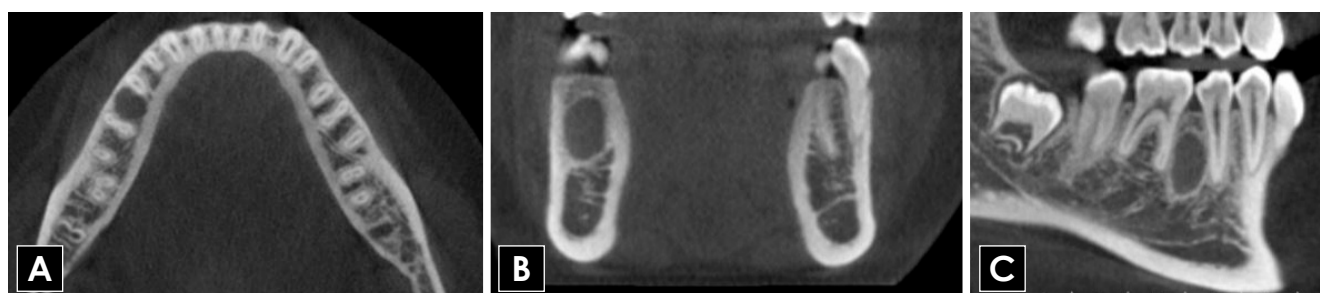


Fig. 7. Axial (A), coronal (B), and sagittal (C) CBCT images of a hybrid CGCG with CODF lesion showing a well-defined, corticated, unilocular, low-density lesion in the posterior right side of the mandible. CBCT: cone-beam computed tomography, CGCG: central giant cell granuloma, CODF, central odontogenic fibroma.

tively indolent course and low recurrence rate, to an aggressive rapidly growing lesion that presents with pain, local bone destruction, root resorption, and tooth displacement, showing a high recurrence rate.⁸ CGCG affects mostly adolescents and young adults and is predominantly seen in the mandible.² While this series did demonstrate a wider age range, most cases were observed within the first 3 decades of life (61.5%). Studies have demonstrated a slight female predominance for CGCG, which is consistent with the findings of the current series. There is speculation that this may be the result of hormonal influences and secretion on the development and growth of CGCG.⁹⁻¹⁹

Previous studies have shown that the mandible, particularly the anterior portion, is the most common location of CGCG lesions.^{16,20} This study showed similar findings, with CGCGs being observed almost twice as often in the mandible than in the maxilla. Moreover, 64.7% of mandibular lesions involved the anterior region (with or without posterior extension). Studies have also reported the tendency of CGCGs to cross the midline.¹⁷ However, in the present series of 26 patients, only 26.9% of lesions crossed the

midline. Of the 26 cases, 30.8% of the lesions were located in the posterior region of the jaws. Lesions in non-tooth-bearing regions (e.g., the ramus or condyle) were not found. The present results differ from those reported by Kaffe et al.,²¹ who found that half of their cases were located in the posterior regions of the jaws.

Histological features

The histological features of CGCG have been defined by the World Health Organization as “a localized, benign but sometimes aggressive, osteolytic proliferation consisting of fibrous tissue with hemorrhage and hemosiderin deposits and presence of osteoclast-like giant cells with reactive bone formation”.¹⁰ Since CGCG is histologically and radiographically identical to brown tumors of hyperparathyroidism, serum levels of parathyroid hormone and calcium should be tested in patients with histologically confirmed CGCG. Furthermore, giant cell granuloma-like lesions can occur in other bone diseases or in association with syndromes, including aneurysmal bone cysts (ABCs), cherubism, Ramon syndrome, Jaffe-Campanacci syndrome,

Noonan-like/multiple giant cell lesion syndrome, and neurofibromatosis type 1.^{6,22,23}

Giant cell tumors of bone are rare benign neoplasms that most often affect the long bones and are histologically indistinguishable from CGCGs. It is important to distinguish between these 2 lesions since giant cell tumors have been reported to show high rates of recurrence, metastasis, and malignant transformation. Genetically, mutations in *H3F3A* and *IDH2* have been observed in true giant cell tumors of bone, but these mutations have not been observed in CGCG.^{9,24,25}

Radiographic features

This study evaluated the radiological features of 26 cases of CGCG. A wide range of radiographic features was seen, ranging from small innocuous lesions to large destructive multilocular lesions involving the mandible or maxilla.

Unilocular lesions were more frequent (65.4%), and larger lesions tended to be multilocular. Point-biserial correlation analysis demonstrated a positive correlation between increased size and an increased likelihood of a lesion being multilocular ($P < 0.05$); however, this was only statistically significant when calculated for lesions regardless of the duration (time) that lesions were present. The mean volume of multilocular lesions was 15,939.45 mm³, whereas the mean volume of unilocular lesions was only 3,264.207 mm³. These results supported the findings of Stavropoulos et al.,¹⁷ Kaffe et al.,²¹ and Wood et al.²⁶ that multilocular lesions tended to be larger.

Previous studies have suggested that these lesions often displace teeth rather than resorb them.^{14,27} However, in the present study, tooth displacement without resorption was found in 19.2% of the cases compared to 50% of cases with both tooth displacement and resorption. Both tooth displacement and resorption occurred predominantly in larger lesions.

The internal structure of CGCG was variable, ranging from lesions that appeared completely hypodense to a more mixed-density internal appearance, showing the presence of internal granular bone deposits. In the present study, most of the lesions (65.4%) were hypodense, with no evidence of internal structures, and 34.6% of lesions were mixed, with internal granular bone deposits. No completely hyperdense lesions were found. These results are consistent with the findings of previous literature.^{17,21}

Wispy or granular septations that emanate at right angles from the periphery of the lesion are some of the characteristic radiographic features of CGCG.²⁸ In this study, the septa of lesions were more granular/wispy, with some of them at right angles to the cortex. Thus, the presence of

granular septations that emanate at right angles from the edge of the lesion can potentially be a diagnostic clue for CGCG. The pattern of septations was not evaluated in prior studies.

Non-aggressive CGCGs are slow-growing lesions and, therefore, they usually have well-defined borders.²¹ In previous studies, most lesions had well-defined borders.^{17,21} The result of this study are in agreement, as 76.9% of the cases had well-defined borders and 19.2% of cases showed partially well-defined borders.^{17,21,29}

Six of the 9 maxillary lesions (66.7%) showed encroachment of the maxillary sinus, and 4 of those lesions affected the nasal cavity as well. Of the maxillary lesions, 4 cases (44.4%) involved the nasopalatine canal. Six of the mandibular lesions (35.3%) showed inferior alveolar canal involvement with or without displacement. No correlation was found between sex and the location of the lesions ($P > 0.05$).

Hybrid lesions are rare and are composed of histopathological features of different distinct entities in a single lesion.³⁰ Previous studies reported hybrid lesions such as CGCG and ameloblastoma, CGCG and aneurysmal bone cyst, CGCG with odontogenic keratocyst, CGCG in association with CODF, and CGCG with fibro-osseous lesions such as COF. The histological features contribute to the diagnosis of these lesions.³¹

In this study, 2 hybrid lesions comprising CGCG and central ossifying fibroma (CGCG-COF) and 1 hybrid lesion comprising CGCG, and central odontogenic fibroma (CGCG-CODF) were identified. Hybrid lesions of CGCG and COF are rare. There is a predominance in women, with a mean age of 35.8 years. It has predilection for mandibular posterior regions. Clinically, this hybrid lesion presents as a slow-growing, firm, painless swelling. The radiographic features of CGCG-COF range from a radiolucent to mixed-density lesion with the presence of varying degrees of radiopacity. According to prior studies, a mixed-density appearance and expansion of the cortical plate are predominant features of this hybrid lesion.^{31,32} In this study, both CGCG-COF lesions presented as expansile, well-defined, corticated, mixed-density lesions with tooth displacement. The management of CGCG-COF ranges from curettage or enucleation for small, well-defined lesions to radical surgery for large lesions with more aggressive patterns.³³

CGCG in association with CODF is fairly uncommon, occurring predominantly in women with an age range from 5 to 75 years (average age: 33.3 ± 20.4 years). The lesion usually occurs in the posterior region of the mandible. Cortical bone expansion is a significant feature of this lesion. Swelling and tooth displacement are noted with this entity

as well. Radiographically, CGCG-CODF presents as well-defined unilocular or multilocular radiolucencies.^{22,34,35} In this study, the CGCG-CODF presented as a well-defined, corticated, unilocular, low-attenuation lesion with no bone expansion. Tooth displacement was noted. Treatment typically consists of curettage and surgical excision.^{22,34,35} Since recurrence of these lesions is common, surgical excision is the treatment of choice.^{22,34}

The top differential diagnoses of CGCG include ABC, brown tumors of hyperparathyroidism, ameloblastoma, and odontogenic myxoma. ABCs show similar radiographic characteristics to those of CGCG. However, ABCs enlarge rapidly with ballooning expansion and occur mostly in the posterior region of the mandible. Fluid-fluid level is a characteristic, but not unique, feature of ABCs on T2-weighted magnetic resonance imaging (MRI).^{36,37} Ameloblastomas occur predominantly in older age groups (third to fifth decades) than CGCGs and are more common in the posterior region of the mandible.³⁸

Odontogenic myxomas occur in older individuals, are less expansile than CGCGs, and are more common in the posterior region of the mandible. Myxomas show high signal intensity on T2-weighted MRI, which is a characteristic of this tumor.³⁹ The radiographic appearance of CGCG is often identical to that of brown tumor of hyperparathyroidism. Hence, patients with histologically confirmed giant-cell lesions should be screened for elevated levels of serum calcium, parathyroid hormone, and alkaline phosphatase.⁶

The appearance of the internal septa can help differentiate lesions. Ameloblastomas usually contain coarse and curved septa whereas odontogenic myxomas may contain thin, sharp, straight/geometric septa. Septa at right angles to the periphery may be present in CGCGs.^{27,36,38,39}

There are some limitations of this study, including the relatively small sample size and lack of clinical signs and symptoms of cases. Additionally, because of the retrospective nature of this study, follow-up information on the cases was limited. Therefore, further studies with advanced imaging and long-term follow-up, including detailed clinical information, are required for a more thorough understanding of this entity.

Treatment

The management of CGCG is currently based on its clinical and radiographic parameters, which vary considerably; therefore, management decisions are usually made on a case-by-case basis. Small non-aggressive lesions are usually treated with curettage, followed by periodic evaluation. However, approximately 20% of cases do show a

tendency to recur. Surgical treatment ranging from curettage to en bloc resection has been suggested for more aggressive lesions. Alternative nonsurgical approaches such as intralesional corticosteroid injection, subcutaneous calcitonin injection, or subcutaneous interferon-alpha injection have been suggested, in addition to the use of newer systemic therapies such as RANKL inhibitors. However, the success rate of these therapies is variable. Research indicates that nonsurgical therapies are not capable of eliminating CGCG in every patient, although good results were noted in some cases.^{6,40,41}

In conclusion, CGCGs show a spectrum of radiographic appearances that vary from well-defined expansile lesions to ill-defined destructive lesions with no obvious expansion. CGCGs are mostly hypodense, with internal granular bone deposits and wispy septations often observed. CBCT imaging is highly effective in demonstrating the radiographic range and extent of CGCGs in the maxillofacial region. CGCG should be considered in the differential diagnosis of lesions with similar radiographic features, such as ABC and brown tumor of hyperparathyroidism. Radiologists should be aware of the variability in the presentation of CGCGs to obtain an accurate diagnosis and, most importantly, to facilitate proper management.

Acknowledgements

The abstract of this study was presented as an oral presentation at the ICDMFR 2021 meeting.

Conflicts of Interest: None

References

1. Jaffe HL. Giant-cell reparative granuloma, traumatic bone cyst, and fibrous (fibro-osseous) dysplasia of the jawbones. *Oral Surg Oral Med Oral Pathol* 1953; 6: 159-75.
2. Baskaran P, Gopal M, Rastogi V, Misra SR. Aggressive central giant cell granuloma of the mandible, a diagnostic dilemma. *J Oral Maxillofac Radiol* 2015; 3: 88-91.
3. Jaju PP, Jaju SP. Clinical utility of dental cone-beam computed tomography: current perspectives. *Clin Cosmet Investig Dent* 2014; 6: 29-43.
4. Gohel A, Villa A, Sakai O. Benign jaw lesions. *Dent Clin North Am* 2016; 60: 125-41.
5. Venkatesh E, Elluru SV. Cone beam computed tomography: basics and applications in dentistry. *J Istanbul Univ Fac Dent* 2017; 51 (3 Suppl 1): S102-21.
6. De Lange J, Van den Akker HP. Clinical and radiological features of central giant-cell lesions of the jaw. *Oral Surg Oral Med Oral Pathol Oral Radiol Endod* 2005; 99: 464-70.
7. Abdelqader S, Roche N, Manfredi L, Papon JF, Maman L, Ferré

- F. Giant-cell granuloma: 2 case reports. *J Oral Med Oral Surg* 2018; 24: 182-6.
8. Jeyaraj P. Management of central giant cell granulomas of the jaws: an unusual case report with critical appraisal of existing literature. *Ann Maxillofac Surg* 2019; 9: 37-47.
 9. Hosur MB, Puranik RS, Vanaki SS, Puranik SR, Ingaleshwar PS. Clinicopathological profile of central giant cell granulomas: an institutional experience and study of immunohistochemistry expression of p63 in central giant cell granuloma. *J Oral Maxillofac Pathol* 2018; 22: 173-9.
 10. Barnes L, Eveson JW, Reichart P, Sidransky D. Odontogenic Tumours. In: WHO classification of tumors: pathology and genetics of head and neck tumours. Lyon: IARC; 2005. p. 53-4.
 11. Andersen L, Fejerskov O, Philipsen HP. Oral giant cell granulomas: A clinical and histological study of 129 new cases. *Acta Pathol Microbiol Scand A* 1973; 81: 606-16.
 12. Eisenbud L, Stern M, Rothberg M, Sachs SA. Central giant cell granuloma of the jaws: experiences in the management of thirty-seven cases. *J Oral Maxillofac Surg* 1988; 46: 376-84.
 13. Ficarra G, Kaban LB, Hansen LS. Central giant cell lesions of the mandible and maxilla: a clinicopathologic and cytometric study. *Oral Surg Oral Med Oral Pathol* 1987; 64: 44-9.
 14. Horner K. Central giant cell granuloma of the jaws: a clinicoradiological study. *Clin Radiol* 1989; 40: 622-6.
 15. Waldron CA, Shafer WG. The central giant cell reparative granuloma of the jaws. An analysis of 38 cases. *Am J Clin Pathol* 1966; 45: 437-47.
 16. Whitaker SB, Waldron CA. Central giant cell lesions of the jaws. *Oral Surg Oral Med Oral Pathol* 1993; 75: 199-208.
 17. Stavropoulos F, Katz J. Central giant cell granulomas: a systematic review of the radiographic characteristics with the addition of 20 new cases. *Dentomaxillofac Radiol* 2003; 31: 213-7.
 18. De Lange J, van den Akker HP, Klip H. Incidence and disease-free survival after surgical therapy of central giant-cell granulomas of the jaw in The Netherlands: 1990-1995. *Head Neck* 2004; 26: 792-5.
 19. Auclair PL, Cuenin P, Kratochvil FJ, Slater LJ, Ellis GL. A clinical and histomorphologic comparison of the central giant cell granuloma and the giant cell tumor. *Oral Surg Oral Med Oral Pathol* 1988; 66: 197-208.
 20. Triantafyllidou K, Venetis G, Karakinaris G, Iordanidis F. Central giant cell granuloma of the jaws: a clinical study of 17 cases and a review of the literature. *Ann Otol Rhinol Laryngol* 2011; 120: 167-74.
 21. Kaffe I, Ardekian L, Taicher S, Littner MM, Buchner A. Radiologic features of central giant cell granuloma of the jaws. *Oral Surg Oral Med Oral Pathol Oral Radiol Endod* 1996; 81: 720-6.
 22. Upadhyaya JD, Cohen DM, Islam MN, Bhattacharyya I. Hybrid central odontogenic fibroma with giant cell granuloma like lesion: a report of three additional cases and review of the literature. *Head Neck Pathol* 2018; 12: 166-74.
 23. Miloro M, Quinn PD. Synchronous central giant cell lesions of the jaws: report of a case and review of the literature. *J Oral Maxillofac Surg* 1995; 53: 1350-5.
 24. Cleven AH, Höcker S, Briaire-de Bruijn I, Szuhai K, Cleton-Jansen AM, Bovée JV. Mutation analysis of H3F3A and H3F3B as a diagnostic tool for giant cell tumor of bone and chondroblastoma. *Am J Surg Pathol* 2015; 39: 1576-83.
 25. Gomes CC, Diniz MG, Amaral FR, Antonini Guimarães BV, Gomez RS. The highly prevalent H3F3A mutation in giant cell tumours of bone is not shared by sporadic central giant cell lesion of the jaws. *Oral Surg Oral Med Oral Pathol Oral Radiol* 2014; 118: 583-5.
 26. Wood NK, Goaz PW. Differential diagnosis of oral lesions. 4th ed. St. Louis: Mosby-Year Book; 1991. p. 393-5.
 27. Bodner L, Bar-Ziv J. Radiographic features of central giant cell granuloma of the jaws in children. *Pediatr Radiol* 1996; 26: 148-51.
 28. Abdelkarim AZ, Abu El Sadat SM, Chmieliauskaite M, Syed AZ. Radiographic diagnosis of a central giant cell granuloma using advanced imaging: cone beam computed tomography. *Cureus* 2018; 10: e2735.
 29. Whitaker SB, Bouquot JE. Estrogen and progesterone receptor status of central giant cell lesions of the jaws. *Oral Surg Oral Med Oral Pathol* 1994; 77: 641-4.
 30. Ide F, Horie N, Shimoyama T, Sakashita H, Kusama K. So-called hybrid odontogenic tumors: do they really exist? *Oral Med Pathol* 2001; 6: 13-21.
 31. Rai A, Ahmad SA, Saleem M, Faisal M. Hybrid central giant cell granuloma and central ossifying fibroma: case report and literature review. *J Oral Maxillofac Surg Med Pathol* 2019; 31: 258-63.
 32. Mosqueda Taylor A, Bermúdez Flores V, Díaz Franco MA. Combined central odontogenic fibroma and giant cell granuloma-like lesion of the mandible: report of a case and review of the literature. *J Oral Maxillofac Surg* 1999; 57: 1258-62.
 33. Fasolis M, Zavatiero E, Garzino-Demo P, Ramieri G, Berrone S. Surgical management of synchronous central giant cell granuloma and ossifying fibroma of the mandible. *J Craniofac Surg* 2013; 24: e627-30.
 34. Bologna Molina R, Pacheco Ruiz L, Mosqueda Taylor A, Huesca Ramírez HG, Ponce Lonato JA, González-González R. Central odontogenic fibroma combined with central giant cell lesion of the mandible. Immunohistochemical profile. *J Clin Exp Dent* 2011; 3: e348-51.
 35. Neville BW, Damm DD, Allen CM, Chi AC. Oral and maxillofacial pathology. 4th ed. St. Louis: Elsevier; 2016.
 36. Möller B, Claviez A, Moritz JD, Leuschner I, Wiltfang J. Extensive aneurysmal bone cyst of the mandible. *J Craniofac Surg* 2011; 22: 841-4.
 37. Yu H, Cui JL, Cui SJ, Sun YC, Cui FZ. Differentiating benign from malignant bone tumors using fluid-fluid level features on magnetic resonance imaging. *Korean J Radiol* 2014; 15: 757-63.
 38. Wood N, Goaz P. Differential diagnosis of oral and maxillofacial lesions. 5th ed. St. Louis: Mosby; p. 337-40.
 39. Wang K, Guo W, You M, Liu L, Tang B, Zheng G. Characteristic features of the odontogenic myxoma on cone beam computed tomography. *Dentomaxillofac Radiol* 2017; 46: 20160232.
 40. de Lange J, van den Akker HP, van den Berg H. Central giant cell granuloma of the jaw: a review of the literature with emphasis on therapy options. *Oral Surg Oral Med Oral Pathol Oral Radiol Endod* 2007; 104: 603-15.
 41. Naidu A, Malmquist MP, Denham CA, Schow SR. Management of central giant cell granuloma with subcutaneous denosumab therapy. *J Oral Maxillofac Surg* 2014; 72: 2469-84.