

Case report

Management and survival of patients with Mullerian adenosarcoma of the cervix without sarcomatous overgrowth desiring fertility preservation, a case report and review of the literature

Nicole Lugo Santiago*, John Groth, Nuzhath Hussain, Rajul Kothari

University of Illinois at Chicago College of Medicine, 820 S Wood St M/C 808 Chicago, IL 60612, United States

1. Introduction

Mullerian adenosarcomas are a rare malignancy, first described in 1974 (Roth et al., 1976). They are a form of mesenchymal tumor that most often arise in the uterus in postmenopausal women, however, there may be extrauterine manifestations including the cervix (Kanayama et al., 2017). They most commonly present in a low-grade fashion with a benign epithelial component and an internal malignant mesenchymal component, although high grade manifestations have been reported (Bagga et al., 2010). On evaluation of mesenchymal tumors, Mullerian adenosarcomas are often described as a stepping point between benign adenofibromas and malignant carcinosarcomas (Andrade et al., 1992). Cervical Mullerian adenosarcomas primarily present in adolescents (Fleming et al., 2009).

There is limited information regarding primary cervical Mullerian adenosarcomas. Prognosis has historically been favorable, with the exception of deeply invasive tumors or those with high-grade sarcomatous overgrowth (Fleming et al., 2009). Twenty-nine cases of women with low grade disease have been collected for review. Twenty cases were primarily managed with hysterectomy. The remaining nine cases underwent local excision, a cold knife conization, or trachelectomy with five known cases of disease recurrence requiring additional intervention. Mortality has been identified in one case. We present a case of a 14-year-old woman treated with a cervical wedge resection and no disease recurrence 4 years after diagnosis (see Table 1).

2. Case

The patient presented at age 14 with intermenstrual spotting with a vaginal mass. The patient was otherwise healthy, not sexually active, with menarche at age 12 with intermittent dysmenorrhea. A pap smear was performed showing ASCUS, High Risk HPV negative. Pelvic ultrasound was noted to be significant for an anteverted uterus measuring $6.7 \times 4.0 \times 5.2$ cm and an endometrial stripe measuring 7 mm. A small 5 mm hypoechoic avascular structure was noted in the cervix and an ovoid hypoechoic structure was seen in the vaginal canal without

vascularity, measuring $1.2 \times 0.7 \times 1.0$ cm. Both ovaries were normal. An exam under anesthesia was performed, and a 2×3 cm polypoid cervical mass was removed using torsion. Electrocautery was used to remove the stump. Pathology was significant for adenosarcoma with low grade morphology and unclear margins. The lesion was described as a polypoid mass with phyllodes type growth pattern with areas of immature spindled stroma condensing around irregular and dilated cystic spaces lined by benign endocervical type columnar epithelium (Fig. 1). No pleomorphic cells were noted in the stroma. As malignancy was not expected at the time of the procedure, the specimen was not marked for orientation, and thus no comment on margins were able to be made.

The patient was referred to gynecologic oncology. MRI pelvis showed a questionable lesion in the mesentery but no pelvic findings. PET CT was concerning for hypermetabolic activity in the subcarinal and right hilar lymph nodes and a possible hypermetabolic mesenteric implant. CT scan confirmed mildly enlarged mesenteric lymph node of unclear clinical significance. The patient underwent subcarinal endoscopic lymph node dissection that showed no carcinomatous or sarcomatous elements identified. A second dilation and curettage was performed. An endometrial polyp was noted and extracted. An additional small cervical polyp was removed and a 1.5×1.5 cm cervical wedge resection of the posterior cervical lip was performed at the site of the original lesion using a scalpel. Final pathology showed no evidence of malignancy. Management options were reviewed with the patient and family including hysterectomy or conservative management with observation. Conservative management was chosen. PET CT after 6 months showed no evidence of recurrence. Patient underwent repeat dilation and curettage and MRI pelvis secondary to intermenstrual vaginal bleeding 7 months after initial diagnosis. No evidence of recurrence was identified. The patient has remained disease free for four years to date with recent MRI pelvis with no evidence of disease. The patient and her mother have consented to participation in this case report (see Fig. 2).

* Corresponding author.

E-mail address: nicole.lugo13@gmail.com (N. Lugo Santiago).

Table 1
Review of the published studies that addressed low grade Mullerian adenocarcinoma of the cervix.

Author	Age (yo)	Diagnosis or Presentation	Available pathology	Treatment	Follow Up	Recurrence	Treatment if recurrence	Surveillance (if available) and outcome
Roth et al., 1976	14	Cervical mass biopsy	Superficial invasion, heterologous elements	RH, BSO, LND, upper vaginectomy, CT, RT	41 months	NED	n/a	NED after RH
Martinelli et al., 1988	55	polypoid mass biopsy	Superficial invasion	TAH, BSO, RT	4.5 years	NED	n/a	NED after TAH
Ostor and Fortune, 1980	Case A: 19 Case B: 19 Case B: 47	Case A: Cervical polyp Case B: cervical polyp	Unavailable	Case A: Polyp excision Case B: Hysterectomy	Case A: 14 years Case B: 5 months	Case A: Endometrium after 11 years Case B: NED	Case A: TAH Case B: n/a	Cases A & B: NED after hysterectomy
Zaloudek and Norris, 1981	Case A: 15yo Case B: 15yo	Cases A & B: Cervical mass biopsy	Case A: Unavailable Case B: No invasion	Case A: Trachelectomy Case B: Local excision	Case A: 6 yrs Case B: 4 yrs	Case A: NED Case B: NED	n/a	Case A: NED Case B: NED, pregnancy
Edinger et al., 1982	17	ECC, polypectomy	Unavailable	RT, TAH, BSO	56 months	NED	n/a	NED after TAH/BSO and RT
Chen, 1985	11	Cervical mass biopsy	Heterologous elements, no invasion	RH, partial vaginectomy, LND	4.5 years	NED	n/a	NED after RH
Gal et al., 1988	14	D&C	Unavailable	CT, RT, TAH, BSO	5 months	Recurrence in pelvis, vagina NED	Chemotherapy	Died of disease, 14 months after recurrence
Gast et al., 1987	15	D&C, polypectomy	Heterologous elements, no invasion	RAH	4 years	NED	n/a	Chest xray and pap smear, NED after hysterectomy
Clement and Scully, 1990	Case A: 17 Case B: 14 Case C: 23 Case D: 45	Cervical mass biopsy	Case A: Adenocarcinoma, not evaluable for invasion Case B: Adenocarcinoma, not evaluable for invasion Case C: Superficial invasion and epithelial atypia Case D: Superficial invasion and epithelial atypia No invasion	Case A: Local excision Case B: Local excision Case C: Local excision Case D: RH, BSO, RT, CT	Case A: recurrence after 8 years Case B: recurrence after 3 years Case C: not reported Case D: lost to follow up 7 years	Case A: Endometrium Case B: Endometrium Case C: Not reported Case D: Lost to follow up	Case A: Cone biopsy, dilation and curettage Case B: D&C Case C: Not reported Case D: Lost to follow up	Case A: NED for 11.5 yrs after Case B: Lost to follow up Case C: Lost to follow up Case D: Died of other causes
Kerner, 1993	30	D&C, cervical polyp excision	No invasion	TAH, BSO	7 years	NED	n/a	NED after hysterectomy
Zichella et al., 1994	43	D&C	No invasion	TAH, BSO	Lost to follow up	Lost to follow up	Lost to follow up	Lost to follow up
Jones and Lefkowitz, 1995	Case A: 67 Case B: 30 Case C: 14 Case D: 13	Case A: Polypoid mass in vagina Case B: Recurrent cervical polyp Case C: Vaginal bleeding Case D: Vaginal bleeding	Case A: No invasion Case B: No invasion Case C: Superficial Invasion Case D: No invasion	Case A: TAH, BSO Case B: TAH, BSO, CT Case C: TAH Case D: TAH	Case A: 3.5 years Case B: 2.5 years Case C: 18.8 years Case D: 2 years	Case A: NED Case B: NED Case C: NED Case D: NED	Case A: n/a Case B: n/a Case C: n/a Case D: n/a	Case A: NED after hysterectomy Case B: NED after hysterectomy Case C: NED after hysterectomy Case D: NED after hysterectomy
Feroze et al., 1997	18	Abdominal mass Biopsy	No invasion	RH	3.5 years	NED	n/a	NED after radical hysterectomy Chest xray, TVUS, pap smear
Ramos et al., 2002	25	D&C	Heterologous elements, no invasion	TAH, BSO	2 years	NED	n/a	NED after hysterectomy
Manoharan et al., 2007	Case A: 26 Case B: 43	Case A: HSC, polypectomy Case B: HSC, polypectomy	Case A: No invasion, suspicion for L.renal vessel lymphadenopathy, negative pathology Case B: No invasion Heterologous elements	Case A: VH, LND Case B: TAH	Case A: 3 years Case B: unclear time frame	Case A: NED Case B: NED	Case A: n/a Case B: n/a	Case A: NED after hysterectomy Case B: NED after hysterectomy
Kanayama et al., 2017	15	Cervical mass biopsy	No invasion	TAH, BSO, LND, omentectomy Simple excision	10 months	NED	n/a	NED after hysterectomy, BSO
Buyykurt et al., 2010	14	Exam under anesthesia, simple excision	No invasion	Simple excision	15 months	NED	n/a	NED after simple excision

(continued on next page)

Table 1 (continued)

Author	Age (yo)	Diagnosis or Presentation	Available pathology	Treatment	Follow Up	Recurrence	Treatment if recurrence	Surveillance (if available) and outcome
Fleming et al., 2009	10	Cervical mass biopsy, HSC, polypectomy, D&C	Superficial invasion	RH, LND, upper vaginectomy	18 months	NED	n/a	6 months pelvic/abdominal MRI, physical exam
Kanayama et al., 2017	28	Cervical mass biopsy	Heterologous elements	CKC	32 months	Cervix and vagina, 3 months NED	Transcervical resection	NED after hysterectomy NED after transcervical resection, pregnancy MRI, US, physical exam
Shinnick et al., 2017	14	Bulging vaginal mass, HSC, D&C	No invasion	CKC	6 months		n/a	

NED: no evidence of disease, BSO: bilateral salpingo-oophorectomy, RH: radical hysterectomy, CT: chemotherapy, RT: radiation therapy, TVUS: transvaginal ultrasound, n/a: not applicable, VH: vaginal hysterectomy, CKC: cold knife cone, HSC: hysteroscopy, D&C: dilation and curettage, ECC: endocervical curettage.

3. Discussion

Cervical Mullerian adenosarcomas are a rare form of malignancy with limited information regarding their management, with historic precedent primarily involving hysterectomy for reproductively aged women. This presents a management dilemma as low grade cervical adenosarcomas typically present in adolescents who may desire fertility preservation.

A literature review of all known cases with low grade cervical Mullerian adenosarcoma was performed and summarized. A total of 29 cases were collected and reviewed.

The patients identified ranged from ages 10 to 67 with the median age of 24.5. Of the total 29 cases reviewed, twenty were noted to have been treated with hysterectomy, with only one having recurrence of disease (Martinelli et al., 1988; Edinger et al., 1982; Chen, 1985).

The patient with recurrent disease was a 14-year-old with a large vaginal mass 12 × 8 × 8 cm occluding her urethra diagnosed as Mullerian adenosarcoma of the cervix with heterologous elements. The patient received 3 cycles of preoperative vincristine, Adriamycin, cyclophosphamide, and Actinomycin D and then underwent pelvic and abdominal radiation. She underwent a hysterectomy and bilateral salpingo-oophorectomy, with negative resection margins. Vaginal recurrence occurred five months later with diagnosis of a 10 cm mass and subsequent demise (Gal et al., 1988). This case is unique in its aggressive and extensive nature of disease at the time of diagnosis and management, despite low grade pathology. This may identify this case as an outlier.

A total of nine patients underwent initial conservative management. Six cases were treated with local resection (Ostor and Fortune, 1980; Clement and Scully, 1990; Zaloudek and Norris, 1981; Buyykurt et al., 2010), one case underwent a trachelectomy (Zaloudek and Norris, 1981), and two cases underwent a cold knife cone as initial treatment (Kanayama et al., 2017; Shinnick et al., 2017).

Of those undergoing local resection, three had documented recurrences. One of these subjects underwent a hysterectomy (Ostor and Fortune, 1980), another was treated with a repeat dilation and curettage (Clement and Scully, 1990), and another underwent a cold knife cone (Clement and Scully, 1990). The patient who initially underwent a trachelectomy had no recurrence (Zaloudek and Norris, 1981). One of the patients who initially underwent a cold knife cone recurred, and was treated with a subsequent resection and has had a successful pregnancy (Kanayama et al., 2017). The other patient that underwent a cold knife cone initially is currently undergoing surveillance with biannual MRI, transvaginal US, and serial clinical exams (Shinnick et al., 2017). These cases summarize how varied the treatment has been for this diagnosis, the majority of which have been hysterectomy for reproductively aged women.

We present the case of a patient with low grade primary cervical adenosarcoma who underwent a cervical wedge resection and polypectomy, and who has remained disease free for four years since diagnosis. This is the first case to have had no evidence of recurrence with the most minimally invasive resection approach for this time frame. We have recommended the patient undergo continued surveillance visits, with specific counseling regarding menstrual disturbances as abnormal bleeding is often the initial symptom of recurrence. There are no formal recommendations by any governing body regarding surveillance timing or interventions. Recurrence has been documented as late as 11 years after diagnosis (Ostor and Fortune, 1980). Surveillance for that minimum of time can be considered. An initial assessment with dilation and curettage or local excision for a visible lesion would be reasonable to evaluate for recurrence, as many have been documented as masses. Although more aggressive surgical management has been undertaken in the past, recurrences appear to be local. Resection is a reasonable option, particularly in cases like ours where the presentation is a small polypoid mass amenable to torsion or local resection. Cold knife cones have also been identified to be successful, however, we present an even

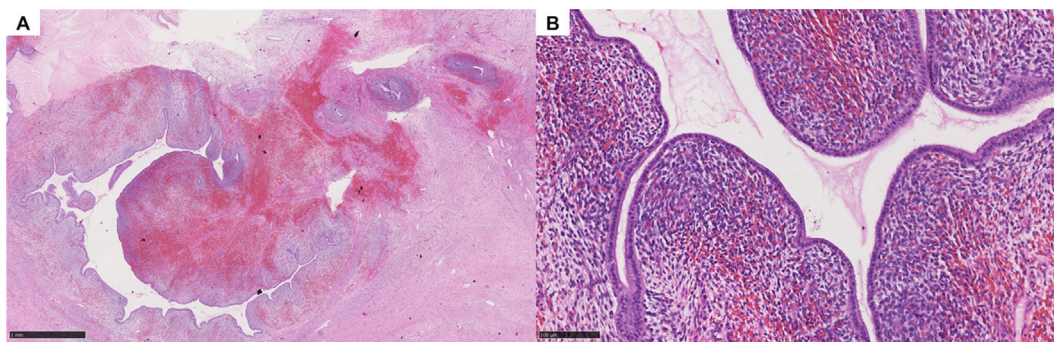


Fig. 1. Adenosarcoma. A. Biphasic lesion with a Phyllodes like pattern with hypercellular periglandular condensation. B. Hypercellular pericellular condensation with mild to moderate atypia, mitotic activity and benign overlying glandular epithelium. (Hematoxylin-eosin, original magnifications X25 [A], X200 [B]).

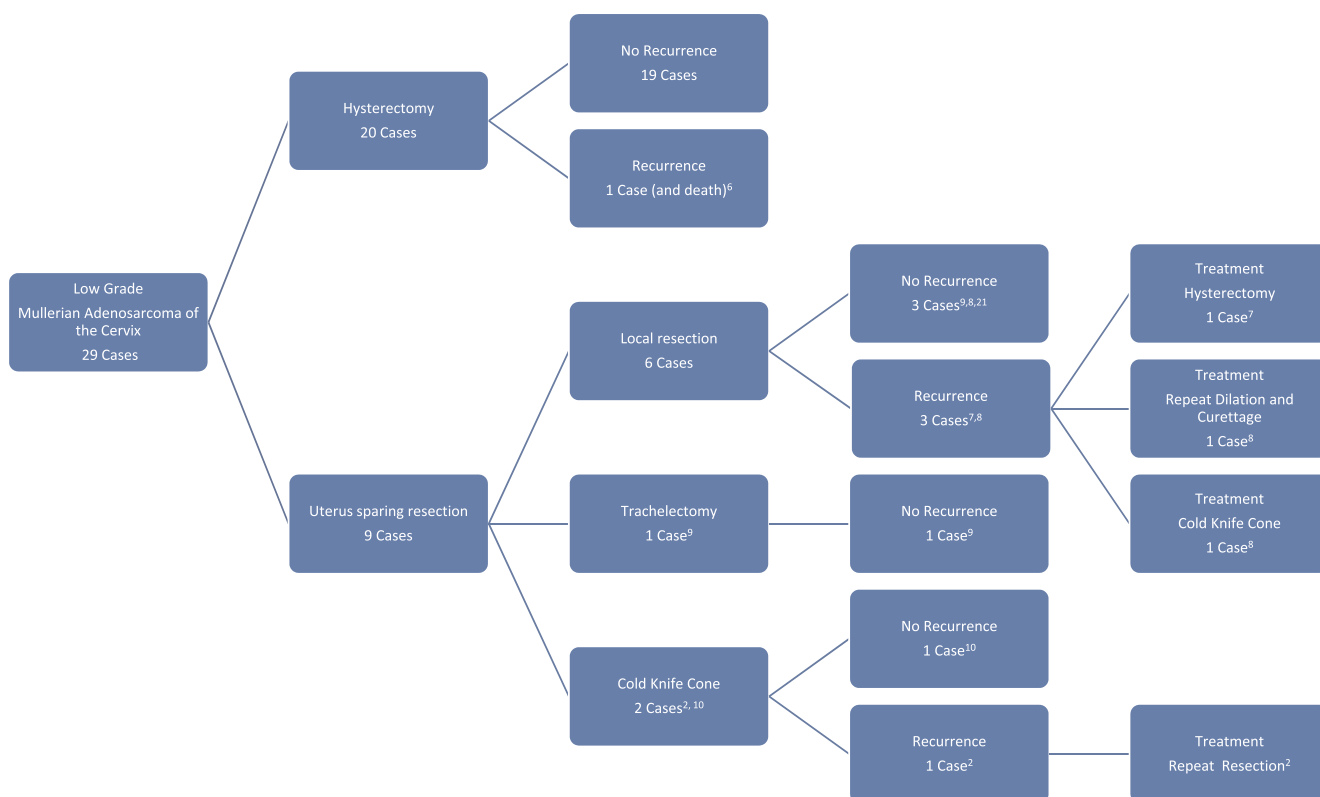

Fig. 2. Flow Diagram Low Grade Mullerian Adenosarcoma of the Cervix Summary of Cases Reviewed.

more minimally invasive resection approach with similar results, which may lead to a better reproductive outcome for patients desiring fertility preservation.

Routine imaging does not appear critical to surveillance with some false positive results documented in our case, but may be a useful tool. Pathology expertise seems essential to ensure correct diagnosis and treatment options. Overall, this case report aims to discuss the possibility of offering more minimally invasive approaches for young women affected with a low grade rare tumor during their reproductive years.

Author contribution

Nicole Lugo Santiago

Assisted in drafting case report, performed literature review
Nlugos2@uic.edu

John Groth

Reviewed case report, performed and provided pathology images and captions

Nuzhath Hussain

Reviewed case report, performed initial procedure that led to diagnosis

Rajul Kothari

Edited and assisted in drafting case report, performed literature review, provided oncologic care to patient

Conflict of Interest

The authors declare that there are no conflicts of interest.

Acknowledgements

University of Illinois at Chicago, Obstetrics and Gynecology Department.

References

- Roth, L.M., Pride, G.L., Sharma, H.M., 1976. Mullerian adenocarcinoma of the uterine cervix with heterologous elements. *Cancer* 37, 1725.
- Kanayama, S., Nakamura, M., Oi, H., Sugimoto, S., Sasaki, Y., Uchiyama, T., Ohbayashi, C., Kobayashi, H., 2017. Case report of successful childbearing after conservative surgery for cervical Mullerian adenocarcinoma. *Case Rep. Obstet. Gynecol* Article ID 4187416.
- Bagga, R., Keenanasseril, A., Srinivasan, R., Dey, P., Gainder, S., Chandra, S., Kaur, L., Patel, F., 2010. Adenocarcinoma of the uterine cervix with heterologous elements: a case report and review of the literature. *Arch. Gynecol. Obstet.* 281, 669–675.
- Andrade, L.A.L.A., Derchain, S.F.M., Vial, J.S., Alvarenga, M., 1992. Mullerian adenocarcinoma of the uterus in adolescents. *Int. J. Gynecol. Obstet.* 38, 119–123.
- Fleming, N., Hopkins, L., de Nanassy, J., Senterman, M., Black, A., 2009. Mullerian adenocarcinoma of the cervix in a 10 year old girl: a case report and review of the literature. *J. Pediatr. Adolesc. Gynecol.* 22e45–e51.
- Gal, D., Kerner, H., Beck, D., Peretz, B.A., Eyal, A., Paldi, E., 1988. Mullerian adenocarcinoma of the uterine cervix. *Gynecol. Oncol.* 31, 445.
- Ostor, A.G., Fortune, D.W., 1980. Benign and low grade variants of mixed Mullerian tumor of the uterus. *Histopathol* 4, 369.
- Clement, P.B., Scully, R.E., 1990. Mullerian adenocarcinoma of the uterus: a clinicopathologic analysis of 100 cases with a review of the literature. *Hum. Pathol.* 21, 363.
- Zaloudek, C.J., Norris, H.J., 1981. Adenofibroma and adenocarcinoma of the uterus: a clinicopathologic study of 35 cases. *Cancer* 48, 354–366.
- Shinnick, J., Kumar, N., Beffa, L., Miller, K., Friedman, M., Kalife, E., DiSilvestro, P., Matthews, C., 2017. Management of low-grade cervical Mullerian adenocarcinoma in a 14 year old girl. *J. Pediatr. Adolesc. Gynecol.* 30 (6), 652–654.
- Martinelli, G., Pileri, S., Bazzocchi, F., Serra, L., 1988. Mullerian adenocarcinoma of the uterus: a report of 5 cases. *Tumori* 66, 499.
- Edinger Jr, D.D., Safaii, H., Tak, W., Anderson, B., Watring, W.G., 1982. Cervical mullerian adenocarcinoma: case report. *Eur. J. Gynaecol. Oncol.* 3, 69–73.
- Chen, K.T., 1985. Rhabdomyosarcomatous uterine adenocarcinoma. *Znt. J. Gynecol. Pathol.* 4, 146–152.
- Gast, M.J., Radkins, L.V., Jacobs, A.J., Gersell, D., 1987. Mullerian adenocarcinoma of the cervix with heterologous elements: diagnostic and therapeutic approach. *Gynecol. Oncol.* 32, 381.
- Kerner, H., 1993. Lichtig: Mullerian adenocarcinoma presenting as cervical polyps: a report of seven cases and review of the literature". *Obstet. Gynecol.* 81 (5), 655–659.
- Zichella, L., Perrone, G., De Falco, V., Pelle, R., Eleuteri Serpieri, D., 1994. Adenocarcinoma mesodermico eterologo dell'endocervice: descrizione di un caso clinico. *Minerva Ginecol.* 46, 511–514.
- Jones, M.W., Lefkowitz, M., 1995. Adenocarcinoma of the uterine cervix: a clinicopathological study of 12 cases. *Int. J. Gynecol. Pathol.* 14, 223–229.
- Feroze, M., Aravindan, K.P., Malini, T., 1997. Mullerian adenocarcinoma of the uterine cervix. *Indian J. Cancer* 34, 68–72.
- Ramos, P., Ruiz, A., Carabias, E., Piñero, I., Garzon, A., Alvarez, I., 2002. Müllerian adenocarcinoma of the cervix with heterologous elements: report of a case and review of the literature. *Gynecol. Oncol.* 84, 161–166.
- Manoharan, M., Azmi, M.A., Soosay, G., Mould, T., Weekes, A.R., 2007. Mullerian adenocarcinoma of uterine cervix: report of three cases and review of literature. *Gynecol. Oncol.* 105, 256–260.
- Buyyukturk, S., Guzel, A.B., Gumurdulu, D., Vardar, M.A., Zeren, H., Sucu, M., 2010. Mullerian adenocarcinoma of the uterine cervix in an adolescent girl. *J. Pediatr. Adolesc. Gynecol.* 23, e13–e15.