



Case report

Recurrent rheumatoid pleural effusions complicated by *Mycobacterium heckeshornense* infection

Daniel Howell^{a,*}, Benjamin T. Galen^b

^a Icahn School of Medicine, Department of Medicine, Division of Pulmonary, Critical Care and Sleep Medicine, USA

^b Albert Einstein College of Medicine, Montefiore Medical Center, Department of Internal Medicine, Division of Hospital Medicine, USA



ABSTRACT

A 41-year-old man with rheumatoid arthritis (RA) presented with worsening dyspnea and deconditioning. He had recently been treated with adalimumab for rheumatoid pleural effusions but developed non-tuberculous mycobacterial pleurisy due to *Mycobacterium heckeshornense*. Despite therapy with appropriate anti-mycobacterial agents, he ultimately required video assisted thoracoscopy for decortication. While *Mycobacterium heckeshornense* has been reported to cause infection in multiple sites including the lung, this is the first case to our knowledge of infection confined to the pleural space. Rheumatoid pleural effusions can be complex and difficult to treat, especially when complicated by mycobacterial infection.

1. Introduction

This case highlights the challenge of treating pleural disease in rheumatoid arthritis (RA) and the further challenge of treating ongoing pleurisy complicated by nontuberculous mycobacterial infection (NTM).

2. Case report

A 41-year-old man presented to the hospital with dyspnea. He had a history of RA and had been well controlled on hydroxychloroquine until 10 months prior. The development of recurrent exudative pleural effusions and weakness prompted a short trial of adalimumab with minimal benefit. Multiple thoracenteses were performed over 6 months to manage persistent hydropneumothorax on the right and loculated pleural effusion on the left. While microscopy of pleural fluid was negative for acid-fast organisms, *Mycobacterium heckeshornense* grew in pleural fluid culture and was identified by 16S rRNA and *rpoB* gene sequencing (performed at National Jewish Health, USA). A pleural biopsy at the time showed chronic inflammation without granulomas. Multiple sputum specimens were negative on microscopy for acid-fast organisms and no mycobacteria grew in culture. The patient was treated with amikacin, rifampin, azithromycin, and ethambutol after susceptibility testing with Middlebrook 7K11 agar. After one month, he was discharged to a nursing facility on rifampin, azithromycin and ethambutol.

Two months later, he was re-admitted with dyspnea. He appeared

markedly cachectic and lung exam revealed dullness to percussion and reduced air entry at both lung bases. Serum albumin was 2.9 g/dL (3.7–5 g/dL) and Rheumatoid Factor (RF) was significantly elevated to 957 IU/ml (0–22 IU/ml). Serum antibodies to CCP and Ro were also positive. Chest computed tomography (CT) showed right-sided hydro-pneumothorax with right lung entrapment, round atelectasis and a left-sided pleural effusion (shown in Figs. 1–3). A large bore chest tube was placed. Pleural fluid analysis showed 560,000 RBCs, Protein 6.1 g/dL, LDH 2456 U/l, Cholesterol 67 mg/dl, pH 8.0 and glucose 2 mg/dl.

Despite chest tube drainage and intrapleural fibrinolytic therapy, repeat chest CT showed persistent left-sided loculated pleural effusion and lung entrapment. Given the patient's poor functional status, no further surgical management was undertaken and the patient was discharged back to a nursing facility. One month later he was admitted after developing acute respiratory failure due to superimposed bacterial pneumonia. When he failed to improve on broad spectrum antibiotics, he underwent video assisted thoracoscopy for decortication and drainage of the left pleural effusion. Mycobacteria were present on microscopy of pleural fluid however culture of the fluid was negative. Levofloxacin was added to his regimen and he was discharged. Over the next year his functional and nutritional status improved without further hospitalization and he remains on treatment with rifampin, azithromycin and ethambutol after having completed 9 months of treatment with levofloxacin.

* Corresponding author. Icahn School of Medicine, Department of Medicine, Division of Pulmonary Critical Care and Sleep Medicine, Annenberg 5, One Gustave L. Levy Pl, New York, NY 10029, USA.

E-mail address: Daniel.howell@mountsinai.org (D. Howell).

<https://doi.org/10.1016/j.rmcr.2018.10.021>

Received 12 October 2018; Accepted 23 October 2018

2213-0071/ © 2018 The Authors. Published by Elsevier Ltd. This is an open access article under the CC BY-NC-ND license (<http://creativecommons.org/licenses/by-nc-nd/4.0/>).

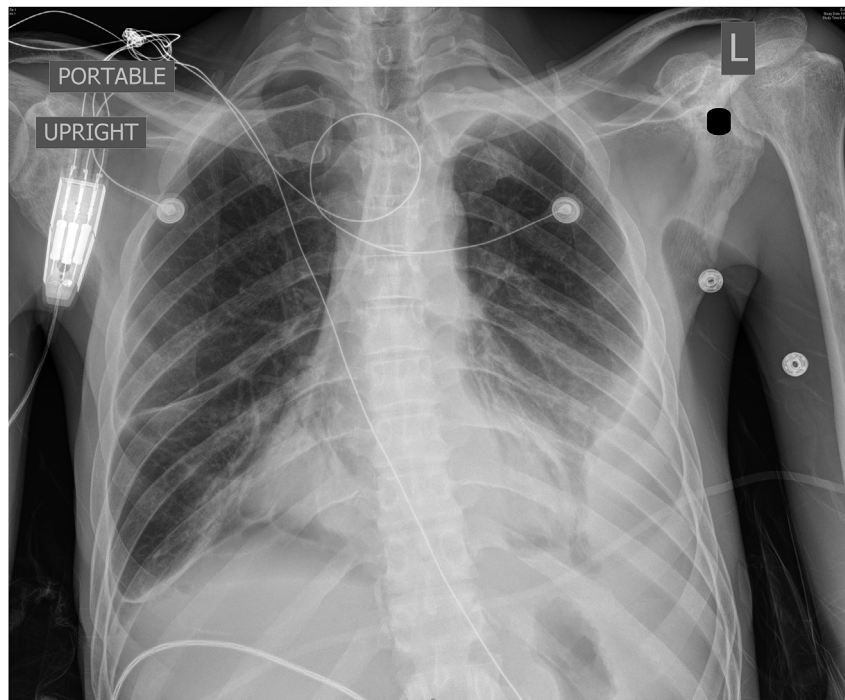


Fig. 1. Chest x-ray.

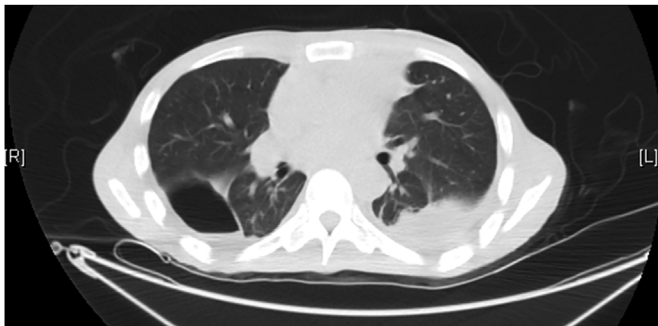


Fig. 2. CT chest axial.

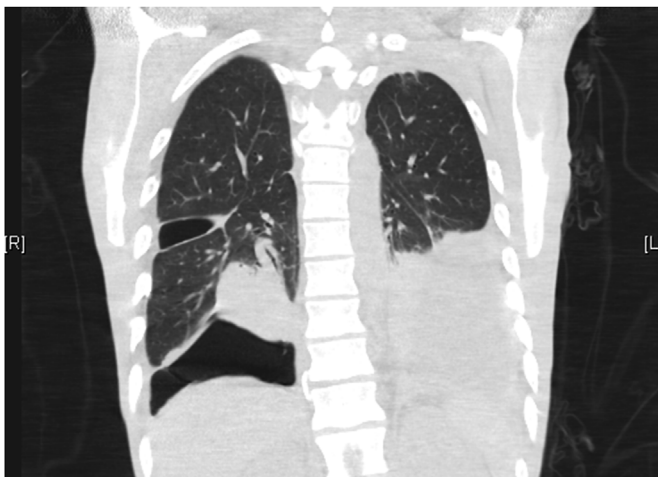


Fig. 3. CT chest coronal.

3. Discussion

Mycobacterium heckeshornense is a rare NTM that can cause disease in multiple sites [1]. It was first identified in 2000 in a patient with severe cavitary pulmonary disease [2]. It is similar to *Mycobacterium xenopi* but has a distinct 16S rRNA and 16S-23S spacer gene sequence and has been mistaken for *M. xenopi* using DNA-DNA hybridization methods [3].

M. heckeshornense is acid fast, grows slowly at temperatures between 37 and 45 degrees Celsius and is negative for arylsulfatase, nicotinamidase and pyrazinamide (this distinguishes it from *M. xenopi*, which has a positive reaction) [2]. To date, *M. heckeshornense* has been reported to cause infection in multiple sites, including cavitary pneumonia and pneumonia with pneumothorax [2–5]. Extrapulmonary cases have included tenosynovitis [6], lumbar spondylodiscitis [7,8], lymphadenitis [9], disseminated infection [10] and peritoneal infection [11]. In all but one case (in which a reverse hybridization line probe was used [11]), *M. heckeshornense* has been identified by sequencing the 16S rRNA gene.

In some cases *M. heckeshornense* has been reported to be resistant to isoniazid, rifampin and amikacin [1]. No resistance to ciprofloxacin, clarithromycin or streptomycin has been noted. Treatment, which is usually prolonged, has usually included combination therapy involving rifampin, isoniazid, ethambutol and pyrazinamide in addition to a fluoroquinolone. Treatment with surgical resection alone was used for the cases of tenosynovitis and lymphadenitis [6,12]. Failure of antimicrobial therapy was reported in two cases of pulmonary disease which eventually required resection [2,5]. While pleural involvement of *M. heckeshornense* infection has complicated prior cases of pulmonary infection, our patient had serial negative sputum cultures. This may, therefore, be the first reported case of non-tuberculous mycobacterial pleurisy due to *Mycobacterium heckeshornense*. *M. heckeshornense* infection complicating treatment with biologic therapy has also been described in a patient with rheumatoid arthritis, although in that case the patient developed spondylodiscitis while on etanercept [7]. This case highlights the challenges and complications of treating rheumatoid pleural effusions, particularly when further complicated by NTM infection.

Author contribution

All authors contributed to the preparation of this manuscript.

Declarations of interest

None.

Acknowledgements

The authors thank James Brust, MD, Albert Einstein College of Medicine and Seth Koenig, MD, Hofstra Northwell School of Medicine, for their assistance in revising this manuscript. They were not compensated. We also thank the patient for his permission to publish this information.

Appendix A. Supplementary data

Supplementary data to this article can be found online at <https://doi.org/10.1016/j.rmcr.2018.10.021>.

References

- [1] W.W. Chan, M.C. Murray, P. Tang, M.G. Romney, *Mycobacterium heckeshornense* peritonitis in a peritoneal dialysis patient: a case report and review of the literature, *Clin. Microbiol. Infect.* 17 (8) (2011) 1262–1264.
- [2] A. Roth, U. Reischl, N. Schönfeld, et al., *Mycobacterium heckeshornense* sp. nov., A new pathogenic slowly growing *Mycobacterium* sp. Causing cavitary lung disease in an immunocompetent patient, *J. Clin. Microbiol.* 38 (11) (2000) 4102–4107.
- [3] K. Morimoto, Y. Kazumi, S. Maeda, et al., *Mycobacterium heckeshornense* lung infection that was diagnosed as *Mycobacterium xenopi* disease by DNA-DNA hybridization (DDH), *Intern. Med.* 50 (11) (2011) 1251–1253.
- [4] R. van Hest, A. van der Zanden, M. Boeree, et al., *Mycobacterium heckeshornense* infection in an immunocompetent patient and identification by 16S rRNA sequence analysis of culture material and a histopathology tissue specimen, *J. Clin. Microbiol.* 42 (9) (2004) 4386–4389.
- [5] F. Kurosaki, T. Yoshimoto, M. Nakayama, M. Bando, K. Hagiwara, Pulmonary *Mycobacterium heckeshornense* infection in a healthy woman, *J. Infect. Chemother.* 24 (6) (2018) 483–486.
- [6] S. Godreuil, H. Marchandin, D. Terru, et al., *Mycobacterium heckeshornense* tenosynovitis, *Scand. J. Infect. Dis.* 38 (11–12) (2006) 1098–1101.
- [7] A.A. Elyousfi, J.R. Leiter, M.J. Goytan, D.B. Robinson, *Mycobacterium heckeshornense* lumbar spondylodiskitis in a patient with rheumatoid arthritis receiving etanercept treatment, *J. Rheumatol.* 36 (9) (2009) 2130–2131.
- [8] N. Douiri, N. Lefebvre, Y. Hansmann, M. Partisani, F. Schramm, Relapsing Pott disease caused by *Mycobacterium heckeshornense* in a well-controlled HIV-infected patient, *Med. Maladies Infect.* 48 (2) (2018) 157.
- [9] S.J. McBride, S.L. Taylor, S.K. Pandey, D.J. Holland, First case of *Mycobacterium heckeshornense* lymphadenitis, *J. Clin. Microbiol.* 47 (1) (2009) 268–270.
- [10] R.A. Ahmed, L.J. Miedzinski, C. Shandro, *Mycobacterium heckeshornense* infection in HIV-infected patient, *Emerg. Infect. Dis.* 16 (11) (2010) 1801–1803.
- [11] F. Jauréguy, V. Ioos, P. Marzouk, et al., *Mycobacterium heckeshornense*: an emerging pathogen responsible for a recurrent lung infection, *J. Infect.* 54 (1) (2007) e33–35.
- [12] Y. Kazumi, I. Sugawara, M. Wada, K. Kimura, H. Itono, [Microbiologically identified isolates of *Mycobacterium heckeshornense* in two patients], *Kekkaku* 81 (10) (2006) 603–607.