



# Humerus Diaphyseal Stress Fracture in a Teenage Tennis Athlete: Case Report

## *Fratura por estresse diafisária do úmero em atleta de tênis adolescente: Relato de caso*

Márcio Schiefer<sup>1,5</sup> <sup>id</sup> Francisco Nanci<sup>2</sup> <sup>id</sup> Luiz Eduardo Abílio<sup>3</sup> <sup>id</sup> Yonder Archanjo Ching San Junior<sup>4</sup> <sup>id</sup> Geraldo Motta Filho<sup>5</sup> <sup>id</sup>

<sup>1</sup> Department of Orthopedics, School of Medicine, Federal University of Rio de Janeiro, Rio de Janeiro, RJ, Brazil

<sup>2</sup> Hospital Central da Polícia Militar, Rio de Janeiro, RJ, Brazil

<sup>3</sup> Shoulder and Elbow Fellow, National Institute of Traumatology and Orthopedics, Rio de Janeiro, RJ, Brazil

<sup>4</sup> Universidade Federal do Estado do Rio de Janeiro, Rio de Janeiro, Brazil

<sup>5</sup> Center of Shoulder and Elbow Surgery, National Institute of Traumatology and Orthopedics, Rio de Janeiro, RJ, Brazil

Address for correspondence Márcio Schiefer, MD, MSc, PhD, Rua Nóbrega, 62/602, Niterói, RJ, 24220-320, Brazil (e-mail: marcioschiefer@hotmail.com).

Rev Bras Ortop 2022;57(1):175–179.

### Abstract

A teenage male tennis player had chronic pain in his dominant arm during tennis practice. Magnetic resonance imaging (MRI) suggested humerus diaphyseal stress injury. After 4 weeks, he became asymptomatic and resumed playing. However, pain recurred after 3 days. A new MRI revealed a diaphyseal undisplaced humerus fracture and significant bone marrow edema. The patient remained in rest for 4 weeks. After that, strengthening exercises were introduced and return to training was allowed after 12 weeks. Even if asymptomatic, we suggest that these patients should not return to play before 12 weeks, depending on the physical exam and imaging findings.

### Keywords

- ▶ fractures, stress
- ▶ humeral fractures
- ▶ humerus
- ▶ tennis/injuries

### Resumo

Um tenista adolescente teve dores crônicas no braço dominante durante o treino de tênis. A ressonância magnética (RM) sugeriu lesão por estresse diafisária do úmero. Depois de 4 semanas, ele se tornou assintomático e voltou a jogar. No entanto, a dor recorreu após 3 dias. A nova RM revelou uma fratura diafisária não desviada do úmero e edema significativo da medula óssea. O paciente ficou em repouso por 4 semanas. Depois disso, exercícios de fortalecimento foram introduzidos e o retorno aos treinamentos foi permitido após 12 semanas. Mesmo que assintomáticos, sugerimos que esses pacientes não voltem a jogar antes das 12 semanas, dependendo dos exames físicos e dos achados por imagem.

### Palavras-chave

- ▶ fraturas de estresse
- ▶ fraturas do úmero
- ▶ úmero
- ▶ tênis/lesões

*The present work was performed at the National Institute of Traumatology and Orthopedics (INTO).*

received  
June 3, 2020  
accepted  
September 17, 2020  
published online  
April 19, 2021

DOI <https://doi.org/10.1055/s-0040-1721837>.  
ISSN 0102-3616.

© 2021. Sociedade Brasileira de Ortopedia e Traumatologia. All rights reserved.

This is an open access article published by Thieme under the terms of the Creative Commons Attribution-NonDerivative-NonCommercial-License, permitting copying and reproduction so long as the original work is given appropriate credit. Contents may not be used for commercial purposes, or adapted, remixed, transformed or built upon. (<https://creativecommons.org/licenses/by-nc-nd/4.0/>)

Thieme Revinter Publicações Ltda., Rua do Matoso 170, Rio de Janeiro, RJ, CEP 20270-135, Brazil

## Introduction

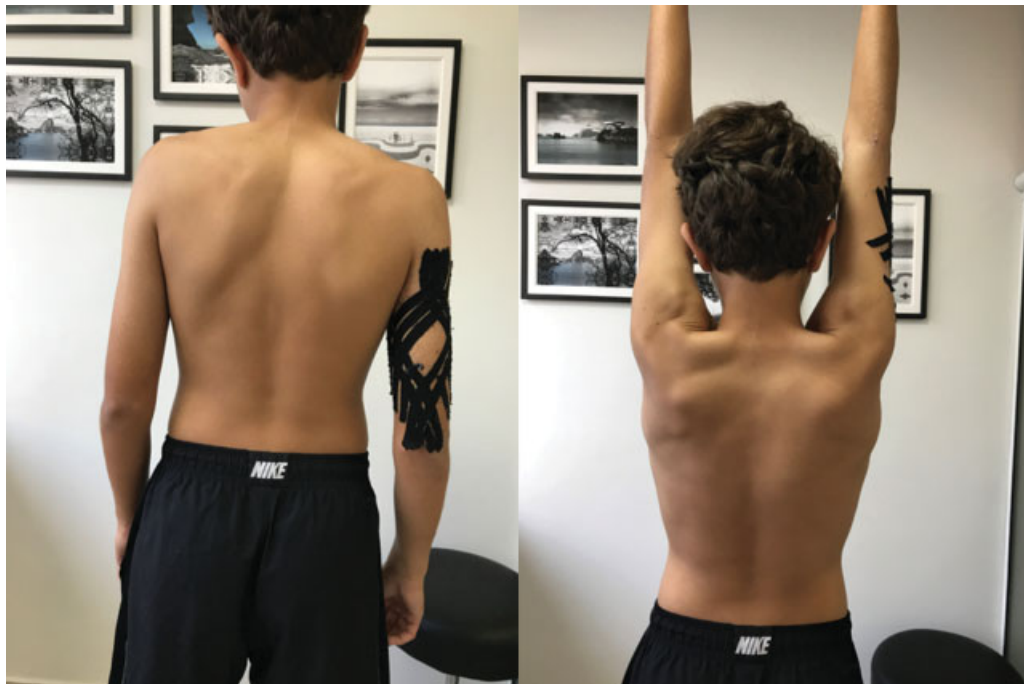Stress fractures are common overuse injuries among athletes and represent a major disruption to training and competition.<sup>1</sup> They result from excessive, repetitive, submaximal loads on bones, causing an imbalance between bone resorption and formation. Osseous microdamage occurs as a result of daily activities and there is osteoclastic resorption of damaged bone followed by osteoblastic bone production, resulting in a balance of resorption and production.<sup>2</sup> High loads of physical activities, little time to rest, insufficient nutritional intake or a combination of those factors may lead to an imbalance between resorption and production with predominance of osteoclastic activity.<sup>3</sup> Upper limb stress fractures are far less common than those in the lower limbs, and have been described in upper limb-dominated sports, such as tennis or throwing activities.<sup>4-6</sup> Due to its low incidence, there are no large series published in the literature, presenting mostly case reports and small case series.<sup>1</sup>

Among upper limb stress fractures, diaphyseal humerus fractures are even rarer. Rizzone et al.<sup>4</sup> found only 1 case among 671 stress fractures in collegiate student athletes. Changstrom et al.<sup>5</sup> did not find any diaphyseal humerus fracture among 389 stress fractures in high school athletes. Based on the few case reports available, one can infer that those fractures predominate in two main age groups: adolescent athletes and healthy middle-aged athletes.<sup>7</sup> The high level of activity, which places a high degree of stress in an immature bone with inadequate muscular development, explains the stress fractures in adolescent athletes. Although the overall prevalence of stress fractures has been shown to be greater in women,<sup>4,5</sup> it seems that both genders are equally affected in upper extremity stress fractures,<sup>5</sup> includ-

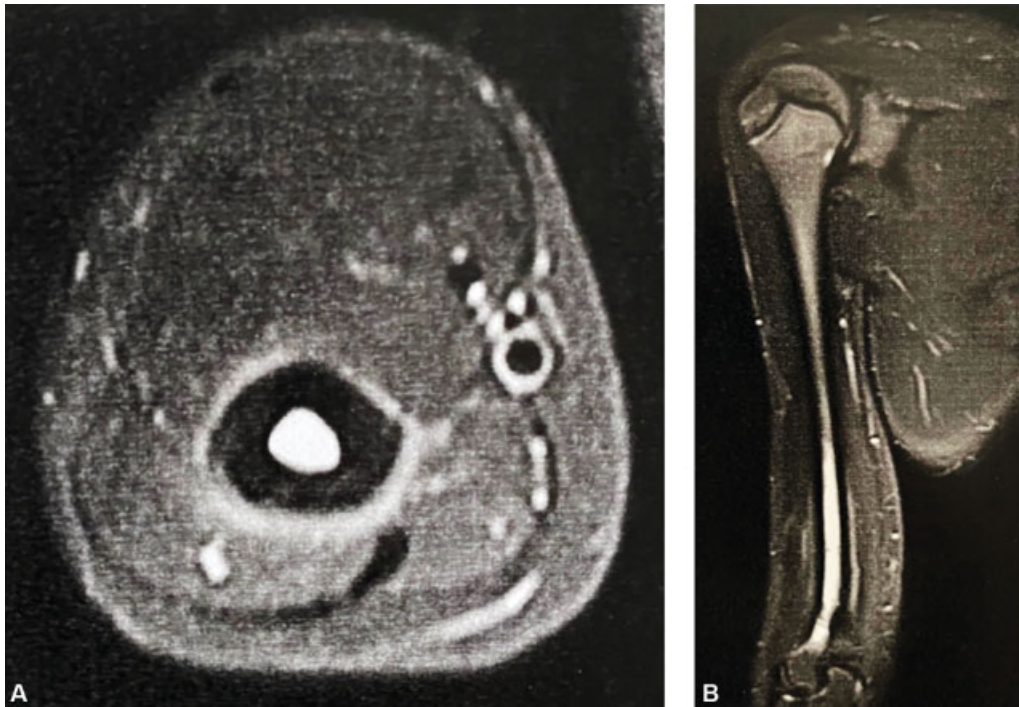
ing those related to tennis practice.<sup>3</sup> Physical examination signs include tenderness to palpation at the site of the stress.<sup>7</sup> Shoulder and elbow range of motion is typically full but pain may be present at the ends of motion.<sup>7</sup> Magnetic resonance imaging (MRI) is the main exam to identify early stress changes within the bone.<sup>2</sup> Due to the paucity of available cases in the literature, there is no consensus on how we should treat those patients, especially regarding how long they should keep away from training.

## Case Report

A 15-year-old male high school tennis player had chronic, progressive pain in his right dominant arm, especially after a long time training or competitions. The day before the consultation, however, he had to stop training due to sudden and severe pain in the arm. Physical examination revealed shoulder and elbow full range of motion and painful palpation of the middle arm (→**Fig. 1**). An MRI revealed massive stress reaction in humerus diaphysis (→**Fig. 2**). The patient interrupted training and started physiotherapy, with complete pain relief after a few days. After 4 weeks, he remained asymptomatic and a new MRI showed a huge regression of the bone edema. Despite medical recommendations of progressive return to sport with reduced training loads, he began heavy training in order to participate in his next scheduled competition. After 3 days of intensive training, pain recurred. Training was then interrupted and the patient returned to physiotherapy. A new MRI detected a diaphyseal undisplaced stress fracture in his right humerus (→**Fig. 3**). After a period of a few days, complete pain relief was achieved once more, but the athlete was only allowed to perform lower limb and core exercises. One month later, a



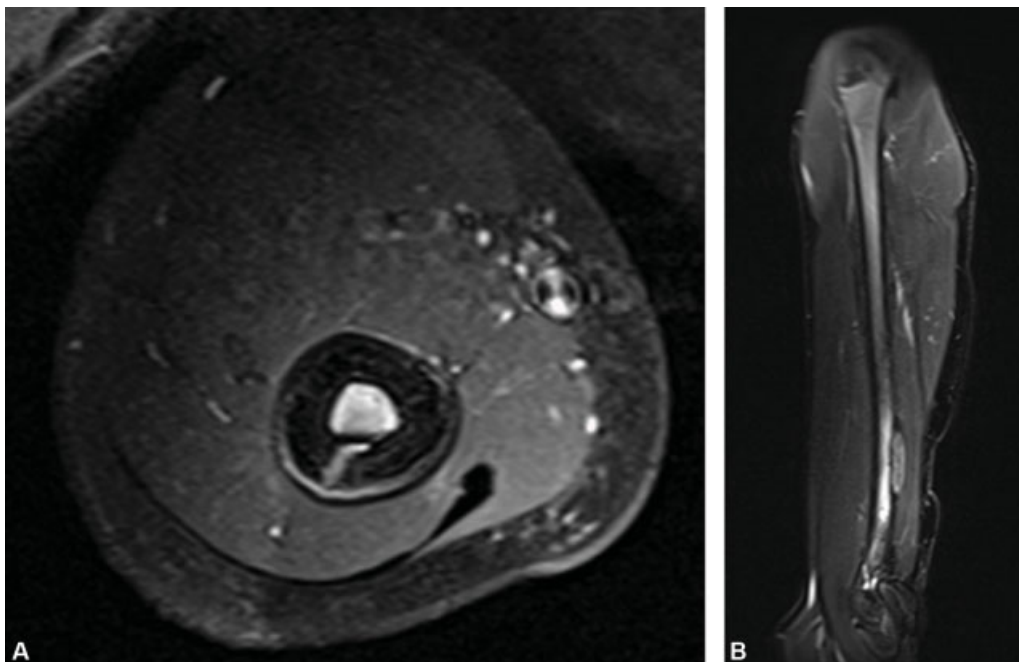
**Fig. 1** Clinical aspect of the patient, showing full elevation of the shoulder.



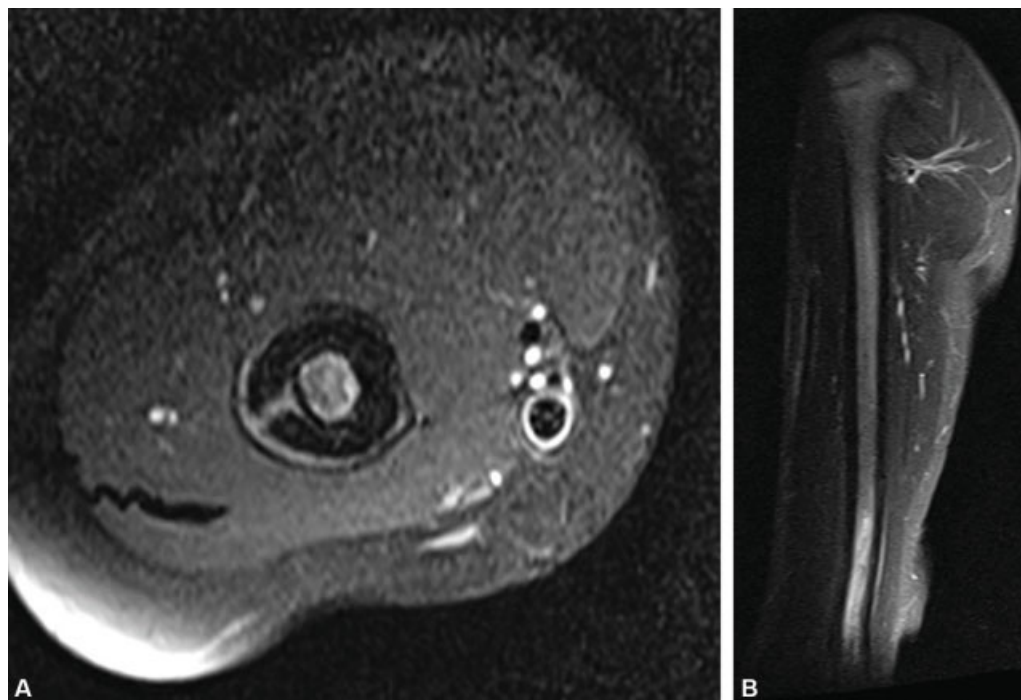
**Fig. 2** Axial (A) and coronal (B) fat-suppressed T2-weighted magnetic resonance imaging showing significant bone marrow and periosteal edema in the lower half of the humerus diaphysis.

new MRI revealed regression of the bone edema (►**Fig. 4**). Muscle strengthening was introduced, focused on biceps and triceps and preventing rotational movements of the arm. Besides, no racket work was allowed. After another month, a computed tomography (CT) scan showed periosteal callus formation (►**Fig. 5**). Muscle strengthening exercises were intensified and specific tennis gestures training was intro-

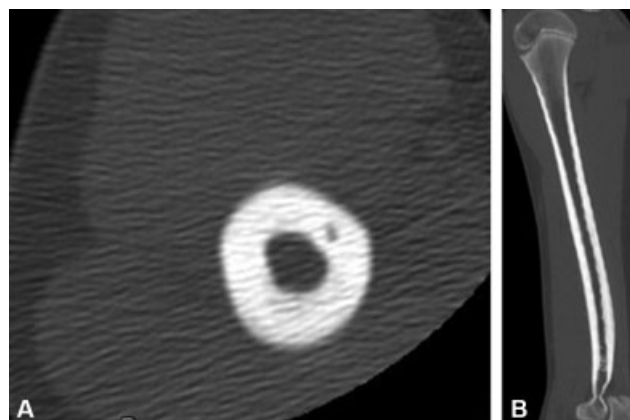
duced. Ten weeks after the recurrence of pain, the patient was suggested to resume training using soft balls and a lighter racket than his usual one. Two weeks after, a new MRI confirmed complete consolidation and residual bone edema (►**Fig. 6**), so that the athlete resumed training with regular balls and racket. Training loads were progressively increased and 2 months afterwards the athlete could



**Fig. 3** (A) Axial STIR magnetic resonance imaging revealing longitudinal fracture through the posterior cortex, which is thickened; endosteal and periosteal edema are also noticed. (B) Sagittal STIR MR image showing cortical thickening and bone marrow edema in distal humeral diaphysis.



**Fig. 4** Axial, fat-suppressed proton density-weighted (A) and STIR sagittal (B) magnetic resonance imaging depicting maintenance of posterior cortex thickening, linear fracture line and slight reduction in periosteal and endosteal edema.

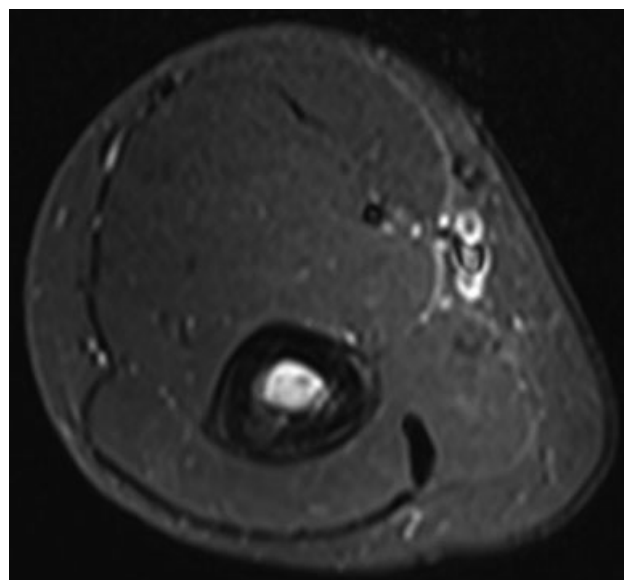


**Fig. 5** Axial (A) and sagittal CT (B) images showing fracture consolidation and persistent thickening of the posterior cortex.

compete. He remains asymptomatic after a 3-year follow-up period.

## Discussion

Stress fractures are not common in tennis players. Iwamoto et al.<sup>8</sup> studied 196 cases of stress fractures in more than ten thousand athletes and found that only 2,6% of all fractures occurred in tennis players. They also noted that only 1,4% of all symptomatic tennis players sustained stress fractures, none of which in the upper limbs. Maquirriain et al.<sup>3</sup> found a higher incidence of stress injuries in elite tennis players, comprising 12,9% of the 139 subjects. The higher rate reported in their paper may be due to the inclusion of all stress injuries rather than only stress fractures. Although



**Fig. 6** Axial, fat-suppressed proton density-weighted magnetic resonance imaging revealing residual bone marrow edema. The fracture line is no longer evident.

they showed that upper extremity stress injuries accounted for 22% of all injuries, none occurred in the humerus. Rizzone et al.<sup>4</sup> evaluated 671 collegiate student athletes with almost 12 thousand athlete-exposures (1 athlete participating in 1 practice or competition) and found that only 1,2% of all stress fractures occurred in tennis players, none of which in the upper extremity.

Teenage athletes seem to be at higher risk of stress fractures. Maquirriain et al.<sup>3</sup> found statistically a significant higher incidence of stress fractures in junior elite tennis

players than in professional players (20,3 versus. 7,5%). Milgrom et al.<sup>9</sup> reported that with each year of increase in age from 17 to 26 years, the stress fracture risk for any site decreased by 28%. Adolescent competitive tennis players usually engage in heavy, professional participation and have long daily training sessions from an early age. Many of them are submitted to adult training volume, which they are not prepared for. Growth spurt leads to fast bone growth, but muscles do not develop so fast.<sup>7</sup> Torsional stress is believed to be the main mechanism of stress fractures in tennis players,<sup>3</sup> as the powerful swinging action transmits considerable force across the bones of the upper limb. It has been suggested that the compressive forces of the biceps and triceps across the humeral shaft are protective against the rotational forces during tennis practice.<sup>7</sup> When those muscles fatigue, their capacity to dissipate energy reduces and a greater rotational strain occurs in the humerus, allowing for stress injuries to occur. Therefore, muscle strengthening exercises may also be important in preventing these injuries. Rest seems to be another key protective factor. It has been suggested that all adolescent involved in competitive tennis should rest at least 1 day a week and undertake 1 week of light training per month.<sup>3</sup>

Tennis elite players with humerus stress injuries may sustain concomitant injuries in the same limb. Hoy et al.<sup>10</sup> found that six out of eight athletes with humerus stress injuries had recent or concurrent ipsilateral shoulder injuries. The authors hypothesized that those athletes may impose high stress on the bone as the result of compensation for an ipsilateral injury. To maintain power of stroke or to impart a degree of spin on the ball, a player may overuse uninjured parts of the limb to compensate for lack of power generation more proximally.<sup>10</sup>

Treatment of stress fractures in athletes represents a challenge, even regarding the commonest ones. First, athletes are particularly resistant to discontinue sportive practice and, once they get even partial pain relief, they want to resume training and competing. Secondly, previous commitment with tournaments or championships are another reason for the athlete to fasten the return to play. Thirdly, some athletes tend to return to sport with excessively high loads of training, and this may predispose to recurrence of injury. Indeed, Rizzzone et al.<sup>4</sup> showed that almost one quarter of stress fractures were recurrent in their series. Treating humeral stress fractures seems to be even more challenging due to the paucity of data in the literature and to the very few cases reported. The lack of a treatment protocol means that each athlete has to be treated in an individual basis. In the case we report, the patient continued playing for months despite having pain. Once the diagnosis of stress reaction was made, he stopped training

and became asymptomatic soon after. Four weeks later, a new MRI showed regression of the bone edema and the patient resumed training. However, he trained excessively hard and pain recurred just after 3 days. A new MRI revealed a stress fracture and the patient had to stay even more time apart from the sport practice. After the stress fracture was detected, the patient remained 4 weeks in rest, more 4 weeks doing strengthening exercises, and light training was only allowed after 12 weeks.

Based on the experience with this case, we recommend a more conservative approach when treating athletes sustaining diaphyseal humerus stress fractures, with rest, physiotherapy, muscle strengthening and gradual progression of training load. In our opinion, return to play should be delayed until 12 weeks, even if the patient becomes asymptomatic before that time.

#### Financial Support

There was no financial support from public, commercial, or not-for-profit sources.

#### Conflict of Interests

The authors have no conflict of interests to declare.

#### References

- 1 Smith SR, Patel NK, White AE, Hadley CJ, Dodson CC. Stress Fractures of the Elbow in the Throwing Athlete: A Systematic Review. *Orthop J Sports Med* 2018;6(10):2325967118799262
- 2 Anderson MW. Imaging of upper extremity stress fractures in the athlete. *Clin Sports Med* 2006;25(03):489-504
- 3 Maquirriain J, Ghisi JP. The incidence and distribution of stress fractures in elite tennis players. *Br J Sports Med* 2006;40(05):454-459
- 4 Rizzzone KH, Ackerman KE, Roos KG, Dompier TP, Kerr ZY. The epidemiology of stress fractures in collegiate student-athletes, 2004-2005 through 2013-2014 academic years. *J Athl Train* 2017;52(10):966-975
- 5 Changstrom BG, Brou L, Khodae M, Braund C, Comstock RD. Epidemiology of stress fracture injuries among US high school athletes, 2005-2006 through 2012-2013. *Am J Sports Med* 2015;43(01):26-33
- 6 Gregory P. Upper extremity injuries in the athlete. *J Orthop Trauma* 1995;9(04):361
- 7 Jones GL. Upper extremity stress fractures. *Clin Sports Med* 2006;25(01):159-174, xi
- 8 Iwamoto J, Takeda T. Stress fractures in athletes: review of 196 cases. *J Orthop Sci* 2003;8(03):273-278
- 9 Milgrom C, Finestone A, Shlamkovitch N, et al. Youth is a risk factor for stress fracture. A study of 783 infantry recruits. *J Bone Joint Surg Br* 1994;76(01):20-22
- 10 Hoy G, Wood T, Phillips N, Connell D, Hughes DC. When physiology becomes pathology: the role of magnetic resonance imaging in evaluating bone marrow oedema in the humerus in elite tennis players with an upper limb pain syndrome. *Br J Sports Med* 2006;40(08):710-713, discussion 713