

## Case Report

# Regrowth and progression of multiple calcifying pseudoneoplasms of the neuraxis: Case report

Akira Watanabe, Kinya Nakanishi, Kazuo Kataoka, Tomoko Wakasa<sup>1</sup>, Yoshio Ohta<sup>1</sup>Departments of Neurosurgery and <sup>1</sup>Laboratory Medicine, Nara Hospital Kindai University Faculty of Medicine, Ikoma, Nara, Japan

Email: \*Akira Watanabe - akirawatanabe2-nsu@umin.net; Kinya Nakanishi - knakanishi-nsu@umin.ac.jp;

Kazuo Kataoka - avianbrain@yahoo.ne.jp; Tomoko Wakasa - wakasa@med.kindai.ac.jp; Yoshio Ohta - narahta@med.kindai.ac.jp

\*Corresponding author

Received: 20 June 18 Accepted: 26 October 18 Published: 04 December 18

## Abstract

**Background:** Calcifying pseudoneoplasms of the neuraxis (CAPNONS) are clinically rare, nonneoplastic, noninflammatory-calcified lesions of the central nervous system. Resection of a lesion usually indicates good prognosis without recurrence. However, we experienced a unique case of CAPNON that repeatedly recurred after resection.

**Case Description:** A 52-year-old woman with recurrence of an undiagnosed brain tumor, which was resected 12 years ago, was admitted to our institution. Three calcifying lesions along with perifocal edema were detected in the frontal interhemispheric fissure. We performed the second surgery for total removal of the lesions. The patient was diagnosed with CAPNON on the basis of the clinical features of the lesions and medical examination results. However, 14 months after the second surgery, recurrence occurred, and the patient has been followed up conservatively thereafter.

**Conclusion:** CAPNONS may indicate healing process associated with an unidentified agent. Maximum resection, including an unidentified agent, is necessary to prevent recurrence.

**Key Words:** Brain tumor, calcification, Calcifying pseudoneoplasms of the neuraxis, recurrence

### Access this article online

**Website:**[www.surgicalneurologyint.com](http://www.surgicalneurologyint.com)**DOI:**

10.4103/sni.sni\_181\_18

**Quick Response Code:**

## INTRODUCTION

Calcifying pseudoneoplasms of the neuraxis (CAPNONS) are rare, heavily calcified lesions of the central nervous system. These lesions are nonneoplastic and noninflammatory. To the best of our knowledge, only 62 cases of CAPNON have been reported, including the present case (intracranial: 44; spinal: 18), since it was first identified in 1978.<sup>[5]</sup> The natural course and precise etiology of these lesions remain unknown. CAPNONS cause a variety of symptoms that depend on their anatomical location, although seizures have often been reported. Previous case studies have indicated that total resection of the lesions is typically associated with good prognosis without recurrence.

Herein, we describe the unique clinical course of CAPNON in a patient who required a second surgical resection 12 years after the initial procedure.

This is an open access journal, and articles are distributed under the terms of the Creative Commons Attribution-NonCommercial-ShareAlike 4.0 License, which allows others to remix, tweak, and build upon the work non-commercially, as long as appropriate credit is given and the new creations are licensed under the identical terms.

**For reprints contact:** [reprints@medknow.com](mailto:reprints@medknow.com)

**How to cite this article:** Watanabe A, Nakanishi K, Kataoka K, Wakasa T, Ohta Y. Regrowth and progression of multiple calcifying pseudoneoplasms of the neuraxis: Case report. *Surg Neurol Int* 2018;9:243.

<http://surgicalneurologyint.com/Regrowth-and-progression-of-multiple-calcifying-pseudoneoplasms-of-the-neuraxis:-Case-report/>

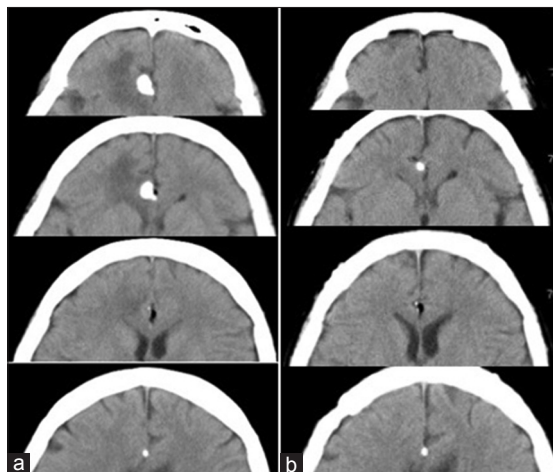
## CASE HISTORY

### Clinical course

A 40-year-old woman presented to our institution with excessive somnolence. She was diagnosed with brain tumor in the right frontal lobe parenchyma following computed tomography (CT) scan of the head. The primary lesion was a high-density mass of approximately 11 mm in diameter. The mass had signs of calcification, and it was surrounded by low-density lipomas [Figure 1a]. Gadolinium-enhanced magnetic resonance imaging (Gd-MRI) revealed a rim-enhanced mass. Moreover, edema was observed in the right frontal lobe parenchyma [Figure 2].

We performed the first surgery to confirm the tumor diagnosis. Only the largest mass was removed. After surgery, CT scan revealed that the edema in the right frontal lobe had resolved [Figure 1b]. No malignant histopathological changes were observed, although a definitive diagnosis was not established. The patient did not experience recurrence for 3 years after the first surgery; however, she did not undergo any medical examinations thereafter.

After 12 years, the patient was admitted to our institution because of tumor recurrence. Head CT-scan revealed three highly dense mass lesions in the frontal interhemispheric fissure [Figure 3a]. On MRI, low-intensity masses were observed on T1- and T2-weighted images. Further analysis revealed the presence of edema surrounding the lesions in the right frontal lobe parenchyma and corpus callosum. CT angiography indicated that the lesions surrounded the anterior cerebral artery (ACA) [Figure 3b]. Conventional cerebral angiography revealed no vascular lesions or blood supply associated with the masses. The lesions were diagnosed as the progression of a residual tumor. She



**Figure 1:** (a) Head computed tomography (CT) scan prior to the first surgery. A high-density calcification associated with a lipoma is seen in the frontal interhemispheric fissure. Swelling is also observed in the brain parenchyma surrounding the lesion. (b) Head CT-scan after the first surgery. The calcification and perifocal edema have resolved

underwent surgery again to excise the lesion to make an accurate diagnosis and reduce perifocal edema.

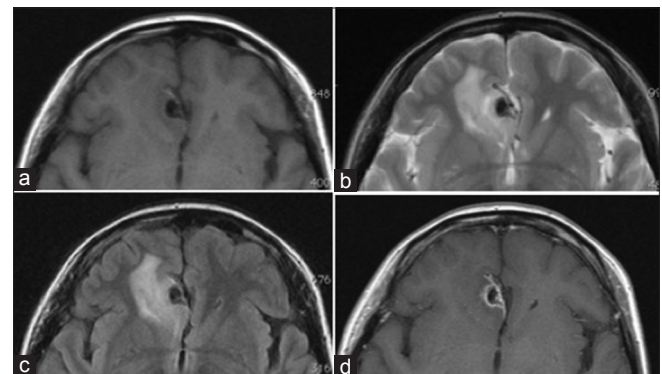
### Second surgery

We performed bifrontal re-craniotomy and approached the lesion by tracing the right ACA from distal to proximal in the interhemispheric fissure and identified a calcifying mass lesion surrounding the ACA [Figure 4]. A lipoma was found near the lesion. However, no association was observed between the two. The calcifying mass was hard to remove using a suction tube. Therefore, the lesion was broken using forceps, and the pieces were gradually removed. Total resection of all three lesions from the artery surface was possible. Postoperative head CT-scan confirmed the absence of all calcifying masses as well as reduced brain edema around the lesion [Figure 5a]. The patient showed partial improvement.

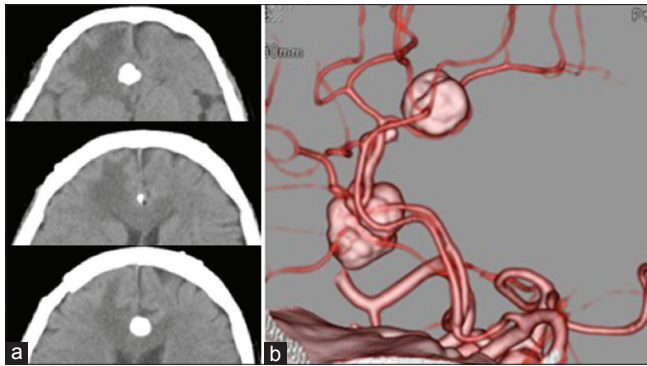
Histopathological examination revealed a hypocellular nodule with calcium deposition. The lymphocyte or plasma cells infiltrated into the margin of the mass. No malignant change occurred [Figure 6a and b]. The patient was diagnosed with CAPNON on the basis of clinical course and imaging histopathological examination results. Follow-up CT-scan was performed 14 months after the second surgery, and it revealed a small, high-density mass at the same location. The lesion was approximately 3.5 mm in diameter, and the size remained the same for 2 years [Figure 5b-d]. Because the patient's neurological condition did not change, we continued to follow-up conservatively.

## DISCUSSION

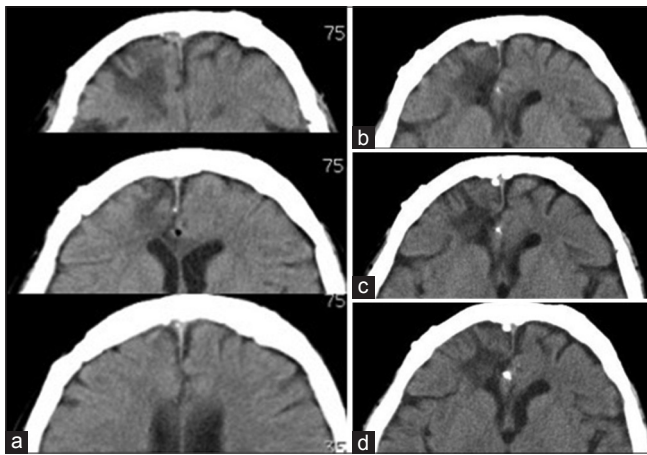
CAPNONs are rare, calcified lesions of the central nervous system; they can occur in extra-axial, intra-axial, and intraosseous locations. Moreover, these lesions have been referred to as fibro-osseous lesions, cerebral calculi, brain stones, and calcifying pseudo-tumors. By exerting pressure on adjacent structures, they may cause various symptoms according to their anatomical location.



**Figure 2:** Initial magnetic resonance imaging. (a-c) A low-intensity area is seen on T1- and T2-weighted and fluid-attenuated inversion recovery images. (d) Gadolinium-enhanced T1-weighted images reveal a high-intensity area around the rim of the mass and edema in the right frontal lobe parenchyma



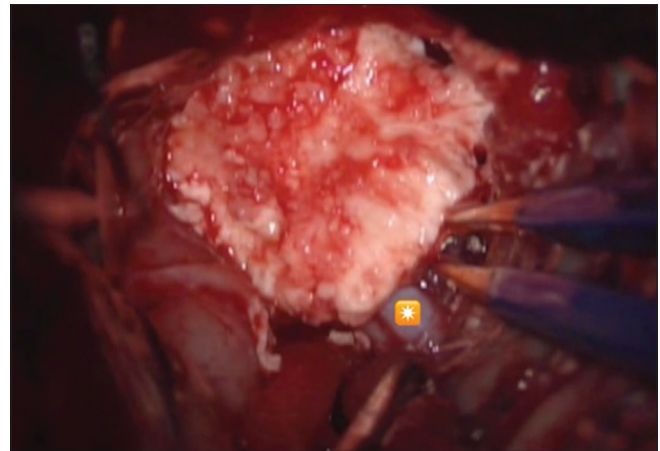
**Figure 3:** (a) Head computed tomography (CT) scan prior to the second surgery. Three high-density mass lesions are observed in the frontal interhemispheric fissure. Swelling is also observed in the brain parenchyma around the lesions. (b) 3D CT angiography reveals an area of calcification surrounding the anterior cerebral artery



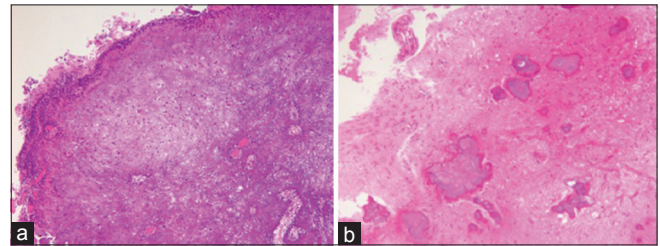
**Figure 5:** (a) Head computed tomography (CT) scan after the second surgery. Three high-density masses are removed without residual calcification. Edema around the lesions is reduced. (b–d) Head CT-scan 14, 18, and 24 months after the second surgery. A small high-density mass observed in the frontal interhemispheric cistern again. The mass lesion has grown to approximately 3.5 mm in diameter, and the size remains the same

Typically, CT scan shows a CAPNON as a well-demarcated, densely calcified mass, whereas MRI shows uniform low-intensity signals on both T1- and T2-weighted images. Rim enhancement may also be observed on Gd-MRI. Shrier *et al.* have reported that gadolinium enhancement occurs when a lesion is associated with a highly vascular fibrous stroma.<sup>[7]</sup> Few cases are associated with perifocal edema in the brain parenchyma. Aiken *et al.* have described these findings as typical radiological features of CAPNON that may help in differentiating it from other diseases.<sup>[1]</sup>

Considering the lack of mass effect, the presence of high-intensity areas around the lesions on T2-weighted images represents gliosis. However, in the present case, a high-intensity area was observed in the adjacent frontal lobe parenchyma prior to the first and second surgeries, which diminished after resection. High-intensity signal on T2-weighted images may indicate areas of edema. So



**Figure 4:** Intraoperative photographs obtained during the second surgery. White calcified mass surrounding the artery in the interhemispheric fissure. \*Branch of anterior cerebral artery



**Figure 6:** (a) Specimens obtained during the second surgery. A strong nodular calcification observed in small vessels. Epithelioid or spindle cells are also observed at the margin of the nodule [hematoxylin–eosin (HE) staining  $\times 40$ ]. (b) Specimens obtained during the first surgery. Multiple calcifications are observed in the brain parenchyma (HE staining  $\times 40$ )

far, six cases of perifocal edema associated with CAPNON have been identified, including the present case. Of them, two included extra-axial lesions that severely compressed the spinal cord and brain stem. Edema in these cases may be a result of the strong mass effect. However, in the present case, prior to the first surgery, no significant compression of the brain parenchyma had occurred. Therefore, an unidentified agent may have contributed to the lesion formation.

Histopathologically, CAPNON is typically characterized by hypocellular chondromyxoid matrix and variable amounts of fibrovascular stroma, which are often surrounded by palisading spindles or epithelioid cells and occasionally surrounded by multinucleate giant cells. Various states of calcification in the form of osseous metaplasia, scattered psammoma bodies, or calcium deposits have been observed in some cases; however, cellular proliferation and mitosis have not been reported. These features may be associated with the healing process that occurs in damaged tissues. Previous reports have indicated that epithelioid cells surrounding the lesion are positive for vimentin, possibly because of the presence of macrophages and lymphocytes and that most cells are positive for epithelial

membrane antigen (EMA) and negative for glial fibrillary acidic protein and S-100. In the present case, epithelioid cells were only positive for vimentin.<sup>[9]</sup> Epithelial-derived EMA-positive cells may not be important for lesion formation. Multiple calcifications were observed in the brain parenchyma after the first surgery, although calcified masses after the second surgery were primarily located in the subarachnoid space surrounding the ACA.

In the present case, CAPNONS were accompanied by lipomas. Salim *et al.* reported a similar case with agenesis of the corpus callosum, and other cases of lipomas were observed in the interhemispheric cistern.<sup>[6,8]</sup> Intracranial lipomas are considered as congenital malformations, and they frequently occur in the interhemispheric cistern. Research has indicated that the abnormal differentiation of the meninx primitiva during subarachnoid cistern development causes the formation of intracranial lipomas, and they are frequently accompanied by other anomalies.<sup>[10]</sup>

Calcifications are usually observed in the collagenous capsule or parenchyma surrounding the lipoma.<sup>[11]</sup> However, in this case, lipomas and CAPNONS were not associated. Although their simultaneous occurrence may be coincidental, these meningeal abnormalities may indicate healing process and the progressive nature of CAPNONS.

Several authors have reported that CAPNONS progressed for 3–11 years.<sup>[2,3,9]</sup> In the present study, the lesion that remained after the first surgery had progressed for over 12 years and recurred 14 months after the second surgery. According to a previous report, the recurrence rate of CAPNON is <10%, and cases where recurrence has been reported typically involve lesions in the base of the skull or intraosseous axial lesions, which cannot be completely removed.<sup>[9]</sup>

After the second surgery, we considered that the residual lesions may regrow in the future, and these lesions should be removed along with the affected tissue as much as possible. Although total resection was performed, regrowth occurred after the second surgery. Therefore, removing the tissues surrounding the calcifications may also be necessary in reducing the effect of the unknown agents that may cause regrowth. However, health-care professionals must be cautious during aggressive resection to avoid injury in the adjacent structures.

Stienen *et al.* have analyzed the association between residual tumors and recurrence based on previous cases. However, they have observed no significant difference in terms of recurrence between the patients who underwent complete resection and the patient who underwent incomplete resection.<sup>[9]</sup> Total resection is not always required, particularly when lesions are associated with important neurological structures. In cases where total resection is not possible, medical treatment may control the lesion progression. Kwan *et al.*<sup>[4]</sup> have reported a case of symptomatic spinal CAPNON that resolved after

indomethacin administration. However, the case may have been representative of a different disease because the lesion was not diagnosed using histological methods. Nevertheless, both medical treatment and surgery should be considered in CAPNON management.

## CONCLUSIONS

This study presented the case of a patient who required a second surgery to remove a CAPNON 12 years after the initial surgery. CAPNONS may be indicative of the healing process associated with an unidentified agent. Although surgery is typically associated with good prognosis, residual lesions may regrow. Thus, maximum resection must be performed, particularly in younger patients. Due to possible recurrence, patients should undergo periodic follow-ups. Moreover, further accumulation of cases is required to elucidate the underlying pathophysiology of CAPNON.

## Declaration of patient consent

The authors certify that they have obtained all appropriate patient consent forms. In the form the patient(s) has/have given his/her/their consent for his/her/their images and other clinical information to be reported in the journal. The patients understand that their names and initials will not be published and due efforts will be made to conceal their identity, but anonymity cannot be guaranteed.

## Financial support and sponsorship

No funding was received for this research.

## Conflicts of interest

There are no conflicts of interest.

## REFERENCES

1. Aiken AH, Akgun H, Tihan T, Barbaro N, Glastonbury C. Calcifying pseudoneoplasms of the neuraxis: CT, MR imaging, and histologic features. *AJNR Am J Neuroradiol* 2009;30:1256-60.
2. Jun C, Burdick B. An unusual fibro-osseous lesion of the brain. Case report. *J Neurosurg* 1984;60:1308-11.
3. Kerr EE, Borys E, Bobinski M, Shahlaie K. Posterior fossa calcifying pseudoneoplasm of the central nervous system. *J Neurosurg* 2013;118:896-902.
4. Kwan MK, Abdelhai AM, Beng Saw L, Wei Chan CY. Symptomatic calcifying pseudotumor of the thoracic spine that resolved with the indomethacin treatment: A case report. *Spine (Phila Pa 1976)* 2012;37:E1676-9.
5. Rhodes RH, Davis RL. An unusual fibro-osseous component in intracranial lesions. *Hum Pathol* 1978;9:309-19.
6. Salim AA, Wilson PJ, Cherukuri RK, McKenzie S, Buckland ME. An unusual association of calcifying pseudoneoplasm of the neuraxis with interhemispheric lipoma and agenesis of corpus callosum. *Pathology* 2012;44:657-9.
7. Shrier DA, Melville D, Millet D, Qian J, Millet D, Nelson C, *et al.* Fibro-osseous lesions involving the brain: MRI. *Neuroradiology* 1999;41:18-21.
8. Smith DM, Berry AD 3<sup>rd</sup>. Unusual fibro-osseous lesion of the spinal cord with positive staining for glial fibrillary acidic protein and radiological progression: A case report. *Hum Pathol* 1994;25:835-8.
9. Stienen MN, Abdulazim A, Gautschi OP, Schneiderhan TM, Hildebrandt G, Lucke S. Calcifying pseudoneoplasms of the neuraxis (CAPNON): Clinical features and therapeutic options. *Acta Neurochir* 2013;155:9-17.
10. Truwit CL, Barkovich AJ. Pathogenesis of intracranial lipoma: An MR study in 42 patients. *AJR Am J Roentgenol* 1990;155:855-64; discussion 865.
11. Yilmaz N, Unal O, Kiyamaz N, Yilmaz C, Etilik O. Intracranial lipomas—a clinical study. *Clin Neurol Neurosurg* 2006;108:363-8.