

# Amsler Grid Versus 10-2 Test in Primary Open Angle Glaucoma

## Abstract

**Background:** Glaucoma is the leading cause of global irreversible blindness. The goal of management in glaucoma lies in its early detection and treatment to prevent further optic neuropathy. Available equipment for early glaucoma detection is not cost-effective or readily available in resource-scarce settings such as Nigeria. Thus, there is a need for a simple cost-effective tool to detect glaucomatous central visual field (CVF) defects in all the stages of glaucoma within the community in resource scarce-settings. **Aims and Objectives:** The aim of this article is to determine the validity of the Amsler grid in detecting central glaucomatous visual field defects in primary open angle glaucoma (POAG). **Materials and Methods:** This was a cross-sectional study of follow-up glaucoma patients at a secondary eye care hospital in Nigeria. All patients had detailed ophthalmic examination in addition to 24-2 and 10-2 CVF tests and Amsler grid test. POAG was classified using the Hodapp–Parrish–Anderson criteria into mild, moderate, and severe on 24-2 CVF. The diagnostic validity of the Amsler grid was calculated using the 10-2 CVF as a reference standard. Regression analyses were performed between the Amsler grid scotoma area and 10-2 CVF parameters [mean deviation (MD), scotoma extent (SE), and scotoma mean depth (SMD)]. **Results:** A total of 150 eyes of 150 patients were enrolled. The sensitivity, specificity, and positive predictive value and negative predictive value of the Amsler grid compared with the 10-2 CVF was 49.5%, 95.9%, 96.2%, and 47.9%, respectively, with an area under curve of 0.7. Sensitivity increased with increasing severity ( $P < 0.001$ ) from 20.0%, 31.0%, and 76.6% in mild, moderate, and severe POAG, respectively. The Amsler grid scotoma area had the strongest relationship with the 10-2 MD, followed by 10-2 SE and 10-2 SMD with a quadratic  $R^2$  of 0.579, 0.370, and 0.307, respectively. **Conclusion:** The Amsler grid has a low sensitivity in mild-to-moderate POAG. However, it may serve as an adjunctive tool in resource-scarce settings for detection of severe POAG in the community by primary eye care providers.

**Keywords:** Amsler grid, primary open angle glaucoma, 10-2 central visual field

## Introduction

Glaucoma is the second leading cause of blindness in the world,<sup>[1]</sup> with Africa having the highest incidence and prevalence.<sup>[1,2]</sup> In 2010, global estimates of people with glaucoma was 60.5 million increasing to almost 80 million in 2020<sup>[3]</sup> and it is projected to rise to a staggering 111.8 million by 2040.<sup>[2]</sup> Glaucoma, the silent thief of sight, is a continuum from relatively asymptomatic disease in its early and moderate stages to irreversible symptomatic visual function deficit in the advanced stages.<sup>[4]</sup> The main goal of treatment is to slow down progression and preserve the quality of life by reducing the intraocular pressure. Unfortunately, most glaucoma patients in Nigeria present in the advanced stage with

irreversible blindness already occurring in at least one eye.<sup>[5,6]</sup>

The standard automated perimetry (SAP) is the clinical gold standard for diagnosing and monitoring functional defects in glaucoma<sup>[7,8]</sup>; however, it is not widely available or accessible in resource-scarce settings such as sub-Saharan Africa (SSA).<sup>[9]</sup> Moreover, patients find testing cumbersome due to the effects of fatigue from lengthy test time.<sup>[10,11]</sup>

Earlier studies reported that glaucoma initially damaged the peripheral visual and spared the central visual field (CVF) until late in the disease. Therefore, the 10-2 test pattern was initially reserved for advanced glaucoma. In the last decade, however, there was evidence that parafoveal visual defects could occur even in early glaucoma.<sup>[12-14]</sup> De Moraes *et al.*<sup>[14]</sup> reported glaucoma suspects and ocular hypertensives, and patients with

**Temitope Mariam Gbadegesin, Olusola Olawoye<sup>1</sup>, Tarela Frederick Sarimiye<sup>1</sup>, Oluwatobi Olalekan Idowu<sup>2</sup>, Benedictus G.K. Ajayi**

*Eleta Eye Institute, Eleta, Ibadan, <sup>1</sup>Department of Ophthalmology, College of Medicine, University of Ibadan, Ibadan, Nigeria, <sup>2</sup>Genentech Inc., South San Francisco, CA, USA*

**Received:** 01-Nov-2022

**Accepted:** 21-Nov-2022

**Published:** 20-Mar-2023

**Address for correspondence:**

*Dr. Olusola Olawoye, Department of Ophthalmology, College of Medicine, University of Ibadan, Ibadan, Nigeria. E-mail: solaolawoye@yahoo.com*

**Access this article online**

**Website:**

www.jwacs-jcoac.com

**DOI:** 10.4103/jwas.jwas\_275\_22

**Quick Response Code:**



**How to cite this article:** Gbadegesin TM, Olawoye O, Sarimiye TF, Idowu OO, Ajayi BGK. Amsler grid versus 10-2 test in primary open angle glaucoma. *J West Afr Coll Surg* 2023;13:92-9.

This is an open access journal, and articles are distributed under the terms of the Creative Commons Attribution-NonCommercial-ShareAlike 4.0 License, which allows others to remix, tweak, and build upon the work non-commercially, as long as appropriate credit is given and the new creations are licensed under the identical terms.

**For reprints contact:** reprints@medknow.com

early glaucoma had an abnormal 10-2 missed by the 24-2 CVF test pattern, which was more likely in patients of African descent. Hood and De Moraes<sup>[15]</sup> recommended that all glaucoma patients and suspects should perform the 10-2 CVF test pattern to evaluate the macula region. It has however not been practical and cost-effective for patients with early or advanced glaucoma to perform serial tests of both 24-2 and 10-2 CVF. In addition, in very advanced glaucoma, it may be difficult to monitor progression even with a 10-2 CVF and clinicians may have to combine both 10-2 and subjective assessments by patients. It is therefore important to consider other forms of testing that can be of benefit to these patients.

The Amsler grid is used to clinically test for visual field defects in the central 10° of the visual field and the macula, as well as monitoring scotomas and metamorphopsia,<sup>[16]</sup> using a supra-threshold target. Several recent studies have described the vision loss of glaucoma patients as a blur or missing features.<sup>[17,18]</sup> These descriptions may be detected with the use of the Amsler grid. The Amsler grid is a simple low-cost chart, which can be self-administered or used by primary eye care providers. Most studies on the use of the Amsler grid have been carried out primarily in patients with retinal diseases or a small number of glaucoma patients<sup>[18-22]</sup> with limited studies in strictly glaucoma patients.<sup>[23-25]</sup> The aim of the current study was to determine the validity of the Amsler grid in detecting central glaucomatous visual field defects in different severities of POAG in a cohort of glaucoma patients in South West Nigeria.

## Materials and Methods

This was a hospital-based, cross-sectional study conducted over a 6-month period from November 2020 to April 2021. Consecutive follow-up patients aged  $\geq 40$  years previously diagnosed with primary open angle glaucoma (POAG) and on treatment attending the outpatient clinic at Eleta Eye Institute, Ibadan were enrolled into this study. Detailed ophthalmic and medical history and ocular examination was obtained from eligible patients to confirm the diagnosis of POAG. The study adhered to the tenets of the Declaration of Helsinki, and approval was obtained from the Ethical Review Board of the Sebastian Centre for Ophthalmic Research and Education, Eleta Eye Institute, Ibadan. Written informed consent was obtained from all the participants.

Participants included in the study were aged 40 years and above with established glaucoma, who had performed at least two previous reliable 24-2 Humphrey Field Analysers (HFAs) at least 6 months apart prior to the study. Other inclusion criteria were open angles on gonioscopy and a visual acuity of 6/36 or better as reasonable vision is important for a reliable visual field analysis and Amsler grid testing.

Patients were excluded from the study if they had any neurological systemic diseases such as stroke or non-glaucomatous ocular diseases or previous posterior segment

intraocular surgeries such as retinal photocoagulation that can affect the visual fields. Patients on miotic drops and patients with extreme refractive errors such as high myopia ( $-6.0$  or higher), high hyperopia ( $+6.0$  or higher), or astigmatism ( $\pm 3$ DCyl) were all excluded. Also excluded were patients who have had any anterior segment surgery less than 3 months prior to enrolment for the study to allow enough time for healing, or presence of visually significant cataracts (that is lens opacities greater than stage 2 using the Lens Opacities Classification System III).<sup>[26]</sup> Patients with posterior capsule opacity or any macula pathology and patients who could not perform reliable CVF or with other forms of glaucoma other than POAG were also excluded.

A detailed ophthalmic history and examination were carried out. Amsler grid test (AGT) and 10-2 CVF test were done on the same day, with the AGT done first to eliminate the effect of fatigue from the CVF testing. During the AGT, one eye was tested with an eye patch occluding the eye not being tested. With the near correction in place, the patient was asked to fixate at the central point of a  $10 \times 10$  cm chart with black vertical and horizontal lines on a white background and a central dot (modified printable Amsler grid) at a distance of 30 cm. For patients who had difficulty fixating at the centre, a chart 2 Amsler grid was used (grid with diagonal lines extending from the corners of the grid to extrapolate the centre of the grid). The patient was then asked to describe and draw the edges of any perceived scotomas. The same examination room and lighting conditions were used for all patients. An abnormal AGT was defined as the presence of a scotoma (i.e., areas with blurry or missing grid lines). The scotoma drawn on the Amsler grid was referred to as the Amsler grid scotoma area, and this was measured using the ImageJ software (version 1.43u, National Institute of Health).

All patients had a new CVF test and glaucoma severity was classified into mild, moderate, and severe based on the mean deviation (MD) of the 24-2 CVF test using the Hodapp–Parrish–Anderson classification.<sup>[27]</sup> The 24-2 and 10-2 CVF tests were done with the same SITA Standard Humphrey Field Analyser (HFAII 750; 2010 Carl Zeiss Meditec, Dublin, CA, USA) using the Goldmann stimulus spot size III and background luminance of 31.5 asb. The same refractive correction was used under the same room lighting conditions for both the 24-2 and 10-2 CVF tests. An interval of at least 20-min rest in between the 24-2 and 10-2 CVF tests was allowed to eliminate the effect of fatigue. A CVF test was regarded as reliable with a fixation loss  $< 20\%$  and false positive and false negative responses  $< 33\%$ . One eye of consecutive patients with different severities of POAG was enrolled concurrently into mild, moderate, and severe until the estimated number (50 eyes per group) was attained for each group. In patients in whom both eyes met the inclusion criteria, the eye with the lesser severity of glaucoma was selected or the right eye was selected if both eyes were of the same severity.

**Table 1: Demographic characteristics of patients across the different severities of POAG**

| Characteristics            | All N=150 (%) | Mild N=50 (%) | Moderate N=50 (%) | Severe N=50 (%) | P-value                   |
|----------------------------|---------------|---------------|-------------------|-----------------|---------------------------|
| Age (mean±SD)              | 59.3±11.0     | 56.5±9.9      | 61.1±10.5         | 60.2±12.2       | 0.0820 <sup>^</sup>       |
| Gender (%)                 |               |               |                   |                 | <b>0.0080<sup>+</sup></b> |
| Male                       | 70 (46.7)     | 17 (34.0)     | 21 (42.0)         | 32 (64.0)       |                           |
| Female                     | 80 (53.3)     | 33 (66.0)     | 29 (58.0)         | 18 (36.0)       |                           |
| Educational status (%)     |               |               |                   |                 | 0.4260 <sup>+</sup>       |
| Primary or less            | 40 (26.7)     | 13 (26.0)     | 10 (20.0)         | 17 (34.0)       |                           |
| Secondary                  | 31 (20.7)     | 10 (20.0)     | 10 (20.0)         | 11 (22.0)       |                           |
| Tertiary                   | 79 (52.7)     | 27 (54.0)     | 30 (60.0)         | 22 (44.0)       |                           |
| Family history of glaucoma |               |               |                   |                 | 0.4240 <sup>+</sup>       |
| Yes                        | 45 (30.0)     | 18 (36.0)     | 12 (24.0)         | 15 (30.0)       |                           |
| No                         | 105 (70.0)    | 32 (64.0)     | 38 (76.0)         | 35 (70.0)       |                           |

P-values less than 0.05 are highlighted in bold. SD: standard deviation; <sup>+</sup>P-value from the  $\chi^2$  test; <sup>^</sup>P-value from one-way analysis of variance

Glaucomatous damage on the 24-2 CVF test using the HPA classification<sup>[27]</sup> was defined as a cluster of three or more non-edge points in a location typical of glaucoma, all of which are depressed on the pattern deviation plot at  $P < 5\%$  and one of which is depressed at  $P < 1\%$ . The 10-2 CVF test was classified as abnormal<sup>[12]</sup> if there are a cluster of contiguous points within a hemi-field on pattern deviation plots (5%, 5% and 1% or 5%, 2% and 2% or worse). The number of abnormal test points with  $P < 0.01$  on the total deviation map on the 10-2 CVF test was counted and defined as scotoma extent (SE),<sup>[24]</sup> whereas the average of the total deviation sensitivity of these abnormal test points on 10-2 CVF was calculated and defined as scotoma mean depth (SMD).<sup>[24]</sup>

### Statistical analysis

Statistical analysis was carried out using the Statistical Package for the Social Sciences (IBM SPSS Statistics for Windows, Version 20.0; IBM Corp., Armonk, NY, USA). P-values  $\leq 0.05$  were considered as being statistically significant. The data were summarized using mean and standard deviation for quantitative data, whereas frequencies and percentages were used for categorical data. Categorical data were analysed using the  $\chi^2$  test. One-way analysis of variance was used for comparison within the groups. The diagnostic validity of the Amsler grid was described with the sensitivity, specificity, and positive predictive value (PPV) and negative predictive value (NPV), and area under the receiver operating curve (ROC) was calculated using the 10-2 CVF test as the clinical reference standard in the different severities of glaucoma. Linear and quadratic regression analyses were calculated using the Amsler grid scotoma area and 10-2 CVF test parameters (MD, SE, and SMD) to describe the relationship between 10-2 CVF test and AGT in glaucoma patients.

### Results

A total of 150 eyes of 150 follow-up patients with mild, moderate, and severe POAG were enrolled into the study from the general outpatient clinic. There were 50 eyes

in each severity group. Table 1 shows the demographic characteristics of the patients. The male-to-female ratio across all the different severities of POAG was 1:1.1. The difference in the distribution of gender across the different severity groups was statistically significant ( $P = 0.008$ ) [Table 1]. The average MD across the different groups on 24-2 and 10-2 CVF was  $-11.7 \pm 8.7$  dB and  $-8.6 \pm 8.6$  dB, respectively, which increased with worsening severity of POAG ( $P < 0.001$ ).

### Diagnostic validity of the Amsler grid in detecting CVF defects in POAG

Of the 150 eyes in all severity groups, 49 had a normal 10-2 CVF, 47 had a normal AGT, and 2 had an abnormal AGT [Table 2]. Of the 101 eyes with an abnormal 10-2 CVF test, 50 had an abnormal AGT and 51 had a normal AGT. The sensitivity, specificity, PPV, and NPV of the AGT in detecting central glaucomatous visual field defects in the different severities of POAG were 49.5%, 95.9%, 96.2%, and 48.0%, respectively, when compared with the 10-2 CVF as the reference standard [Table 2]. The area under curve of the Amsler grid and 10-2 CVF was 0.7 (95% confidence interval: 0.6–0.8). Sensitivity and specificity of the Amsler grid increased with increasing glaucoma severity [Table 2].

### Relationship of Amsler grid scotoma area and 10-2 CVF test parameters

Of the 10-2 CVF test parameters (10-2 MD, 10-2 SE, and 10-2 SMD), the 10-2 CVF MD [Figure 1(a)] had the strongest relationship with the Amsler grid scotoma area on linear as well as quadratic regression analyses (linear  $R^2 = 0.574$ ; quadratic  $R^2 = 0.579$ ) followed by the 10-2 CVF test SE [Figure 1(b)] (linear  $R^2 = 0.352$ ; quadratic  $R^2 = 0.370$ ) and then the least the SMD [Figure 1(c)] (linear  $R^2 = 0.288$ ; quadratic  $R^2 = 0.307$ ).

### Discussion

This study showed that the Amsler grid had moderate diagnostic validity in detecting central glaucomatous visual field defects within  $10^\circ$  of the visual field when compared

**Table 2: Diagnostic validity of the Amsler grid in detecting central glaucomatous visual field defects within 10° of the visual field in different severities of POAG**

| Presence of scotoma on Amsler grid | Presence of scotoma on 10-2 CVF test |          |             | Diagnostic validity (%) | ROC area (95% CI) |
|------------------------------------|--------------------------------------|----------|-------------|-------------------------|-------------------|
| Mild                               | Normal                               | Abnormal |             |                         |                   |
|                                    | Normal                               | 24       | 20          | Sensitivity             | 20.0 (6.8–40.7)   |
| Abnormal                           | 1                                    | 5        | Specificity | 96.0 (79.6–99.9)        |                   |
|                                    |                                      |          | PPV         | 83.3 (35.9–99.6)        |                   |
|                                    |                                      |          | NPV         | 54.5 (38.8–69.6)        |                   |
| Moderate                           | Normal                               | Abnormal |             |                         |                   |
|                                    | Normal                               | 20       | 20          | Sensitivity             | 31.0 (15.3–50.8)  |
| Abnormal                           | 1                                    | 9        | Specificity | 95.2 (76.2–99.9)        |                   |
|                                    |                                      |          | PPV         | 90.0 (55.5–99.8)        |                   |
|                                    |                                      |          | NPV         | 50.0 (34.8–66.2)        |                   |
| Severe                             | Normal                               | Abnormal |             |                         |                   |
|                                    | Normal                               | 3        | 11          | Sensitivity             | 76.6 (61.6–87.2)  |
| Abnormal                           | 0                                    | 36       | Specificity | 100.0 (31.0–100)        |                   |
|                                    |                                      |          | PPV         | 100.0 (88.0–100.0)      |                   |
|                                    |                                      |          | NPV         | 21.4 (5.7–51.2)         |                   |
| Overall                            | Normal                               | Abnormal |             |                         |                   |
|                                    | Normal                               | 47       | 51          | Sensitivity             | 49.5 (39.5–59.6)  |
| Abnormal                           | 2                                    | 50       | Specificity | 95.9 (84.9–99.2)        |                   |
|                                    |                                      |          | PPV         | 96.2 (85.7–99.3)        |                   |
|                                    |                                      |          | NPV         | 48.0 (37.8–58.2)        |                   |

PPV: positive predictive value; NPV: negative predictive value; CI: confidence interval. Diagnostic validity is expressed in percentage

with 10-2 CVF with an AUC of 0.7 (95% confidence interval of 0.6–0.8). Across the different severity groups, this study found a sensitivity, specificity, PPV, and NPV of 48.0%, 95.9%, 96.2%, and 47.9%, respectively. Several studies<sup>[18,28]</sup> for different ocular conditions have reported that the Amsler grid has a high specificity (low false positive) but a low sensitivity (high false negative) for detecting ocular diseases. The reduced ability of the Amsler grid to detect a scotoma may be attributed to the filling-in phenomenon whereby visual features are perceived on the basis of the surrounding features,<sup>[29,30]</sup> thus accounting for the low sensitivity of the Amsler grid. This perceptual filling-in explains the absence of the blind spot on AGT. In addition, Schuchard<sup>[19]</sup> demonstrated that small scotomas less than 6°, which is equivalent to the size of the physiological blind spot,<sup>[30]</sup> could be missed on the Amsler grid. Similarly, in the USA, Su *et al.*<sup>[24]</sup> reported the sensitivity, specificity, PPV, NPV, and AUC of 68%, 92%, 97%, 46%, and 0.8, respectively, for Amsler grid assessment across different severities of glaucoma further buttressing a low Amsler grid sensitivity. Interestingly, the authors reported a higher sensitivity when compared with the current study. This observation may be explained by the different classification criteria used for the severity of POAG. Su *et al.*<sup>[24]</sup> used the MD of 10-2 CVF to classify the severity of POAG, whereas the MD of 24-2 CVF was used in this study.

The sensitivity of the Amsler grid increased with worsening severity of POAG. A sensitivity of 20.0% in the group with mild POAG increased to 31.0% in moderate POAG and 76.6% in severe POAG. The wide disparity among

the different groups may be because the participants in the group with severe POAG had more widespread CVF defects as demonstrated on the 10-2 CVF test and hence easily detected by the Amsler grid.

On the sub-group analysis, the current study found the sensitivity, specificity, PPV, and NPV of the Amsler grid in patients with severe POAG to be 76.6%, 100%, 100%, and 21.4%, respectively. Similarly, in Ethiopia, Gessesse *et al.*<sup>[25]</sup> found the sensitivity, specificity, PPV, and NPV to be 80.4%, 95.4%, 93%, and 85.1%, respectively, on black-on-white Amsler grid in 100 eyes with advanced glaucoma. The severity of the advanced glaucoma in their study was greater as evidenced by the average MD on 10-2 CVF of  $-19.9 \pm 9.8$  dB compared with the average MD of  $-18.6 \pm 7.9$  dB in this study, which may account for the large disparity in the NPV.

In a bid to increase the sensitivity, advances over the traditional Amsler grid have been made using either a threshold Amsler grid with polarized lenses<sup>[31]</sup> or a three-dimensional computer automated threshold Amsler grid (3D CTAG).<sup>[16,32]</sup> The 3D CTAG was reported to be more sensitive in detecting and characterizing scotomas in glaucoma suspects<sup>[33]</sup> and glaucoma patients<sup>[16]</sup> when compared with SAP as well as in age-related macular degeneration when compared with fundus angiograms.<sup>[32]</sup> The 3D CTAG requires the use of a computer which may not be readily available and hence forfeits the use of a tool that is cost-effective, readily available, and accessible in the community and in primary healthcare settings. However,



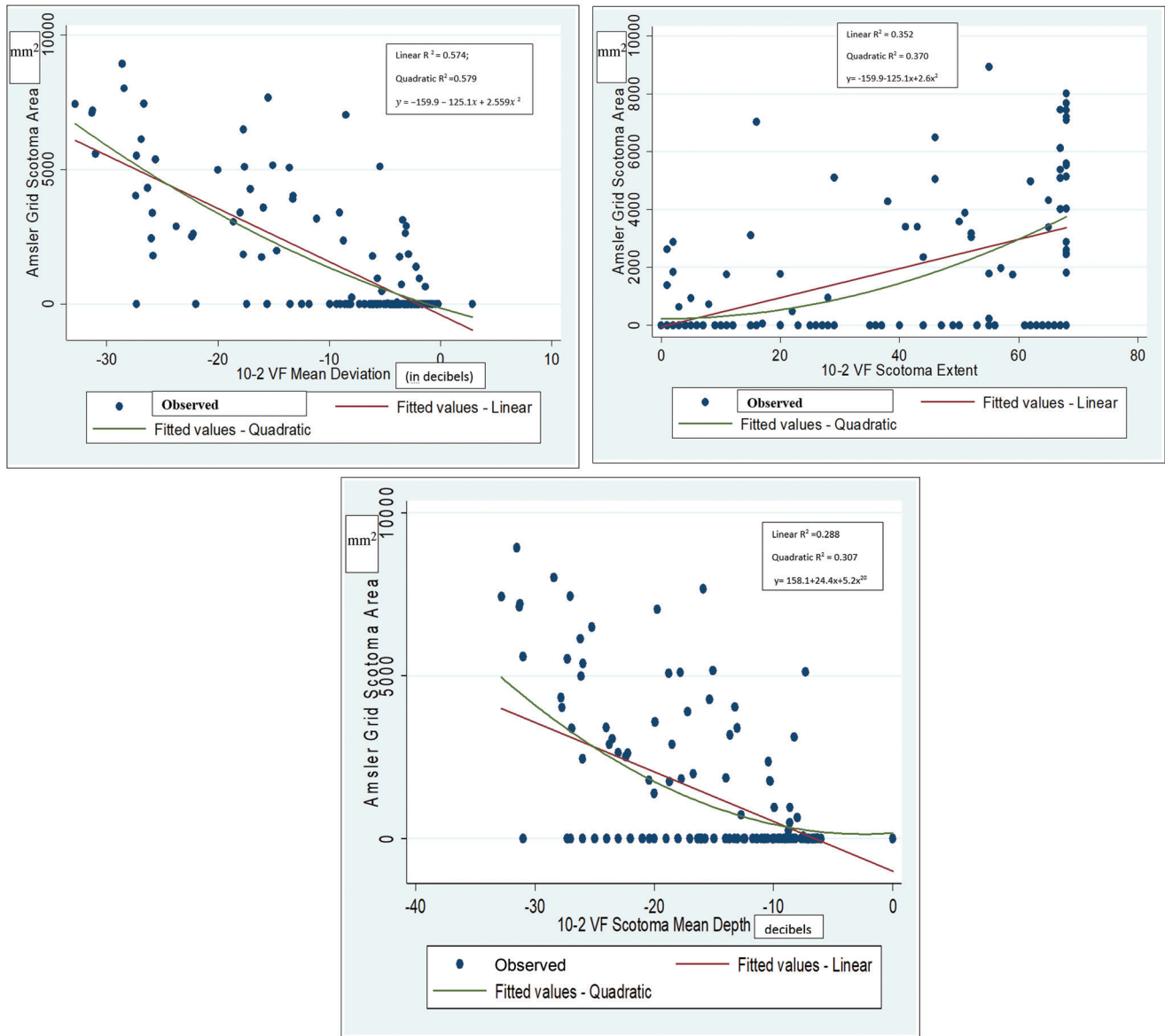


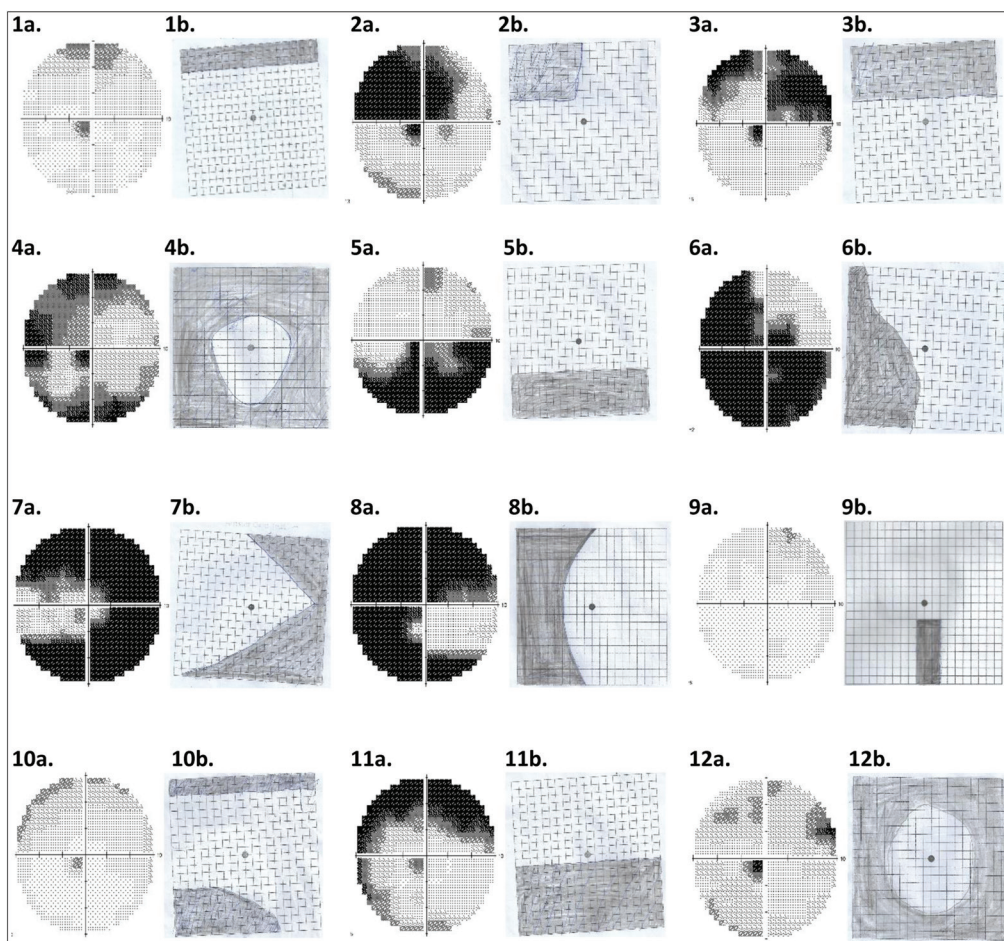
Figure 1: (a) Relationship between Amsler grid scotoma area and 10-2 CVF MD. (b) Relationship between Amsler grid scotoma area and 10-2 CVF SE (number of test points with  $P < 1\%$  on total deviation). (c) Relationship between Amsler grid scotoma area and 10-2 SMD (the average total deviation of test point with  $P < 1\%$  on 10-2 CVF)

smartphones are more readily available when compared with computers, and its use with the 3D CTAG may be considered for future studies.

This study showed good agreement between the location of visual field defects on 10-2 CVF test and AGT within the hemi-fields ( $P < 0.001$ ), as also reported in a similar study.<sup>[24]</sup> In contrast, findings by Gessesse *et al.*<sup>[25]</sup> showed that there was no correlation between the hemi-field locations of the visual field defects on AGT and 10-2 CVF among patients with advanced glaucoma using both white-on-black and black-on-white Amsler grids. The marked visual field loss which involved their central vision might have led to inaccurate responses. Even in the current study, the visual field changes on HFA and Amsler grid did not correspond in some cases as demonstrated in Figure 2 (images 9–12).

This may be due to certain patient factors such as severe vision loss, leading to difficulty in reproducing the perceived scotoma on the Amsler grid chart.

The 10-2 MD had the best agreement with the Amsler grid scotoma area, although it had moderate correlation ( $R^2 = 0.579$ ). This implies that the Amsler grid scotoma area increased as disease severity worsened; hence, there is a possibility of using the Amsler grid in monitoring disease progression. However, future longitudinal studies are needed to further elucidate this utility. The Amsler grid scotoma area increased with an increase in the number of depressed points with  $P < 1\%$  on 10-2 total deviation (SE), although there was poor agreement ( $R^2 = 0.370$ ). Additionally, the average sensitivity of the depressed points on total deviation (SMD,  $R^2 = 0.307$ ) had poor agreement



**Figure 2:** Scanned images of the grey scale of the 10-2 CVF test (a) with the corresponding perceived scotoma on AGT (b) as drawn by the patients with different severities of POAG in 12 patients (1–12). The shaded area on the Amsler grid represents the Amsler scotoma area. Images 1–4 have good correlation between the grey scale on the 10-2 CVF test and the scotoma area drawn on the Amsler grid by the participants. Images 5–8 have some correlation, whereas images 9–12 have no correlation

with the Amsler grid scotoma area. This may occur in the presence of other ocular conditions such as lens opacities, which may also cause depression on the total deviation map. Perhaps, using the pattern deviation map may be considered for calculating the SE and SMD in future studies.

Patients often present with advanced glaucoma in SSA,<sup>[5,6,34,35]</sup> due to the chronic asymptomatic nature of glaucoma, poor awareness and knowledge of the disease, as well as poor access to appropriate care. Hence, there is a need for a simple and effective tool which can be used within communities as well as in primary healthcare settings for identifying those at risk of glaucoma-related severe binocular vision loss for appropriate referral. The Amsler grid has been recommended as a home monitoring tool to detect new onset or progression of scotomas in age-related macular degeneration,<sup>[19,22,36]</sup> probably because of its ease of use by patients and high specificity. This can also be adopted in glaucoma care especially in low-resource settings to reduce the burden of visual impairment and blindness from glaucoma.

The present study shows that the Amsler grid has a high false negative rate (low sensitivity) in detecting central

glaucomatous visual field defects with higher proportions in the mild-to-moderate stages of POAG. Therefore, at these stages, the likelihood of Amsler grid detecting a visual field defect is low. Perhaps, combining the Amsler grid because of its high specificity with other examinations such as visual acuity assessment, tonometry, and funduscopy<sup>[18,37]</sup> where available in the primary healthcare setting and communities may improve its sensitivity in detecting mild-to-moderate POAG. Among patients with severe POAG, the sensitivity of the AGT was high. Conceivably, AGT may be useful in detecting severe POAG in which CVF testing may be difficult to perform either because of poor vision or unavailability of the visual field machine. It may detect widening of previous scotomas or new onset scotomas in patients with severe glaucoma and therefore may be relevant in monitoring progression in patients with advanced disease. Nevertheless, the presence of a scotoma on Amsler grid requires further evaluation. Hence, the Amsler grid may be a useful tool by primary eye care providers<sup>[38]</sup> in the community or eye outreach programmes in which facilities for conventional SAP may not be readily available for detecting CVF defects due to severe POAG.

The Amsler grid is a subjective test that is affected by several factors such as illumination of the room, an alterable test distance, participants' understanding of the instructions given among others, which may introduce some variation in the results. Certain patient factors such as severe vision loss or a co-existing neurological disease such as Parkinson's disease may affect the ability to draw the perceived scotoma on the Amsler grid charts accurately.

In conclusion, this study shows that the Amsler grid may be an effective tool in identifying patients with advanced glaucoma who have the highest risk of glaucoma-related blindness. It may serve as a cost-effective tool in resource-scarce settings for the detection of severe previously undiagnosed glaucoma in the community by primary eye care providers or for monitoring patients with severe glaucoma unable to perform SAP. It may also serve as a useful tool to describe visual field loss to patients with severe POAG, in order to enhance counselling and drug adherence.

### Acknowledgement

We appreciate the Oyin Odutola-Olurin Centre for Glaucoma Cure and Research and the Sebastian Centre for Ophthalmological Research and Education (SCORE) for part funding the 24-2 and 10-2 central visual field tests.

### Financial support and sponsorship

Nil.

### Conflicts of interest

There are no conflicts of interest.

### References

1. Quigley HA, Broman AT. The number of people with glaucoma worldwide in 2010 and 2020. *Br J Ophthalmol* 2006;90:262-7.
2. Tham YC, Li X, Wong TY, Quigley HA, Aung T, Cheng CY. Global prevalence of glaucoma and projections of glaucoma burden through 2040: A systematic review and meta-analysis. *Ophthalmology* 2014;121:2081-90.
3. Pascolini D, Mariotti SP. Global estimates of visual impairment: 2010. *Br J Ophthalmol* 2012;96:614-8.
4. Weinreb RN, Friedman DS, Fechtner RD, Cioffi GA, Coleman AL, Girkin CA, et al. Risk assessment in the management of patients with ocular hypertension. *Am J Ophthalmol* 2004;138:458-67.
5. Adekoya BJ, Shah SP, Onakoya AO, Ayanniyi AA. Glaucoma in southwest Nigeria: Clinical presentation, family history and perceptions. *Int Ophthalmol* 2014;34:1027-36.
6. Omoti AE, Osahon AI, Waziri-Erameh MJ. Pattern of presentation of primary open-angle glaucoma in Benin city, Nigeria. *Trop Doct* 2006;36:97-100.
7. Blumberg DM, De Moraes CG, Liebmann JM, Garg R, Chen C, Theventhiran A, et al. Technology and the glaucoma suspect. *Invest Ophthalmol Vis Sci* 2016;57:OCT80-5.
8. Blumenthal EZ, Sample PA, Berry CC, Lee AC, Girkin CA, Zangwill L, et al. Evaluating several sources of variability for standard and swap visual fields in glaucoma patients, suspects, and normals. *Ophthalmology* 2003;110:1895-902.
9. Adekoya BJ, Shah SP, Adepoju FG. Managing glaucoma in Lagos State, Nigeria—Availability of human resources and equipment. *Niger Postgrad Med J* 2013;20:111-5.
10. Jampel HD, Singh K, Lin SC, Chen TC, Francis BA, Hodapp E, et al. Assessment of visual function in glaucoma: A report by the American Academy of Ophthalmology. *Ophthalmology* 2011;118:986-1002.
11. Zhang X, Dastiridou A, Francis BA, Tan O, Varma R, Greenfield DS, et al.; Advanced Imaging for Glaucoma Study Group. Comparison of glaucoma progression detection by optical coherence tomography and visual field. *Am J Ophthalmol* 2017;184:63-74.
12. Traynis I, De Moraes CG, Raza AS, Liebmann JM, Ritch R, Hood DC. Prevalence and nature of early glaucomatous defects in the central 10° of the visual field. *JAMA Ophthalmol* 2014;132:291-7.
13. Grillo LM, Wang DL, Ramachandran R, Ehrlich AC, De Moraes CG, Ritch R, et al. The 24-2 visual field test misses central macular damage confirmed by the 10-2 visual field test and optical coherence tomography. *Transl Vis Sci Technol* 2016;5:15.
14. De Moraes CG, Hood DC, Thenappan A, Girkin CA, Medeiros FA, Weinreb RN, et al. 24-2 visual fields miss central defects shown on 10-2 tests in glaucoma suspects, ocular hypertensives, and early glaucoma. *Ophthalmology* 2017;124:1449-56.
15. Hood DC, De Moraes CG. Four questions for every clinician diagnosing and monitoring glaucoma. *J Glaucoma* 2018;27:657-64.
16. Nguyen DT, Fahimi A, Fink W, Nazemi PP, Kim JK, Sadun AA. Novel 3D computer-automated threshold Amsler grid visual field testing of scotomas in patients with glaucoma. *Eur J Ophthalmol* 2009;19:776-82.
17. Crabb DP, Smith ND, Glen FC, Burton R, Garway-Heath DF. How does glaucoma look?: Patient perception of visual field loss. *Ophthalmology* 2013;120:1120-6.
18. Ariyasu RG, Lee PP, Linton KP, LaBree LD, Azen SP, Siu AL. Sensitivity, specificity, and predictive values of screening tests for eye conditions in a clinic-based population. *Ophthalmology* 1996;103:1751-60.
19. Schuchard RA. Validity and interpretation of Amsler grid reports. *Arch Ophthalmol* 1993;111:776-80.
20. Do DV. Detection of new-onset choroidal neovascularization. *Curr Opin Ophthalmol* 2013;24:244-7.
21. Augustin AJ, Offermann I, Lutz J, Schmidt-Erfurth U, Tornambe P. Comparison of the original Amsler grid with the modified Amsler grid: Result for patients with age-related macular degeneration. *Retina* 2005;25:443-5.
22. Amsler M. Earliest symptoms of diseases of the macula. *Br J Ophthalmol* 1953;37:521-37.
23. Fujitani K, Su D, Ghassibi MP, Simonson JL, Liebmann JM, Ritch R, et al. Assessment of patient perception of glaucomatous visual field loss and its association with disease severity using Amsler grid. *PLoS ONE* 2017;12:e0184230.
24. Su D, Greenberg A, Simonson JL, Teng CC, Liebmann JM, Ritch R, et al. Efficacy of the Amsler grid test in evaluating glaucomatous central visual field defects. *Ophthalmology* 2016;123:737-43.
25. Gessesse GW, Tamrat L, Damji KF. Amsler grid test for detection of advanced glaucoma in Ethiopia. *PLoS ONE* 2020;15:e0230017.
26. Sullivan-Mee M, Karin Tran MT, Pensyl D, Tsan G, Katiyar S. Prevalence, features, and severity of glaucomatous visual field

- loss measured with the 10-2 achromatic threshold visual field test. *Am J Ophthalmol* 2016;168:40-51.
27. Brusini P, Johnson CA. Staging functional damage in glaucoma: Review of different classification methods. *Surv Ophthalmol* 2007;52:156-79.
  28. Crossland M, Rubin G. The Amsler chart: Absence of evidence is not evidence of absence. *Br J Ophthalmol* 2007;91:391-3.
  29. Ramachandran VS, Gregory RL. Perceptual filling in of artificially induced scotomas in human vision. *Nature* 1991;350:699-702.
  30. Armaly MF. The size and location of the normal blind spot. *Arch Ophthalmol* 1969;81:192-201.
  31. Wall M, Sadun AA. Threshold Amsler grid testing. Cross-polarizing lenses enhance yield. *Arch Ophthalmol* 1986;104:520-3.
  32. Nazemi PP, Fink W, Lim JI, Sadun AA. Scotomas of age-related macular degeneration detected and characterized by means of a novel three-dimensional computer-automated visual field test. *Retina* 2005;25:446-53.
  33. Nazemi PP, Fink W, Sadun AA, Francis B, Minckler D. Early detection of glaucoma by means of a novel 3d computer-automated visual field test. *Br J Ophthalmol* 2007;91:1331-6.
  34. Kyari F, Adekoya B, Abdull MM, Mohammed AS, Garba F. The current status of glaucoma and glaucoma care in Sub-Saharan Africa. *Asia-Pacific J Ophthalmol* 2018;7:375-86.
  35. Abdu L. Epidemiological properties of primary open angle glaucoma in Nigeria. *J Ophthalmol* 2013:1-6.
  36. Trevino R, Kynn MG. Macular function surveillance revisited. *Optometry* 2008;79:397-403.
  37. Wilson MR, Khanna S. The value of different screening techniques for glaucoma. *Curr Opin Ophthalmol* 1994;5:69-75.
  38. Sharma P, Sample PA, Zangwill LM, Schuman JS. Diagnostic tools for glaucoma detection and management. *Surv Ophthalmol* 2008;53(Suppl. 1):17-32.