


HOSTED BY



ELSEVIER

Contents lists available at ScienceDirect

International Journal of Pediatrics and Adolescent Medicine

journal homepage: <http://www.elsevier.com/locate/ijpam>

Case report

Beyond a routine blood gas, an easily picked but missed diagnosis of chronic Encephalopathy

Haya S. AlFaris^{a, b}, Ghasan Elhissi^c, Aziza Chedrawi^b, Mohammad A. Al-Muhaizea^{a, b, *}^a College of Medicine, Alfaisal University, Riyadh, Saudi Arabia^b Division of Pediatric Neurology, Department of Neurosciences, King Faisal Specialist Hospital and Research Centre, Riyadh, Saudi Arabia^c Department of Pediatrics, King Khaled University Hospital, King Saud University, Riyadh, Saudi Arabia

ARTICLE INFO

Article history:

Received 29 October 2019

Received in revised form

19 December 2019

Accepted 7 January 2020

Available online 17 January 2020

Keywords:

Methemoglobinemia

Microcephaly

Developmental delay

ABSTRACT

Recessive congenital methemoglobinemia (RCM) is a rare neurological disorder caused by a deficiency in NADH-CYB5R. RCM has two main types I&II, with cyanosis being the hallmark feature in both. Type-I is a mild form, with cyanosis being the only feature. While type-II is the severe form with prominent neurological symptoms including, dystonia and spasticity. However, the cyanosis is subtle and difficult to appreciate. The cyanosis in RCM is treated with ascorbic-acid or methylene-blue. However, those treatments will not alter the neurological complication. In this paper, we report two cases of RCM type-II in Saudi siblings. They presented with cyanosis at birth; a CO-oximetry was done showing a high level of methemoglobin and a trail of methylene blue was used. The siblings were followed up and showed signs of developmental delay, hypotonia, exaggerated reflex, and seizure. A genetic analysis was requested, which showed missense mutation (c.274 C > T), leading to amino acid substitution; p. Arg92Trp.

© 2020 Publishing services provided by Elsevier B.V. on behalf of King Faisal Specialist Hospital & Research Centre (General Organization), Saudi Arabia. This is an open access article under the CC BY-NC-ND license (<http://creativecommons.org/licenses/by-nc-nd/4.0/>).

1. What this paper adds

- First reported cases of RCM type-II in Saudi Arabia, with a novel mutation in CYB5R gene.
- The subtleness of cyanosis in RCM type-II can be easily missed, emphasize the importance of considering this diagnosis in any child with dyskinetic cerebral palsy, particularly patients with a combination of epilepsy, dystonia, spasticity, and acquired microcephaly.

2. Introduction

Methemoglobin (MetHB) is a form of hemoglobin that is produced when the ferrous iron (Fe+2) is oxidized into ferric iron (Fe+3) [1,2]. In normal physiological settings, MetHB remains below 1% through the nicotinamide adenine dinucleotide-

cytochrome b5 reductase system, which converts the Fe+3 back to Fe+2 [1]. Recessive congenital methemoglobinemia (RCM) is a rare disorder characterized by the decreased NADH-CYB5R enzyme, leading to the accumulation of MetHB in the body [3].

CYB5R is encoded by the CYB5R3 gene, located in chromosome 22q12-qter [4]. It is present in two main forms in the body: the soluble and membrane-bound form [1,4]. The soluble form is composed of 275 amino acids and plays a role in reducing the Fe+3 to Fe+2 within the RBC. Patients who have a deficiency in the soluble form have RCM type-I [1]. The membrane-bound form is present in the endoplasmic reticulum and mitochondria and is composed of 300 amino acids [3]. It plays a role in lipid synthesis, elongation, and drug metabolism [3,5]. Deficiency in both membrane-bound and soluble forms results in RCM type-II [4]. Type-I is a mild form that presents with cyanosis and no neurological sequelae [1]. Type-II is the severe form of the disease where the cyanosis is very subtle and might be difficult to appreciate in patients with dark skin [1]. They have severe neurological symptoms like seizures, spasticity, acquired microcephaly, and dystonia [1,5].

RCM type-II is a rare disorder that has never been described in the Middle East. In this paper, we report the detailed clinical, laboratory, and radiological findings of two siblings in the age group of

* Corresponding author. Dept. of Neurosciences (MBC76), KFSH&RC, P.O. Box 3354, Riyadh, 11211, Saudi Arabia.

E-mail address: mmuhaizea@kfshrc.edu.sa (M.A. Al-Muhaizea).

Peer review under responsibility of King Faisal Specialist Hospital & Research Centre (General Organization), Saudi Arabia.

9 and 24 months presenting with RCM type-II. We aim to highlight the importance of early diagnosis with simple methods, such as measuring the MetHB.

3. Case report

3.1. Patient 1

B1 was a 2-year-old boy, born at term following uncomplicated pregnancy and normal delivery. He was discharged home with the mother on the second day. His head circumference at birth was 33 cm (on the 10th centile). His other growth parameters were also at 10th percentile for his age. He was the first child to a second degree consanguineous Saudi couple. At 4 months of age, the patient started to have fisting of the hands and flexion of the arms with an increase in muscle tone. An initial EEG at the age of 10 months showed epileptiform discharges for which the patient was started on Levetiracetam with no improvement. No MRI or CT was obtained at the referring hospital.

Furthermore, the patient failed to develop appropriate milestones for his age. He had poor head control at 2 months, was unable to sit with or without support, and was unable to rollover or grab objects by 6–9 months. He was unable to stand or crawl by 12 months. Also, he did not babble at 6 months, or produce a single word by 12 months of age, and was only able to coo. Physical examination at 13 months showed microcephaly (40.5 cm, below the 3rd centile). He had severe head lag with truncal hypotonia and appendicular spasticity. Deep tendon reflexes were brisk.

At the age of 22 months, the examination was remarkable for microcephaly (45 cm, below the 3rd centile), spastic, and dystonic limbs with brisk deep tendon reflexes. He had no language skills apart from crying and making moaning sounds to his parents. Seizures were intractable and his dystonia was not responsive to dopamine supplementation. He was stroller bound and could not sit unsupported. Comprehensive metabolic testing was unremarkable. MRI of the brain done at 10 months of age showed white matter hypomyelination with atrophy of basal ganglia (Fig. 1A and B).

3.2. Patient 2

B2 was a 9-month-old boy, a product of uncomplicated pregnancy and delivery at term. He was the second affected child for the same couple. At birth, the patient had respiratory distress for which blood gas test was done. The blood gas test showed a high level of MetHB (18%) (reference value: $\leq 2.0\%$). He had cyanosis on the lips and tongue. A diagnosis of RCM was suspected, and the patient received weekly methylene blue injections for 6 weeks. This led to an improvement in cyanosis.

B2 was evaluated at our institute at the age of 8 weeks. No history of abnormal movements and the child was not on any medications at that time. On physical examination, there were no dysmorphic features; the head circumference was 40.5 cm (on the 75th centiles). There was subtle cyanosis detected on the tongue and lip. The patient had occasional fisting of the hands and flexed postures of the arm. He had mildly increased tone with brisk reflexes and crossed adductor response. He had good head control when he was in a prone position.

At the age of 6 months, he lagged behind in terms of development. He could not sit with or without support, roll over, reach, or hold objects with his hands. He had a social smile and could only coo. On physical examination, the head circumference was below the 3rd centile (41 cm) and the cyanosis was no longer appreciated. The patient had severe head lag with appendicular spasticity.

An MRI was done at the age of three and a half months, which

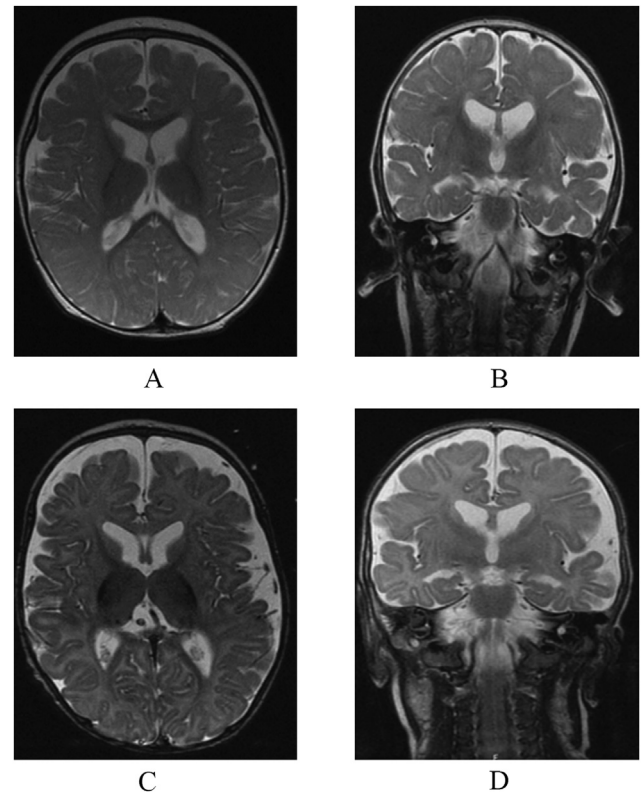


Fig. 1. T2 axial weighted magnetic resonance imaging (MRI) showing hypomyelination and hypoplasia of basal ganglia. Prominent extra-axial CSF spaces more prominent frontal and temporal regions. **1A and 1B** is an axial and coronal section of B1 at 10 months. **1C and 1D** is an axial and coronal section of B2 at three and a half months.

showed similar findings to B1 (Fig. 1C and D). MR single voxel-spectroscopy through the basal ganglia demonstrates no significant abnormalities for the patient's age. Also, ECHO obtained at 6 months of age showed a tiny patent foramen ovale.

After learning about the younger (B2) sibling's history, B1 was reexamined and it was found that he had subtle cyanosis on the lips, which was missed during the first encounter. A blood gas obtained from B1 showed increased MetHB of 16.6%. Interestingly, the cyanosis on B2 was very subtle and could easily be missed. This directed the diagnosis on B1. Genetic testing for methemoglobinemia type-II confirmed a novel homozygous mutation of the CYB5R gene in both siblings and a heterozygous state in both parents. The mutation was missense mutation (c.274 C > T), leading to amino acid substitution; p. Arg92Trp.

4. Discussion

Cyanosis is the first sign of RCM presenting at birth. It is highly apparent in the benign type-I RCM than the more severe type-II RCM. Furthermore, it becomes less appreciated with time in type-II, which is relevant to neurologists [6]. Routine blood gas tests do not include the determination of MetHB, therefore, more cases are probably missed. Attention to this fact by requesting a CO-oximetry will provide the answer, showing elevated levels of MetHB [2]. Both RCM types will present with a high level of MetHB at birth. However, type-I is a nonprogressive form with cyanosis being the only symptom. On the other hand, type-II presents with progressive neurological symptoms, thus requiring further follow-up. The different presentations in RCM types I&II could be attributed to different functions of the enzyme isoforms. The number of amino

acids of the membrane-bound enzyme is 25 amino acids longer than the soluble form of the enzyme [7,8].

Earlier reports suggested that missense mutations lead to type-I, while deletions and nonsense mutations lead to type-II RCM [6]. Our patients proved the opposite, as they had missense mutation leading to type-II RCM. Other reports also documented cases of type-I RCM with deletion-type mutations [9]. RCM types I&II are inherited as autosomal recessive disorders with a 25% recurrence risk in affected families [9].

The sequela of presentation varies among patients. In our patients, both of them presented with cyanosis, which was more prominent in the younger brother given the fact that he had respiratory distress at birth. Further follow-up of both siblings showed delay in fine and gross motor skills, hypotonia, and exaggerated reflex consistent with the literature on RCM type-II. Also, the older sibling presented with an intractable seizure. He had 3 seizure semiologies: eyelid myoclonic, tonic seizure with stiffness and cyanosis, and in severe cases, he develops generalized tonic-clonic seizures. An EEG at 13 months of age showed abundant epileptic discharge, multiregional with generalized intermittent slowing. However, seizures are uncommon in RCM type-II and are only reported in a few cases [5]. MRI findings are not specific and variable [1,4,5].

Type-I is easily treated with either ascorbic acid or methylene blue. However, type-II does not have a cure to this day. Treating cyanosis does not affect the neurological outcome. It is important to note that patients with type-II who present with seizure, hypotonia, and dystonia might be labeled as cerebral palsy [1]. Attention to acquired microcephaly and testing for MetHB level may be the best way to pick such cases, because all the usual imaging and metabolic testing would be unremarkable or nondiagnostic.

Our patient is added to the pathogenic mutation list of RCM type-II and represents the first case report from Saudi Arabia.

In conclusion, RCM type-II is a progressive neurological disorder with subtle clues. Attention to disease progression, acquired microcephaly, and testing for MetHB remain crucial. Pediatricians and pediatric neurologists need to consider this diagnosis in cases

of an undiagnosed or unexplained spastic and dyskinetic type of cerebral palsy.

Financial disclosures

No financial support declared.

Funding sources

No funding source declared.

Declaration of competing interest

No conflicts of interest declared.

References

- [1] Devadathan K, Sreedharan M, Sarasam S, Colah RB, Kunju PA. Neurometabolic disorder with microcephaly, dystonia, and central cyanosis masquerading as cerebral palsy. *J Child Neurol* 2014;29(11):NP139–N142.
- [2] Wright RO, Lewander WJ, Woolf AD. Methemoglobinemia: etiology, pharmacology, and clinical management. *Ann Emerg Med* 1999;34(5):646–56.
- [3] Percy MJ, McFerran NV, Lappin TR. Disorders of oxidised haemoglobin. *Blood Rev* 2005;19(2):61–8.
- [4] Warang PP, Kedar PS, Shanmukaiah C, Ghosh K, Colah RB. Clinical spectrum and molecular basis of recessive congenital methemoglobinemia in India. *Clin Genet* 2015;87(1):62–7.
- [5] Ewencyk C, Leroux A, Roubergue A, Laugel V, Afenjar A, Saudubray JM, et al. Recessive hereditary methaemoglobinaemia, type II: delineation of the clinical spectrum. *Brain* 2008;131(Pt 3):760–1.
- [6] Aalfs CM, Salieb-Beugelaar GB, Wanders RJ, Mannens MM, Wijburg FA. A case of methemoglobinemia type II due to NADH-cytochrome b5 reductase deficiency: determination of the molecular basis. *Hum Mutat* 2000;16(1):18–22.
- [7] Hultquist DE, Passon PG. Catalysis of methaemoglobin reduction by erythrocyte cytochrome B5 and cytochrome B5 reductase. *Nat New Biol* 1971;229(8):252–4.
- [8] Yubisui T, Miyata T, Iwanaga S, Tamura M, Takeshita M. Complete amino acid sequence of NADH-cytochrome b5 reductase purified from human erythrocytes. *J Biochem* 1986;99(2):407–22.
- [9] Fermo E, Bianchi P, Vercellati C, Marcello AP, Garatti M, Marangoni O, et al. Recessive hereditary methemoglobinemia: two novel mutations in the NADH-cytochrome b5 reductase gene. *Blood Cells Mol Dis* 2008;41(1):50–5.