



Systematic review and meta-analysis of the effect of nerve block under ultrasound in ilioinguinal/iliohypogastric in children

Junming Chen¹, Daiqiang Song², Guifeng Zheng², Yu Luo¹

¹Anesthesia Department, Taizhou Hospital of Zhejiang Province Affiliated to Wenzhou Medical University, Taizhou, China; ²Pediatric Department, Taizhou Hospital of Zhejiang Province Affiliated to Wenzhou Medical University, Taizhou, China

Contributions: (I) Conception and design: J Chen, Y Luo; (II) Administrative support: D Song; (III) Provision of study materials or patients: All authors; (IV) Collection and assembly of data: J Chen, D Song, G Zheng; (V) Data analysis and interpretation: J Chen, G Zheng, Y Luo; (VI) Manuscript writing: All authors; (VII) Final approval of manuscript: All authors.

Correspondence to: Yu Luo. Anesthesia Department, Taizhou Hospital of Zhejiang Province Affiliated to Wenzhou Medical University, No. 150, Ximen Street, Linhai, Taizhou, China. Email: q15824013914@163.com.

Background: Ilioinguinal/iliohypogastric nerve block (IINB) is a common operation in pediatric surgery. Nerve block under contrast-enhanced ultrasound (CEUS) has the advantages of visualization and noninvasiveness, which creates conditions for its application in nerve block. It can significantly improve the success rate of nerve block and reduce the complications of nerve block. At present, few studies in China have analyzed the effect of nerve block guided by ultrasound technology compared with ordinary treatment.

Methods: With “ilioinguinal/iliohypogastric nerve block”, “ultrasonic examination of the children”, and “ultrasonography for ilioinguinal/iliohypogastric” as the keywords, the related literature published before 2022 was searched. RevMan 5.3 and Stata provided by the Cochrane Collaboration were employed for analysis and evaluation. Begg’s risk of bias was utilized to assess the risk bias of the included references. Heterogeneity among studies was evaluated using the Q test and heterogeneity (I^2).

Results: Six studies were included, with a total of 391 cases. The overall risk (OR) of ilioinguinal/iliosubabdominal complications in children treated with nerve block after ultrasound examination was 0.49, and the complications of ilioventral/iliosubabdominal complications in children treated with nerve block after ultrasound examination were reduced. The OR of inhibiting pain events was 0.35, and the ilioinguinal/iliosubabdominal pain events were reduced after nerve block treatment by ultrasound examination. The OR of inhibiting adverse reactions was 0.45. After ultrasound examination, the adverse reactions of ilioinguinal/iliosubabdominal nerve block treatment were reduced, and there was no heterogeneity among the study groups ($I^2=0.00\%$).

Conclusions: The results of the meta-analysis confirmed that the complications of nerve block treatment after ultrasound examination were less than those of ordinary treatment. The incidence of pain events and adverse reactions in nerve block treatment were reduced after ultrasonography. Moreover, in terms of pain events, the effect of ultrasound guidance was significant. In short, in clinical studies, CEUS can be used to accurately evaluate complex situations and provide a more accurate reference for subsequent treatment.

Keywords: Inferior iliac abdomen; iliac groin; ultrasound examination; nerve block; meta-analysis

Submitted Jun 13, 2022. Accepted for publication Oct 10, 2022.

doi: 10.21037/tp-22-308

View this article at: <https://dx.doi.org/10.21037/tp-22-308>

Introduction

Ilioinguinal/iliohypogastric nerve block (IINB) is a clinically commonly used anesthetic technique used in iliac inguinal nerves and iliac stomach nervous feeling under the area of surgery. For groin surgery, i.e., inguinal hernia repair or orchiopexy, IINB is clinically as effective as caudal block (1-3). Ilioinguinal/subilioabdominal surgery is a common operation in pediatric surgery and is characterized by a large amount of surgery, young children, postoperative irritability, difficulty in cooperating, and a low satisfaction rate of parents with anesthesia (4,5). At the same time, the changes in physiological function during anesthesia, short operation time, and quick recovery after surgery make it difficult to administer anesthesia and intraoperative management. The incidence of agitation during the recovery period of general anesthesia is high in children and clinically manifests as inappropriate behavior during the recovery period of anesthesia, including excitement, agitation and disorientation, involuntary movements of limbs, crying, shouting, moaning, incoherent speech, and delusional thinking (6,7). In clinical practice, combined anesthesia is widely respected for its advantages of low dosage of anesthetics, rapid recovery after surgery, and low incidence of adverse reactions (8).

In recent years, contrast-enhanced ultrasound (CEUS) nerve block has been widely adopted in foreign countries, and increasing evidence-based medical data also support the role of ultrasound technology in regional anesthesia. Nerve stimulators appeared in the early 1980s. Although they have improved the success rate of nerve block to a certain extent, the puncture location and direction are mainly determined by body surface markers. For obesity, anatomical variation, and other conditions, puncture difficulties still occur, and even serious complications may occur (9). Under the guidance of ultrasound, the distribution and course of peripheral nerves, as well as the surrounding blood vessels and organs, can be observed, and the puncture localization is accurate, which avoids stray into blood vessels, thoracoperitoneum, and important organs. Moreover, the injection and diffusion process of local anesthetics can be observed, reducing the amount of local anesthetics, and the block effect is obvious and lasts for a long time (10,11). Nerve block by ultrasonography can block multiple small nerves or plexuses to achieve regional anesthesia and analgesia through the diffusion of local anesthetics in the musculofascial plane. General anesthesia combined with regional nerve block can not only meet the needs of the

operation but also reduce the amount of opioids used during the operation, which can provide satisfactory postoperative analgesia. Compared with traditional drugs and epidural analgesia, nerve block has fewer adverse reactions and satisfactory anesthetic and postoperative analgesia effects, making it an indispensable part of clinical anesthesia and analgesia work (12,13).

Ultrasound technology has the advantages of visualization and noninvasiveness, which creates conditions for its application in nerve block. It can significantly improve the success rate of nerve block and reduce the complications of nerve block (14-16). IINB can provide a good analgesic effect for inguinal area surgery. The site for traditional “fascial breakthrough” acupuncture is located on the upper side of the junction of the anterior and medial 1/3 of the iliac crest and on the rear side of the lateral cutaneous branch of the 12th thoracic nerve. The success rate is affected by the operator’s proficiency, and the success rate is generally only 70–80%. The use of local anesthetics was lower in the ultrasound-guided group than in the blind group, and only 4% of the children in the ultrasound group required additional anesthetics, compared with 26% in the blind group. Ultrasound-guided IINB can significantly improve the success rate, and relevant studies have shown that the incidence of adverse reactions is reduced from 24% to 12%, which can reduce complications such as local anesthetic poisoning, pelvic hematoma, and punctured intestinal tube (17,18). In recent years, it has been reported that iliohypogastric nerve block and human body inguinal nerve block combined with general anesthesia are ideal anesthesia methods for pediatric inguinal surgery. However, the traditional iliac nerve block is mainly performed by body surface positioning puncture, and there are certain risks in the process of puncture (19,20). At present, ultrasound technology has been introduced into pediatric anesthesia in foreign countries, and the effect has been unanimously recognized. Moreover, several medical centers have successfully carried out the application of ultrasound-guided iliosubabdominal and ilioinguinal nerve blocks in pediatric inguinal surgery, but there are few reports in China.

Therefore, the current domestic and foreign literature on ultrasound-guided ilioinguinal/hypoilioabdominal nerve block were innovatively included in this study to systematically evaluate and compare the effect of ultrasound-guided nerve block and common treatment on IINB in children by meta-analysis to evaluate the advantages of ultrasonography in IINB and to provide a theoretical reference for the treatment of IINB. We present

the following article in accordance with the PRISMA reporting checklist (available at <https://tp.amegroups.com/article/view/10.21037/tp-22-308/rc>).

Methods

Literature search

PubMed, MEDLINE, EBSCO, Science Direct, Cochrane Library, and China National Knowledge Infrastructure (CNKI) were searched to retrieve relevant articles published from January 2000 to January 2022 using the following search terms: “ilioinguinal/iliohypogastric nerve block”, “ultrasonic examination of children”, and “ultrasonography for ilioinguinal/iliohypogastric”. Manual retrieval of some professional journals when necessary to prevent omissions. The research objects of literature retrieval are all human beings.

During the search process, multiple word combinations of related topics were used to search for references that could be included in the systematic analysis, and a search engine was then used to trace each article. The quality of the included articles was assessed using RevMan 5.3 provided by the Cochrane Collaboration.

Literature inclusion and exclusion criteria

Inclusion criteria: (I) studies on IINB; (II) all studies were randomized controlled trials; (III) patients were children: younger than 18 years old; (IV) the overall risk (OR) of the therapeutic effect can be obtained directly or indirectly in the study; (V) the sample size in the study was greater than 10 cases.

Exclusion criteria: (I) reports, reviews, conferences, journals, evaluations, etc.; (II) no ultrasound guidance or other block as the main treatment instead of nerve block in the study; (III) literature with fewer than 10 subjects; (IV) literature without sufficient data to determine outcome indicators.

Data extraction

Literature screening and data extraction were independently performed by two professionals using unified Microsoft Excel (Microsoft, the United States) and cross-checked and included the final desired outcome indicators. If there was any disagreement, it was resolved through discussion. The main extracted data included (I) general information about

the included studies: title, first author, publication year, etc. (II) basic characteristics of the research subjects: number of cases, detection methods, etc.; and (III) outcome indicators that can be obtained indirectly or directly in the study.

Literature appraisal criteria

The Cochrane (USA) recommended version 2 of the Cochrane Tool for Estimating Risk of Bias in RCTs was used. Trial, RoB2 criteria evaluated the quality of the included literature. The quality of the included original literature was evaluated according to each evaluation index, and each study was evaluated according to “low risk”, “high risk”, and “uncertain”.

Statistical methods

RevMan 5.3 (Cochrane, USA) and Stata (Stata Corp, USA) were used to evaluate the risk bias of the included references using the risk of bias assessment map. The Q test and heterogeneity (I^2) were used to evaluate the heterogeneity among studies. The complications, pain events, and adverse reactions of CEUS-guided nerve block were calculated and compared with the 95% confidence interval (CI). Forest plots and funnel plots were drawn for the heterogeneity test, and asymmetric linear regression plots were drawn for the publication bias test.

Results

Search results and basic information of the literature

A total of 275 articles were obtained by searching databases. First, 8 duplicate publications were excluded, 94 unqualified articles and 23 articles were excluded for other reasons, and the remaining 150 articles were initially selected. After reading the abstracts and titles, 37 articles were excluded, and 113 articles remained. Sixty-two research reports and review articles were excluded, leaving 51 articles. After reading the full text of all the remaining articles one by one, 21 articles with incorrect research types were excluded; 16 articles were excluded if the required treatment results were incomplete or unavailable; eight articles were not included in the study of children with ilioinguinal/iliac hypogastric nerve block, and six articles were finally included in the meta-analysis. *Figure 1* shows a flow chart for searching the literature.

The basic information of the included literature was

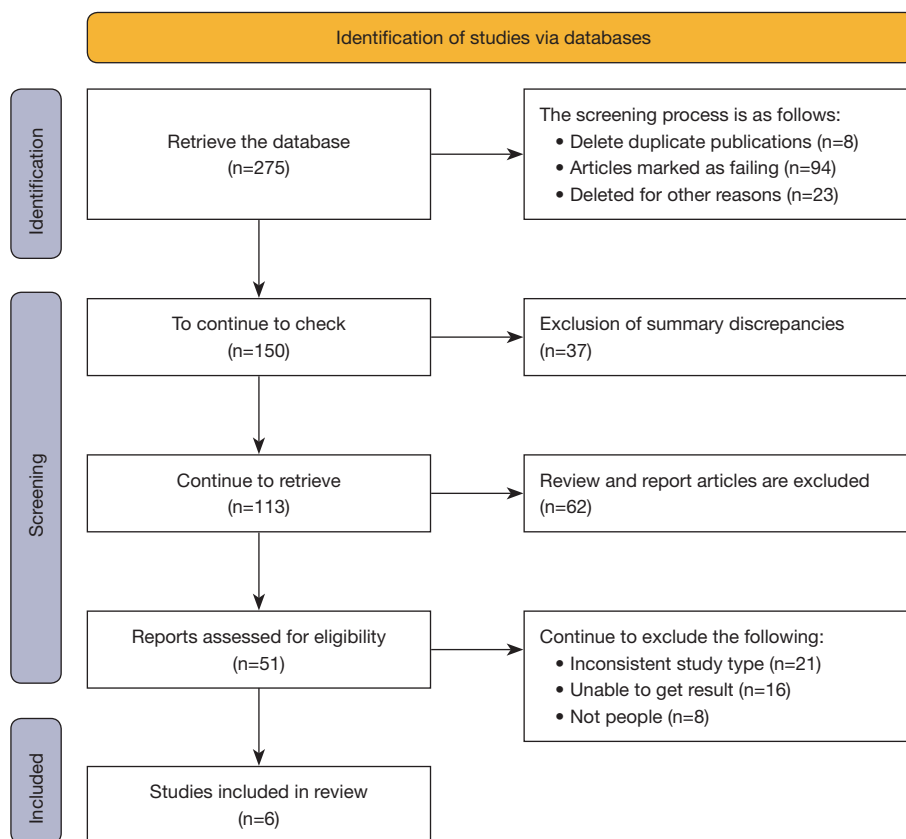


Figure 1 The reference retrieval process of this study.

Table 1 Basic information and data of the included literature

Author	Year	Cases	Processing method	Age (years)
Flack (21)	2014	40	CEUS	4–17
Grosse (22)	2020	103	CEUS	<1
Harju (23)	2016	30	CEUS	2
Markham (24)	1986	52	CEUS	1–12
Weintraud (25)	2009	66	CEUS	>8
Willschke (26)	2005	100	CEUS	>2

CEUS, contrast-enhanced ultrasound.

extracted by reading the content of the literature. Among the 6 included studies (21-26), 244 cases were examined and treated by CEUS, and 237 cases were treated by other methods. In addition, the sample size of the 6 included studies varied from 10 to 103. The quality evaluation of the 6 included articles showed that 4 articles (66.67%) were rated as grade A, 1 article (16.67%) was rated as grade

B, and 1 article (16.67%) was rated as grade C. *Table 1* shows the basic characteristics of the included literature. *Figures 2,3* show the evaluation chart of reference risk bias and summary chart of reference risk bias drawn by RevMan 5.3, respectively.

Heterogeneity assessment results

The heterogeneity of the included literature (21-26) was evaluated, and the results showed that there was no heterogeneity among the studies in terms of complications of nerve block treatment after ultrasound examination ($I^2=0.00\%$). There was no heterogeneity among studies ($I^2=0.00\%$) in pain response to nerve block after ultrasound examination. There was no heterogeneity among studies ($I^2=0.00\%$) in the adverse reactions of nerve block after ultrasound examination. To further verify the heterogeneity of the treatment effect after ultrasound examination and compare the differences in indicators of different treatment methods, a random effect model was used for summary

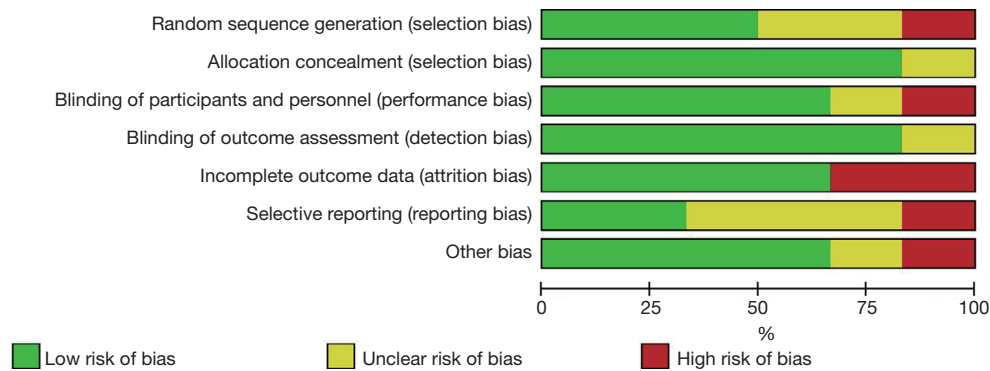


Figure 2 Bibliographic risk bias assessment chart drawn by RevMan 5.3.




Figure 3 Summary graph of reference risk bias. “+” indicates low risk; “-” indicates high risk; and “?” indicates unclear risk.

analysis and funnel plot fitting.

Meta-analysis of complications of nerve block after ultrasound examination

The OR was taken as a clinical outcome indicator. In Figure 4, the OR of 6 cases of ilioinguinal/iliosubabdominal

complications in children treated with nerve block after ultrasound examination was 0.49, 95% CI was (0.31, 0.79), $I^2=0.00\%$, $P=0.99$. The OR showed fewer complications in IINB treatment after ultrasonography, with no heterogeneity between study groups. The lowest OR was 0.31, 95% CI was (0.05, 1.93), and the highest OR was 0.62, 95% CI was (0.24, 1.63). To further observe the effect of the treatment, a comprehensive analysis of the stability of the treatment was carried out. Figures 5,6 show the stability heterogeneity of the nerve block after ultrasound. Assessing the heterogeneity and potential outlier value among the studies, it was found that the heterogeneity gap between studies was small and the accuracy was high. Figure 7 shows a funnel plot of the stability of nerve block therapy after ultrasonography. It can be observed that the risk of bias in each study was small. According to the above results, the stability of nerve block treatment after ultrasonography was better in the treatment of children’s ilioinguinal/iliac hypogastric; on the other hand, data from individual studies on the stability of nerve block therapy after ultrasonography were better than those of normal therapy. Therefore, in terms of the stability of treatment, the effect of treatment after ultrasound examination was better.

Meta-analysis of pain events after nerve block therapy after ultrasonography

The OR was taken as a clinical outcome indicator. In Figure 8, the OR of ilioinguinal/iliosubabdominal pain suppression events in 6 children treated with nerve block after ultrasound examination was 0.35, 95% CI was (0.21, 0.59), $I^2=0.00\%$, $P=0.95$. The OR showed a reduction in ilioinguinal/iliosubabdominal pain events with nerve block after ultrasound examination, with no heterogeneity

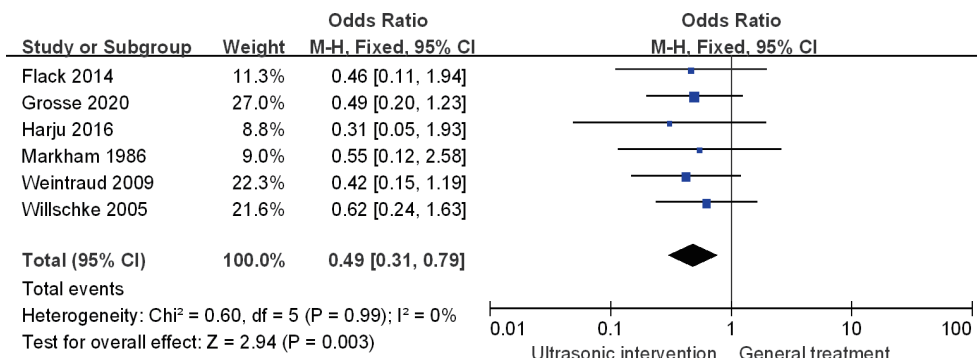


Figure 4 Forest plot of complications of nerve block after ultrasonography. CI, confidence interval; df, degrees of freedom.

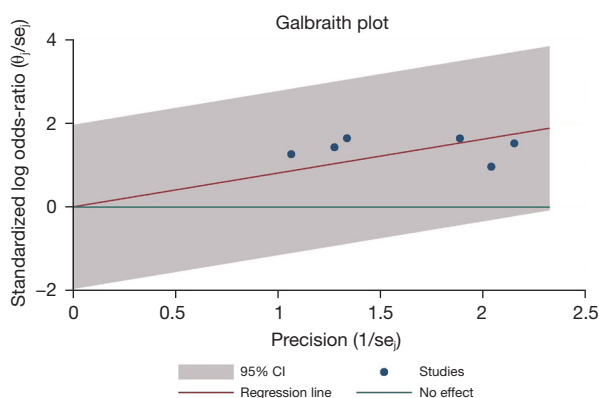


Figure 5 Galbraith heterogeneity test for complications of nerve block after ultrasonography. se, estimated σ ; CI, confidence interval.

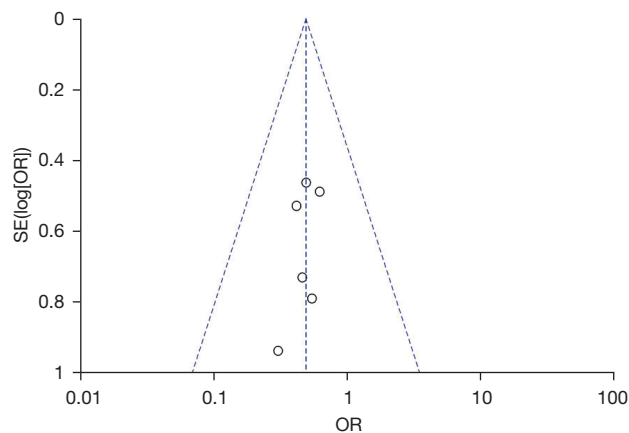


Figure 7 Funnel plot of a complication of nerve block after ultrasonography. SE, standard error; OR, overall risk.

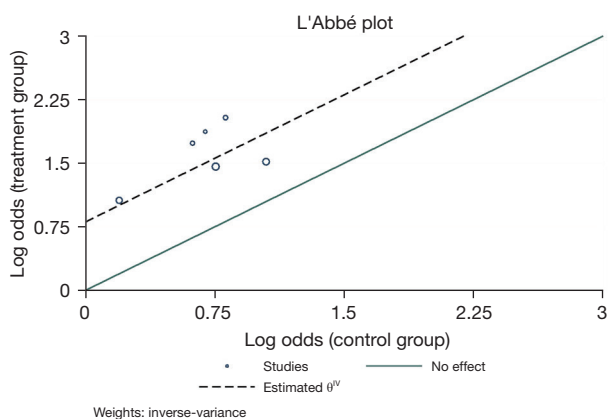


Figure 6 Labbe heterogeneity test for complications of nerve block treatment after ultrasonography.

between study groups. The lowest OR value was 0.25, the 95% CI was (0.07, 0.82), and the highest OR value was 0.50, the 95% CI was (0.13, 1.93). To further observe the effect of the treatment, a comprehensive analysis of the pain events was carried out. *Figures 9,10* show the heterogeneity test diagrams of the pain events of the nerve block treatment after the ultrasound examination. Assessing the heterogeneity and potential outlier value among the studies, it was found that the heterogeneity gap between studies was small and the accuracy was high. *Figure 11* shows a funnel plot of pain events with nerve block therapy after ultrasonography. It can be observed that the risk of bias in each study was small. Based on the above results, the incidence of pain events after nerve block therapy after ultrasonography was lower in the

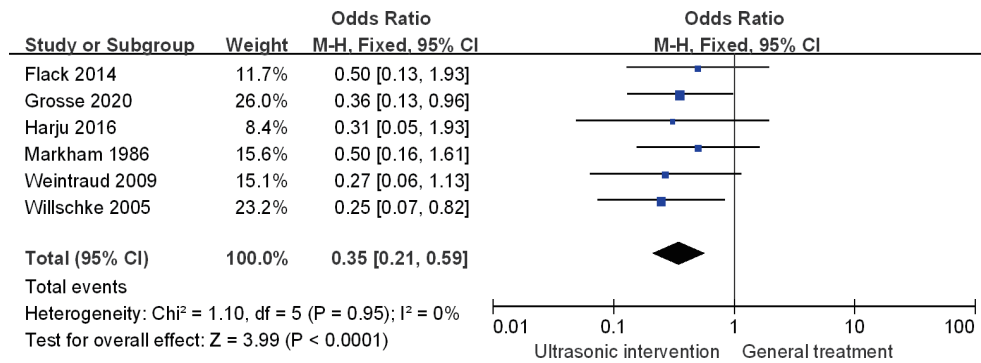


Figure 8 Forest plot of the effects of nerve block treatment on pain events after ultrasonography. CI, confidence interval; df, degrees of freedom.

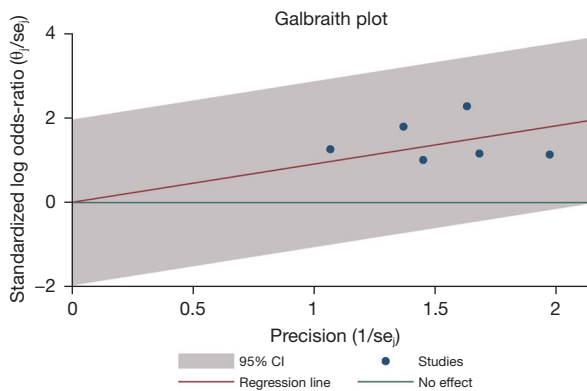


Figure 9 Galbraith heterogeneity test for the effects of nerve block on pain events after ultrasonography. se_i , estimated σ_i ; CI, confidence interval.

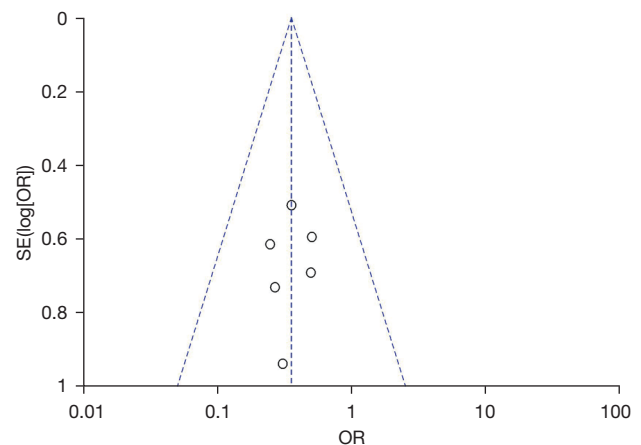


Figure 11 Funnel plot of the effect of nerve block on pain events after ultrasonography. SE, standard error; OR, overall risk.

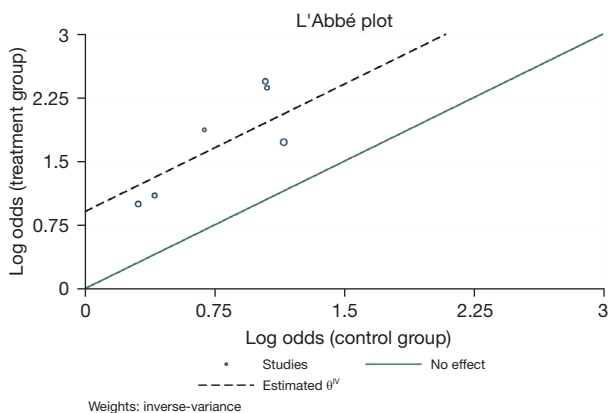


Figure 10 Labbe heterogeneity test for the effect of nerve block on pain events after ultrasonography.

ilioinguinal/iliac hypogastric treatment of children. On the other hand, data from individual studies on the incidence of pain events with nerve block therapy after ultrasonography were lower than those with normal treatment. Therefore, in terms of the occurrence of pain events treated, the effect of treatment after ultrasonography was better.

Meta-analysis of adverse reactions to nerve block therapy after ultrasonography

The OR was taken as the clinical outcome indicator. In *Figure 12*, the OR of the adverse reactions of ilioinguinal/ iliosubabdominal inhibition in 6 children treated with nerve

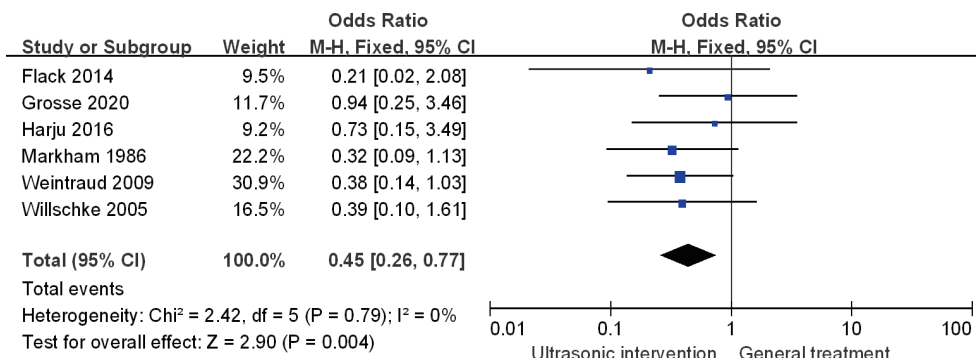


Figure 12 Forest plot of adverse effects of nerve block after ultrasonography. CI, confidence interval; df, degrees of freedom.

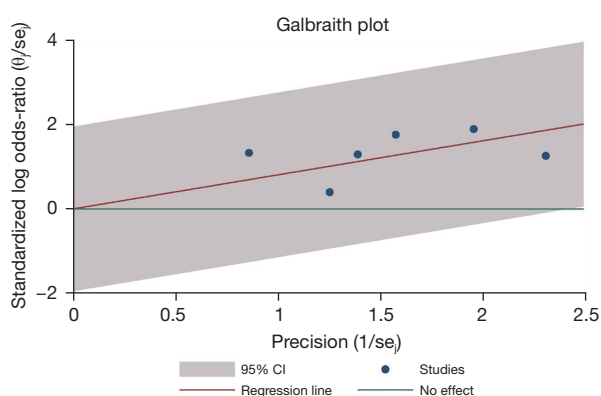


Figure 13 Galbraith heterogeneity test for adverse effects of nerve block after ultrasonography. se, estimated σ ; CI, confidence interval.

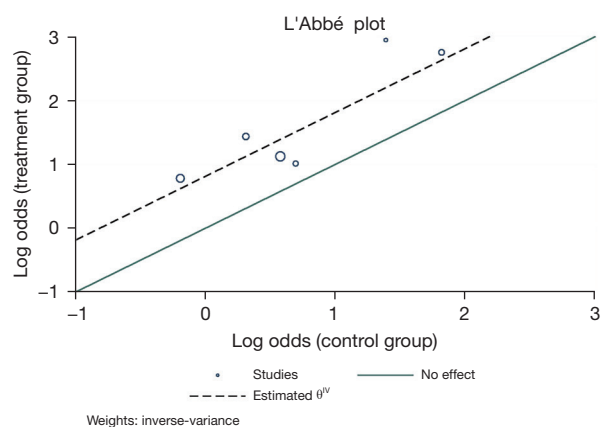


Figure 14 Labbe heterogeneity test for adverse effects of nerve block after ultrasonography.

block after ultrasound examination was 0.45, 95% CI was (0.26, 0.77), $I^2=0.00\%$, $P=0.79$. The OR value showed that the adverse events of IINB treatment were reduced after ultrasound examination, and there was no heterogeneity among the study groups. The lowest OR value was 0.21, the 95% CI was (0.02, 2.08), and the highest OR value was 0.94, the 95% CI was (0.25, 3.46). To further observe the effect of the treatment, a comprehensive analysis of the adverse reactions of the treatment was carried out. *Figures 13,14* show the heterogeneity of the adverse reactions to nerve block after ultrasound examination. Assessing the heterogeneity and potential outlier value among the studies, it was found that the heterogeneity gap between studies was small and the accuracy was high. *Figure 15* shows a funnel plot of adverse reactions to nerve block therapy after ultrasound examination. It can be observed that the risk of bias in each study was small. According to the above results, the adverse reactions of nerve block treatment after ultrasound examination were reduced in children with ilioinguinal/iliac hypogastric treatment; on the other hand, there are fewer single-study data on adverse effects of nerve block therapy after ultrasonography than with normal therapy. Therefore, in terms of adverse reactions to treatment, the effect of treatment after ultrasound examination was better.

Reliability analysis

The reliability analysis was performed by changing the analysis model. The results of the meta-analysis showed that there was no significant change in the summary results

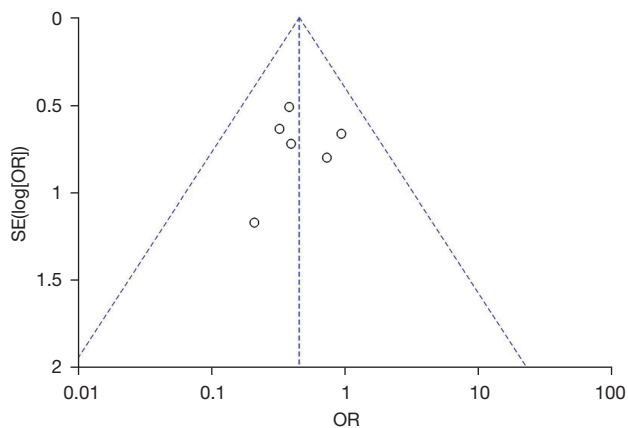


Figure 15 Funnel plot of adverse effects of nerve block after ultrasonography. SE, standard error; OR, overall risk.

of different analysis models, indicating that the included literature had good stability. Model analysis, such as funnel asymmetric linear regression analysis, can also show that the consistency of treatment effect verification is good.

Discussion

Children do not have mature physiological function, and their tolerance to anesthesia is poor. The statistical data show that the mortality rate of children who receive general anesthesia is 16.7 times that of children who receive regional anesthesia (27). Thus, higher quality control requirements have been put forward for the administration of anesthesia during surgery in children. At present, for lower abdominal surgery in young children, it has begun to explore the clinical application of nerve block combined with anesthesia sedation to meet the anesthesia required by surgery while providing adequate and appropriate sedation and improving the safety and comfort of anesthesia. Combining anesthesia with multimodal pain relief has become a trend in surgery. The use of a nerve block under CEUS provides regional anesthesia and pain relief by diffusing local anesthetics in the muscle fascia plane to block multiple small nerves or nerve plexuses. Intraoperative general anesthesia combined with a regional nerve block not only meets the needs of surgery but also reduces the dose of opioids required during surgery while providing satisfactory postoperative analgesia.

In recent years, CEUS technology has been widely used in peripheral nerve blocks and has become the “gold standard” for peripheral nerve localization. Ultrasound-guided peripheral nerve block has the advantage of

visualization. After preliminary scanning by ultrasound, the target nerve, nearby blood vessels, and important organ tissues can be clearly observed. After adjusting the positional relationship between the target nerve and ultrasound imaging, a nerve block needle is placed after the puncture site has been selected; the puncture needle and target nerve are clearly visible under real-time ultrasound guidance, and the puncture needle is advanced around the target nerve. This needle insertion method can display the path and direction of needle insertion and the direction of the needle body and needle tip on the ultrasound imaging screen and can guide the movement direction, depth, and angle of the needle body in a timely manner according to the positional relationship between the nerve block needle and target nerve (28). When the nerve block needle is advanced to the vicinity of the target nerve, the syringe is withdrawn, drawing no blood or tissue fluid, and the local anesthetic is then injected. When the drug solution is observed to surround the nerve, all the remaining previously pumped local anesthetics are injected, and the injection state of the local anesthetics is observed at the same time. This peripheral nerve block technique significantly improves. This peripheral nerve block technique has the characteristics of reducing the incidence of complications while significantly improving the success rate, making nerve block safer, easier, and more effective (29-31).

By comparison, it was found that the complications of nerve block treatment after ultrasound examination were less than the effect of ordinary treatment. The incidence of pain events and adverse reactions in nerve block treatment were reduced after ultrasonography. This is consistent with the outcome of many studies. According to the research results, after ultrasound examination, the complications of treatment can be significantly improved, which means that ultrasound examination can better guarantee a smooth operation and improve the treatment effect. In summary, this meta-analysis synthesized and evaluated the efficacy of conventional ultrasound and CEUS in the treatment of IINB, which can provide evidence-based recommendations for clinical practice guidelines. In clinical studies, on the basis of ordinary treatment, ultrasound examination can be used to accurately evaluate the complex situation to provide a more accurate reference for subsequent treatment.

Conclusions

In this study, literature related to the diagnosis and treatment of IINB was screened and included in the meta-analysis,

aiming to explore the therapeutic effect of IINB guided by ultrasound. Meta-analysis confirmed that ultrasound-guided treatment had a better effect, and its OR value was higher than that of conventional treatment. However, for the changes in plasma concentration and other biochemical indexes of CEUS in IINB, more in-depth studies are needed, and more samples and higher quality studies are needed to further demonstrate these findings to provide a more accurate and effective basis for clinical practice.

Acknowledgments

Funding: None.

Footnote

Reporting Checklist: The authors have completed the PRISMA reporting checklist. Available at <https://tp.amegroups.com/article/view/10.21037/tp-22-308/rc>

Conflicts of Interest: All authors have completed the ICMJE uniform disclosure form (available at <https://tp.amegroups.com/article/view/10.21037/tp-22-308/coif>). The authors have no conflicts of interest to declare.

Ethical Statement: The authors are accountable for all aspects of the work in ensuring that questions related to the accuracy or integrity of any part of the work are appropriately investigated and resolved.

Open Access Statement: This is an Open Access article distributed in accordance with the Creative Commons Attribution-NonCommercial-NoDerivs 4.0 International License (CC BY-NC-ND 4.0), which permits the non-commercial replication and distribution of the article with the strict proviso that no changes or edits are made and the original work is properly cited (including links to both the formal publication through the relevant DOI and the license). See: <https://creativecommons.org/licenses/by-nc-nd/4.0/>.

References

1. Bischoff JM, Koscielniak-Nielsen ZJ, Kehlet H, et al. Ultrasound-guided ilioinguinal/iliohypogastric nerve blocks for persistent inguinal postherniorrhaphy pain: a randomized, double-blind, placebo-controlled, crossover trial. *Anesth Analg* 2012;114:1323-9.
2. Huang Z, Guan Y, Feng Q, et al. Systematic Evaluation of Biyuan Tongqiao Granule in the Treatment of Chronic Sinusitis in Children Based on Meta-analysis. *Medicinal Plant* 2020;11:5-10.
3. Thomassen I, van Suijlekom JA, van de Gaag A, et al. Ultrasound-guided ilioinguinal/iliohypogastric nerve blocks for chronic pain after inguinal hernia repair. *Hernia* 2013;17:329-32.
4. Gu J, Hao C, Yan X, et al. Applied analysis of ultrasound-guided ilioinguinal and iliohypogastric nerve blocks in the radical surgery of aged cervical cancer. *Oncol Lett* 2017;13:1637-40.
5. Baird R, Guilbault MP, Tessier R, et al. A systematic review and meta-analysis of caudal blockade versus alternative analgesic strategies for pediatric inguinal hernia repair. *J Pediatr Surg* 2013;48:1077-85.
6. Wang Q, Yang Y, Yang Z, et al. Analgesic Effects of Ultrasound-Guided Iliohypogastric/Ilioinguinal Nerve Block Combined with Lateral Femoral Cutaneous Nerve Block in Total Hip Arthroplasty via Direct Anterior Approach: A Retrospective Cohort Study. *Orthop Surg* 2021;13:920-31.
7. Yimer Y, Mohammed A, Ahmed S, et al. Analgesic effect of caudal and IL/IH nerve blockade among children undergoing inguinal surgeries: A prospective cohort study, 2019. *Int J Surg Open* 2020;27:123-9.
8. Drakonaki EE, Adriaensen MEAPM, Al-Bulushi HIJ, et al. Sonoanatomy of the ilioinguinal, iliohypogastric, genitofemoral, obturator, and pudendal nerves: a practical guide for US-guided injections. *J Ultrason* 2022;22:e44-50.
9. Sohoni A, Nagdev A, Takhar S, et al. Forearm ultrasound-guided nerve blocks vs landmark-based wrist blocks for hand anesthesia in healthy volunteers. *Am J Emerg Med* 2016;34:730-4.
10. Schmutz M, Schumacher PM, Luyet C, et al. Ilioinguinal and iliohypogastric nerves cannot be selectively blocked by using ultrasound guidance: a volunteer study. *Br J Anaesth* 2013;111:264-70.
11. Yetneberk T, Chekol B, Teshome D. The efficacy of TAP block versus ilioinguinal block for post-cesarean section pain management: A systematic review and meta-analysis. *Heliyon* 2021;7:e07774.
12. McNamara KF, Biondi BE, Hernández-Ramírez RU, et al. A Systematic Review and Meta-Analysis of Studies Evaluating the Effect of Medication Treatment for Opioid Use Disorder on Infectious Disease Outcomes. *Open Forum Infect Dis* 2021;8:ofab289.
13. Wang Y, Wu T, Terry MJ, et al. Improved perioperative

- analgesia with ultrasound-guided ilioinguinal/iliohypogastric nerve or transversus abdominis plane block for open inguinal surgery: a systematic review and meta-analysis of randomized controlled trials. *J Phys Ther Sci* 2016;28:1055-60.
14. Min L, Chunyan W, Biaoxue R. Effects of valproic acid on skeletal metabolism in children with epilepsy: a systematic evaluation and meta-analysis based on 14 studies. *BMC Pediatr* 2020;20:97.
 15. Abdellatif AA. Ultrasound-guided ilioinguinal/iliohypogastric nerve blocks versus caudal block for postoperative analgesia in children undergoing unilateral groin surgery. *Saudi J Anaesth* 2012;6:367-72.
 16. Bhalla T, Sawardekar A, Dewhirst E, et al. Ultrasound-guided trunk and core blocks in infants and children. *J Anesth* 2013;27:109-23.
 17. Kupeli I, Bicer S. Contribution of Ultrasound-Guided Ilioinguinal/Iliohypogastric Block To Intraoperative Anesthesia In Children-Randomized Controlled Study. *Iran J Pediatr* 2018;28:e65146.
 18. Kiran LV, Sivashanmugam T, Kumar VRH, et al. Relative Efficacy of Ultrasound-guided Ilioinguinal-iliohypogastric Nerve Block versus Transverse Abdominis Plane Block for Postoperative Analgesia following Lower Segment Cesarean Section: A Prospective, Randomized Observer-blinded Trial. *Anesth Essays Res* 2017;11:713-7.
 19. Lee S, Tan JS. Ultrasonography-guided ilioinguinal-iliohypogastric nerve block for inguinal herniotomies in ex-premature neonates. *Singapore Med J* 2013;54:e218-20.
 20. Gao W, Chen Y, Wang W, et al. The 90% minimum effective volume and concentration of ropivacaine for ultrasound-guided median nerve block in children aged 1-3 years: A biased-coin design up-and-down sequential allocation trial. *J Clin Anesth* 2022;79:110754.
 21. Flack SH, Martin LD, Walker BJ, et al. Ultrasound-guided rectus sheath block or wound infiltration in children: a randomized blinded study of analgesia and bupivacaine absorption. *Paediatr Anaesth* 2014;24:968-73.
 22. Grosse B, Eberbach S, Pinnschmidt HO, et al. Ultrasound-guided ilioinguinal-iliohypogastric block (ILIH) or perifocal wound infiltration (PWI) in children: a prospective randomized comparison of analgesia quality, a pilot study. *BMC Anesthesiol* 2020;20:256.
 23. Harju J, Kalliomäki ML, Leppikangas H, et al. Surgical pleth index in children younger than 24 months of age: a randomized double-blinded trial. *Br J Anaesth* 2016;117:358-64.
 24. Markham SJ, Tomlinson J, Hain WR. Ilioinguinal nerve block in children. A comparison with caudal block for intra and postoperative analgesia. *Anaesthesia* 1986;41:1098-103.
 25. Weintraud M, Lundblad M, Kettner SC, et al. Ultrasound versus landmark-based technique for ilioinguinal-iliohypogastric nerve blockade in children: the implications on plasma levels of ropivacaine. *Anesth Analg* 2009;108:1488-92.
 26. Willschke H, Marhofer P, Bösenberg A, et al. Ultrasonography for ilioinguinal/iliohypogastric nerve blocks in children. *Br J Anaesth* 2005;95:226-30.
 27. Faramawy SAMS, Abdel-Latif SAM, Abdel-Atte MASM, et al. Comparison between Ultrasound Guided Transversus Abdominis Plane Block versus Ultrasound Guided IlioInguinal/Iliohypogastric Nerves Block for Postoperative Analgesia in Patients Undergoing Unilateral Oblique Inguinal Hernia Repair Under General Anesthesia. *QJM* 2021;114: hcab086. 106.
 28. Zhou Y, Chen M, Zhang Y, et al. Ilioinguinal/iliohypogastric nerve block versus transversus abdominis plane block for pain management following inguinal hernia repair surgery: A systematic review and meta-analysis of randomized controlled trials. *Medicine (Baltimore)* 2019;98:e17545.
 29. Bhatia N, Sen IM, Mandal B, et al. Postoperative analgesic efficacy of ultrasound-guided ilioinguinal-iliohypogastric nerve block compared with medial transverse abdominis plane block in inguinal hernia repair: A prospective, randomised trial. *Anaesth Crit Care Pain Med* 2019;38:41-5.
 30. Kaçmaz M, Bolat H. Comparison of spinal anaesthesia versus ilioinguinal-iliohypogastric nerve block applied with tumescent anaesthesia for single-sided inguinal hernia. *Hernia* 2020;24:1049-56.
 31. Bolzan JA, Lino de Oliveira C. Protocol for systematic review and meta-analysis of the evidence linking hippocampal neurogenesis to the effects of antidepressants on mood and behaviour. *BMJ Open Sci* 2021;5:e100077.
- (English Language Editor: L. Huleatt)

Cite this article as: Chen J, Song D, Zheng G, Luo Y. Systematic review and meta-analysis of the effect of nerve block under ultrasound in ilioinguinal/iliohypogastric in children. *Transl Pediatr* 2022;11(10):1604-1614. doi: 10.21037/tp-22-308