

A rare case of adrenal collision tumor: Myelolipoma and schwannoma in the adrenal gland

SAGE Open Medical Case Reports
Volume 8: 1–4
© The Author(s) 2020
Article reuse guidelines:
sagepub.com/journals-permissions
DOI: 10.1177/2050313X20921074
journals.sagepub.com/home/sco



Mariangela Gomez  and Rohin Mehta

Abstract

Adrenal collision tumors refer to coexistence of two adjacent, but histologically distinct, neoplasms involving the adrenal gland without histologic admixture at the interface. Myelolipoma is a rare but benign neoplasm. As its name implies, displays both mature adipose tissue and hematopoietic elements. These are usually unilateral and asymptomatic. Schwannomas, tumors derived from the peripheral nerve sheath, are also uncommon lesions in the adrenal gland. Here, we present a rare case of a 65-year-old male with clinical history of abdominal aortic aneurysm who was found to have a 13-cm “incidentaloma” by interventional radiologist during his aortic endograft control. Giving the size of the mass, team decided to excise it, and histopathological examination was performed. While most incidentally discovered adrenal tumors are benign, surgical excision is recommended in large lesions to exclude malignancy, avoid hemorrhage, and/or acute adrenal insufficiency. Given the rarity of such entity, its clinical course and prognosis remains unclear.

Keywords

Adrenal incidentaloma, myelolipoma, schwannoma

Date received: 27 August 2019; accepted: 27 March 2020

Introduction

Myelolipoma is a rare, benign neoplasm composed of mature adipose and hematopoietic tissue, resembling bone marrow that predominantly occurs in the adrenal gland.¹ Females and males are equally affected with a peak prevalence of 50 and 70 years of age, and slightly right side predilection.² Myelolipomas have been reported at various sites, including the presacral region, pelvis, retroperitoneum, lung, thoracic spine, mediastinum, spleen, liver, mesentery, and lymph nodes.³

Schwannomas are a type of peripheral nerve tumor composed of a cellular component (Antoni A) with nuclear palisading around fibrillary process (Verocay bodies) and a myxoid hypocellular component (Antoni B). These lesions are benign, with a slow growth pattern and manifest mostly in the extremities, head, and neck. Its presentation as an adrenal mass is exceedingly rare.⁴

To date, this is the second case reported in the literature of adrenal myelolipoma (AML) coexisting with a schwannoma.

Case report

A 65-year-old male patient with a history of abdominal aortic aneurysm repair was found to have an incidental 13-cm

mass in the left adrenal gland identified during imaging of the aortic endograft during follow-up with his vascular surgeon. He had a past medical history of significant cardiovascular and peripheral vascular disease, status post coronary artery angioplasty with stent placement, abdominal aortic aneurysm repair, and femoral artery bypass. He was a former smoker, hypertensive, and had a myocardial infarction 25 years ago.

A computed tomography (CT) angiogram with contrast identified a large, fat-containing lesion within the left adrenal gland. There were also right adrenal nodules that were fat containing, measuring each up to 2 cm in diameter. The differential diagnosis based on imaging included myelolipoma or liposarcoma. Myelolipomas approaching 10 cm are at risk for internal hemorrhage, and since malignancy could not be completely ruled out, removal of the lesion was recommended. Robotic-assisted laparoscopic left adrenalectomy

Department of Pathology, SUNY Upstate Medical University, Syracuse, NY, USA

Corresponding Author:

Mariangela Gomez, Department of Pathology, SUNY Upstate Medical University, 750 E. Adams St., Syracuse, NY 13210, USA.

Email: gomezma@upstate.edu



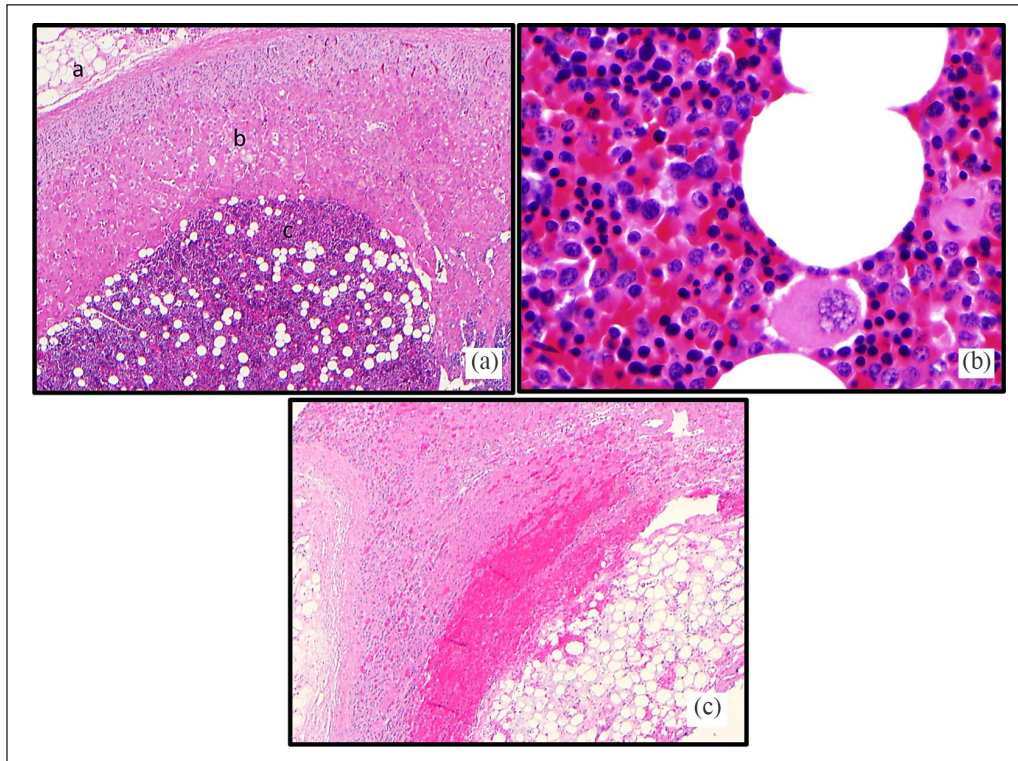


Figure 1. (H&E): (A) Histological examination showed a neoplasm composed of mature adipocytes (a), adrenal cortex (b), and hematopoietic elements (c) (5×), (B) Trilineage hematopoiesis with erythroid precursors, myeloid cells, and megakaryocytes (40×), and (C) Benign adipose tissue and hemorrhage within the adrenal gland parenchyma (5×).

was performed. Pre-operative labs showed no chemical evidence of a hypersecretory tumor or adrenal insufficiency. Histopathological report demonstrated a $13.1 \times 11.4 \times 5.3$ cm brown, nodular mass, weighting 358 g. Microscopic sections showed multiple islands of hematopoietic cells with trilineage maturation admixed with benign adipose tissue within the adrenal parenchyma, consistent with a myelolipoma and focal areas of hemorrhage (Figure 1(a)–(c)). In addition, a focus adjacent to the myelolipoma, of interlacing fascicles of spindle cells with nuclear palisading (Verocay bodies), was seen, staining positive for S100 by immunohistochemistry, and was subsequently identified as a schwannoma (Figure 2(a)–(c)).

Discussion

The accessibility to imaging studies has contributed to the increasing detection of AMLs, now constituting up to 10%–15% of incidental adrenal masses.³ These are usually smaller than 4 cm in diameter, with the largest reported adrenal myelolipoma measuring $31 \times 24.5 \times 11.5$ cm, and weighing 6 kg.⁵ Surgical excision is usually indicated in lesions over 6 cm due to chance of necrosis, rupture, retroperitoneal hemorrhage, hemorrhagic shock, and also in cases where the patient is either symptomatic, presenting with bilateral involvement (extremely rare) or malignancy is suspected.

Radiologically, differential diagnosis for this specific case where chemical analysis did not revealed hormonal secretion may include lipoma, angiomyolipoma, retroperitoneal sarcoma, and adrenal adenoma. A homogeneous fatty adrenal mass is diagnostic of myelolipoma, but when non-homogeneous characteristics are present, clinical team should rely on histopathological evaluation as a tool to exclude malignancy.^{3,6} The use of image guided needle biopsy could be performed to confirm the diagnosis, but this method could potentially complicate the clinical status of the patient by causing iatrogenic rupture and subsequent bleeding.⁷ Management should be performed on a case-by-case basis.

These types of tumor had been previously associated with medical conditions such as obesity, hypertension, atherosclerosis, diabetes mellitus, and malignancy.⁸ Stressful lifestyle and an unbalanced diet might also play a role, according to studies.^{9,10} But it is unclear whether myelolipomas are truly neoplastic, or if they are on a spectrum with the reactive change of extramedullary hematopoiesis within tissues. They differ from extramedullary hematopoiesis by having a lipomatous component of benign fatty tissue within the same lesion that is without hematopoietic elements. Its relationship with different adrenal disorders like adrenal carcinoma, Cushing's syndrome, congenital 21-hydroxylase deficiency, and pheochromocytoma is well documented. Although

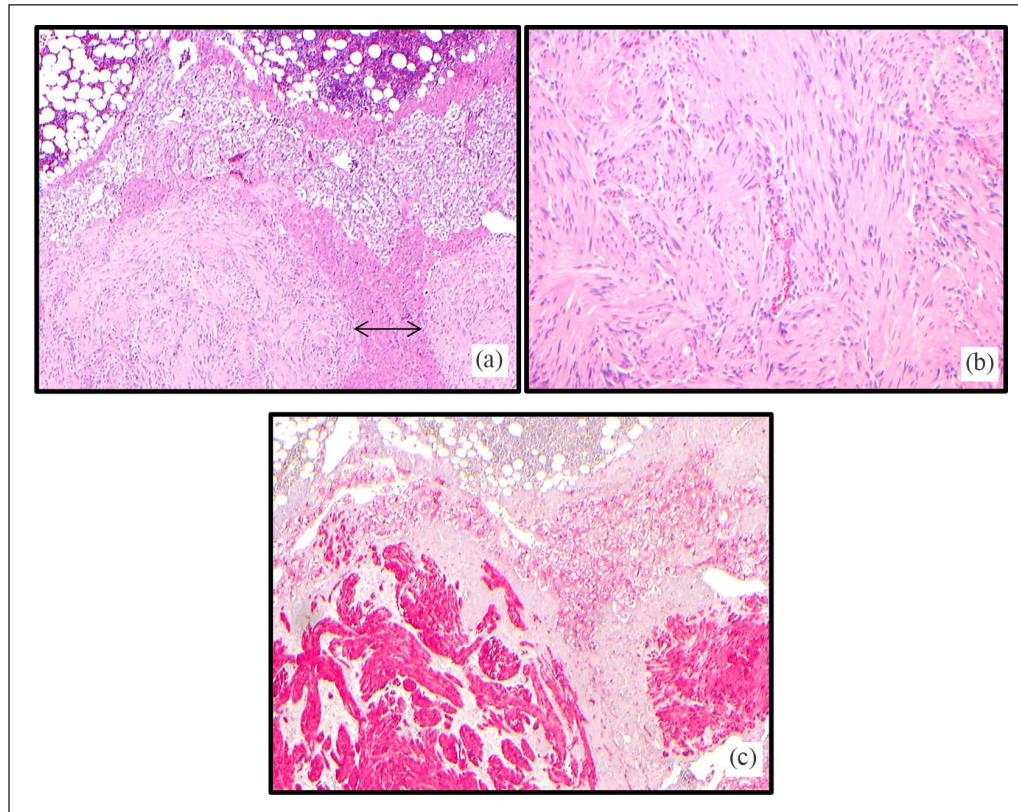


Figure 2. (a) Spindle cell lesion with nuclear palisading/Verocay bodies (arrows; 5 \times), (b) Verocay bodies (40 \times), and (c) staining positive for S100 (5 \times).

multiple endocrine neoplasia type 1 (MEN-1) association has been suggested in some of the reported cases, complete DNA sequencing yielded no hint that defects of the MEN-1 gene is responsible for the formation of AML.¹¹ Low levels of p53 proteins in AML suggest the role of tumor suppressor gene in its tumorigenesis.¹²

Ancient schwannomas, also described as degenerative neurilemmomas, are a rare variant first described by Ackerman and Taylor,¹³ displaying degenerative changes such as cysts formation, calcification, hemorrhage, hyalinization, and nuclear atypia. These findings might represent an obstacle for the pathologist when identifying schwannomas and the use of immunohistochemistry will be essential to confirm diagnosis, with spindle cell showing positivity for S-100 protein, laminin, and/or vimentin.

At the time of this report, only one case of adrenal myelolipoma coexisting with a schwannoma had been reported, Yang et al.,¹⁴ a 47-year-old woman presented with abdominal pain for 3 months. Imaging study was performed, and patient was diagnosed with acute cholestatic hepatitis, and cholelithiasis, but also a 7-cm adrenal mass. Surgical resection was indicated for diagnosis and therapeutic reasons, with no recurrence described after 2 years of follow-up.

The lack of additional reported cases in the literature referring to this rare entity makes it difficult to the clinical team to predict the clinical outcome of the patients presenting with

adrenal myelolipoma. But we remain expectant to confirm its non-neoplastic behavior.

Conclusion

Given the difficulty of exclude malignancy relying only on imaging, the decision of surgical management of adrenal “incidentalomas” should be considered on an individual basis. Even though most of these tumors turn out to be benign (as in our case), complete excision may warranty an accurate final diagnosis, cessation of the symptomatology (if any), and lower chances of acute events that might compromise the life of the patient, such as rupture, hemorrhage, or hormone disbalances.

Declaration of conflicting interests

The author(s) declared no potential conflicts of interest with respect to the research, authorship, and/or publication of this article.

Ethics approval

Our institution does not require ethical approval for reporting individual cases or case series.


Funding

The author(s) received no financial support for the research, authorship, and/or publication of this article.

Informed consent

Written informed consent was obtained from the patient(s) for their anonymized information to be published in this article.

ORCID iD

Mariangela Gomez  <https://orcid.org/0000-0001-7346-201X>

References

1. Feng C, Jiang H, Ding Q, et al. Adrenal myelolipoma: a mingle of progenitor cells? *Med Hypotheses* 2013; 80(6): 819–822.
2. Lam AK. Lipomatous tumours in adrenal gland: WHO updates and clinical implications. *Endocr Relat Cancer* 2017; 24(3): R65–R79.
3. Blake MA, Kalra MK, Sweeney AT, et al. Distinguishing benign from malignant adrenal masses: multi-detector row CT protocol with 10-minute delay. *Radiology* 2006; 238(2): 578–585.
4. Bittner JG IV and Brunt LM. Evaluation and management of adrenal incidentaloma. *J Surg Oncol* 2012; 106: 557–564.
5. Brogna A, Scalisi G, Ferrara R, et al. Giant secreting adrenal myelolipoma in a man: a case report. *J Med Case Rep* 2011; 5: 298.
6. Rao P, Kenney PJ, Wagner BJ, et al. Imaging and pathologic features of myelolipoma. *Radiographics* 1997; 17(6): 1373–1385.
7. Bhansali A, Dash RJ, Singh SK, et al. Adrenal myelolipoma: profile of six patients with a brief review of literature. *Int J Endocrinol Metab* 2003; 1: 33–40.
8. Hofmockel G, Dammrich J, Manzanilla Garcia H, et al. Myelolipoma of the adrenal gland associated with contralateral renal cell carcinoma: case report and review of the literature. *J Urol* 1995; 153(1): 129–132.
9. Decmann Á, Perge P, Toth M, et al. Adrenal myelolipoma: a comprehensive review. *Endocrine* 2018; 59(1): 7–15.
10. Liu W, Chen W and He X. An unusual cause of Cushing's syndrome and virilization. *Gastroenterology* 2015; 149(4): e5–e6.
11. Schulte KM, Heinze M, Mengel M, et al. Complete sequencing and mRNA expression analysis of the MEN-I gene in adrenal myelolipoma. *Horm Metab Res* 2000; 32(5): 169–173.
12. Adleff V, Rác K, Tóth M, et al. p53 protein and its messenger ribonucleic acid in human adrenal tumors. *J Endocrinol Invest* 1998; 21: 753–757.
13. Ackerman LV and Taylor FH. Neurogenous tumors within the thorax; a clinicopathological evaluation of forty-eight cases. *Cancer* 1951; 4: 669–691.
14. Yang K-F, Lee H-Y, Wu W-J, et al. Ancient schwannoma and myelolipoma coexist in an adrenal incidentaloma. *Urologic Sci* 2015; 26: 134–138.